

## ● Review paper

## RECOMMENDATIONS FOR FETAL ECHOCARDIOGRAPHY IN TWIN PREGNANCY IN 2016

**Authors:**

Katarzyna Leszczyńska<sup>1</sup>, Krzysztof Preis<sup>1</sup>, Maria Respondek-Liberska<sup>2,3</sup>, Maciej Słodki<sup>3,4</sup>, Dennis Wood<sup>5</sup>, Stuart Weiner<sup>6</sup>, Ulli Gembruch<sup>7</sup>, Giuseppe Rizzo<sup>8</sup>, Reuven Achiron<sup>9</sup>, Jay D Pruetz<sup>10</sup>, Mark Sklansky<sup>11</sup>, Bettina Cuneo<sup>12</sup>, Birgit Arabin<sup>13</sup>, Isaac Blickstein<sup>14</sup>, The International Prenatal Cardiology Collaboration Group.

1. Department of Obstetrics, Medical University of Gdansk, Poland, 2. Department of Diagnoses and Prevention Fetal Malformations, Medical University of Lodz, Poland, 3. Department of Prenatal Cardiology, Polish Mother's Memorial Hospital Research Institute, Lodz, Poland, 4. Institute of Health Sciences, The State School of Higher Professional Education in Plock, Poland, 5. Department of Obstetrics and Gynecology, Thomas Jefferson University, Philadelphia, Pennsylvania, USA, 6. Thomas Jefferson University and Hospitals, Philadelphia, Pennsylvania, USA, 7. Department of Obstetrics and Prenatal Medicine, University Bonn Medical School, Bonn, Germany, 8. Department of Obstetrics and Gynecology, Università Roma Tor Vergata, Ospedela Fatebenefratelli Isola Tiberina, Rome, Italy, 9. Department of Obstetrics and Gynecology, The Chaim Sheba Medical Center Tel-Hashomer, Sackler School of Medicine, Tel-Aviv University, Israel, 10. Division of Pediatric Cardiology, Children's Hospital Los Angeles, Los Angeles, CA, USA; Keck School of Medicine, University of Southern California, Los Angeles, California, USA, 11. Division of Pediatric Cardiology, Department of Pediatrics, David Geffen School of Medicine, Los Angeles, California, USA, 12. Department of Pediatric Cardiology, Then Fetal Heart Program, Colorado Fetal Care Center, Colorado Institute for Maternal Fetal Health, Children's Hospital Colorado, University of Colorado School of Medicine, Aurora, Colorado, USA, 13. Center for Mother and Child, Philipps University, Marburg, Germany, 14. Department of Obstetrics and Gynecology, Kaplan Medical Center, 76100 Rehovot and the Hadassah-Hebrew University School of Medicine, Jerusalem, Israel.

Prenat Cardio 2016 Jan; 6(1):6-15  
DOI: 10.1515/pcard-2016-0001

**Abstract**

Progress in the fields of fetal cardiology and fetal surgery have been seen not only in singleton pregnancies but also in multiple pregnancies. Proper interpretation of prenatal echocardiography is critical to clinical decision making, family counseling and perinatal management for obstetricians, maternal fetal medicine specialists, neonatologists and pediatric cardiologists. Fetal echocardiography is one of the most challenging and time-consuming prenatal examinations to perform, especially in multiple gestations. Performing just the basic fetal exam in twin gestations may take an hour or more. Thus, it is not practical to perform this exam in all cases of multiple gestations. Therefore our review and recommendations are related to fetal echocardiography in twin gestation.

**Key words:** fetal echocardiography, twin pregnancy, TTTS, TRAP, TAPS, SIUGR

**INTRODUCTION**

Progress in the fields of fetal cardiology and fetal surgery have been seen not only in singleton pregnancies but also in multiple pregnancies<sup>1,2</sup>. Proper interpretation of prenatal echocardiography is critical to clinical decision making, family counseling and perinatal management for obstetricians, maternal fetal medicine specialists, neonatologists and pediatric cardiologists. Fetal echocardiography (FE) is one of the most challenging and time-consuming prenatal examinations to perform, especially in multiple gestations. Performing just the basic fetal exam in twin gestations may

**How to Cite this Article:**

Leszczyńska K, Preis K, Respondek-Liberska M, Słodki M, Wood D, Weiner S, Gembruch U, Rizzo G, Achiron R, Pruetz J, Sklansky M, Cuneo B, Arabin B, Blickstein I, The International Prenatal Cardiology Collaboration Group.:  
**Recommendations for fetal echocardiography in twin pregnancy in 2016**  
Prenat Cardio 2016 Jan; 6(1):6-15



take an hour or more<sup>3</sup>. Thus, it is not practical to perform this exam in all cases of multiple gestations.

In select cases fetal echocardiography is recommended to assess fetal well being, confirm the safety for pregnancy continuation or provide warnings for changing perinatal management. There have been multiple prior recommendations for FE in singleton pregnancies with few guidelines reported on twin gestation<sup>4,5,6</sup>. Furthermore, prior recommendations for twins were focused on ultrasound and perinatal management and not specific to FE.<sup>7,8</sup> We have assembled a group of representatives from multiple centers to create a review of

FE recommendations in twin gestations based on existing publications and our own experience..

Recent data from the United States, England and Wales demonstrate decreasing rates of higher-order multiple births and represent, for the first time, a striking change in trend when compared with the previous steep 4-fold increase since the early 1980s. However, the incidence of twin pregnancies continues to increase. The reasons for these changes are probably new embryo transfer guidelines and wider availability of multi-fetal pregnancy reduction procedures. Because actual numbers of higher-order multiples are by far lower than the number of twins, and because twins are predictably associated with significant perinatal morbidity and mortality, the implications of the increasing twin birth rates are alarming<sup>9</sup>.

Therefore our review and recommendations are related to fetal echocardiography in twin gestation.

### GENERAL CONSIDERATIONS:

During the 1<sup>st</sup> trimester, the presence of multiple pregnancy should be documented on ultrasound images; gestational age according to the last menstrual period and fetal biometry should be provided separately for each fetus, chorionicity and amnionicity should be determined and shown on the images as recommended by ISUOG guidelines<sup>8</sup>. During subsequent visits, this documentation

with images should be presented to an obstetrician, and in selected cases to a fetal cardiologist, maternal fetal medicine specialist, neonatologist, or specialist in genetics.

In patients whose twin pregnancy is a result of IVF, gestational age can be determined from the date of embryonic transfer (optimally, the data on the type of IVF technique, number of embryos transferred, and center where it was performed should be mentioned in the report).

Genetic testing during the 1<sup>st</sup> trimester should follow the recommendations for singleton pregnancies, depending on the accuracy of pre-implantation genetic diagnosis or cell-free DNA for multiple pregnancies.

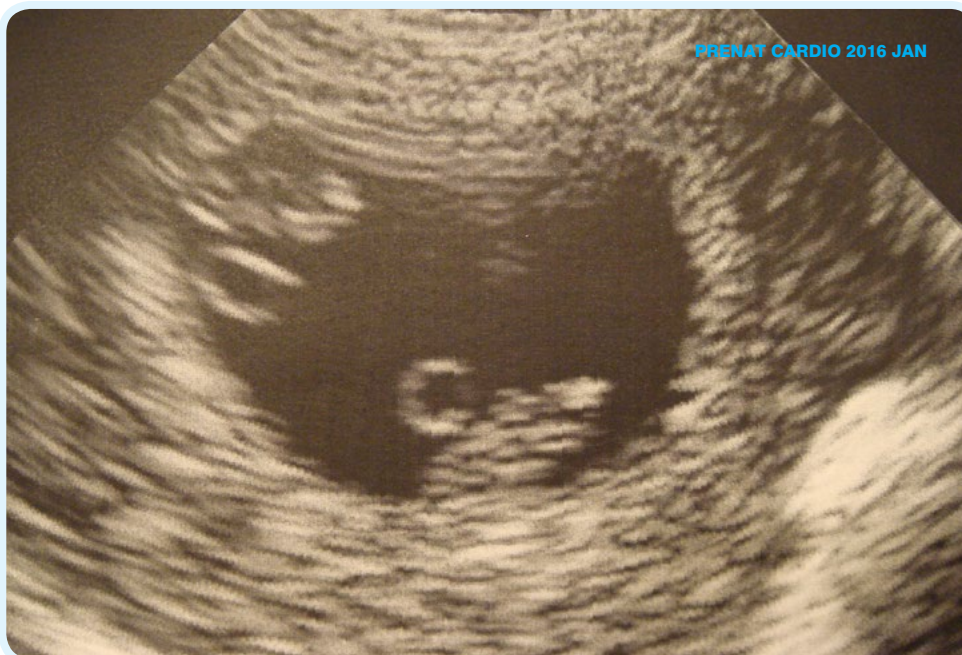The early multiple pregnancy should be confirmed after 12<sup>th</sup> weeks of pregnancy and in case of “vanishing” twin the care in such pregnancy should be the same as in singleton pregnancy<sup>10</sup>, although analysis or cell-free DNA testing may not be as accurate in these cases. In case of conjoined twins several options would exist including termination of pregnancy<sup>11</sup>. However this review would not be related to the conjoined twin pregnancy despite that conjoined twins might be a specific prenatal fetal cardiac problem<sup>12</sup>

Fetal biometry in the 2<sup>nd</sup> and 3<sup>rd</sup> trimester should be assessed based on combination of at least 3 parameters: BPD, HC, AC and FL for each of the twins.

For symmetrical twins in dichorionic pregnancy further ultrasound exams should be performed at 3- to 4-week intervals starting from week 18<sup>th</sup>, and nuchal translucency measurement may be of importance..

For symmetrical twins in monochorionic pregnancy further ultrasound exams should be performed at 2-week intervals starting from week 16<sup>th</sup><sup>13,14</sup>, increasing to every week if abnormalities in size, amniotic fluid, fetal bladder, or umbilical artery Doppler finding are noted

In the case of symmetrical growth of monochorionic twins optimally fetal echocardiographic exams should be conducted as planned procedure at 18-22 weeks of gestation, or earlier in very high risk cases (e.g., diabetics with elevated hemoglobin A1C levels or enlarged nuchal translucency)



Fot. 1 Twin pregnancy at 6 weeks of gestation suspected for monochorionicity. This photo should be kept for the whole pregnancy and later on be included in newborns medical history

Position of the heart, thoracic and abdominal organs
Assessment of heart size in relation to the chest (h/c index)
Assessment of venous inflow, atrioventricular and ventriculoarterial junctions
Assessment of heart chamber size and proportion – routine 2d measurements and m-mode scans with determination of left ventricular ejection fraction
Assessment of cardiac septa (interventricular septum: integrity, thickness, degree of hypertrophy if any; interatrial septum: presence of foramen ovale (fo), presence of fo shunting, its direction and presence of potential restrictions)
Assessment of cardiac function (heart rhythm, atrioventricular conduction: doppler-based measurement, presence of conduction disorders or arrhythmia: m-mode scans, doppler, myocardial contractility: tei index for the left and right ventricle, tapse, mapse)
Assessment of heart valve morphology and function: 2d echocardiography, degree of valve stenosis/insufficiency: doppler echocardiography
Assessment of large vessels (ventriculoarterial junction, diameters and proportion of the vessels, doppler evaluation of blood flow in the ascending aorta, aortic arch, aortic isthmus, pulmonary trunk, arterious duct, venous duct, umbilical artery and vein, flow velocity in the middle cerebral artery)

Table 1. Echocardiographic parameters to be determined in every twin:

Criterion/Degree	I	II	III	IV	V
Polyhydramnios in the recipient twin/ oligohydramnios in the donor twin	+	+	+	+	+
The urinary bladder of the donor twin is not visible	-	+	+/-	+/-	+/-
Abnormal arterial and venous flows	-	-	+	+	+
Signs of hydrops in either fetus	-	-	-	+	+
Fetal demise	-	-	-	-	+

Table 2. Quintero scale (1999)

	Parameter	Score	
<b>Donor</b>	UA flow	0 – normal	1 – decreased diastolic flow
<b>Recipient</b>	Ventricular hypertrophy	0 – none	1 – present
	Cardiac dilation	0 – < 1/3	1 – 1/3-1/2
	Ventricular dysfunction	0 – normal	1 – SF < 30
	MV regurgitation	0 – none	1 – mild
	TV regurgitation	0 – no	1 – mild
	MV inflow	0 – biphasic	1 – monophasic
	TV inflow	0 – biphasic	1 – monophasic
	DV flow	0 – normal	1 – absent diastolic flow
	UV	0 – no pulsation	1 – pulsations
	RVOT	0 – PA > Ao	1 – PA = Ao 2 – PA < Ao
	PA regurgitation	0 – none	1 – present

UA – umbilical artery, AREDF – absent/reversed end-diastolic flow, SF – shortening fraction, MV – mitral valve, TV – tricuspid valve, DV – venous duct, UV – umbilical vein, RVOT – right ventricular outflow tract, PA – pulmonary valve diameter, Ao – aortic valve diameter, RVOTO – right ventricular outflow tract obstruction

Table 3. CHOP Scoring System according to Rychik (2007)

In the case of asymmetrical growth of monozygotic twins in the 1<sup>st</sup> trimester, fetal echocardiographic exams should be performed earlier, at 14-15 weeks, as the so-called urgency exam.

In monozygotic pregnancies the presence of specific syndromes, such as TTTS, TRAP, TAPS and SIUGR, should be ruled out at every ultrasound exam. In case of early suspicion of one of these syndromes fetal echocardiography is recommended as early as possible.

The volume of amniotic fluid in twins should be estimated on the basis of maximal volume pocket (MVP), rather than based on amniotic fluid index (AFI) as recommended in singleton pregnancies<sup>13,14</sup>.

## DICHORIONIC PREGNANCY

Examinations conducted according to the same schedule as for singleton pregnancies<sup>4,5,6</sup>

**To confirm normal heart anatomy in both twins. In case of abnormalities we would recommend:**

**Twin A with an isolated congenital heart defect (CHD) and twin B healthy:**

Although no clear recommendations regarding intrauterine pharmacotherapy or surgical treatment have been established thus far in either critical CHD or posing a risk of heart failure, these options should be discussed with a pregnant woman and her partner.

**Twin A with CHD and extracardiac malformation and twin B healthy:**

While the abnormal fetus can be a subject of selective termination, this, however, does not exclude the risk of complications (e.g. premature ruptured membranes, miscarriage, preterm birth) in the normally growing fetus.<sup>15</sup>

In the situation of a cardiac problem in one of the twins, for instance CHD or even a tumor, both fetuses require fetal echocardiography and longitudinal monitoring to avoid premature delivery and ensure proper development of both fetuses.

Congestive heart failure in one of the twins requires the consideration of in

Fetal hydrops	Normal (2 points) None	1 point Ascites, pleural effusion, or pericardial effusion	2 points Skin edema
Abnormal venous Doppler Cardiomegaly (CT ratio = cardiac area/thoracic area)	Normal venous Doppler CT ratio $\leq 0.35$	Venous duct atrial systolic reversal CT ratio $>0.35$ & $<0.50$	Umbilical venous pulsations CT ratio $>0.50$
Abnormal myocardial function	Ventricular SF $>0.28$ & no valve regurgitation	SF $<0.28$ or TR or semilunar valve regurgitation	TR + dysfunction or any MR
Abnormal arterial Doppler	Normal umbilical artery diastolic flow	Absent end-diastolic flow in the umbilical artery	Reverse end-diastolic flow in the umbilical artery

CT – cardiothoracic, MR – mitral regurgitation, SF – shortening fraction, TR – tricuspid regurgitation

Table 4. Cardiovascular Profile Score by Shah (2008)

utero treatment before making a decision regarding emergency cesarean section.<sup>16</sup>

### MONOCHORIONIC PREGNANCY

Ultrasound examination between 11w0d and 13w6d performed according to the FMF standards; a difference in nuchal translucency (NT) between twins may be the first manifestation of abnormal cardiac function and twin-to-twin transfusion syndrome (TTTS)<sup>16,17</sup>.

Whenever NT of one fetus exceeds 3.5 mm or 90<sup>th</sup>% for CRL, an early echocardiographic examination is recommended at about 14 weeks, since cardiologic abnormalities may often precede the other later sonographic markers of TTTS<sup>16,17,18</sup>.

In case of symmetric twin growth and no abnormalities on ultrasound exam and echo exam at 14<sup>th</sup> week, further control exams should be scheduled at 2-week intervals.

In case of a difference in fetuses size (CRL  $> 1$ wk GA) or NT measurements, or abnormal flow in tricuspid valve (TV) in one of the twins, further ultrasound exams should be scheduled once a week.

In case of a sudden increase in abdominal size of the pregnant woman, raising suspicion of a progressive polyhydramnios, urgent ultrasonography and

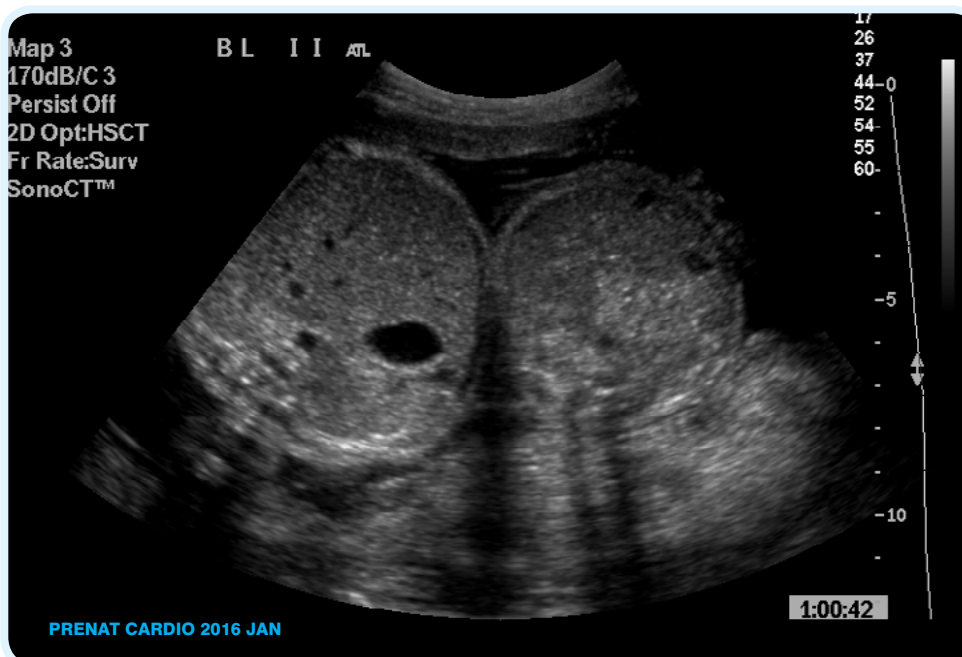
echocardiography should be performed irrespective of gestational age.

#### Concerns for TTTS or selective intrauterine growth restriction (SIUGR):

1. Twin gestations should be referred to tertiary center which specialize in fetal diagnosis and fetal therapy for further surveillance.
2. At the tertiary center baseline examination including complete fetal echocardiography to confirm the diagnosis, determine current hemodynamic status of both fetuses is performed.

Serial fetal echocardiography and Doppler recordings may show hemodynamic changes in the fetal circulation of discordant twins. Sometimes these changes may be temporal<sup>18</sup>. In the majority of cases, however, the abnormalities can progress:

The recipient twin may have progressive volume and pressure overload, congestive heart failure, and hydrops. Recipient twin echocardiographic findings, which typically include valvar regurgitation/stenosis, ventricular hypertrophy, and diastolic/systolic dysfunction, tend to occur predominantly in the right heart, with relative sparing of the left heart. To prevent the progression to fetal heart failure and hydrops surgical treatment options are



Fot. 2. The twin pregnancy with discrepancy in abdominal size. Without photo from the first trimester and without fetal echo evaluation no simple diagnosis is possible at this stage.

offered in the majority of fetal centers. Based on the precise diagnosis and twins condition a surgical treatment is discussed with parents to be ( e.g. selective laser therapy)<sup>19</sup>.

3. In the case of a surgical procedure, control fetal echocardiography examinations are recommended: in our Polish centers (in Gdansk and in Lodz) we would perform echo a day before exam and post-procedure, within the next 24 hours, on the 3<sup>rd</sup> and 7<sup>th</sup> day (in a hospital setting), and then at 14-day intervals (in an outpatient setting). According to J. Pruetz it usually performed FE a pre-op and 14-28 days post op. Subsequent FE are performed if fetal CHD persists or CHD is suspected.

Laser ablation of placental anastomoses might influence myocardial function in the postoperative period and only detailed fetal echocardiography may reveal early changes in fetal myocardial contractility<sup>20</sup>. Shortened IRT intervals or improved shortening fraction of the ventricles may reflect an improvement of diastolic or systolic (respectively) function in recipients<sup>21</sup>.

Optimally each examination should include parameters listed in Table 1, however Willruth and group of Gembruch would also recommend speckle tracking if available<sup>22,23</sup>.

### SINGLE FETAL DEMISE

Twin pregnancies are at higher risk for fetal mortality when compared with singleton pregnancies. Single fetal demise occurs in 3.7 – 6.8 % of all twin pregnancies and considerably increases the complication rate in the co-twin including fetal loss, premature delivery, and end-organ damage<sup>24</sup>, especially of the fetal brain.

In the case of intrauterine demise of one of the twins so far attention was focus on central nervous system on the survivor twin or umbilical blood flow<sup>25,26,27</sup>, however nowadays it is not enough and fetal echocardiography is strongly recommended in such a case<sup>28</sup>

Stage	Donor	Recipient	Recipient cardiomyopathy
I	Oligohydramnios	Polyhydramnios	None
II	Bladder absent	Bladder seen	None
III	Abnormal Doppler	Abnormal Doppler	None
III A	+/- Abnormal Doppler	+/- Abnormal Doppler	Mild
III B	+/- Abnormal Doppler	+/- Abnormal Doppler	Moderate
III C	+/- Abnormal Doppler	+/- Abnormal Doppler	Severe
IV	Hydrops	Hydrops	
V	Death	Death	

Table 5. Cincinnati Scale by Habli (2008)

## ULTRASOUND AND FETAL ECHOCARDIOGRAPHY SCALES FOR TWINS

**For better definition and progress of abnormalities in TTTS several scales had been published so far:**

### Quintero Scale of TTTS from 1999<sup>29</sup> (Table 2)

The scale is based on ultrasonographic assessment of amniotic fluid and the fetal bladders, and Doppler evaluation of blood flow, without inclusion of echocardiographic abnormalities.

### Children's Hospital of Philadelphia (CHOP) scoring system according to J. Rychik<sup>30</sup> et al. from 2007 (Table 3)

This system focuses more on cardiac findings, particularly in the recipient twin. Each parameter is scored depending on its presence and severity, with the maximum score of 20. There are four grades of TTTS severity, from I (mild) to IV (most severe). Such detailed assessment requires appropriate echocardiographic preparation of an examiner and sufficient amount of time for the examination, but has not only diagnostic role but also perhaps prognostic value<sup>31</sup>

### Cardiovascular Profile Score (CVPS) by Shah<sup>32</sup> (Table 4)

Aside from Doppler evaluation of blood flow in the umbilical vessels and potential fetal hydrops, also presence of cardiomegaly and myocardial performance (MPI or TEI index) are considered<sup>32,38,39,40</sup>.

### Cincinnati Scale by Habli et al.<sup>33</sup> (Table 5)

The scale is based on the presence and degree of atrioventricular valve insufficiency, myocardial thickness and ventricular function expressed by myocardial performance index (MPI, Tei-Index) in the recipient twin to assess for cardiomyopathy and upstage patients for surgery.

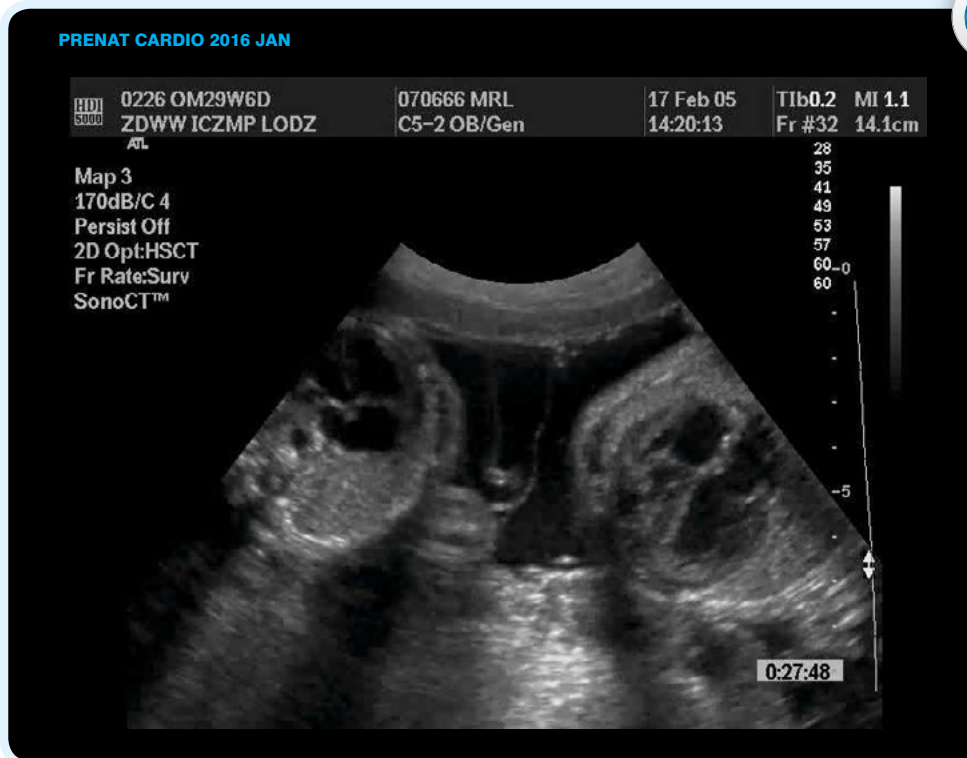
### Stirnemann Scale<sup>34</sup> (Table 6)

According to the authors of this scale, the most sensitive marker of fetal heart function is myocardial performance index, Tei-Index.

**Other anomalies in twin pregnancy that benefit from fetal echocardiography monitoring:**

## TWIN REVERSED ARTERIAL PERFUSION (TRAP) SEQUENCE

TRAP sequence is associated with abnormal reverse flow from one fetus to the other, without passing the blood through placental capillaries. Consequently, one fetus receives non-oxygenated blood from the other, which eventually results in cardiac arrest and development of the so-called acardiac fetus. The other fetus, donor of the blood is also referred to as a pump twin; the management of TRAP sequence should be aimed at survival of the pump



twin with digitalis preparations), intrauterine blood transfusion for evidence of anemia in the pump twin, or early delivery. Blood flow parameters of the pump twin should be assessed regardless of the ultrasonographic scales for fetuses with TTTS.

SIUGR is associated with unequal placental sharing of various degrees between each twin. This results in progressive growth restriction in one fetus and lack of any abnormalities in the other. SIUGR twins can be mistaken for a diagnosis of TTTS on the basis of apparent differences in fetal biometry. Placental area shared by the “smaller” fetus and resultant timing of manifestation are the key factors determining the outcome of SIUGR. The smaller the placental area per

Fig. 3 (Cine) Twin pregnancy at 29 weeks of gestation with different fetal heart size and fetal echo functional abnormalities due to Twin Twin Transfusion Syndrome (very late diagnosis)  
 Play the movie directly in the pdf by clicking on the content

fetus. In many cases, the reversed flow between fetuses resolves spontaneously, which is the most favorable outcome. However, an intervention is required in the remaining cases, as growth of the acardiac fetus results in progressively increasing myocardial strain in the pump fetus<sup>35</sup>. One option of treatment is fetoscopic laser occlusion of the vessel supplying non-oxygenated blood to the acardiac twin. An important question is when this invasive intervention should be taken ...as early as possible or as late as possible...<sup>36</sup>.

fetus, the earlier the symptoms develop and the worse is prognosis. Aside from fetal biometry and amniotic fluid volume, another key parameter which should be monitored in the case of SIUGR is Doppler evaluation of peripheral blood flow. In particular, Doppler flow patterns in the umbilical vessels can deteriorate with gestational age. Initially, there is increased resistance observed in

Fetal echo has been used to risk stratify fetuses with TRAP using abnormalities of cardiac size, combined cardiac output, AV valve regurgitation and valve sizes (aortic and mitral) in order to predict outcomes or indicate need for fetal intervention<sup>37</sup>. Alternative treatments are symptomatic treatment (i.e. pharmacological support of myocardial function in the pump

	Quintero et al.1999	Rychik et al. 2007 CHOP score	Shah et al. 2008 Cardiovascular Profile Score	Habli et al 2008 Cincinnati staging	Stirnemann et al. 2010
<b>Cardiothoracic ratio</b>		X	X		
<b>Ventricular wall thickness</b>		X		X	
<b>Shortening fraction</b>		X	X		
<b>Tei-Index RV</b>				X	X
<b>Tei-Index LV</b>				X	X
<b>AV regurgitation</b>		X	X	X	
<b>AV inflow</b>		X			
<b>Pulmonary insufficiency</b>		X			
<b>Outflow tract size</b>		X			
<b>Venous duct</b>	X	X	X	X	
<b>Umbilical Vein</b>	X	X	X	X	
<b>Hydrops</b>	X		X	X	
<b>Umbilical artery</b>	X	X	X	X	

Table 6. Comparison of cardiologic parameters included in various scales (Tin Van Mieghem, The Fetal Heart in Twin-to-Twin Transfusion)

	Quintero et al. 1999	Rychik et al. 2007 CHOP score	Shah et al. 2008 Cardiovascular Profile Score	Habli et al 2008 Cincinnati staging	Stirnemann et al. 2010	Other
Med Univ of Gdansk, Poland	x					Tei index
Department of Prenatal Cardiology, Lodz, Poland		x				Tei index for each twin before and after any kind of treatment
Jefferson Univ Philadelphia	x	x				Tei if uncertain
Univ Bonn	x					MCA-PSV, Tei index, and AV insufficiency in both fetuses, blood flow across pulmonary valve, pulmonary trunk and ductus arteriosus (recipient),
Univ Roma Tor Vegata		x				Tei in difficult cases
Children's Hospital Los Angeles and University of Southern California		x	x	x	x	Combination of measures used in all scoring systems with no single system used to describe fetal cardiovascular status.
David Geffen School of Medicine, LA						No single scoring system to describe fetal cardiovascular status
Institute for Maternal Fetal Health, Children's Hospital Colorado				x		
Birgit Arabin	x					Tei index
Hadassah-Hebrew Univ School of Medicine, Jerusalem						No single cardiac parameter

Table 7. Comparison of various scales preferred in our centers for fetal heart evaluation in complicated twins pregnancy

the umbilical artery, followed by absence of end-diastolic flow (AEDF) and eventually reversal of end-diastolic flow (REDF), which may be followed within days to a few weeks by fetal demise of the growth-restricted fetus with potential harmful consequences to the other twin.

Prompt termination of the pregnancy at a tertiary neonatology center with an intensive care unit should be considered as early as AEDF was observed. In early pregnancy, in which the abnormalities of the umbilical flow manifested relatively early and patient is eligible for surgical treatment, a fetoscopic procedure can be offered; this includes either selective cord occlusion in the fetus with SIUGR or laser coagulation of the placenta with closing all possible anastomoses between fetuses and resultant creation of dichorionic pregnancy.

### TWIN ANEMIA POLYCYTHEMIA SEQUENCE (TAPS)

Twin anemia-polycythemia sequence (TAPS) is a rare condition in monochorionic twin pregnancies. Small intertwin placental vascular communications allow transfusion, which results in a hemoglobin difference in the twins in the absence of oligohydramnios or

polyhydramnios. It may be useful to pay attention on the different echogenicity of the placenta (part of it maybe hyperechogenic and part hypoechogenic).

Fetoscopic laser surgery is the only curative treatment, but is challenging in TAPS because of the absence of polyhydramnios and the presence of minuscule anastomoses.

The other option could be intra-uterine transfusion.

TAPS may be some time very difficult to distinguish from TTTS, as findings might be overlapping.

The principal ultrasonographic parameter determined in fetuses with TAPS is flow velocity in the middle cerebral artery; this parameter is used to calculate the risk for fetal anemia from the following formula:

<http://www.perinatology.com/calculators/MCA.htm><sup>38</sup>

### PHARMACOLOGICAL TRANSPLACENTAL AND/OR INDIRECT THERAPY IN FETAL HEART FAILURE

Whenever one or both fetuses present with the signs of heart failure, transplacental or indirect therapy should be considered and discussed with parents to be. An example

of indirect treatment is administration of adenosine to the umbilical vein; this option is limited solely to the cases of persistent, severe tachyarrhythmias that are resistant to transplacental treatment.

However, although middle cerebral artery measurement of the peak systolic velocity has been well studied and documented to relate to anemia in the donor twin, its sensitivity and specificity for determining polycythemia in the recipient twin has not been as thoroughly studied.

Another example of indirect treatment are intrauterine blood transfusions; indications for this treatment include TAPS, evidence of anemia in one fetus during the course of laser therapy-ineligible SIUGR, TTTS or TRAP, or the signs of anemia found on necropsy of one of the fetuses with any of the syndromes mentioned above.

Transplacental pharmacotherapy should be considered whenever a persistent, severe tachyarrhythmia is diagnosed in one or both fetuses. The typical anti-arrhythmic agents used are digoxin, amiodarone, sotalol, flecainide, and propranolol with the same principles of administration that apply to singleton pregnancy<sup>39,40,41</sup>. The status of both the fetus(es) and their mother should be monitored throughout the treatment.

Another example of transplacental treatment is management of heart failure in recipient fetus with TTTS. The treatment of choice are digitalis, initially administered intravenously, and then orally after achieving an appropriate concentration of the drug in the blood of pregnant woman. If fetal hydrops is noted in the recipient twin, intravenous treatment via cordocentesis may be more efficient, since trans-placental delivery of drugs may be impaired.

Frequently, the treatment is initiated already prior to the scheduled selective photocoagulation of communicating vessels to improve myocardial status and cardiovascular performance of the recipient fetus.

Due to similar reasons, transplacental digoxin is also sometimes implemented in pump fetuses with TRAP sequence ineligible for early fetoscopic procedure.

In some centers since the treatment is laser surgery in TTTS – Digoxin is not used any longer.

Sometimes maternal Nifedipine is introduced to improve outcomes in TTTS<sup>42</sup>.

### **DELIVERY IN COMPLICATED TWIN OR MULTIPLE PREGNANCY WITH A CARDIOLOGIC PROBLEM IN ONE OF THE FETUSES**

Two issues should be considered prior to delivery. The first of them are general rules and timing for delivery in multiple pregnancies; this issue has been discussed in detail in many obstetrical publications<sup>12,13,41,43,44,45</sup>. Another problem is the presence of a cardiac defect or heart failure in one or both fetuses. All decisions regarding the timing and method for delivery should be made within a multidisciplinary team including an obstetrician,

maternal fetal medicine specialist, neonatologist, fetal cardiologist, pediatric cardiologist and cardiac thoracic surgeon.

In the case of a fetus with congenital heart disease, historically, the method for delivery was typically established based on obstetrical indications. However, a contemporary definition of CHD is one that recognize there are various levels of severity some of which requires urgent intervention/treatment in the first 24 h of life to prevent death<sup>45,46</sup>. Critical CHD cases may require delivery at specialized centers that can provide perinatal, obstetric, cardiology and cardiothoracic surgery care<sup>47</sup>. Fetuses diagnosed in mid-gestation require detailed fetal diagnostics and serial monitoring during the prenatal period, in order to assess for ongoing changes and identify progression to a more severe cardiac status. In the case of CHD in twin gestations, the location and mode of delivery should be based on a group consensus regarding the optimal perinatal management for the affected twin.

In the situation when fetal heart failure and generalized hydrops has developed. This may preclude safe natural labor, and thus, elective cesarean section might be considered.

Optimally, the labor should take place at a specialist obstetrical center with a neonatal intensive care unit and cardiology/cardiac surgery department<sup>5</sup>, or at a tertiary center.

In the previous decade, with the late detection of TTTS, lack of the possibility of laser treatment, lack of possibility of precise echocardiography monitoring, the main issue of delivery in twins was prematurity, the high mortality of newborns, and also the high rate of conjoined twins<sup>49</sup>.

Despite of huge progress in perinatal care in twins in this decade, we should remember the Blickstein's "citation":<sup>50</sup> "the vast majority of long-term morbidity related to monochorionicity at large does not come from complications of TTTS or TRAP sequence, but from 'banal' ones related to prematurity and growth restriction. Prematurity and growth restriction, however, are not specific to anomalous splitting of the zygote, but plague all multiple gestations simply because the human uterus is unable to carry multiples to the same extent that it carries singletons. Until a (real) advance is made to reduce the risks

affecting all twins, irrespective of chorionicity, we shall continue to rely on the formidable remedies devised for individual cases of complicated monochorionic twin gestation".

### **OTHER PRENATAL ISSUES**

Uterine artery Doppler evaluation in twin pregnancies beginning in the 1<sup>st</sup> trimester<sup>51</sup> could be the next important parameter monitor, however this protocol was focused mainly on the fetal echocardiography in twins.



## POSTNATAL ISSUES

The delivery does not preclude further postnatal care of twins who prenatally had evaluation by fetal cardiologists. After delivery and transition each previous "twin", especially those that have undergone a fetal intervention, should be considered for referral to a pediatric cardiologist to evaluate for heart disease. There is evidence that there is an increased postnatal prevalence of CHD among both former recipients and donors<sup>52</sup> as well as increased risk for CHD in monochorionic gestations in general.

Newborns should be referred to pediatric cardiologists, as among this population there is an increased prevalence of congenital heart defects both in former recipients and donors and they may also present elevated blood pressure in the first or second year of postnatal age<sup>53</sup>.

Whether the elevated blood pressure is related to their prenatal cardiovascular problems or to prematurity warrants future studies.

## FINAL CONCLUSIONS

Fetal echocardiography in dichorionic pregnancy should be offered based on similar protocols as in singleton pregnancy.

Fetal echocardiography in monochorionic pregnancy should be offered as early as possible (perhaps the 14<sup>th</sup> week of gestation) and used for monitoring fetal hearts in out-patient settings and in selected cases for monitoring invasive and/ or pharmacological treatment in hospital settings.

The main goal of fetal cardiac evaluation is to provide thorough and safe perinatal care for the fetuses, mothers, and obstetricians as well, and to ensure timely delivery.

As fetal echocardiography in twins is difficult and time consuming it should be provided by fetal cardiologists or maternal-fetal medicine specialists, but preferably both in concert in tertiary centers, cooperating with obstetricians and pediatric cardiologists.

### References

- Pruetz JD, Sklansky M, Detterich J, Korst LM, Llanes A, Chmait RH. Twin-twin transfusion syndrome treated with laser surgery: postnatal prevalence of congenital heart disease in surviving recipients and donors. *Prenat Diagn*. 2011 Oct;31(10):973-7. doi: 10.1002/pd.2818. Epub 2011 Jul 11.
- Lewi L, Jani J, Blickstein I, Huber A, Gucciardo L, Van Mieghem T, Doné E, Boes AS, Hecher K, Gratacós E, Lewi P, Deprest J. The outcome of monochorionic diamniotic twin gestations in the era of invasive fetal therapy: a prospective cohort study. *Am J Obstet Gynecol*. 2008 Nov;199(5):514.e1-8. doi: 10.1016/j.ajog.2008.03.050. Epub 2008 Jun 4
- Arabin B, Gembruch U, von Eyck J. Registration of fetal behaviour in multiple pregnancy. *J Perinat Med*. 1993;21(4):285-94.
- Rychik J, Ayres N, Cuneo B, Gotteiner N, Hornberger L, Spevak F, Van Der Veld M.: American Society of Echocardiography Guidelines and Standards for Performance of the Fetal Echocardiogram. *J Am Soc Echocardiogr* 2004,17:803-10
- Allan L, Dangel J, Fesslova V, Marek J, Mellander M, Oberhänsli I, Oberhoffer R, Sharland G, Simpson J, Sonesson SE.: Fetal Cardiology Working Group; Association for European Paediatric Cardiology. Recommendations for the practice of fetal cardiology in Europe. *Cardiol Young*. 2004,14:109-14
- Respondek-Liberska M, Sklansky M, Wood D, Słodki M, Weiner S, Cuneo BF, Huhta JC, Gembruch U, Rizzo G, Sharland G, Achiron R, Pruetz JD. Recommendations for fetal echocardiography in singleton pregnancy in 2015. *Prenat Cardio*. 2015 Jun;5(2):28-34. doi 10.12847/06155
- Blickstein I, Arabin B, Lewi L, Matias A, Kavak ZN, Basgul A, Kalish R, Vladareanu R, Ville Y. A template for defining the perinatal care of monochorionic twins: the Istanbul international ad hoc committee. *J Perinat Med*. 2010 Mar;38(2):107-10. doi: 10.1515/JPM.2010.058. Erratum in: *J Perinat Med*. 2010 May;38(3):343. Valideranu, Radu [corrected to Vladareanu, Radu].
- ISUOG Practice Guidelines: role of ultrasound in twin pregnancy. *Ultrasound Obstet Gynecol* 2016; 47: 247–263
- Blickstein I, Keith LG. The decreased rates of triplet births: temporal trends and biologic speculations. *Am J Obstet Gynecol*. 2005 Aug;193(2):327-31.
- Landy HJ, Weiner S, Corson SL, Batzer FR, Bolognese RJ. The "vanishing twin": ultrasonographic assessment of fetal disappearance in the first trimester. *Am J Obstet Gynecol*. 1986 Jul;155(1):14-9.
- Kalchbrenner M, Weiner S, Templeton J, Losure TA. Prenatal ultrasound diagnosis of thoracopagus conjoined twins. *J Clin Ultrasound*. 1987 Jan;15(1):59-63.
- Respondek-Liberska M [Specific and nonspecific fetal cardiac problems]. *Pol Merkur Lekarski*. 2004 May;16(95):415-9.
- Blickstein I, Keith LG.: Multiple Pregnancy: Epidemiology, Gestation, and Perinatal Outcome, CRC Press, 2007
- Morin L., Lim K., Ultrasound in Twin Pregnancies, SOGC Clinical Practice Guideline, 2011, No 260.
- Donnenfeld AE, Glazerman LR, Cutillo DM, Librizzi RJ, Weiner S. Fetal exsanguination following intrauterine angiographic assessment and selective termination of a hydrocephalic, monozygotic co-twin. *Prenat Diagn*. 1989 May;9(5):301-8.
- Sklansky M, Greenberg M, Lucas V, Gruslin-Giroux A. Intrapericardial teratoma in a twin fetus: diagnosis and management. *Obstet Gynecol*. 1997 May;89(5 Pt 2):807-9.
- Rizzo G, Muscatello A, Angelini E, Capponi A. Abnormal cardiac function in fetuses with increased nuchal translucency. *Ultrasound Obstet Gynecol* 2003 Jun; 21(6):539-42
- Rizzo G, Arduini D, Romanini C. Cardiac and extracardiac flows in discordant twins. *Am J Obstet Gynecol*. 1994 May;170(5 Pt 1):1321-7.
- Van Mieghem T, Lewi L, Gucciardo L, DeKoninck P, Van Schoubroeck D, Devlieger R, Deprest J. The Fetal Heart in Twin-to-Twin Transfusion Syndrome. *International Journal of Pediatrics* Volume 2010 (2010), Article ID 379792.
- Leszczyńska K, Preis K, Świątkowska-Freund M et al., Comparison of fetal myocardial contractility before and after laser photocoagulation of communicating vessels in twin-to-twin transfusion syndrome, *Ginekologia Polska*, 2014;85:283-286
- Degenhardt J, Reinold M, Enzensberger C, Wolter A, Kaweckki A, Kohl T, Graupner O, Willruth A, Gembruch U, Bahlmann F, Steinhard J, Axt-Fliedner R. Short-Time Impact of Laser Ablation of Placental Anastomoses on Myocardial Function in Monochorionic Twins with Twin-to-Twin Transfusion Syndrome. *Ultraschall Med*. 2015 Sep 2. [Epub ahead of print]
- Willruth A, Geipel A, Berg C, Fimmers R, Gembruch U. Assessment of cardiac function in monochorionic diamniotic twin pregnancies with twin-to-twin transfusion syndrome before and after fetoscopic laser photocoagulation using Speckle tracking. *Ultraschall Med*. 2013 Apr;34(2):162-8. doi: 10.1055/s-0032-1312773. Epub 2012 May 23.
- Willruth AM, Geipel AK, Berg CT, Fimmers R, Gembruch UG. Comparison of global and regional right and left ventricular longitudinal peak systolic strain, strain rate and velocity in healthy fetuses using a novel feature tracking technique. *J Perinat Med*. 2011 Sep;39(5):549-56. doi: 10.1515/JPM.2011.060. Epub 2011 Jul 13.
- Blickstein I, Perlman S. Single fetal death in twin gestations. *J Perinat Med*. 2013 Jan;41(1):65-9.
- Malinowski W, Janowski J, Łokociejewski J, Rózewicki K, Tomala J. [Intrauterine death of one twin in the third trimester]. *Ginekol Pol*. 2003 Feb;74(2):135-43.
- Malinowski W, Dec W, Biskup I. The assessment of the umbilical blood flow of the surviving twin after the intrauterine death of the other twin. *Acta Genet Med Gemellol (Roma)*. 1996;45(3):383-6.

27. Simonazzi G, Segata M, Ghi T, Sandri F, Ancora G, Bernardi B, Tani G, Rizzo N, Santini D, Bonasoni P, Pilu G. Accurate neurosonographic prediction of brain injury in the surviving fetus after the death of a monochorionic cotwin. *Ultrasound Obstet Gynecol.* 2006 May;27(5):517-21.
28. Gembruch U, Viski S, Bagamery K, Berg C, Germer U. Twin reversed arterial perfusion sequence in twin-to-twin transfusion syndrome after the death of the donor co-twin in the second trimester. *Ultrasound Obstet Gynecol.* 2001 Feb;17(2):153-6.
29. Quintero RA, Morales WJ, Allen MH, Bornick PW, Johnson PK, Kruger M. Staging of twin-twin transfusion syndrome. *J Perinatol.* 1999 Dec;19(8 Pt 1):550-5.
30. Rychik J, Tian Z, Bebbington M, et al. The twin-twin transfusion syndrome: spectrum of cardiovascular abnormality and development of a cardiovascular score to assess severity of disease. *Am J Obstet Gynecol.* 2007;197:392.e1-392e8
31. Davey BT, Donofrio MT, Moon-Grady AJ, Fifer CG, Cuneo BF, Falkensammer CB, Szwasz AL, Rychik J. Development and Validation of a Fetal Cardiovascular Disease Severity Scale. *Pediatr Cardiol* 2014; 35: 1174-1180
32. Shah AD, Border WL, Crombleholme TM et al., Initial Fetal Cardiovascular Profile Score Predicts Recipient Twin Outcome in Twin-Twin Transfusion Syndrome, *J Am Soc Echocardiogr* 2008; 21: 1105-1108
33. Habli M, Michelfelder E, Cnota J et al., Prevalence and progression of recipient-twin cardiomyopathy in early-stage twin-twin transfusion syndrome, *Ultrasound Obstet Gynecol* 2012; 39:63-68
34. Stirnemann JJ, Nasr B, Proulx F et al., Evaluation of the CHOP cardiovascular score as a prognostic predictor of outcome in twin-twin transfusion syndrome after laser coagulation of placental vessels in a prospective cohort, *Ultrasound Obstet Gynecol* 2012; 36:52-57
35. Donnenfeld AE, van de Woestijne J, Craparo F, Smith CS, Ludomirsky A, Weiner S. The normal fetus of an acardiac twin pregnancy: perinatal management based on echocardiographic and sonographic evaluation. *Prenat Diagn.* 1991 Apr;11(4):235-44.
36. Berg C, Holst D, Mallmann MR, Gottschalk I, Gembruch U, Geipel A. Early vs late intervention in twin reversed arterial perfusion sequence. *Ultrasound Obstet Gynecol.* 2014 Jan;43(1):60-4. doi: 10.1002/uog.12578.
37. Byrne FA, Lee H, Kipps AK, Brook MM., Moon-Grady AJ.: Echocardiographic Risk Stratification of Fetuses with Sacrococcygeal Teratoma and Twin-Reversed Arterial Perfusion *Fetal Diagn Ther* 2011;30:280-288, DOI: 10.1159/000330762
38. *perinatology.com, Diagnosis and Staging of Twin to Twin Transfusion Syndrome.*
39. Huhta JC. Fetal congestive heart failure. *Semin Fetal Neonatal Med* 2005 Dec; 10(6):542-52
40. Huhta JC, Paul JJ. Doppler in fetal heart failure. *Clin Obstet Gynecol* 2010 Dec; 53(4):915-29
41. Huhta JC. Guidelines for the evaluation of heart failure in the fetus with or without hydrops. *Pediatr Cardiol.* 2004;25(3):274-286
42. Crombleholme TM1, Lim FY, Habli M, Polzin W, Jaekle R, Michelfelder E, Cnota J, Liu C, Kim MO. Improved recipient survival with maternal nifedipine in twin-twin transfusion syndrome complicated by TTTS cardiomyopathy undergoing selective fetoscopic laser photocoagulation. *Am J Obstet Gynecol.* 2010 Oct;203(4):397.e1-9. doi: 10.1016/j.ajog.2010.06.032. Epub 2010 Aug 17.
43. Bręborowicz G, Malinowski W, Ronin-Walknowska E, Multiple pregnancy, 2003, PZWL, (in Polish)
44. Keith LG, Blickstein I, Multiple Pregnancy: Epidemiology, Gestation, and Perinatal Outcome, 2005.
45. Marcinkowska Joanna, Janiak Katarzyna, Stodki Maciej, Moczulska Hanna, Respondek-Liberska Maria. [Analysis of prenatal diagnostic (USG and ECHO) of 100 consecutive fetuses from twins pregnancies in fetal cardiology center type C]. *Prenat Cardio.* 2012 Jun;2(3),14-20.
46. Pruetz JD, Carroll C, Trento LU, Chang RK, Deterich J, Miller DA, Sklansky M. Outcomes of critical congenital heart disease requiring emergent neonatal cardiac intervention. *Prenat Diagn.* 2014 Dec;34(12):1127-32. doi: 10.1002/pd.4438. Epub 2014 Jul 22.
47. Stodki M, Respondek-Liberska M Comment on "Outcomes of critical congenital heart disease requiring emergent neonatal cardiac intervention": a new classification of congenital heart disease. *Prenat Diagn.* 2015 Jun;35(6):620-1. doi: 10.1002/pd.4576.
48. Stodki M, Respondek-Liberska M, Pruetz JD, Donofrio MT. Fetal cardiology: changing the definition of critical heart disease in the newborn. *J Perinatol.* 2016 Mar 10. doi: 10.1038/jp.2016.20. [Epub ahead of print]
49. Respondek-Liberska M, Czichosz E, Nowak S, Sobantka S, Maroszyńska I, Gulczyńska E, Janiak K, Lukaszek S, Krasomski G, Szpakowski M. [Analysis of perinatal death at the Institute of the Health Center of the Polish mother in 1995, 1996 and 1997. The reason for making changes in the accountability for perinatal death]. *Ginekol Pol.* 1999 Sep;70(9):581-7.
50. Blickstein I. Monochorionicity in perspective. *Ultrasound Obstet Gynecol.* 2006 Mar;27(3):235-8.
51. Rizzo G, Pietrolucci ME, Aiello E, Capponi A, Arduini D. Uterine artery Doppler evaluation in twin pregnancies at 11 + 0 to 13 + 6 weeks of gestation. *Ultrasound Obstet Gynecol.* 2014 Nov;44(5):557-61. doi: 10.1002/uog.13340. Epub 2014 Sep 15.
52. Pruetz JD, Sklansky M, Deterich J, Korst LM, Llanes A, Chmait RH. Twin-twin transfusion syndrome treated with laser surgery: postnatal prevalence of congenital heart disease in surviving recipients and donors. *Prenat Diagn.* 2011 Oct;31(10):973-7. doi: 10.1002/pd.2818. Epub 2011 Jul 11.
53. Pruetz JD1, Schrager SM2, Wang TV3, Llanes A4, Chmait RH4, Vanderbilt DL5. Blood pressure evaluation in children treated with laser surgery for twin-twin transfusion syndrome at 2-year follow-up. *Am J Obstet Gynecol.* 2015 Sep;213(3):417.e1-7. doi: 10.1016/j.ajog.2015.05.031. Epub 2015 May 21.

#### Division of work:

Katarzyna Leszczyńska: first draft, literature search

Co-authors: work with manuscript

Maria Respondek-Liberska: concept of the manuscript, figures, final version

**Conflict of interest:** The authors declare no conflict of interest

Authors do not report any financial or personal links with other persons or organizations, which might affect negatively the content of this publication and/or claim authorship rights to this publication