

Surgical treatment options in a patient with borderline resectable tumour – a case report of a 54-year-old patient with locally advanced melanoma

Anna Ryguła¹, Michał Kowalski¹, Patrycja Stec², Marcin Ziętek³

¹Student Research Group of Experimental Dermatology, Department of Dermatology, Venereology and Allergology, Wrocław Medical University, Wrocław, Poland

²Student Research Group of Oncology, Department of Oncology, Wrocław Medical University, Wrocław, Poland

³Department of Oncology, Department of Oncological Surgery, Wrocław Medical University, Wrocław, Poland

Adv Dermatol Allergol 2023; XL (1): 178–180

DOI: <https://doi.org/10.5114/ada.2022.124720>

Melanoma is a malignant neoplasm of the skin deriving from melanocytes [1]. Skin melanoma accounts for 1.7% of cases in men and 1.9% of cases in women, among all other cancers. Approximately 1.4% of deaths in men and 1.2% of deaths in women are recorded due to melanoma [2]. Treatment of clinical-stage III melanoma with resectable tumours is based on wide surgical excision of the primary tumour and removal of regional lymph nodes, followed by adjuvant systemic therapy such as nivolumab (anti-PD-1), pembrolizumab (anti-PD-1), or, in the event of a BRAF mutation, dabrafenib with trametinib (anti-BRAF). In patients with unresectable tumours, palliative systemic therapy remains the only treatment option [3].

The study aims to draw attention to the role of surgical treatment in patients with borderline resectable tumours by describing the case of a patient in whom systemic treatment was postponed due to pulmonary embolism, and the molecularly targeted treatment option was not available due to the lack of BRAF V600 mutation.

In August 2018, a skin lesion on the abdomen of a 50-year-old man was removed in a regional hospital due to suspected melanoma. Histopathological examination confirmed the diagnosis of nodular melanoma. The lesion thickness was 3.5 mm according to the Breslow scale, pT3a stage, with no ulcer present. Melanoma micrometastases were present in the sentinel lymph node taken from the left groin. A complementary left inguinal lymphadenectomy was performed, but no melanoma metastases were found in the histopathological examination.

In June 2021, the patient came to the Lower Silesian Oncology Centre with positron emission tomography-computed tomography (PET-CT) results, which were

performed due to a suspected nodal recurrence of melanoma in the left groin. In PET-CT, metabolically active metastases in the subcutaneous tissue of the abdominal integuments and the lymph nodes, external iliac and inguinal on the left side, were described. A biopsy of the left inguinal tumour was performed in the Lower Silesian Oncology Centre, and melanoma infiltration described in the histopathological diagnosis. A CT scan of the abdomen and pelvis showed a 7.9 cm × 6.7 cm × 7.5 cm tumour in the left groin, fusing with the skin contours, with a tissue defect in the anterior part suggesting ulceration, and above, in the subcutaneous tissue, another tumour measuring 4.2 cm × 3.6 cm × 4.3 cm, also blending with the contours of the skin and emphasizing them.

The BRAF gene mutation test was performed, which turned out to be negative. Therefore, despite the local advancement of the disease, the patient was qualified for surgery. On 9 August 2021, a left-sided inguinal and iliac-obturator lymphadenectomy and resection of both soft tissue tumours of the left lower abdomen were performed during one surgical block. In the histopathological examination of the material from the procedure, the procedure was defined as radical, and metastases of melanoma were confirmed in the soft tissues of the left lower abdomen (in-transit metastases), in the external left iliac lymph nodes, and the left obturator lymph nodes. In September 2021, a chest, abdominal, and pelvic CT scan was performed as an examination qualifying for complementary systemic treatment, in which no contrast was detected in the lumen of both lobar arteries of the left lung and in the lumen of the right upper lobe artery, which indicated a pulmonary embolism. After conservative treatment of the pulmonary embolism, PET-CT was

Address for correspondence: Michał Kowalski, ul. Jarosława Iwaszkiewicza 3/12, 52-211 Wrocław, Poland, phone: +48 501 137 837, e-mail: michal.kowalski.0597@gmail.com

Received: 4.05.2022, **accepted:** 25.07.2022.

This is an Open Access article distributed under the terms of the Creative Commons Attribution-NonCommercial-ShareAlike 4.0 International (CC BY-NC-SA 4.0) License (<http://creativecommons.org/licenses/by-nc-sa/4.0/>)

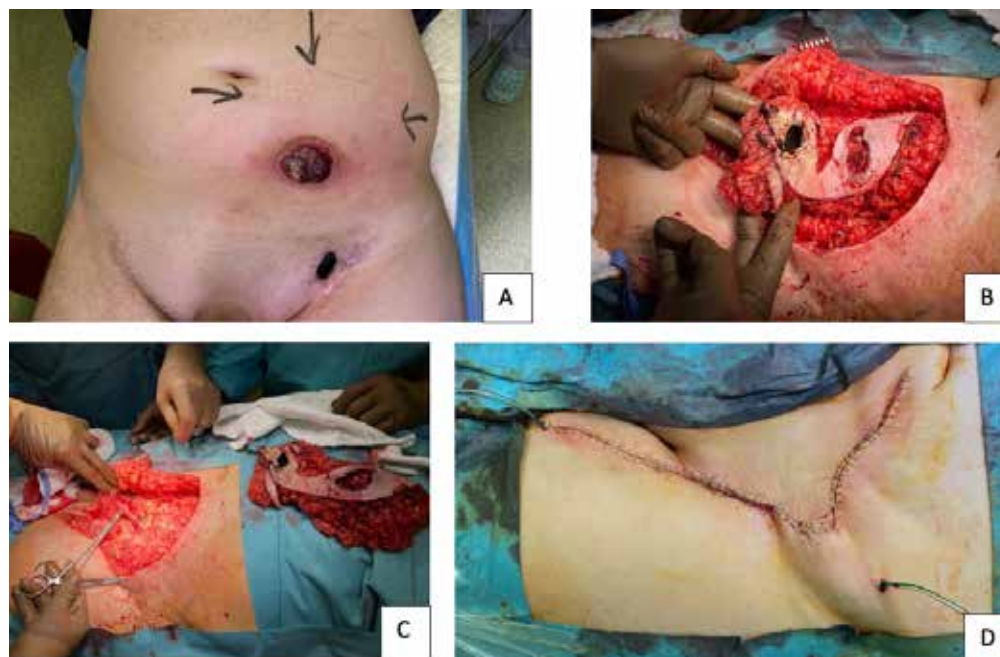


Figure 1. A – Melanoma metastasis to the soft tissue of the lower abdomen. Metastases during surgical excision (B) and after excision (C, D)

performed to exclude recurrence of the disease, which showed the presence of an active neoplastic infiltration on the left side of the pelvis with a possible infiltration of the abdominal subcutaneous tissue on the left side, left groin, and left oblique and rectangular muscles of the abdomen. In October 2021, a CT scan was performed, where the thickening of the peritoneum in the pelvis was described, suggesting neoplastic spreading over a distance of more than 10 cm.

The patient was qualified for palliative therapy with ipilimumab and nivolumab. Unfortunately, due to the lack of BRAF mutation, it was impossible to qualify for molecularly targeted therapy (Figure 1).

In stage 3 of melanoma, in the presence of clinically suspicious lymph nodes, the method of choice is a surgical treatment with lymph node biopsy to confirm the diagnosis, imaging examination to determine the staging and to exclude dissemination of the disease, and testing for the presence of the BRAF gene mutation. If resectable lymph nodes are present, they should be removed. Then complementary systemic therapy should be administered, which includes drugs such as nivolumab (anti-PD-1), pembrolizumab (anti-PD-1) or dabrafenib/trametinib (for patients with BRAF mutation V600) [3].

The therapy based on nivolumab in combination with ipilimumab, thanks to which the immune response of patients is enhanced, brings many positive results in patients with advanced melanoma. Despite its high toxicity, this is the pathway recommended by the NCCN [4]. The reported effectiveness of this therapy is 57.8% [5]. In

addition, efficacy may be increased by using BRAF inhibitors such as dabrafenib and trametinib in patients with a BRAF mutation [6, 7].

Despite the increasing role of systemic treatment of metastatic melanoma, the described case shows that surgical treatment of stage III is possible even in the case of large metastatic tumours and remains the standard of care in combination with adjuvant systemic treatment. Unfortunately, in the described situation, it was impossible to initiate such treatment to prevent the spread of the disease because the diagnosed postoperative pulmonary embolism postponed the initiation of this treatment. In addition, the patient could not be treated with drugs such as dabrafenib and trametinib because no mutation in the BRAF gene was detected.

In conclusion, adjuvant systemic therapy plays an important role in the treatment of lymph node melanoma metastases. The most commonly used drugs are ipilimumab, nivolumab and dabrafenib with trametinib in the presence of the BRAF V600 mutation. The effectiveness of this therapy depends on the performance of the radical surgical resection with the determination of the BRAF mutation and sufficiently quick qualification for the adjuvant treatment to minimize the risk of recurrence and spread of the disease.

Conflict of interest

The authors declare no conflict of interest.

References

1. Rutkowski P, Wysocki PJ, Nasierowska-Guttmejer A, et al. Cutaneous melanomas. *Oncol Clin Pract* 2017; 13: 241-58.
2. Wojciechowska U, Didkowska J. Zachorowania i zgony na nowotwory złośliwe w Polsce. Krajowy Rejestr Nowotworów, Narodowy Instytut Onkologii im. Marii Skłodowskiej-Curie – Państwowy Instytut Badawczy 2010.
3. National Comprehensive Cancer Network. Melanoma (Version 2.2022).
4. Fujimura T, Kambayashi Y, Sato Y, et al. Successful treatment of unresectable advanced melanoma by administration of nivolumab with ipilimumab before primary tumor resection. *Front Med* 2019; 6: 140.
5. Hodi FS, Chiarion-Sileni V, Gonzalez R, et al. Nivolumab plus ipilimumab or nivolumab alone versus ipilimumab alone in advanced melanoma (CheckMate 067): 4-year outcomes of a multicentre, randomised, phase 3 trial. *Lancet Oncol* 2018; 19: 1480-92.
6. Long GV, Flaherty KT, Stroyakovskiy D, et al. Dabrafenib plus trametinib versus dabrafenib monotherapy in patients with metastatic BRAF V600E/K-mutant melanoma: long-term survival and safety analysis of a phase 3 study. *Ann Oncol* 2017; 7: 1631-9.
7. Dummer R, Ascierto PA, Gogas HJ, et al. Overall survival in patients with BRAF-mutant melanoma receiving encorafenib plus binimetinib versus vemurafenib or encorafenib (COLUMBUS): a multicentre, open-label, randomised, phase 3 trial. *Lancet Oncol* 2018; 10: 1315-27.