

# Effect of hormone replacement therapy on the incidence and extent of *Candida*-associated denture stomatitis

ELŻBIETA MIERZWIŃSKA-NASTALSKA<sup>1</sup>, MAGDALENA GOLECKA-BAKOWSKA<sup>1</sup>,  
MAŁGORZATA BYCHAWSKA<sup>2</sup>, EUGENIUSZ SPIECHOWICZ<sup>1</sup>

<sup>1</sup>Department of Prosthetic Dentistry, Medical University of Warsaw, Poland

<sup>2</sup>Department of Laboratory Diagnostics, Institute of Tuberculosis and Lung Diseases, Warsaw, Poland

## Abstract

Menopause is a physical condition that occurs when the ovaries cease to function, decreasing the concentration of sex hormones. The deficiency of female steroid hormones also exerts an effect on the condition of oral mucosa.

The aim of the study was to evaluate the effect of hormone replacement therapy (HRT) on the incidence and extent of *Candida*-associated denture stomatitis in menopausal women who wear removable dentures. The study group was composed of 65 women, wearers of removable dentures, who were taking hormone replacement therapy. The control group comprised 65 women who also wear removable dentures, but are not using HRT. Clinical studies included an anamnesis, physical examinations of the oral mucosa condition and evaluation of dentures. Laboratory microbiological tests were performed, applying direct swabs collection from the oral mucosa. Moreover, the level of anti-nuclear antibodies against *Candida albicans* was analysed. Cases of denture stomatitis, characterized by a higher fungal growth rate, were found more frequent in patients wearing removable denture and taking HRT than in the control group. Patients wearing removable denture and taking hormone replacement therapy form a high-risk group in terms of fungal infections and inflammations of the oral mucosa. Therefore, they must have regular dental check-ups.

**Key words:** denture stomatitis, hormone replacement therapy, antibodies against *C. albicans*.

(Centr Eur J Immunol 2013; 38 (2): 226-230)

## Introduction

Menopause is a physical condition that occurs when the ovaries cease to function, decreasing the concentration of sex hormones [1, 2]. The deficiency of female steroid hormones also exerts an effect on the condition of oral mucosa. It often happens that menopausal women complain of dryness and burning sensation in the mouth or taste disturbances. These symptoms are caused by atrophic inflammatory changes [2].

Hormone replacement therapy (HRT) involves the administration of sex hormones in the case of ovarian insufficiency. HRT alleviates women's immediate complaints and contributes to an improved quality and comfort of life. There are reports, which provide evidence that estrogens

and progesterone selectively influence the immune system. Albrecht *et al.* have observed a higher activity of natural killer cells in women who do not take HRT [3]. Other authors report that HRT is a negative regulator of B lymphopoiesis [2, 4].

In Poland, the average age of the natural menopause is 50.8 years, whereas women living in Western Europe start to go through menopause at the age of 50. A lot of menopausal women wear removable mucosal-borne dentures, and their presence yields non-physiological conditions in the oral cavity. A denture plaque makes salivary rinsing of the mucosa more difficult, hence retention of food debris under the plaque and an elevated temperature in the oral cavity, which creates conditions favourable for the multiplication of microorganisms and the development of

Correspondence: Elżbieta Mierzwińska-Nastalska, Katedra Protetyki Stomatologicznej, Warszawski Uniwersytet Medyczny, ul. Nowogrodzka 59, 02-006 Warszawa, tel. +48 22 502 18 86, e-mail: katedraprotetyki@wum.edu.pl

inflammations termed “denture stomatitis” [5, 6]. Newton [5] has distinguished three classes of this condition: class I – limited, spot inflammations most frequently localized around the ostia of palatal mucous glands; class II – diffused inflammation of mucosa, usually covered with a denture surface; and class III – hypertrophic inflammation.

A mechanical trauma is the most frequent cause of denture stomatitis. This is followed by yeast-like fungal infections and prosthetic plaque [6, 7]. The condition of the denture foundation area mucosa is also greatly influenced by a general state of patients’ health, particularly by the presence of diseases characterized by immune deficiency, hormone disorders (diabetes), cancerous cachexia, malnutrition, avitaminoses, and those requiring specific pharmacotherapies [5-9]. A sharp intramucosal side of the prosthetic plaque, abnormal occlusion, improper stabilization or too limited range of the prosthetic plaque may also cause a mechanical trauma of the mucosa in the denture foundation area.

The aim of the study was to evaluate the effect of hormone replacement therapy on the incidence and extent of *Candida*-associated denture stomatitis in menopausal women who wear removable denture and to analyse the level of anti-nuclear antibodies against *Candida albicans*.

## Material and methods

The study was carried out in the population of 130 menopausal women, wearers of removable denture, patients of the Clinic of Gynaecology and Obstetrics, Warsaw Medical University. The study group (A) was composed of 65 healthy women, aged 44-59 (mean 51.95 years) taking hormone replacement therapy (oral or percutaneous) for at least one year. They neither used other medication nor showed any evident cause of impaired immunity. The control group (B) comprised 65 healthy women, aged 47-57 (mean 54 years) also wearers of removable denture but not taking HRT. The majority of patients used removable partial dentures and complete dentures.

All patients gave informed consent to participation in the study and the study design was approved by the Bioethics Committee of the Warsaw Medical University.

Clinical examinations comprised the analysis of clinical manifestations, subjective and objective examinations of the oral mucosa and the denture assessment. The anamnesis provided data on the patients’ health state. The reason for and time of starting HRT were regarded as essential data derived from the anamnesis. Then, the occurrence of subjective symptoms in the oral cavity, defined by the patients as sore, dryness and burning sensation of the oral mucosa as well as taste disturbances were recorded. As regards the use of removable dentures, the attention was focused on finding out for how long and in what way they were being worn (night’s break or a 24-hour use).

The mucosal condition of the denture foundation area was assessed according to a modified version of Newton’s

classification [5, 6]. The mycological test was performed using the method of direct swab collection from the oral cavity. The swabs were collected with pledgets and referred to the laboratory, where direct preparations were produced and incubated on Sabouraud agar. After 48-72 h the growth of yeast-like fungal colony was assessed.

In addition to the mycological examination, the presence of antinuclear antibodies against *Candida albicans* was identified and assessed in 20 patients, applying indirect immunofluorescence (IF) test and a commercial Anti-*Candida albicans* IIFT kit (EUROIMMUN, Lübeck, Germany). For this purpose, sera of the patients of both groups, A and B, were used. In the IF test, yeast cellular smears were used to assess IgG and IgM antibodies against *Candida albicans* present in the patients’ blood serum. The test was performed according to the manufacturer’s recommendations.

The patients of both groups (A and B), undergoing individual examinations, did not report any diseased condition or medication being prescribed within the previous year. The eligibility of persons for the study was determined by their good general health state.

## Results

The anamnesis data, as well as the numeric and percentage values revealed that manifestations, such as night sweats, hot flash, vaginal dryness, heart palpitation, insomnia, nervousness, and mood swings were the most frequent reasons for taking hormone replacement therapy (48 women, 73.85%). Menstrual irregularities were reported by 9 (13.85%) women and conditions after adnexectomy due to an ovarian cyst by 8 (12.3%) women.

In each group (A and B), 36 (55.4%) women reported the use of removable dentures for less than five years. In the study group 18 (27.7%) and in the control group 22 (33.8%) women have used them for more than 5 years, but no longer than 10 years; 11 (16.9%) in group A and 7 (10.8%) in group B have used removable dentures for more than 10 years (Table 1).

Figure 1 summarises the clinical assessment of the oral mucosa in the denture foundation, according to a modified version of Newton’s classification. In both groups (A and B), the study revealed the incidence of the same percentage (55.4%) of denture stomatitis class II. Single spots of hyperaemia, corresponding to class I, were found in 35.4% of

**Table 1.** Length of removable denture wear

	Length of removable denture wear (years)		
	0-5	5-10	< 10
Study group (n = 65)	36 55.4%	18 27.7%	11 16.9%
Control group (n = 65)	36 55.4%	22 33.8%	7 10.8%

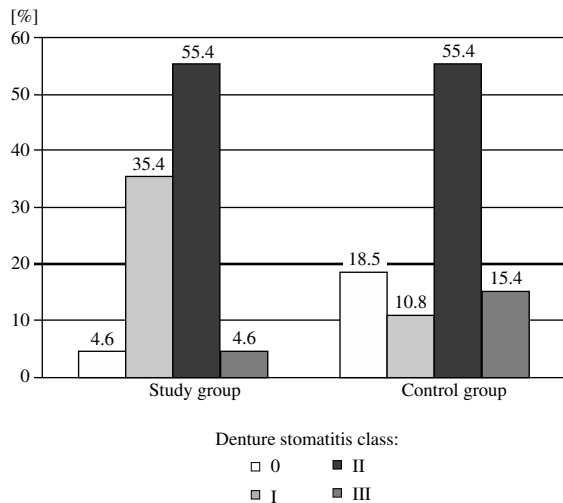


Fig. 1. The condition of oral mucosa in denture foundation

cases in group A and in 10.8% of cases in group B. Denture stomatitis class III was more frequent (15.4%) in the control group than in the study group (4.6%), whereas denture stomatitis class 0 and class III was found less frequently ( $\chi^2 = 17.7; p < 0.05$ ) and class I more frequently in the study group than in controls.

On mycological examination, the presence of yeast-like fungi was found in swabs collected from the oral mucosa surface in patients of group A and B. The mean number of fungal colonies was higher in patients of group A ( $11.89 \pm 2.92$ ) than in the control group ( $3.13 \pm 0.60$ ). In the study group, the growth of single fungal colonies was obtained in 69.6% and the growth of numerous colonies in 15.2% of cases. In 15.2% of the HRT-taking patients, an abundant growth of yeast-like fungal colonies was disclosed. In the control group, the growth of single fungal colonies was obtained in 84.0% and of numerous fungal colonies in 16% of women, but no abundant growth of yeast-like fungal colonies was observed in this group (Table 2).

Table 2. Incidence of yeast-like fungi cultured on swabs derived from the oral mucosa surface and the degree of its growth

Results of mycological test				
	Mean number of fungal colonies	Growth intensity of fungal colonies		
		A	B	C
Study group n = 65	11.89 $\pm 2.92$	32 69.60%	7 15.20%	7 15.20%
Control group n = 65	3.13 $\pm 0.60$	42 84.00%	8 16.00%	0 0.00%

Group A – growth of single colonies (1-10)

Group B – numerous fungal colonies (10-50)

Group C – abundant fungal growth (50 and more)

Table 3. IgM and IgG antinuclear antibodies against *Candida albicans* in the study group

Study group	Antinuclear antibodies against <i>Candida albicans</i>			
	IgG		IgM	
	Result	Antibody titre	Result	Antibody titre
1	+	1 : 2000	+/-	doubtful
2	+	1 : 1000	+	1 : 400
3	+	1 : 4000	-	-
4	+	1 : 1000	+	1 : 200
5	+++	1 : 16 000	+	1 : 400
6	+++	1 : 8000	+/-	doubtful
7	+	1 : 4000	+++	1 : 800
8	+++	1 : 8000	+	1 : 100
9	+++	1 : 16 000	+	1 : 400
10	+	1 : 2000	+	1 : 100

**Table 4.** IgM and IgG antinuclear antibodies against *Candida albicans* in the control group

Control group	Antinuclear antibodies against <i>Candida albicans</i>			
	IgG		IgM	
	Result	Antibody titre	Result	Antibody titre
1	+++	1 : 16 000	+/-	doubtful
2	+	1 : 4000	+	1 : 200
3	+	1 : 1000	-	-
4	+++	1 : 16000	+	1 : 100
5	+	1 : 4000	-	-
6	+	1 : 8000	+	1 : 400
7	-	-	+	1 : 100
8	+++	1 : 8000	+/-	doubtful
9	+	1 : 2000	-	-
10	+	1 : 4000	+	1 : 100

The positive titres of IgG antinuclear antibodies were obtained in all 10 patients of group A, including four of a very high value. Of the 10 examined patients of group B, one person showed negative and nine persons positive IgG antibodies titres, including three cases with very high titres. When determining IgM antibodies titre in group A, positive results were obtained in seven persons, negative in one and doubtful in two persons, whereas in group B, in five, three and two persons, respectively (Tables 3 and 4).

## Discussion

Clinical observations reveal that the use of removable dentures is quite common in menopausal women. Physiological processes occurring in women's body in the menopausal period have a great impact on their health and general well-being. Patients frequently complain of discomfort in their oral cavity, defined as dryness, burning or taste disturbances, most frequently associated with a decreased excretion of unstimulated and stimulated saliva [10, 11]. The examinations performed in women with the diagnosed osteoporosis, who take HRT, show less frequent occurrence of these symptoms than in women without hormonal replacement therapy [12].

The presence itself of removal partial denture made of microporous acryl, develops non-physiological conditions in the oral cavity [13]. The electron microscopic studies carried out by Radford [14] disclosed the presence of a biofilm composed of bacteria and a large number of fungal cells. In the reported study, aimed at assessing the clinical state of oral mucosa in the denture foundation, according to a modified version of Newton's classification, different extent of inflammation was revealed in 95.4% of HRT-taking women and in 81.5% of those who did not take HRT. Moreover,

a diffused inflammation corresponding to class II was observed in the similar percent of women in both groups, however, healthy oral mucosa without inflammatory symptoms and reddening was more frequent in the control group.

The risk of fungal infection development depends on the risk factors found in an individual person. Apart from the local factors in the oral cavity, related to removable denture wearing, the condition of the host immune system plays a very important role. Budtz-Jørgensen *et al.* [7] emphasizes the effects of the antibiotics used, hormonal changes, endocrinological disorders, malnutrition, diseases of the hematopoietic system, immune defects and saliva excretion disorders, on the development of fungal infections. The laboratory mycological tests showed, on the basis of swabs derived from oral mucosa, that the mean number of fungal colonies was higher in the group of women using HRT than in those without hormonal therapy. Moreover, in the HRT-taking women fungal growth was significantly more pronounced. It should be emphasized that in the control group, none of the women showed abundant fungal growth.

The length of removable partial denture wear and denture hygiene greatly influence the development of denture stomatitis complicated by fungal infection [6]. In both groups (A and B), over 50% of women reported the length of denture use shorter than 5 years, 30% of them reported a longer (5-10 years) period and the smallest group reported the period exceeding 10 years. The correlation analysis did not show a statistically significant relationship between the growth intensity of fungi obtained from the surface of oral mucosa and the length of denture use.

The analysis of our own results of the mycological test revealed a higher intensity of fungal growth in women of group A. It is likely that a more intensive multiplication of

fungal flora in this group of patients was associated with the decreased chemiluminescence activity of blood neutrophils after the applied hormonal therapy: their decreased metabolic activity may contribute to the attenuation of their bacteri- and fungicidal activities, generating a potential risk of fungal infection [15].

The contact with an infectious agent, involving humoral immune response, is followed by the production of specific anti-*Candida* immunoglobulins in the human body. IgA and sigA antibodies present in saliva are excreted mainly by submandibular and sublingual salivary glands, as well as by the parotid gland but to a lower extent. High levels of IgG, IgA, IgM-anti-*Candida* antibodies have been observed in persons with chronic mucocutaneous mycosis. The patients with chronic atrophic candidiasis have been found to show higher levels of IgG and IgM than those with acute pseudomucosal candidiasis. It has been revealed that the level of IgA immunoglobulins is considerably higher in patients with chronic candidiasis than in controls free of infection [16, 17]. Anti-*Candida* antibodies are detected in blood serum and saliva of persons with clinical symptoms of candidiasis and in healthy persons, however, some differences in antibody titres are observed [17]. In the case of suspected proliferous lesions of epithelium, Budtz-Jørgensen [18] claimed that the testing of anti-*Candida* antibodies level could be useful in determining the innate ability of the human organism to protect from the disease and to predict its remission. He also observed that patients with oral mycosis usually show a slightly elevated level of *Candida albicans* antibodies in serum and saliva. The determination of the level of antigens and antibodies can be beneficial in patients with the diagnosed oral candidiasis, who are resistant to antimycotic treatment. In the literature, conflicting results of the studies on anti-*Candida* antibody levels in patients with symptoms of candidiasis can be found [19, 20]. Our study showed that in a selected group of HRT-taking patients with the positive mycological tests, positive results of serum antinuclear IgG antibodies titres were obtained in all of them. Similar results were found in the control group, in which only one patient showed a negative result of the titre in the same class of antibodies. The determination of IgM antibody titres revealed positive results in 70% of persons in the study group and in 50% of controls. The study carried out by Leimola-Virtanen *et al.* [20] has indicated the decreased level of IgA, sigA and IgG antibodies and the increased level of IgM antibodies in HRT-taking menopausal women. They analysed the levels of peroxidase, IgG, IgM and IgA in saliva before and after menopause in HRT-taking women. In both groups, the level of peroxidase was elevated. In perimenopausal women taking HRT, saliva IgA concentration was higher, whereas HRT-taking postmenopausal women showed its lower level.

Female wearers of removable mucosal-borne dentures, who take hormone replacement therapy, should be undergo periodical mycological tests. Early detection of fungal infections and check-ups of patients' removable denture

prove to be an effective tool in the prevention of fungal infections and inflammations of the oral mucosa.

*The authors declare no conflict of interest.*

## References

1. Baron J, Baron A. (1996): Outline of Gynaecologic and Obstetric Endocrinology. PZWL, Warsaw.
2. Hoffman-Goetz L (1999): Effect of estradiol and exercise on lymphocyte proliferation responses in female mice. *Physiol Behav* 68: 169-174.
3. Albrecht AE, Hartmann BW, Scholten C, et al. (1996): Effect of estrogen replacement therapy on natural killer cell activity in postmenopausal women. *Maturitas* 25: 217-222.
4. Kincade PW, Medina KL, Smithson G (1994): Sex hormones as negative regulators of lymphopoiesis. *Immunol Rev* 137: 119-134.
5. Newton A (1962): Denture sore mouth. *Brit Dent J* 112: 357-360.
6. Spiechowicz E, Mierzińska-Nastalska E. (1998): Oral cavity mycoses. Med Tour Press Int. Warsaw.
7. Budtz-Jørgensen E, Mojon E, Banon-Clement JM, Baehni P (1996): Oral candidosis in long-term hospital care: comparison of edentulous and dentate subjects. *Oral Diseases* 2: 285-290.
8. Dorocka-Bobkowska B, Budtz-Jørgensen E, Włoch S (1996): Non-insulin-dependent diabetes mellitus as a risk factor for denture stomatitis. *J Oral Pathol Med* 25: 411-415.
9. Mierzińska-Nastalska E, Spiechowicz E, Rusiniak-Kubik K, Skopińska-Różewska E (1997): Prevention of oral cavity mycotic infection and its immunologic sequelae. *Protet Stomatol* 1: 4-9.
10. Friedlander AH (2002): The physiology, medical management and oral implications of menopause. *J Am Dent Assoc* 133: 73-81.
11. Skalba P (2002): Hormonal replacement therapy. Wyd. Lek. PZWL, Warszawa.
12. Androsz O, Jakubas-Kwiatkowska W, Blachowicz A, et al. (2006): The assessment of progression of periodontal disease in osteoporosis women in dependence on hormone replacement and osteoporosis therapy. A preliminary study. *Nowa Stomatol* 2: 93-96.
13. Nikawa H, Hamada T, Yamamoto T (1998): Denture plaque – past and recent concerns. *J Dent* 26: 299-304.
14. Radford DR, Radford JR (1993): A SEM study of denture plaque and oral mucosa of denture-related stomatitis. *J Dent* 21: 87-93.
15. Pertyńska MP, Tchórzewski H, Lewkowicz P, et al. (2000): Evaluation of the hormonal replacement therapy (HRT) effect on generation of reactive oxygen intermediates (ROI) by neutrophils in peripheral blood of menopausal women. *Gin Pol* 71: 55-62.
16. Jaikittivong A, Johnson DA, Yeh CK (1998): The relationship between salivary histatin levels and oral yeast carriage. *Oral Microbiol Immunol* 13: 181-187.
17. Kantardijev TV, Popova EV (2002): Anti-*Candida* antibodies in serum and saliva of patients with denture stomatitis. *Folia Medica* 4: 39-43.
18. Budtz-Jørgensen E (1990): Histopathology, immunology and serology of oral yeast infections. *Acta Odontol Scand* 48: 37-43.
19. Schröder JM, Moravič J (1980): Immunoglobuline in serum und Speichel bei Patienten mit Stomatitis prothetica. *Dtsch Zahnärztl Z* 35: 953-958.
20. Leimola-Virtanen R, Helenius H, Laine M (1997): Hormone replacement therapy and some salivary antimicrobial factors in post- and perimenopausal women. *Maturitas* 27: 145-151.