

Cutaneous expressions of interleukin-6 and neutrophil elastase as well as levels of serum IgA antibodies to gliadin nonapeptides, tissue transglutaminase and epidermal transglutaminase: implications for both autoimmunity and autoinflammation involvement in dermatitis herpetiformis

JUSTYNA GORNOWICZ-POROWSKA¹, MONIKA BOWSZYC-DMOCHOWSKA²,
AGNIESZKA SERASZEK-JAROS³, ELŻBIETA KACZMAREK³, PAWEŁ PIETKIEWICZ¹,
MARIAN DMOCHOWSKI¹

¹Autoimmune Blistering Dermatoses Section, Department of Dermatology, Poznan University of Medical Sciences, Poznan, Poland

²Cutaneous Histopathology and Immunopathology Section, Department of Dermatology, Poznan University of Medical Sciences, Poznan, Poland

³Department of Bioinformatics and Computational Biology, Poznan University of Medical Sciences, Poznan, Poland

Abstract

Introduction: Dermatitis herpetiformis (DH) seems to be a chronic immune-mediated inflammatory disease of partially known origin. In light of its known biological functions and its involvement in tissue pathology in other disease states, particularly in nickel-induced allergic contact dermatitis coexisting with DH, it would appear that the central and peripheral response by neutrophils and their mediators (e.g. neutrophil elastase – NE) in DH may be partially mediated by interleukin-6 (IL-6).

The aim of the study was to assess the role of IL-6 in DH lesions by examining the relationships between IL-6/NE cutaneous expression and levels of serum anti-nonapeptides of gliadin (npG) IgA, anti-tissue transglutaminase (tTG) immunoglobulin A (IgA), anti-epidermal transglutaminase (eTG) IgA in DH.

Material and methods: In total, 24 DH patients having IgA cutaneous deposition were studied. Immunohistochemistry on paraffin-embedded sections with quantitative digital morphometry was used to measure the intensity of IL-6 and NE cutaneous expressions. Levels of serum anti-npG IgA, anti-tTG IgA and anti-eTG IgA were evaluated with ELISA.

Results: We found no statistically significant correlation between the NE and IL-6 expression intensities. Our results revealed also a lack of correlations between NE/IL-6 expressions and levels of anti-npG IgA, anti-tTG IgA, anti-eTG IgA in DH. However, the IL-6 expression level was significantly lower than that of NE.

Conclusions: The lack of correlations suggested no substantial interactions between IL-6, NE, IgA/npG, IgA/tTG or IgA/eTG in DH. Presented results might indicate the heterogenetic nature of DH pathogenesis suggesting further that both autoimmune and autoinflammatory phenomena may be involved in DH cutaneous pathology.

Key words: dermatitis herpetiformis, interleukin-6, neutrophil elastase, autoimmunity.

(Centr Eur J Immunol 2014; 39 (3): 331-337)

Introduction

Dermatitis herpetiformis (DH) is an autoimmune blistering dermatosis with a chronic, intensely itchy, polymorphic, vesicle-forming skin manifestation that develops predominantly in young adult or adolescent men [1-7]. Dermatitis herpetiformis seems to be a chronic immune-mediated inflammatory disease of only partially known origin. Lack of precise identification of a specific individual antigen (epidermal transglutaminase – eTG, tissue transglutaminase – tTG, nonpeptides of gliadin – npG, neoepitopes of gliadin/transglutaminases are commonly implicated) [5-8] suggests that DH, being more prevalent in men who appear to be less prone to autoimmunity development than women, is unlikely to be a classical autoantigen-driven autoimmune disease.

The histology of DH skin lesions demonstrate a predominantly neutrophilic infiltrate at the dermal-epidermal junction (DEJ), which often localizes to the papillary tips. The ultrastructural features and biological properties of these neutrophils, involving secretion of various proteases like neutrophil elastase (NE), suggest that they may play an important role in DEJ damaging, leading to blister formation [2, 4]. The involvement of an impaired human IgA Fc receptors (FcalphaRs) regulatory system, which may cause the activation of neutrophils with subsequent NE secretion, is proposed [2, 4]. In light of DH pathogenesis, FcalphaRs have been described on neutrophils.

The therapy of DH also indicates the important role of inflammatory cells in disease development. Interestingly, dapsone, rapidly improving DH rash (in a matter of days), seems to target rather neutrophils (inhibition of their chemotaxis and some cytokines release) than T- or B-cell. Despite its clinical utility, dapsone intake does not seem to affect cutaneous IgA deposition [1, 9, 10].

It is postulated that interleukin-6 (IL-6) plays a major role in neutrophil recruitment and function. Interleukin-6 is a multifunctional cytokine with both pro- and anti-inflammatory properties that may play a regulatory role in the immune system [11]. It may be secreted by epidermal cells suggesting their function in local cutaneous inflammation and autoimmunity. Interleukin-6 and its corresponding receptor are known to be synthesized by keratinocytes and have been proposed to affect the function of dermal inflammatory cells [12, 13].

Keratinocyte-derived IL-6 was observed in the relatively late phase of nickel-induced allergic contact dermatitis. We identified middle-aged women affected by itchy rash with concurrent DH diagnosed with direct immunofluorescence (DIF) and nickel hypersensitivity as suggested by epicutaneous patch testing. Thus, IL-6 might be a factor linking pathogenesis of those illnesses. In light of its known biological functions and its involvement in tissue pathology in other disease states, particularly in nickel-induced allergic contact dermatitis, it would appear that the

central and peripheral response by neutrophils in DH may be partially mediated by IL-6. It is known that IL-6 could also be produced locally within the skin and thus augment or control the extent of tissue inflammation.

We designed a study to examine some of these relationships and interactions, because the precise role of IL-6 in mediating pathological events of DH has not been elucidated, however a possible mechanism may involve the modulation of the functional repertoire of neutrophils and/or IgA production. Thus, an issue-probing study was done to assess the role of IL-6 in DH lesions by examining the relationships between IL-6/NE cutaneous expression and levels of serum anti-npG IgA, anti-tTG IgA, anti-eTG IgA in DH.

Material and methods

Sample collection and tissue specimens

The examined material consisted of lesional skin tissues and sera from the examined group (altogether 24 DH patients) before initiation of treatment. All patients had various extent of the disease and various disease duration, however none of patients was treated for DH before the clinical suspicion of DH was confirmed. Patients were diagnosed and treated at the Department of Dermatology, Poznan University of Medical Sciences in Poland. The study was approved by the local Ethics Committee of the Poznan University of Medical Sciences, Poland. The inclusion criteria involved:

- clinical features,
- typical immunoreactant deposits detected with DIF: the diagnosis of DH in each case was made when whichever pattern of possible 7 diagnostic patterns of granular IgA deposition was detected in DIF [1],
- histological aspects: conventional hematoxylin and eosin staining was performed to further support the diagnoses.

Skin tissues involved paraffin-embedded sections. The tissue sections were subject to 4- μ m section and then mounted on poly-L-lysine coated glass slides.

The serum used in the serological tests was taken at the time of hospital admission/ambulatory care.

Validation of proteins by immunohistochemistry

Paraffin-embedded sections were used for immunohistochemistry (IHC). Immunohistochemical staining was performed using the mouse monoclonal antibody to human NE, clone NP57 (Dako, Denmark), mouse monoclonal antibody to human IL-6, clone 10C12 (Leica, United Kingdom) and LSAB+ system HRP visualization kit (Dako, Denmark). The sections were washed in xylene (deparaffinization) and lightly rehydrated with a graded ethanol series. The samples were digested with proteinase K. Then, the slides were incubated with an appropriate dilution of antibodies, and, after visualization, washed with

PBS, counterstained with hematoxylin, dehydrated with an alcohol gradient, treated with xylene, and coverslipped. The appropriate IHC procedure controls were performed.

The slides were examined by light microscopy (BX40, Olympus, Japan) and digitally photographed to assess the intensities of positive immunostaining signals (expression intensities). The analysis of IHC staining was conducted with a specifically designed in Borland C++ image analysis software: "Analyser 4D" to quantitatively measure the stain intensity in percentage of reaction under the magnification 200× (NE) as well as 400× and 600× (IL-6).

Immunoenzymatic assay

Five milliliters of blood serum were obtained from each individual and anti-eTG/anti-tTG/anti-npG IgA antibodies were evaluated with three commercially available ELISAs. The level of circulating serum anti-npG IgA was evaluated with Anti-Gliadin (GAF-3X) ELISA (Euroimmun, Germany) with the manufacturer's cut-off value of 25 RU/ml. The level of circulating serum anti-tTG IgA was detected with Anti-tTG ELISA (Euroimmun, Germany) with the manufacturer's cut-off value of 20 RU/ml. The level of circulating serum anti-eTG IgA was detected with Anti-eTG ELISA (Immundiagnostic, Germany) with the manufacturer's cut-off value of 18 AU/ml. All three tests are recommended by producers as useful in DH diagnosis. All measurements were made in ELISA plate reader by a single operator following the manufacturer's instructions.

Statistical analysis

Significant differences in expression intensities of IL-6/NE in the examined group were evaluated by the Wilcoxon rank-sum test with a significance level of $p < 0.05$ [14]. Correlations between the investigated parameters were determined by the Spearman's rank correlation coefficient.

All statistical analyses were performed with the use of statistical analysis Software Statistica PL 10.0 (StatSoft Inc., USA).

Results

Intensity of NE and IL-6 deposits processed with digital image analysis in representative DH patients lesional skin is shown in Figs. 1 and 2, respectively.

The analysis of correlation showed no statistically significant correlations between the intensity of cutaneous NE expression and the intensity of cutaneous IL-6 expression. We revealed also a lack of correlations between IL-6 expressions and the levels of serum IgA antibodies to eTG, tTG, npG in patients with DH. Obtained results are presented in Table 1.

The IL-6 expression was significantly lower than that of NE (the mean of NE was 3.46 percentage of reaction, the mean of IL-6 was 0.20 percentage of reaction;

$p = 0.0006$). The results of calculated difference are shown in graphs in Fig. 3.

Discussion

The precise mechanism involved in the stimulation of cutaneous lesions in DH is unknown. Probably, neutrophils have a pivotal role in mediating pathological inflammatory states in DH. However, various studies evaluated the participation of T lymphocytes (CD4) [15], antigens (eTG, tTG, npG, heat shock proteins 60, 70, and 90) [5-8, 16] that would lead to the production of cytokines (IL-6), which would be responsible for the chemotaxis of neutrophils, microabscess formation and development of skin lesions.

During allergic or irritant reactions, the expression of IL-6 by keratinocytes is significantly enhanced and can be considered as one of the mediators of inflammation present in allergic reactions [17]. Nickel demonstrated the highest immune activation within the common allergens and coexistence of nickel-induced contact dermatitis with DH may be observed. Thus, the conjunction of nickel hypersensitivity and DH may suggest common signaling pathways. Dhingra *et al.* [18] noted that innate/interferon (IFN)/Th1-related (including IL-6) and Th-17-related genes were commonly induced by nickel. Interleukin-6 as a marker of innate immunity was significantly upregulated for most allergens [18]. Using gene arrays [18], a higher mRNA expression of the IL-6 gene was observed in nickel than in other allergen groups. Other unifying data [19] for DH and nickel hypersensitivity indicated IL-6 as an important modulator of the *CAMP* gene expression, a gene coding the human antibacterial peptide LL-37. A pronounced induction in keratinocytes for LL-37 is noted in both diseases [19]. In fact, this molecule plays a crucial role in local and systemic inflammation. Thus, one of the effects of IL-6 might be the up-regulation of the *CAMP* gene that was documented in different inflammatory dermatoses: nickel contact hypersensitivity and DH.

The ability of IL-6 to induce or augment neutrophils activity has been reported by several investigators. Moreover, it was postulated that IL-6 delays neutrophils apoptosis, resulting in a larger population of surviving cells with a greater collective capacity for proteolytic enzymes (e.g. NE) release. Interleukin-6 may stimulate neutrophils to produce NE, however our IHC study did not support this thesis as we found no correlation between cutaneous expression of IL-6 and cutaneous expression of NE. Nevertheless, probably some correlations may be revealed in individual cases or between IL-6 and other neutrophil degradation products (e.g. cathepsin G, proteinase 3 measured separately or added together).

Probably, pathological responses in DH may be initiated after cross-linking of cell surface Fc receptors that bind the constant portion of IgA (FcalphaR/CD89). Liter-

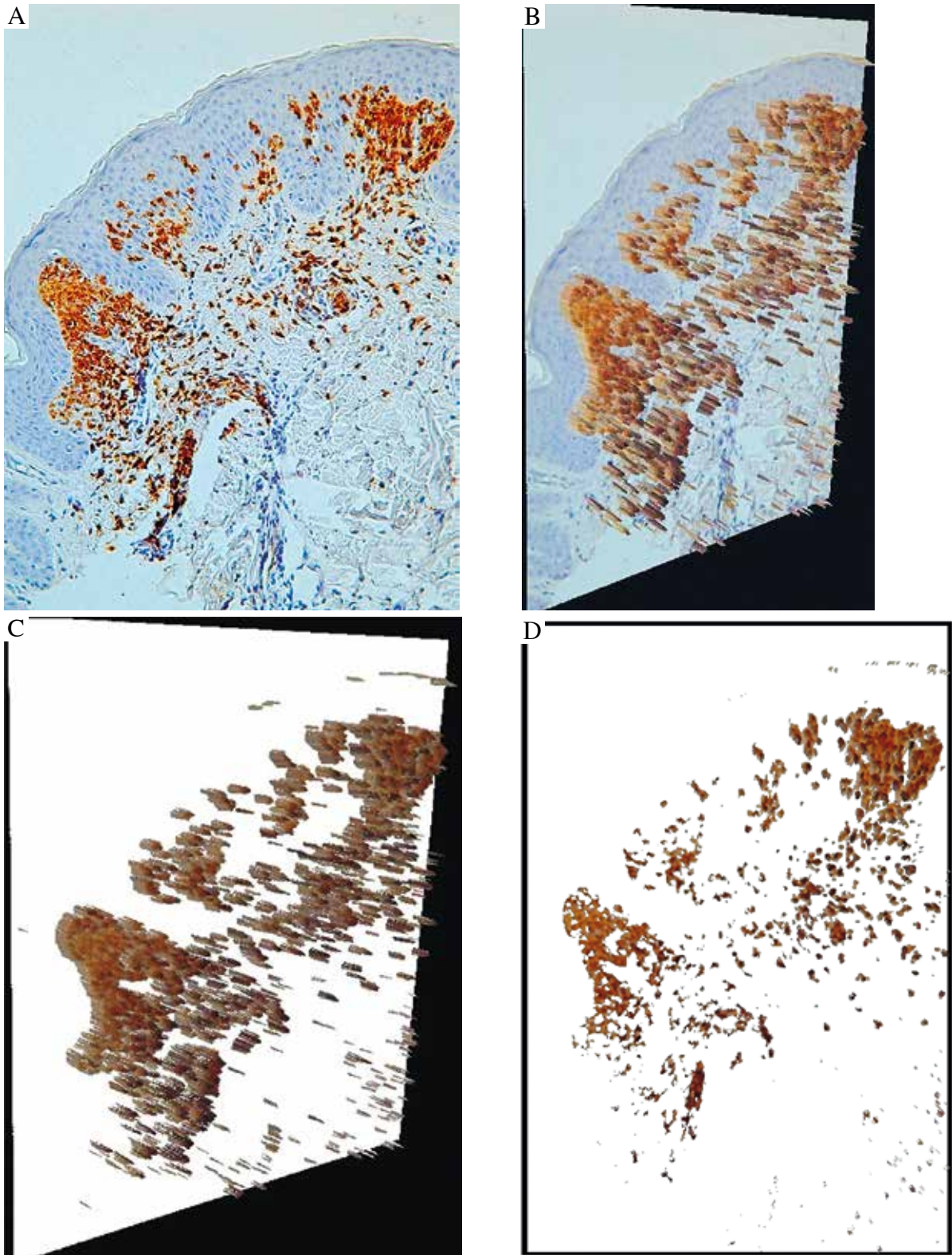


Fig. 1. The intensity of cutaneous NE expression. NE deposits in immunohistochemistry in lesional skin in a patient with DH (immunoperoxidase staining on paraffin embedded sections, original magnification x200) (A). Intensity of NE deposits processed with digital microscopic image analysis superimposed on immunohistochemistry (B). Intensity of NE deposits processed with digital microscopic image analysis: 3D (C). Intensity of NE deposits processed with digital microscopic image analysis: 2D (D)

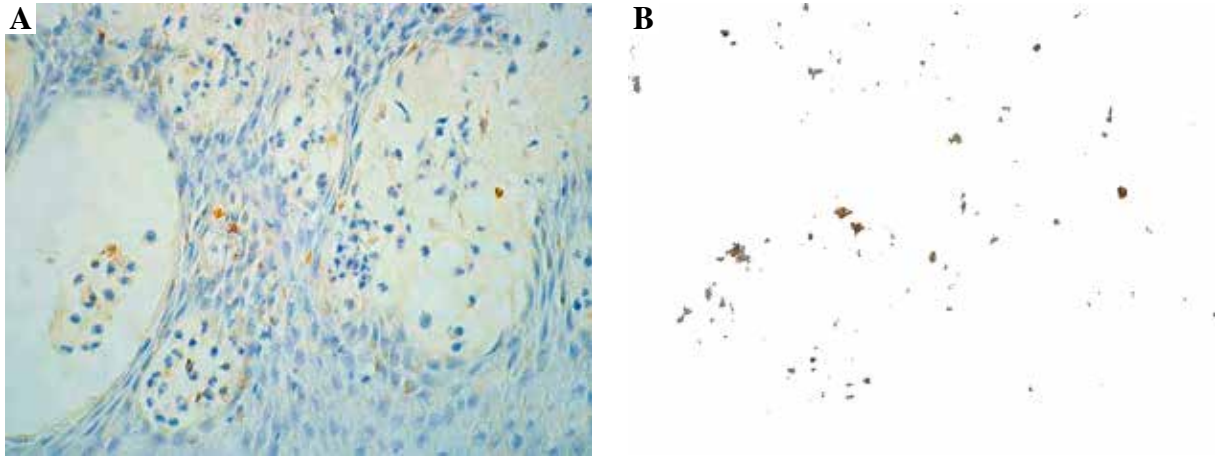


Fig. 2. The intensity of cutaneous IL-6 expression. IL-6 deposits in immunohistochemistry in lesional skin in a patient with DH (immunoperoxidase staining on paraffin embedded sections, original magnification x600) (A). Intensity of IL-6 deposits processed with digital microscopic image analysis: 2D (B)

ature data suggest that FcαR, through its capacity to mediate secretion of IL-6, may play an important role in B-cell proliferation and immunoglobulin production. The identification of FcαR has elucidated the link between inflammatory cells and IgA antibodies, which can result in a variety of responses, including release of inflammatory mediators (e.g. NE) and skin lesion formation. A previous study indicated elevated levels of IL-6 in sera from patients with diseases associated with increased IgA antibodies, suggesting that FcαR may be involved in this process. Thus, multivalent cross-linking of FcαR may induce a significant release of IL-6 by inflammatory cells (neutrophils). Release of IL-6 by triggering the FcαR may reveal an additional effector function for neutrophils in IgA-mediated inflammatory responses. However, presented results are in conflict with this opinion. Our findings are expanding/validating the observations of previous investigations and showing insignificant effects of anti-tTG/eTG/npG IgA on the release of inflammatory mediators in cutaneous DH lesions – NE and IL-6. It is in accordance with our initial study which revealed that the strength of correlation between the intensity of NE expression in lesional skin and the level of serum anti-eTG IgA in DH was low and should not be regarded as a moderate relationship [20].

On the other hand, the role of IL-6 in IgA production has been demonstrated [21] in mice with targeted disruption of the gene encoding IL-6. These mice have a profound reduction in the number of IgA producing cells and have grossly deficient local antibody responses on mucosal challenge. Interestingly, this defect was corrected by IL-6 gene therapy, demonstrating a critical role for IL-6 *in vivo* in the development of IgA mucosal antibody response.

Our findings suggest no substantial interplays between IL-6, NE, anti-npG IgA, anti-tTG IgA or anti-eTG IgA in DH. Possibly, presented results may indicate the

Table 1. No correlations between the intensity of IL-6 expression (in percentage of reaction) and analyzed parameters

Intensity of IL-6 expression versus	Correlation coefficient <i>r</i>	<i>p</i> value
intensity of NE expression	0.2111	0.4501
anti-eTG IgA	0.0626	0.8246
anti-tTG IgA	0.3596	0.1881
anti-npG IgA	0.0787	0.7804

IL-6 – interleukin 6; NE – neutrophil elastase; eTG – epidermal transglutaminase; tTG – tissue transglutaminase; npG – nonapeptides of gliadin

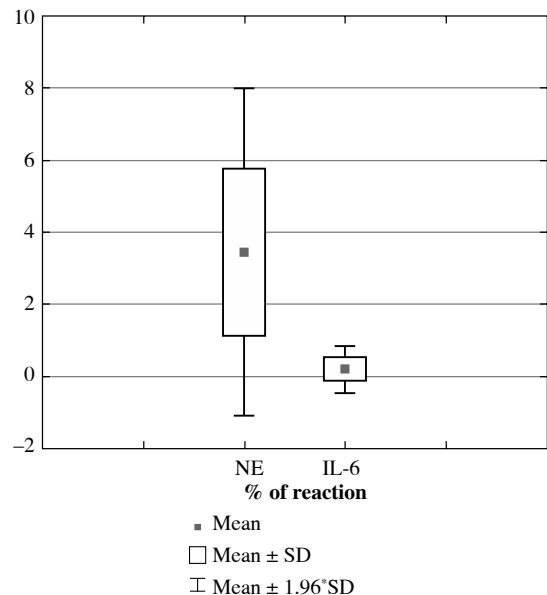


Fig. 3. The statistically significant difference between the intensity of cutaneous NE expression and cutaneous IL-6 expression (in percentage of reaction)

substantial role of neoepitopes in DH pathogenesis, which can be involved in examined interactions. However, we found a significantly higher NE expression than that of IL-6. Moreover, prominent tissue NE expression suggests that this is not an epiphenomenal bystander [2, 7] (Fig. 1). Thus, we postulated that the intense NE expression does indicate this protease as the major mediator of DEJ remodeling in DH, whereas a weak IL-6 expression might reflect faulty IL-6 signaling in the acute DH. Seemingly, releasing of NE at sites of inflammation in active human DH may not be primarily associated with IL-6 action. In light of this, the involvement of intertwining autoinflammation and autoimmunity processes in DH development should be considered. However, the crucial issue is the proper understanding of the differences between these two immunological mechanisms: they have different ways to chronic activation of immune system. Thus, in autoinflammation the innate immune system directly causes tissue inflammation, whereas in autoimmunity the innate immune system, with IL-1 β participating, activates the adaptive immune system which, in turn, is responsible for the inflammatory process [22]. The pure autoinflammation is characterized by neutrophilic inflammation, what is consistent with predominant neutrophilic infiltration in DH. Excitingly, propafenone and interferon alpha can apparently trigger DH rash by activating neutrophils [23-26]. It is known that interferon α can induce autoimmune-mediated pemphigus and there is a time-lag between interferon α usage and DH rash development so interferon α might have delayed dual action on autoimmunity triggering and neutrophil activation in DH. Obviously, also iodides exacerbate DH skin lesions in a matter of hours probably through the activation of neutrophils apparently without any autoimmune processes [1]. Moreover, DH patients demonstrate skin lesions of symmetric distribution in strictly specified locations prone to continuously repetitive local microtrauma, i.e. knees, extensor surfaces of forearms next to elbows and gluteal region [1], suggesting the involvement of local factors conceivably co-activating autoinflammatory process. Furthermore, Dolcino *et al.* [27] showed an increased expression of genes coding for neutrophil-derived proteins suggesting autoinflammatory background. On the other hand, besides the autoimmune-derived immune response, DH has a strong genetic association with HLA DQ2 and/or DQ8 indicating autoimmune background. Dolcino *et al.* [27] indicated that consistently with the possibly autoimmune origin of DH, gene profiling revealed a B- and T-cell immune response. A unifying hypothesis for DH requires the explanation of some links between mentioned two arms of the immune system. One explanation might be an uncontrolled innate-related inflammation provoked by local microtrauma-derived stimulus or stimuli causing adaptive system activation only as a secondary response. An overactivated cytokine cascade through IL-6 might activate nonspecific and nonpathogenic T-/B-cell responses

in DH. Yet another possibility is that mainly gut-derived autoimmunity and predominantly skin-derived autoinflammation initially developing independently finally combine to produce DH rash. In light of this, Hall *et al.* [28] hypothesized that the presence of mucosal inflammation in the gut of DH patients may be crucial in priming both neutrophils and cutaneous endothelial cells through the production of elevated proinflammatory cytokine levels. Moreover, neutrophils, although accepted as primary effector cells of inflammation, are usually ignored in their role in later stages of immune stimulation. In this context, neutrophil activation, cytokine release and antigen presentation may link the innate immune system to adaptive responses giving a broader role to neutrophils than pure 'autoinflammation'. Dermatitis herpetiformis in this respect requires a more critical analysis of neutrophil activation, and DH neutrophils may have a different profile compared with autoinflammatory disorders. Plausibly, the activation of inflammasome as an important component of the innate immune response [29], may be critically involved in DH inflammation. Thus, further studies on inflammasomes in DH would provide new evidence if autoantibodies binding represents a secondary autoimmunity or heterogeneity of disease with a broad immunopathological spectrum.

Presented results seem to indicate the heterogenetic nature of DH pathogenesis suggesting that both autoimmune and autoinflammatory phenomena may be involved in DH cutaneous pathology.

These observations may imply that the cutaneous rashes lumped together as DH have no uniform pathogenesis: in some cases, particularly those connected with the nickel hypersensitivity, autoinflammation predominantly underlies the disease (IL-6 contributes to this process), whereas in other cases autoimmunity is the main pathogenic mechanism.

This preliminary hypothesis on the possible dual functions of IL-6 as a molecule that interacts between the immune and inflammatory system, offers a new opportunity to study the pathogenesis of autoantibody-mediated cell separation and blister formation in the DH skin. Perhaps, DH should be added to the growing list of diseases in pathogenesis of which autoinflammation is hypothesized in recent reviews [29, 30]. It is felt then that research studies utilizing various experimental approaches are needed to resolve this intriguing issue, which might offer novel possibilities for the management of DH.

This study was partly funded from the grant of the Polish Ministry of Science and Higher Education (N N 401 00 12 39).

A part of this study was accepted for presentation at the 44th Annual ESDR Meeting (10-13 September 2014, Copenhagen, Denmark): Unrelated cutaneous expressions

of interleukin-6 and neutrophil elastase are also unlinked to IgA antibodies to gliadin nonapeptides, epidermal and tissue transglutaminases in dermatitis herpetiformis (abstract no. 099). *J Invest Dermatol* 2014; 134 suppl. 2: s.17.

References

- Dmochowski M (ed.). (2006): Opryszczkowe zapalenie skóry. In: Autoimmunizacyjne dermatozy pęcherzowe. Wydawnictwo Naukowe AM w Poznaniu, Poznań: 1-311 (printed text and iconography on CD) ISBN 83-60187-21-5: www.dmochowski.com.pl (2004).
- Gornowicz-Porowska J, Seraszek-Jaros A, Kaczmarek E, et al. (2012): IgA autoantibodies to gliadin nonapeptides, tissue transglutaminase and epidermal transglutaminase are associated, but unrelated to neutrophil elastase expression in lesional skin in human dermatitis herpetiformis. *Post Derm Alergol* 29: 233-239.
- Gornowicz-Porowska J, Bowszyc-Dmochowska M, Seraszek-Jaros A, et al. (2012): Association between levels of IgA antibodies to tissue transglutaminase and gliadin-related nonapeptides in dermatitis herpetiformis. *Scientific World Journal* 2012: 363296.
- Gornowicz-Porowska J, Bowszyc-Dmochowska M, Dmochowski M (2012): Autoimmunity-driven enzymatic remodeling of the dermal-epidermal junction in bullous pemphigoid and dermatitis herpetiformis. *Autoimmunity* 45: 71-80.
- Dieterich W, Laag E, Bruckner-Tuderman L, et al. (1999): Antibodies to tissue transglutaminase as serologic markers in patients with dermatitis herpetiformis. *J Invest Dermatol* 113: 133-136.
- Sárdy M, Kárpáti S, Merkl B, et al. (2002): Epidermal transglutaminase (TGase 3) is the autoantigen of dermatitis herpetiformis. *J Exp Med* 195: 747-757.
- Gornowicz-Porowska J (2012): Expression of neutrophil elastase in relation to the autoimmunity to epidermal transglutaminase, BP180, BP230, desmoglein 1 and 3 in autoimmune blistering dermatoses. ISBN 978-3-8454-3373-8, LAP Lambert Academic Publishing GmbH&Co Kg.
- Schwartz E, Kahlenberg F, Sack U, et al. (2004): Serologic assay based on gliadin-related nonapeptides as a highly sensitive and specific diagnostic aid in celiac disease. *Clin Chem* 50: 2370-2375.
- Mendes FB, Hissa-Eliañ A, Abreu MA, Gonçalves VS (2013): Review: dermatitis herpetiformis. *An Bras Dermatol* 88: 594-599.
- Plotnikova N, Miller JL (2013): Dermatitis herpetiformis. *Skin Therapy Lett* 18: 1-3.
- Hirano T (2010): Interleukin 6 in autoimmune and inflammatory diseases: a personal memoir. *Proc Jpn Acad Ser B Phys Biol Sci* 86: 717-730.
- Paquet P, Piérard GE (1996): Interleukin-6 and the skin. *Int Arch Allergy Immunol* 109: 308-317.
- Yao X, Huang J, Zhong H, et al. (2014): Targeting interleukin-6 in inflammatory autoimmune diseases and cancers. *Pharmacol Ther* 141: 125-139.
- Wehrens R, Franceschi P (2012): Thresholding for biomarker selection in multivariate data using Higher Criticism. *Mol Biosyst* 8: 2339-2346.
- Caproni M, Feliciani C, Fuligni A, et al. (1998): Th2-like cytokine activity in dermatitis herpetiformis. *Br J Dermatol* 138: 242-247.
- Kasperkiewicz M, Tukaj S, Gembicki AJ, et al. (2014): Evidence for a role of autoantibodies to heat shock protein 60, 70, and 90 in patients with dermatitis herpetiformis. *Cell Stress Chaperones* [Epub ahead of print]. DOI: 10.1007/s12192-014-0507-6.
- Sosroseno W (1995): The immunology of nickel-induced allergic contact dermatitis. *Asian Pac J Allergy Immunol* 13: 173-181.
- Dhingra N, Shemer A, Correa da Rosa J, et al. (2014): Molecular profiling of contact dermatitis skin identifies allergen-dependent differences in immune response. *J Allergy Clin Immunol* 134: 362-372. DOI: 10.1016/j.jaci.2014.03.009.
- Frohman M, Agerberth B, Ahangari G, et al. (1997): The expression of the gene coding for the antibacterial peptide LL-37 is induced in human keratinocytes during inflammatory disorders. *J Biol Chem* 272: 15258-15263.
- Bowszyc-Dmochowska M, Seraszek A, Kaczmarek E, et al. (2009): Low strength of correlation between the intensity of neutrophil elastase expression in lesional skin and the level of serum IgA antibodies to epidermal transglutaminase in dermatitis herpetiformis. *Open Autoimmun J* 1: 1-4.
- Ramsay AJ, Husband AJ, Ramshaw IA, et al. (1994): The role of interleukin-6 in mucosal IgA antibody responses in vivo. *Science* 264: 561-563.
- Doria A, Zen M, Bettio S, et al. (2012): Autoinflammation and autoimmunity: bridging the divide. *Autoimmun Rev* 12: 22-30.
- Duś M, Dańczak-Pazdrowska A, Gornowicz J, et al. (2009): Przejściowe ujawnienie się opryszczkowego zapalenia skóry u kobiety z predyspozycją rodzinną wywołane przyjmowaniem propafenonu. *Post Derm Alergol* 26: 239-242.
- Dmochowski M, Neumann E, Bowszyc-Dmochowska M, et al. (1995): Dermatitis herpetiformis following interferon-alpha therapy. *Post Derm* 12: 7-10.
- Borghi-Scoazec G, Merle P, Scoazec JY, et al. (2004): Onset of dermatitis herpetiformis after treatment by interferon and ribavirin for chronic hepatitis C. *J Hepatol* 40: 871-872.
- Dmochowski M, Januszkiewicz-Lewandowska D, Bowszyc-Dmochowska M (2007): Interferon-alpha and dermatitis herpetiformis. *Dermatol Klin* 9: 237-238.
- Dolcino M, Cozzani E, Riva S, et al. (2012): Gene expression profiling in dermatitis herpetiformis skin lesions. *Clin Dev Immunol* 2012: 198956.
- Hall RP 3rd, Takeuchi F, Benbenisty KM, Streilein RD (2006): Cutaneous endothelial cell activation in normal skin of patients with dermatitis herpetiformis associated with increased serum levels of IL-8, sE-Selectin, and TNF-alpha. *J Invest Dermatol* 126: 1331-1337.
- Beer HD, Contassot E, French LE (2014): The inflammasomes in autoinflammatory diseases with skin involvement. *J Invest Dermatol* 134: 1805-1810.
- Nguyen TV, Cowen EW, Leslie KS (2013): Autoinflammation: From monogenic syndromes to common skin diseases. *J Am Acad Dermatol* 68: 834-853.