

● Original paper

DO UMBILICAL CORD WRAPPED AROUND THE FETAL BODY CAN MIMIC SIGNS OF AORTAL COARCTATION?

**Authors:**

Katarzyna Więckowska¹, Katarzyna Zych-Krekora², Maciej Słodki^{3,4}, Maria Respondek-Liberska^{2,3}

1. Medical University of Lodz, 5th Grade, Scientific Student's Circle of Prenatal Cardiology 2. Department for Diagnoses & Prevention of Congenital Malformations, Medical University of Łódź, Łódź, Poland 3 Department of Prenatal Cardiology, Research Institute Polish Mother's Memorial Hospital, Łódź, Poland 4. Faculty of Health Sciences. The State University of Applied Sciences in Plock, Poland

Prenat Cardio 2016 Jan; 6(1):82-86
DOI: 10.1515/pcard-2016-0011

Abstract**Objectives:**

Coarctation of the aorta (CoA) is an irreversible congenital heart defect. Its prenatal diagnosis is not rare a subject to false-positive conclusion. We present a novel hypothesis explaining the basis of this error.

Methods:

Ten cases of prenatal suspicion of the coarctation of the aorta (based on disproportion at the level of 4 chamber view and mediastinum) coincided with the umbilical cord wrapped around the fetal body were found in the Filemaker database of the Fetal Cardiology Department. Only single pregnancies were taken into account. In all cases another cardiac and extracardiac malformations were excluded.

Results:

The mean maternal age was 29,6 years. The mean gestational age was 33 7/8 weeks. All fetuses were in a good cardiovascular condition. The usual position of the umbilical cord was neck, but they were also location such as nucha, abdomen or lower limb.

At birth, all newborns had normal anatomy of the heart. We conclude that the explanation of the false diagnosis was haemodynamic, resulting from the compression of the fetal neck by the umbilical cord that resulted in a disproportion of cardiac blood flow, "mimicking" CoA.

Conclusions:

1. Functional disturbances can mimic prenatal CoA.
2. Umbilical cord position (specially enlacing the fetus neck) should be taken into consideration in suspected cases of fetal CoA.

Key words: fetal echocardiography, coarctation of the aorta, prenatal diagnosis, perinatal outcome, umbilical cord, pediatric cardiology

INTRODUCTION

Coarctation of the aorta is a pathological narrowing of the aorta that changes flow through this great vessel. It usually affects the segment between the left subclavian artery and the ductus arteriosus. Spectrum of this congenital heart disease (CHD) ranges from only a slight narrowing to a hypoplastic or even an interrupted aortic arch¹. It is a common anomaly. The National Polish Register of Prenatal Cardiac Anomalies reports its 2.5% prevalence in fetuses afflicted with CHD in Poland².

There are two conceptional explanations of the origin of coarctation: ductus tissue theory, explains this anomaly by the migration of smooth muscle cells from the ductus to

the aorta, and the hemodynamic theory, which assumes the reduced blood flow through the aorta in fetal life³.

The primary aim of our report was to determine whether physiological alterations of fetal and umbilical circulation have led to this discrepancy of pulmonary artery and aortic sizes resulting in false-positive diagnosis of coarctation.

How to cite this article:

Więckowska K, Zych-Krekora K, Słodki M, Respondek-Liberska M

Do umbilical cord wrapped around the fetal body can mimic signs of aortal coarctation?.

Prenat Cardio 2016 Jan; 6(1):82-86

METHODS

For the purpose of the study the Filemaker database of the Department was searched to find all cases with disproportion of the heart's chambers coexisting with the umbilical cord enlacing the fetus. The fetus could not have

other cardiac nor extracardiac abnormalities.

The images of three vessels view were analyzed. Each had to comprise the isoechogenic area of the thymus and

the measurements of the great vessels in the mediastinum. The pulmonary artery and the aorta diameters were compared and the PA/Ao ratio was calculated for each of fetuses. The size of the aortic isthmus in saggital plane were collected and the Z-score was found if possible (Fig. 1). The nomograms of Z-scores were obtained by <http://fetal.parameterz.com/app> website. The PA/Ao > 1,6 and Z-score lower than 1,65 of standard deviation were considered as indicating the coarctation.

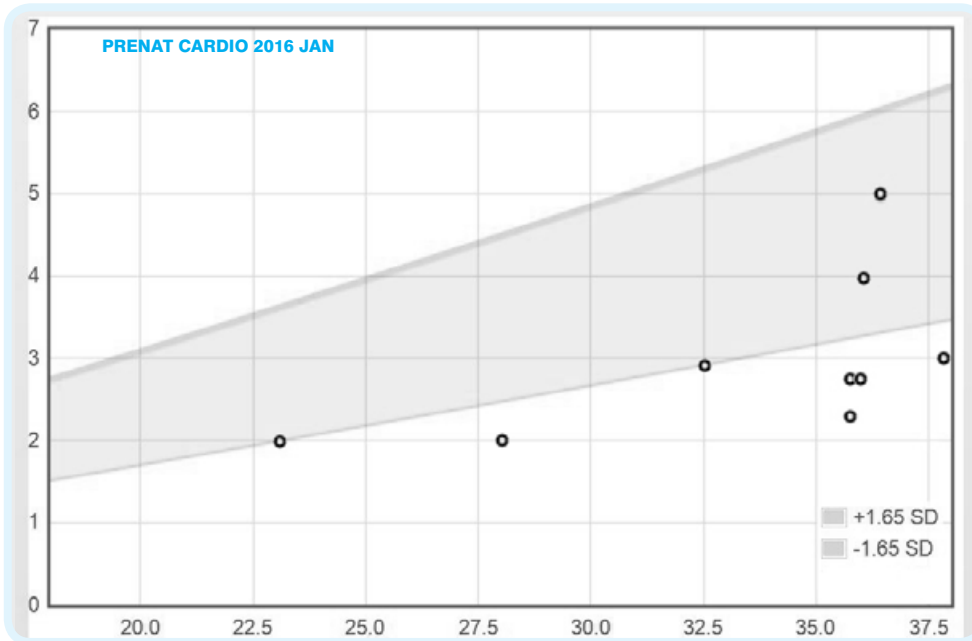


Fig.1. Z-scores of the known isthmus sizes according to Pasquini et. al.

Table 1. Sonographic and echocardiographic features of prenatal MS and current case

	Patient's age [years]	Gestational age (last menstrual period) [weeks]	Estimated fetal weight (Hadlock et al. ²⁵) [g]	PA/Ao ratio	Isthmus of the aorta [mm], Z-score	CVPS	The umbilical cord enlacing	Other
1.03.2017	29	35 5/7	2234	1,53	2,8 (-2,45)	8	The neck and thorax	Oligohydramnion
2.03.2017	20	38	2623	1,86	3 (-2,45)	10	The neck	Reverse flow in the aortic arch
3.03.2017	32	35 6/7	2692	1,6	4 (-0,52)	8	The neck	Reverse flow in the aortic arch
4.03.2017	31	35 5/7	2386	1,57	2,3 (-3,56)	10	The neck	
5.03.2017	29	23	550	1,68	2 (-1,62)	10	The tight and the abdomen	
6.03.2017	23	35 6/7	2840	1,79	2,8 (-2,48)	8	The neck	Reverse flow in the aortic arch
7.03.2017	35	36 3/7	2637	1,41	5 (0,61)	7	The abdomen	TR, PE
8.03.2017	37	28	1232	1,8	2 (-2,82)	10	The neck and the thorax	Two-way flow through the FO
9.03.2017	24	37 4/7	2276	1,75	No data*	10	The neck	
10.03.2017	36	32 4/7	1789	1,67	3,2 (-1,7)	8	The neck	Hyperechogenic bowels
Average	29,6	33 7/8	2125,9	1,67		9		

* Not measured because of the fetal position during the examination

RESULTS

Since January 2012 to March 2016 ten such cases have been examined. The mean age of the pregnant women was 29,6 years (see Table 1. below). The mean gestational age at the time of the first examination was 33 7/8 weeks. It is worth noting that only one case has been diagnosed in the second trimester, the other observations have been done in the third trimester. All ten fetuses had an efficient cardiovascular system (cardiovascular condition of the fetus number 7. improved in consequent examinations). The cardiovascular condition was described by Cardiovascular Profile Score. The patency of the foramen ovale and of the arterial duct was confirmed.

The photo of the umbilical cord is presented in Fig. 2. The most common location of the umbilical cord was neck of the fetus (8 out of 10). Surprisingly, in two cases in which the cord was wrapped around the abdomen, the observations were similar to these in 'neck' cases.

Eventually, the fetuses follow-up was checked to see whether

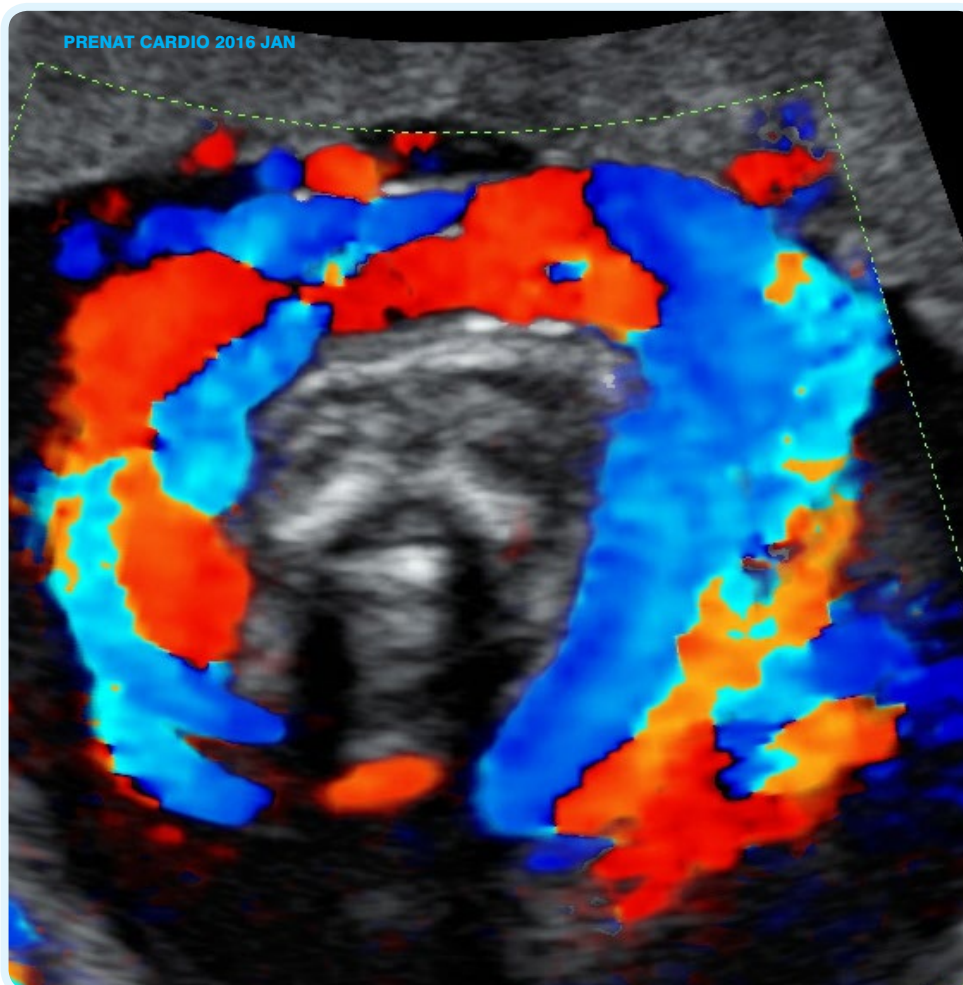


Fig. 2. Umbilical cord enlacing fetal neck

newborns were suffering from any of the cardiac dysfunction, particularly from the coarctation of the aorta. The collected data are found in Table 2. All babies were delivered on time with a mean birth weight 3054,4 g. Female newborns consisted 6 out of 10 cases.

DISCUSSION

The problem of high incidence of false-positive diagnoses of the CoA caused difficulties since the beginning of the fetal ultrasonograms. The investigators have been trying to select the best method for the assessment of fetal aorta in each trimester.

Coarctation is suspected in the basic screening of the heart, i.e. by obtaining the four-chamber view, because examination shows that the right side of the heart is larger than the left and the disproportion is also seen in the great vessels in the mediastinum^{4,5,6,7}. The inference is strengthened if there is disproportion between the pulmonary artery and the aorta with the PA/Ao ratio equal

to or larger than 1,6 should alert about CoA^{8,9}. However, these indicators are not absolutely foolproof^{10,11}. The ultrasonographic diagnosis includes also Z-scores of the ascending aorta and aortic isthmus dimensions. Isthmal to ductal ratio may be helpful in exclusion of the CoA too^{12,13}.

The enlarged right heart structures may be a result of late pregnancy¹⁴, restrictive foramen ovale¹⁵ and premature fetal closure of the arterial duct¹⁶.

Coarctation of aorta is considered to be an irreversible defect. However, there have been several cases of spontaneous regression of the CoA in infants¹⁷. How can we explain the absence of the suspected CoA just after a birth? False positive diagnoses of prenatal CoA have been reported several times^{18,19}, but we noted and are reporting for the first time that the prenatal condition – the umbilical cord enlacing the neck – may mimic CoA. How can the umbilical cord wrapping the fetal neck affect the fetal circulation?

Umbilical cord wrapped around the fetal neck causes disturbances in the blood supply to the cerebrum. In our hypothesis a decreased flow through cerebral

	Weeks of birth	Type of the labor	Newborn's weight	Apgar score	Sex of the child
1.03.2017	38	Vaginal	2750	10	F
2.03.2017	38	Cesarean section	2500	9	F
3.03.2017	36	Cesarean section	2900	9	M
4.03.2017	38	Vaginal	2900	9	F
5.03.2017	38	Cesarean section	3480	10	F
6.03.2017	39	Cesarean section	3290	9	M
7.03.2017	39	Cesarean section	3360	9	M
8.03.2017					F
9.03.2017	39	Vaginal	2960	9	F
10.03.2017	40	Vaginal	3350	9	M
Average	38,3		3054,4	9,2	

Table 2. Postnatal follow-up of cases presented above.

PRENAT CARDIO 2016 JAN

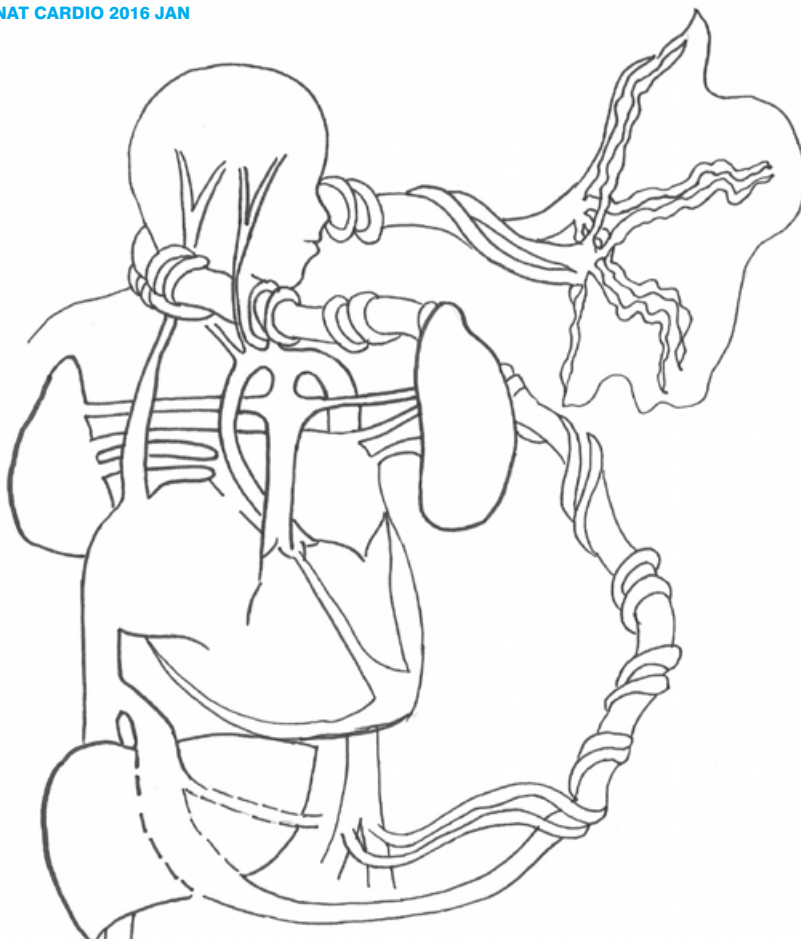


Fig 3. Fetal circulation alternations

vessels leads to the alternations in ductus venosus functioning and its dilation (Fig. 3.).

The authors believe that the consequence of this condition is an enlargement of the right atrium and ventricle due to the redistribution of the blood, which may be a direct basis of a reduced flow through the aorta (Fig. 4.).

This hypothesis is drawn from the report published by Tchirikov et al. Scientists have found that the ductus venosus/ umbilical vein blood flow ratio increases in the state of fetal hypoxia in the lambs, which means that larger part of the umbilical venous blood flow enters the DV during hypoxia, even if the velocity through the DV is decreased.²⁰

The problems with umbilical cord encompass its knots and many morphological abnormalities²¹. A true knot of the umbilical cord may lead to e. g. fetal hypoxia, intrauterine growth restriction and even to fetal death. Compression of the umbilical cord may threaten fetal life too, reducing the blood flow through

the vein and arteries.²² Fetuses with the true knot of the umbilical cord are at higher risk of fetal distress and meconium stained amniotic fluid and fourfold higher risk of antepartum fetal death.²³

Kobayashi et al. focused on the issue of the entanglement of the cord and its consequences. They mention higher frequency of Apgar scores in the 1 minute and 5 minute lower than 7 and umbilical artery pH lower than 7,1 in the group of fetuses whose neck or trunk was enlaced by the cord.²⁴

Although earlier reports associated umbilical cord tightening up with other disturbances, we propose that umbilical cord enlacing the fetus may influence the image derived from an ultrasonographic examination and we suggest a haemodynamic explanation of the disproportion in the prenatal cardiac blood flow. This report is limited only to the investigation of the impact of entanglement of the cord on the fetal hypoxia, although there are several causes of this state, e. g. disturbances in the placental circulation.

Functional disturbances of blood flow may mimic prenatal narrowing of the aorta due to the appearing

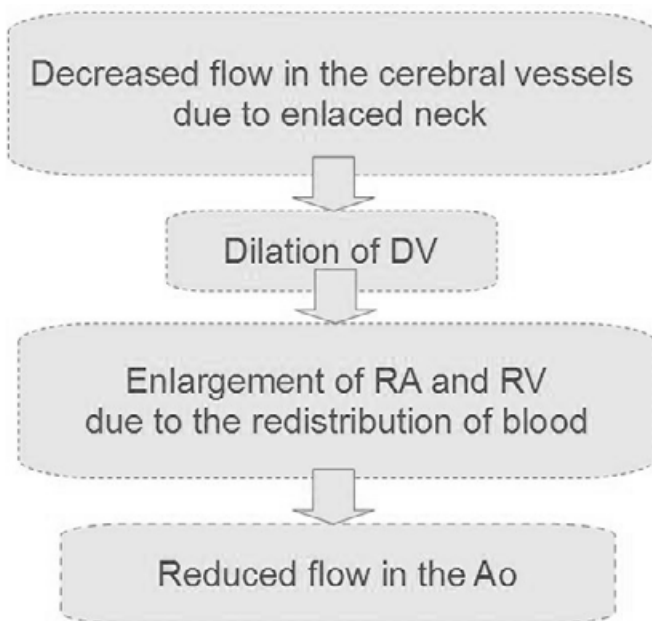


Fig 3. Possible explanation to this phenomenon

disproportion between the heart's chambers and great vessels. Not each of disproportions will result in diagnosis of the coarctation. Umbilical cord position and specially enlacing neck of the fetus should be ruled out as an alternative explanation, in cases suspected of fetal CoA.

CONCLUSIONS

1. Functional disturbances can mimic prenatal CoA.
2. Umbilical cord position (specially enlacing the fetus neck) should be taken into consideration in suspected cases of fetal CoA.

References

1. Respondek-Liberska M. Prenatal cardiology for obstetrician and pediatric cardiologists, Czelej 2006, Poland (in Polish).
2. Website of The National Polish Register of Prenatal Cardiac Anomalies www.orpkp.pl
3. Abuhamad A, Chaoui R. A Practical Guide to Fetal Echocardiography. Wolters Kluwer 2010 p. 158.
4. Brown DL, Durfee SM, Hornberger LK. Ventricular discrepancy as a sonographic sign of coarctation of the fetal aorta: How reliable is it? *J Ultrasound Med* 1997;16:95-99.
5. Benacerraf BR, Saltzman DH, Sanders SP. Sonographic sign suggesting the prenatal diagnosis of coarctation of the aorta. *J Ultrasound Med* 1989;8:65.
6. Emerson D, Cartoer M, DiSessa T, et al. Prenatal sonographic identification of coarctation of the aorta. *J Ultrasound Med* 1988;7: 271.
7. Allan LD, Chita SK, Anderson RH, et al. Coarctation of the aorta in prenatal life: An echocardiographic, anatomical and functional study. *Br Heart J* 1988;59:356.
8. Słodki M, Rychik J, Moszura T, Janiak K, Respondek-Liberska M. Measurement of the great vessels in the mediastinum could help distinguish true from false-positive coarctation of the aorta in the third trimester. *J Ultrasound Med*. 2009; 28:1313-1317.
9. Gomez-Montes E, Herraiz I, Mendoza A, Escribano D, Galindo A. Prediction of coarctation of the aorta in the second half of pregnancy. *Ultrasound Obstet Gynecol* 2013; 41:298-305.
10. Sharland GK, Chan K, Allan LD. Coarctation of the aorta: Difficulties in prenatal diagnosis. *BR Heart J* 1994; 71:70.
11. Hornberger LK, Sahn DJ, Kleinman CS, et al. Antenatal diagnosis of coarctation of the aorta: A multicenter experience. *J Am College Cardiol* 1994; 23:417.
12. Pasquini L, Mellander M, Seale A, Matsui H, Roughton M, Ho SY, Gardiner HM. Z-scores of the fetal aortic isthmus and duct: an aid to assessing arch hypoplasia. *Ultrasound Obstet Gynecol* 2007; 29:628-633.
13. Matsui H, Mellander M, Roughton M, Jicinska H, Gardiner HM. Morphological and physiological predictors of fetal aortic coarctation. *Circulation*. 2008;118:1793-1801.
14. Allan LD. Fetal cardiac scanning – Online Education. Fetal Medicine Foundation. <https://fetalmedicine.org/fetal-echocardiography-1>. [11 August 2016]
15. Uzun O, Kadir B, Ayhan YI, Moselhi M, Rushworth F, Morris S, Beatti B, Wiener J, Lewis MJ. Diagnostic ultrasound features and outcome of restrictive foramen ovale in fetuses with structurally normal hearts. *Pediatr Cardiol* 2014;35(6):943-52.
16. Gewillig M, Brown SC, De Catte L, Debeer A, Eyskens B, Cossey V, Van Schoubroeck D, Van Hole C, Devlieger R. Premature foetal closure of the arterial duct: clinical presentations and outcome. *European Heart Journal* 2009; 30:1530-1536.
17. Chebab G, Abdel-Massih T, Smayra T, Saliba Z. Spontaneous regression of coarctation of the aorta in infant, *J Med Liban*. 2014;62(3):168-72.
18. Respondek-Liberska M. Atlas of prenatal heart defects. Selected examples and their clinical significance. Chapter 5. Adi 2011.
19. Paladini D, Russo MG, Vassallo M, Tartaglione A, Pacileo G, Martinelli P, Calabro R. Ultrasound evaluation of aortic valve anatomy in the fetus. *Ultrasound Obstet Gynecol* 2002; 20: 30–34.
20. Tchirikov M, Eisermann K, Rybakowski C, Schroeder HJ. Doppler Ultrasound Evaluation of Ductus Venosus Blood Flow During Acute Hypoxemia in Fetal Lambs. *Ultrasound Obstet Gynecol* 1998;11 (6): 426-431.
21. Joura EA, Zeisler H, Sator MO. Epidemiology and clinical value of true cord knots. *Wien Summary Klin Wochenschr*. 1998; 110: 232-5.
22. Ramon y Cajal CL, Martínez RO. Four-dimensional ultrasonography of a true knot of the umbilical cord. *Am J Obstet Gynecol* 2006; 195: 896-8.
23. Hershkovitz R, Silberstein T, Sheiner E, et al. Risk factors associated with true knots of umbilical cord. *Eur J Obstet Gynecol Reprod Biol* 2001; 98: 36-9.
24. Kobayashi N, Aoki S, Oba MS, Takahashi T, Hirahara F. Effect of umbilical cord entanglement and position on pregnancy outcomes. *Obstetrics and Gynecology International* 2015; 2015:342065.
25. Hadlock FP, Deter RL, Harrist RL. Fetal biparietal diameter: rational choice of plane for sonographic measurement. *Am J of Roentgenol*. 1982; 138:871 – 874.

Division of work:

K. Więckowska: data search and first draft.

K. Zych-Krekora, M. Słodki: discussion, correction of the manuscript
M. Respondek-Liberska: concept of the research, correction of the paper, final version.

Acknowledgement:

The authors declares that there is no conflict of interest regarding the publication of this paper.