

POLISH NATIONAL REGISTRY FOR FETAL CARDIAC MALFORMATIONS (WWW.ORKP.PL) AND NEGATIVE VERIFICATIONS DURING THE 10 YEARS



Authors:
 Maria Respondek-Liberska^{1,2}

1. Department of Prenatal Cardiology, Polish Mother's Memorial Hospital Research Institute 2. Department of Diagnoses and Prevention Fetal Malformations Medical University of Lodz, Poland

PRENAT CARDIO. 2015 DEC;5(4):4-11
 DOI 10.1515/pcard-2015-0001

Abstract

Polish National Registry for Fetal Cardiac Malformations (initiated in 2004) was opened for primary practitioners as well as for the referral centers performing or basic fetal heart evaluation or targeted fetal echocardiography. None of the physicians until current era had regular education of fetal cardiology. It was necessary to create an audit – verification system, which was provided as a checking each record by the 3 most experienced fetal cardiologists in Poland, using randomised computer system.

The aim of this analysis was a retrospective evaluation of „Negatively Verified”

Material and methods: The total number of fetuses in Registry during 2004 and 2013 was 5682 and there were 170 negative verified cases. Every „negative case” was analyzed and qualified to one of five categories: An error in classification of the severity of CHD; computer mistakes, reported other prenatal problems but not CHD, different interpretation of the images (frozen frames or cine loops) and bad order of the labels of cardiac anomalies.

Results: The percentage of negative verifications was similar every year and total number of negative verification was 2,9%. The main reason for negative was first of all improper fetal heart classification in 71 cases (42%). In majority the differences in interpretations were minor: but there were 5 huge differences between primary and secondary interpretation.

Conclusions:

- 1) Fetal heart cardiology requires prenatal heart classification instead of pediatric classification
- 2) Computer mistakes (missing fields, missing diagnoses, lack of frozen frames or cine-loops) should be picked up by the system during up-loading of the cases
- 3) The different interpretation of the images could be used for teaching purpose of fetal cardiology.

Key words: data base, verification, fetal heart defect, classification

Polish National Registry for Fetal Cardiac Malformations was initiated in the year 2004 and has successfully since then evolved^{1,2}.

The main goal of the Registry was to create an organised network of Polish fetal cardiac centers with different expertise evaluated based on an individual input into the Registry³.

The Polish Ultrasound Society started the process of issuing certifications (Basic Level of Fetal Cardiac Examination and Advanced Level), based on data from the Registry and according to the Polish guidelines published in 2006^{4,5}.

This National internet Registry was created for the use of any physician or center willing to share his/her cases and is dedicated to both primary practitioners as well as referral centers performing either basic fetal heart evaluation or targeted fetal echocardiography^{6,7,8,9,10}. None of the physicians, until the current era, received any regular education regarding fetal cardiology, so the experience was gained during postgraduate courses and individual experience.

Within the Registry it was necessary to create an audit – verification system. The audit system was based on the checking of each record by the most experienced fetal cardiologists. Using randomised computer systems, every case was verified

How to cite this article:
 Respondek-Liberska M.
 Polish National Registry for Fetal Cardiac Malformations (www.orkp.pl) and negative verifications during the 10 years.
 Prenat Cardio. 2015 Dec;5(4):4-11

Corresponding author: majkares@uni.lodz.pl

Submitted: 2015-11-16; accepted: 2015-11-25

Year	2004	2005	2006	2007	2008	2009	2010	2011	2012	2013
Nr of records	299	398	362	482	659	663	649	655	690	825
Nr of negative verifications	0	4	7	6	10	32	25	24	25	37

Table 1. Comparison of number of congenital heart defects in years 2004 to 2013 and number of negative verifications

Total	170	100%	69	100%
Unproper classification of fetal CHD	71	42%	9	13%
Computers mistakes	44	26%	24	35%
Other diagnoses not CHD	30	17%	11	16%
Unproper order of labels of CHD	2	1%	2	1%
Different interpretation of images	23	14%	24	35%

Table 2: Five categories of the possible mistakes in relations to the n=170 (total negative verifications) and in relations to the n=69 cases with frozeed frames and/ or cine loops

and forwarded to the „Secondary” Registry (after the verification process).

The aim of this analysis was a retrospective evaluation of „Negatively Verified” cases to see what was the main reason for a different second opinion.

MATERIAL AND METHODS

The number of negatively verified cases between 2004 and 2013 was 170 (Table 1). The total number of fetuses in the Registry during this time was 5682.

Every „negative case” was analyzed and qualified into one of the following categories:

- An error in classification regarding the severity of CHD^o;
- Computer mistakes (no primary diagnosis, missing fields or proper initial diagnosis but false „verification”)
- Other prenatal problems but without CHD; for instance TTTS or hydrothorax but no CHD, premature contractions and normal heart anatomy, functional tricuspid regurgitation and normal heart anatomy, diaphragmatic hernia and normal heart anatomy, cystic hygroma without proven CHD, rhabdomyoma but normal heart anatomy, aberrant left subclavian artery in otherwise normal heart anatomy

- Different interpretation of the images (freezed frames or cine loops)
- Incorrect labeling of cardiac anomalies (for instance primary diagnosis VSD + CoA, and proper order should be CoA

+ VSD, as CoA indicates short term prognosis and VSD long term prognosis).

The data was analysed in two ways:

- 1) according to the total 170 cases with negative verification in the last 10 years and
- 2) according to the total of 69 cases completed with frozeed frames or cine loops (Table 2).

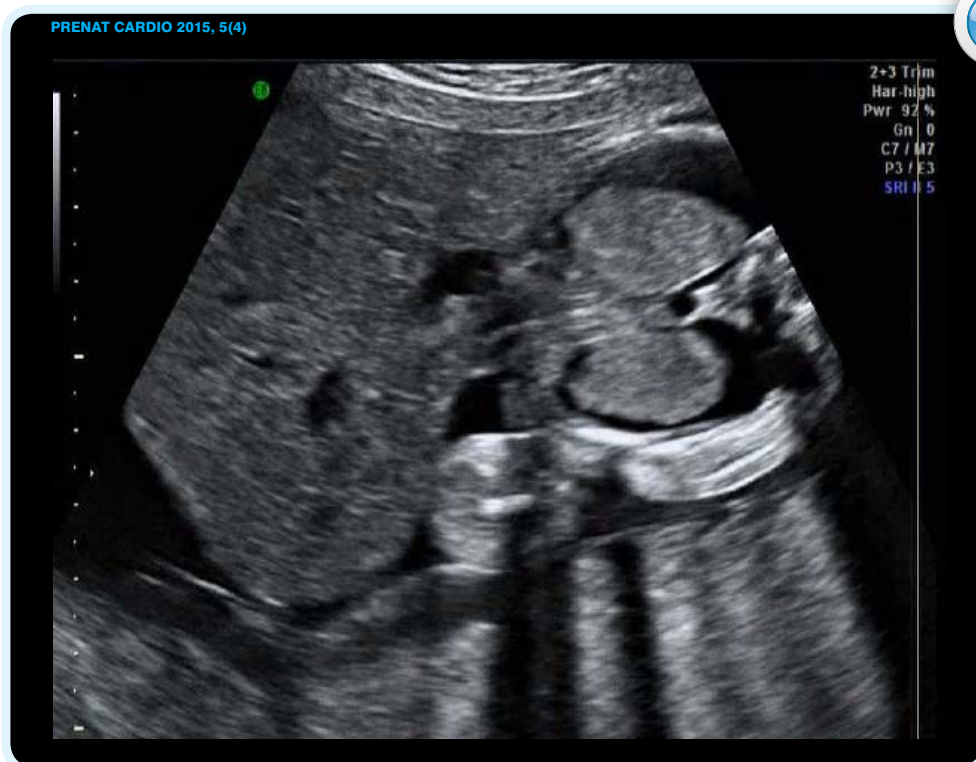The list of improper 24 cases with different image interpretation is presented in Table 3.

RESULTS

The percentage of negative verifications was similar every year and total number of negative verifications was 2,9% (Table 1).

The main reason for negative verification in the whole group was first of all, an improper fetal heart classification in 71 cases (42%).

However taking into account only cases with uploaded images (freezed frames or cine loops) the improper

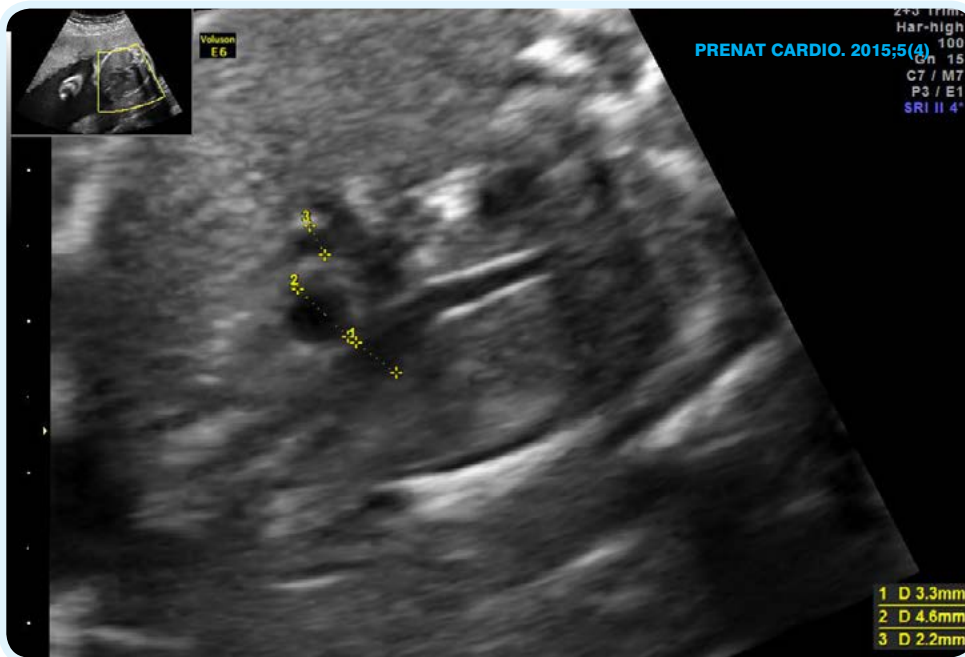


Cine. 1 (Case Nr 18 in Table 3). Opinion 1: Cantrell syndrome and VSD. Opinion 2: nonurgent VSD despite critial fetal condition and expected intrauterine demise. Case presented by IMF center
Play the movie directly in the pdf by clicking on the above picture

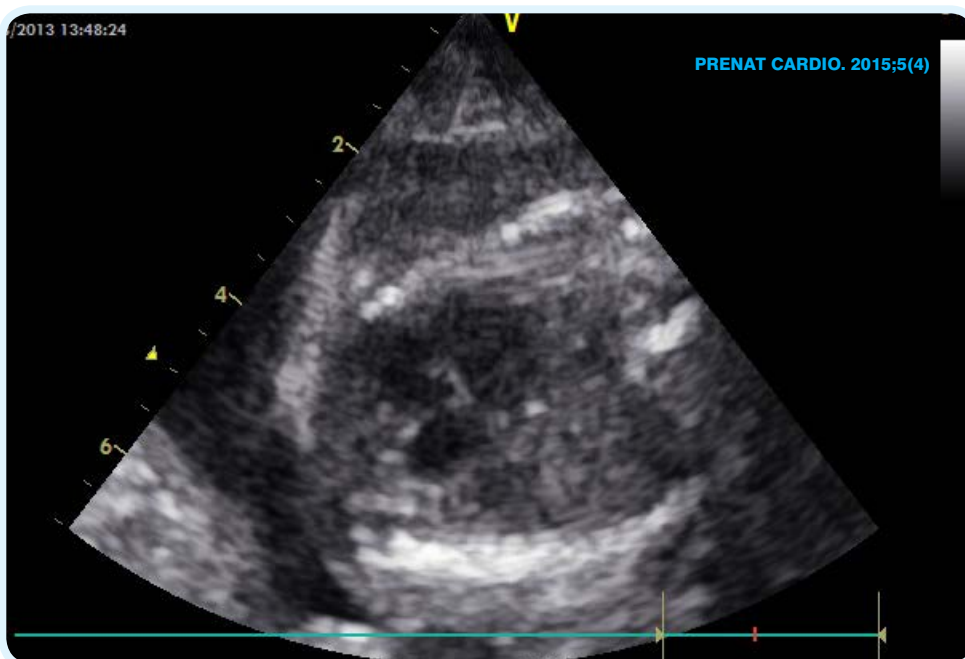
Nr of case	Code of center	Primary dgn	Gest age	Biometry	Classification First opinion	Classification Second opinion	Corrected dgn	Year
1	YBX	DILV, RV hypoplasia, VSD, TGA	24	24	Severe	Severe	DOLV, DILV	2009
2	GFV	Pulmonary Atresia + VSD	24	24	Severe	Severe	Pulmonary stenosis + VSD	2009
3	LMA	DORV + PS			Severe	Severe	DORV + Ao hypoplasia	2009
4	GFX	ASD primum	24	26	Severe	Non-urgent	AVC	2009
5	YBX	RAA	34	34	Non-urgent	Non-urgent ?	RAA + dilatation of SVC	
6	GFV	HLHS + straddling AVvalve	28	28	Critical	Severe	No straddling in HLHS	2010
7	SFH	LV hypoplasia	19	18	Severe	Severe	HLHS + AVC	2011
8	YBX	PAVC	27	23	Severe	Not enough data	?	2011
9	YBX	AVC	27	27	Non-urgent	Non-urgent	Isomerism	2011
10	YBX	AS	35	35	Non-urgent	Non-urgent	NHA	2011
11	KVQ	AVC + Dextrocardia	25	25	Severe	Severe	Isomerism	2012
12	ZAV	CoA + VSD	37	38	Non-urgent	Non-urgent	Only VSD	2012
13	KVQ	LSVC	34	32	Non-urgent	Other anomaly	Bilateral SVC	
14	XVR	TR	18	19	CRITICAL	Severe	Ebstein	2013
15	OUI	Ao overriding VSD	26	26	Severe	Severe	Truncus arteriosus	2013
16	IMF	LSVC to CS	30	28	Non-urgent	Severe	Ao arch hipoplasia + LSVC to CS	2013
17	XVR	CoA	21	21	Severe	Other	NHA or mild PS	2013
18	IMF	Cantrell + VSD	28	28	Critical	Non-urgent	VSD	
19	UIS	AS	32	28	Severe	Other	No CHD or mild AS with poststenotic dilatation	
20	HJK	Truncus + AVC	21	21	Severe	Severe	c-TGA, VSD, Pulm valve imperforate, Ebstein (neonatal echo)	
21	QLP	TOF + AVC	30	29	Severe	Non-urgent	TOF + AVC	
22	HJK	CoA	22	22	Severe	Non-urgent (False 2nd opinion – neonatal sugery of CoA)	CoA	2013
23	GDX	AS	29	29	Nonurgent	Critical	AS critical	2013
24	IJQ	ASD primum	22	22	Nonurgent	Severe	TGA severe	2013

Table 3. Negative verifications in 24 cases with up-loaded images

minor differences n= 9 not enough data to confirm CHD n= 4 HUGE differences n=5 major differences, that might influence counsseling and perinatal management n= 6 cases



Fot. 1 (Case nr 17, Table 3). Opinion 1: CoA Severe. Opinion 2: It is not CoA, maybe mild PS



Fot. 2 (Case nr 4, Table 3). Opinion 1: ASD primum, severe CHD. Opinion 2: Just one single photo of poor quality, probably AVC non-urgent CHD

classification was only in 13% and majority of reasons for a different opinion were due to computer mistakes (for instance missing fields), 35% of different interpretation of images was in 24 cases – 35% (Table 2).

In majority the differences in interpretation (Table 3) were minor: for instance added DOLV to initial diagnosis DILV, or changes pulmonary atresia to pulmonary stenosis, ASD primum to AVC, or instead of LV hypoplasia, HLHS + AVC was a more precise description. But there were 5/24 (21 %) huge differences between primary and secondary interpretation, such as in the case of Ebstein

anomaly which was labelled as critical at 18/19 week of gestation based on only TR without major cardiomegaly (should be labeled as severe at that stage (case 14); or aortic stenosis detected at 29 weeks of gestation and considered non-urgent, despite max velocity of 3 m/sec at 29th week of gestation, baby required emergency valvuloplasty just after delivery (so it was a critical CHD – case 23). There was a peculiar diagnosis of ASD primum (case 24th), however there were several good quality cine-loops showing parallel great vessels not mentioned in the diagnosis.

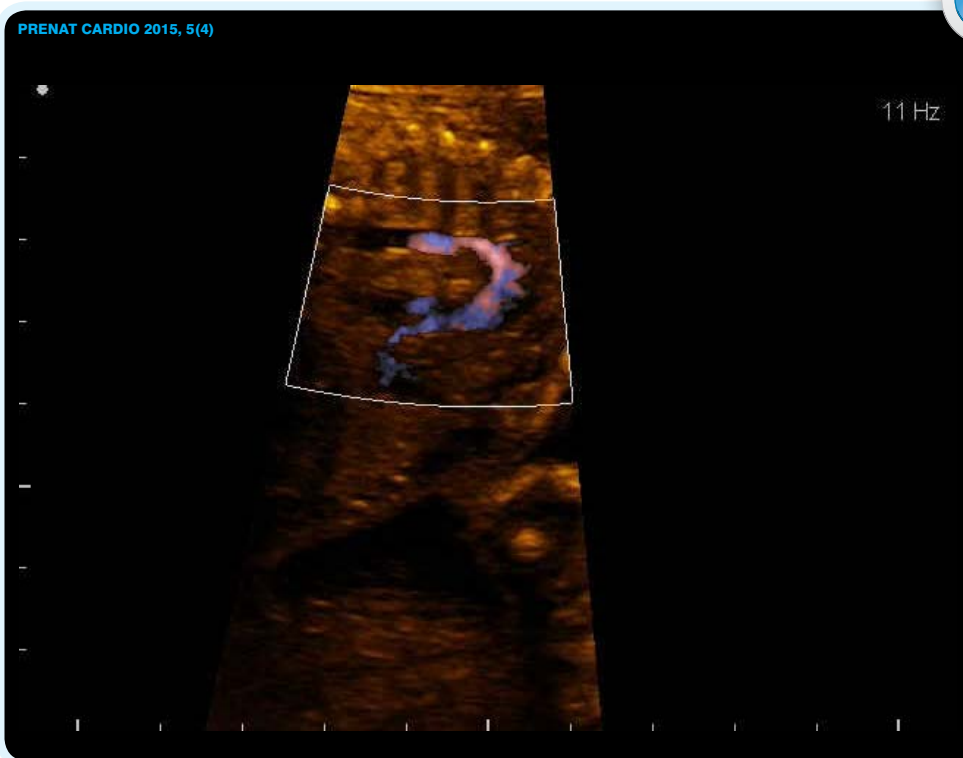
There was an important mistake made by myself in case 22. Based on very good quality of images coarctation of the aorta shown at the level of isthmus at the 22nd week of gestation, with normal 4 chamber view, my guess was: non-urgent CHD and maybe even false positive diagnosis, however I was wrong and the baby underwent coarctation repair in the first week after birth. It was a good example that the differential diagnosis between severe, critical and non-urgent CHD should be postponed until 3rd trimester

DISCUSSION

One of the first registries in perinatology was introduced by Z. Papp¹². The authors implemented and introduced a filing system representing the complexity of obstetric, genetic

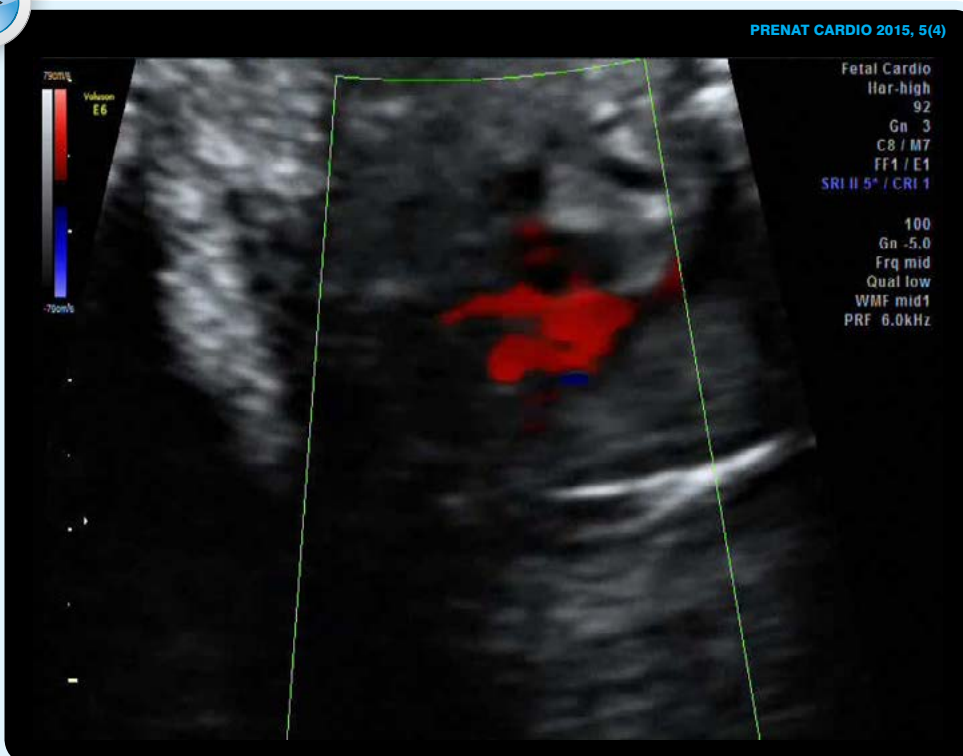
and neonatal care for the three counties of the Eastern part of Hungary. The computer registry was suitable for systematic storage of approximately 500 prenatally diagnosed cases yearly.

Currently, one the biggest registries is Eurocat¹³. This registry for instance, describes the prevalence, associated anomalies, and demographic characteristics of cases of multiple congenital anomalies (MCA) in 19 population-based European registries (EUROCAT) covering 959,446 births in 2004 and 2010.



Cine. 2, Case 22, Table 3. Opinion 1: Coarctation of the aortae as severe heart defect; Opinion 2: nonurgent Coa (the proper opinion was the first1, heart surgery in the first week). A good example that the differential diagnosis between severe, critical and non-urgent CHD should be postponed until 3rd trimester

[Play the movie directly in the pdf by clicking on the above picture](#)



Cine. 3. Case 21, Table 3. Opinion 1: Severe Tetralogy of Fallot Opinion 2: Fallot nonurgent

[Play the movie directly in the pdf by clicking on the above picture](#)

In perinatology, there are a few publications considering different databases, for instance: multi layer maternal and child health¹⁴, rare diseases¹⁵, or fetal urology¹⁶.

Registries are based on multicenter or regional co-operations or medical sub-specialties. Polish National Registry seems to be unique completing patient data for scientific purposes, but on the same token giving feedback for those who participate, in the form of certificates which are recognized by the National Health System in Poland.

However, as any registry, this one also has its limitations. In every major database, one may deal with human, computer or system errors¹⁷.

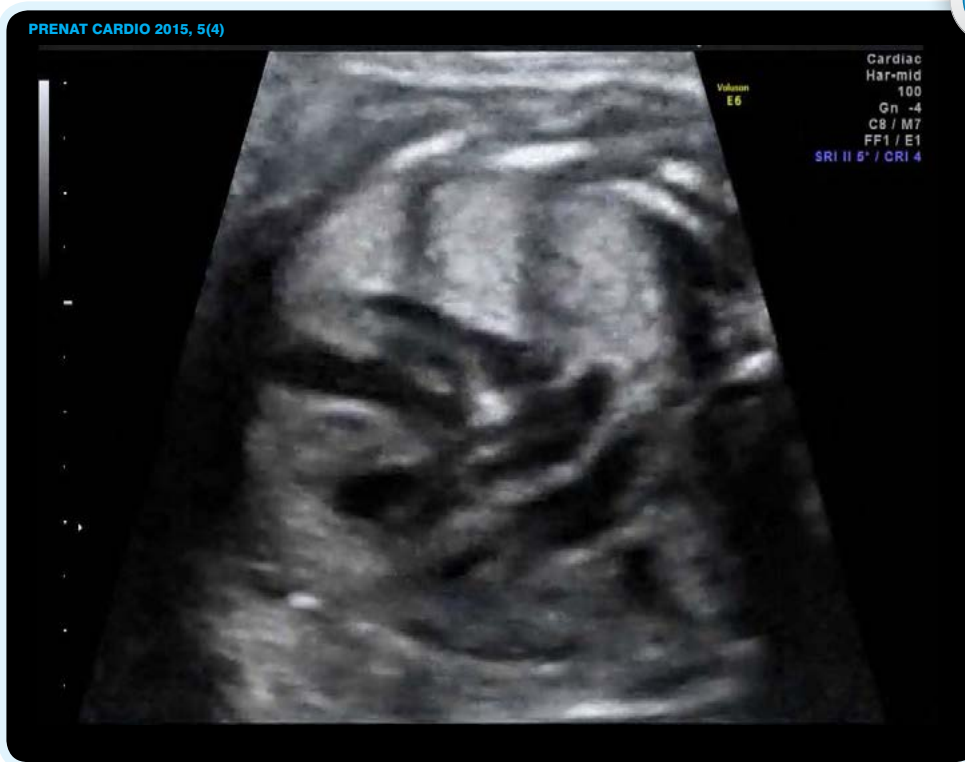The main goal of this research was to check how useful our system of verification was, after 10 years of collecting fetal cardiac cases.

Starting our internet Registry in 2004, originally we wanted to collect different types of data, demographic, reason for referral, the number of ultrasound examinations before the detection of the congenital heart defect, information regarding termination of pregnancy or continuation of pregnancy, intrauterine demise, type of delivery, the follow-up of the most common cardiac defects etc^{9,10,11}.

We realized that in order to maintain good quality of the Registry it was necessary to also add images: frozen frames, cine loops or both. However, as late as in 2009 (in the 6th year running), different centers started in majority to upload the images.

Therefore, analysis of negative verification was performed in two ways: primary, including all negative verifications since 2004 and secondary for those with images since 2009 (Table 1).

Originally, the majority of negative verifications were related to miss- classification regarding the

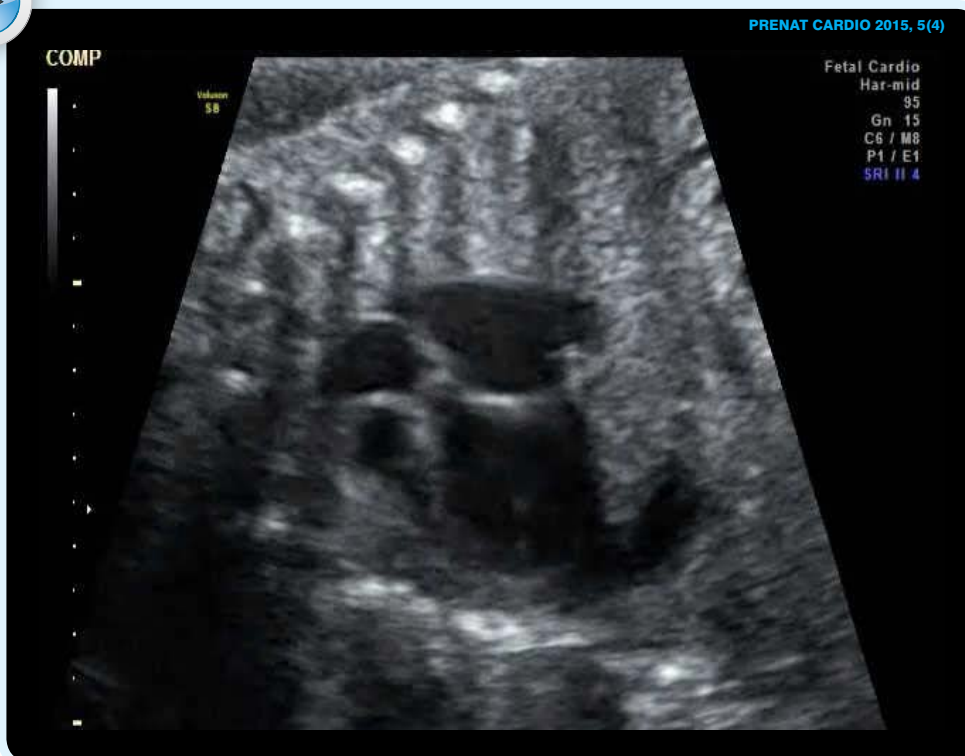

Cine. 4 Case 19, Table 3. Opinion 1 Critical AS Opinion 2: Not confirmed; case presented by UIS

[Play the movie directly in the pdf by clicking on the above picture](#)

the heart classification was critical, which was only partially true. The fetal condition was critical and neonatal demise anticipated however, from prenatal cardiology point of view, VSD is not a heart defect that requires emergency intervention just after delivery.

Or another example of misinterpretation: in a fetus at 20 wks of gestation with AVC and normal heart size and bilateral hydrothorax the primary heart classification was "severe" with congestive heart failure diagnosed. This could imply the possibility of heart surgery in 1st month of postnatal life, however this fetus could have a viral infection with spontaneous regression of hydrothorax or could undergo intrauterine demise and would never be considered for cardiac surgery.



Cine. 5. Case 23, Table 3. Opinion 1: Nonurgent aortic stenosis Opinion2: Critical AS (baloon valvuloplasty on the 2nd day after birth; case presented by GDx

[Play the movie directly in the pdf by clicking on the above picture](#)

As there was in 2004 no specific prenatal heart classification, very often for prenatal purpose the pediatric heart anomalies classification was used. For instance, d-TGA was considered, as always, critical heart defect, meaning neonatal heart defect requiring prostin infusion followed by neonatal heart surgery.

With the progress of knowledge in the field of prenatal cardiology, we realized that d-TGA in the fetus is not uniform and among this group we should be able to distinguish those who, in addition to prostin infusion, would require first of all emergency Rashkind procedure just after birth. So fetal d-TGA may be a critical heart defect or severe heart defect just after delivery⁹.

severity of the defect. Many classified the condition of the fetus instead of type of congenital heart defect (Table 2 – 42%). For instance in case of VSD and Cantrell syndrome

Another example may be given for tetralogy of Fallot. From the point of view of pediatric cardiology, it is always a severe heart defect; however, from prenatal point of

view, tetralogy of Fallot usually does not require cardiac surgery in the first 28 days after birth, so it is not an urgent heart defect.

Having new fetal heart defects classification in recent years^{11,18,19}, the problem in classifying prenatal heart defects was brought to light and accepted by the majority of physicians cooperating with our national Registry (Table 2 : according to the n=69 cases improper classification of CHD was only 13%) .

Therefore, more important became the different interpretation of the uploaded images of fetal cardiac cases (Table 3).

As this was a retrospective analysis dealing with multicenter practitioners, the internet system was uploaded with classical echocardiography images: usually 2D and color Doppler, freezed frames and cine loops. We did not upload volume images, for several reasons: restricted capacity of virtual memory of our system, current limited use for volume images for clinical practice, relatively rare are good quality images due to unfavorable fetal positions during examinations. However, maybe storing 3D cardiac volumes would be available in the nearest future²⁰.

We believe, that the National Registry is an important source of information on such „rare” cases like fetal heart defects. For the average practitioner – obstetrician, it is truly a „rare” problem as they usually encounter 1-to 5 cases per year. Thus, for the average obstetrician it is very difficult to build up clinical experience based on such a small number of cases. For educational purposes and practical point of view, it may be useful to look inside a „live” library of hundreds of fetal heart cases, such as „prenatal heart wikipedia”, which would be our next goal.

So far, based on our current experience and retrospective quality assessment of the Registry we have come to the following conclusions:

- Fetal heart cardiology requires prenatal rather than pediatric heart defects classification as it deals not only with structural anatomy but also with option of perinatal care and the time of cardiac surgery; it should be used first of all during the third trimester of gestation
- Computer mistakes (missing fields, missing diagnoses, lack of freezed frames or cine-loops) should be picked up by the system during the uploading of cases and the operator should receive an immediate alert from the system (technical problem which could be solved with the newest software)
- The different interpretation of the images could be used for teaching purposes in the field of fetal cardiology

ACKNOWLEDGEMENT

The author would like to thank prof. Joanna Dangel and prof. A. Wloch for their input into the Registry and work in the verification process.

Special acknowledgement also for our administrator Z. Tobota MD, working for the last couple years with the Registry pro publico bono.

References

1. Respondek-Liberska M., Szymkiewicz-Dangel J, Tobota Z, Stodki M.: Purpose and preliminary conclusions from The National Registry of Fetal Cardiac Pathology in Poland (www.orpkp.pl) *Polski Przegląd Kardiologiczny* 2008, 10, 19-23
2. Stodki M, Szymkiewicz-Dangel J, Tobota Z, Seligman NS, Weiner S, Respondek-Liberska M.: The Polish National Registry for Fetal Cardiac Pathology: organization, diagnoses, management, educational aspects and telemedicine endeavors. *Prenatal Diagnosis* 2012 ;32:456-60
3. Stodki M, Dangel J and Respondek-Liberska M.:The National Registry of Fetal Cardiac Pathology in Poland (www.orpkp.pl) is the core of a novel national system to assess the competence of ultrasonographers in fetal echocardiography. *Ultrasound Obstet Gynecol* 2011; 37 : 739 – 742
4. Respondek-Liberska M, Dangel J, Wloch A.: Certificate of competence in screening of fetal heart. *Fetal Echocardiography And Cardiology Section of Polish Ultrasound Society & Polish Gynecological Society. Ultrasonografia* 2006, 25, 83-86
5. Respondek-Liberska M, Dangel J, Wloch A. Certificate of competence in echocardiography of fetal heart. *Fetal Echocardiography And Cardiology Section of Polish Ultrasound Society. Ultrasonografia* 2006, 25, 87-90
6. Stodki M and Respondek-Liberska M.: Proposal of screening fetal heart examination form granted by Polish Ministry of Health Program Kardio-Prenatal 2008; *Ginekol Pol.* 2009, 80, 466-470
7. Wood D, Respondek-Liberska M, Puerto B, Weiner S; Perinatal echocardiography: protocols for evaluating the fetal and neonatal heart. *World Association of Perinatal Medicine Ultrasonography Working Group. J Perinat Med.* 2009;37:5-11
8. Respondek-Liberska M and Janiak K.: Fetal echocardiography protocol for reference centers. *Polski Przegląd Kardiologiczny* 2010;12(3):212-218
9. Kordjalik P, Radzyńska-Chruściel B, Stodki M, Wloch A, Szymkiewicz-Dangel J, Respondek-Liberska M, Tobota Z. The Polish National Registry for Fetal Cardiac Pathology (www.orpkp.pl) - selected data analysis for 2013 and 2014 and comparison with data from 2004 to 2012. *Prenat Cardio* 2015, 1, 6-12
10. Kordjalik Paulina, Maria Respondek-Liberska. HLHS on the basis of a Nationwide Registry of Fetal Cardiac Pathology www.orpkp.pl. *Prenat Cardio.* 2013;3:18-21.
11. Stodki M, Respondek-Liberska M. Comment on „Outcomes of critical congenital heart disease requiring emergent neonatal cardiac intervention”: a new classification of congenital heart disease. *Prenat Diagn.* 2015;35:620-1
12. Papp Z, Süveges D, Szabó G, Kámán A, Papp C, Tóth-Pál E, Takács L. [A computerized follow up system of obstetric and genetic care]. *Orv Hetil.* 1990;131:803-6.
13. Calzolari E1, Barisic I, Loane M, Morris J, Wellesley D, Dolk H, Addor MC, Arriola L, Bianchi F, Neville AJ, Budd JL, Klungsoyr K, Khoshnood B, McDonnell B, Nelen V, Queisser-Luft A, Rankin J, Rissmann A, Rounding C, Tucker D, Verellen-Dumoulin C, de Walle H, Garne E. Epidemiology of multiple congenital anomalies in Europe: a EUROCAT population-based registry study. *Birth Defects Res A Clin Mol Teratol.* 2014;100:270-6
14. Salemi JL, Tanner JP, Bailey M, Mbah AK, Salihu HM. Creation and evaluation of a multi-layered maternal and child health database for comparative effectiveness research. *J Registry Manag.* 2013;40:14-28
15. Messiaen C1, Le Mignot L, Rath A, Richard JB, Dufour E, Ben Said M, Jais JP, Verloes A, Le Merrer M, Bodemer C, Baujat G, Gerard-Blanluet M, Bourdon-Lanoy E, Salomon R, Ayme S, Landais P. CEMARA: a Web dynamic application within a N-tier architecture for rare diseases. *Stud Health Technol Inform.* 2008;136:51-6.
16. Chaviano AH, Maizels M, Yerkes EB, Cheng EY, Hagerty J, Meyer T, Kaplan WE. Incidence based fetal urological counseling using the virtual pediatric urology registry: importance of insignificant fetal pyelectasis (sonographically evident renal pelvis). *J Urol.* 2007;178:1781-5

17. Jahn A, Berle P. [Quality of prenatal data in the Hessian Perinatal Registry. A comparison with data from maternal health record and results of a pregnancy survey]. *Geburtshilfe Frauenheilkd.* 1996;56:132-8

18. Donofrio MT, Moon-Grady AJ, Hornberger LK, Copel JA, Sklansky MS, Abuhamad A, Cuneo BF, Huhta JC, Jonas RA, Krishnan A, Lacey S, Lee W, Michelfelder EC Sr, Rempel GR, Silverman NH, Spray TL, Strasburger JF, Tworetzky W, Rychik J; American Heart Association Adults With Congenital Heart Disease Joint Committee of the Council on Cardiovascular Disease in the Young and Council on Clinical Cardiology, Council on Cardiovascular Surgery and Anesthesia, and Council on Cardiovascular and Stroke Nursing. *Diagnosis and treatment of fetal cardiac disease: a scientific statement from the American Heart Association. Circulation.* 2014;129:2183-242

19. Pruetz JD, Carroll C, Trento LU, Chang RK, Detterich J, Miller DA, Sklansky M. *Outcomes of critical congenital heart disease requiring emergent neonatal cardiac intervention. Prenat Diagn.* 2014;34:1127-32

20. Yeo L, Romero R. *Fetal Intelligent Navigation Echocardiography (FINE): a novel method for rapid, simple, and automatic examination of the fetal heart. Ultrasound Obstet Gynecol.* 2013;42:268-84

Conflict of interest: The author declares no conflict of interest

Author does not report any financial or personal links with other persons or organizations, which might affect negatively the content of this publication and/or claim authorship rights to this publication



Comment - Prof. Zoltán Papp

Maternity Department of Obstetrics and Gynecology, Budapest, Hungary

This paper of Maria Respondek about the Polish National Registry for Fetal Cardiac Malformation and Negative Verification is a unique one in the literature. The main reason of this is that the Internet Registry was created for any physicians and practitioners who perform basic cardiac scan or detailed fetal echocardiography as well- independently of their experiences. Their Verification Process System –checking each record by the most experienced fetal cardiologist- is a great challenge because of very different quality of the records. (It should be interesting to know and present the mean gestational maternal age when fetal scan was performed.) Their retrospective analyzing methods of the negatively verified cases showed that the main reason was an unproper fetal heart classification (42%). This demonstrates the difficulties of heart classification in fetal versus neonatal group. The main conclusion of authors is very important, namely that using The National Registry and creating an audit-verification system could be used for teaching purpose as well. The other very important point is that using the verification process it is possible to receive correct diagnosis of congenital heart disease which is inevitable for the parent decision making of termination or continuation of pregnancies.

Corresponding author: info@maternity.hu

An answer from M. Respondek-Liberska:

I would like to thank Prof. Z. Papp for his kind comment.

The data of mean gestational maternal age in our Registry will be presented in the next issue of *Prenatal Cardiology* by P. Kordjalik