

● Reply to correspondence

REPLY TO COMMENTS FROM DR. JOANNA SZYMKIEWICZ-DANGEL AND HER COLLEAGUES



Maciej Słodki, Maria Respondek-Liberska on behalf of all of the authors

Department of Prenatal Cardiology, Polish Mother's Memorial Hospital Research Institute

PRENAT CARDIO. 2015 DEC;5(4):40-42  
DOI 10.1515/pcard-2015-0007

**Description:**

Recommendation discussion in singleton pregnancy

**Key words:** prenatal echocardiography, recommendations

We would like to thank Dr. Joanna Szymkiewicz-Dangel and her co-workers for their careful reading of and detailed comments on our recent article, entitled "Recommendations for fetal echocardiography in singleton pregnancy in 2015", published in Prenatal Cardiology (2015; 2 (17): 28-34).

Although some of their comments and concerns appear to be directed specifically to the first author of the article, our prepared responses represent the collective input of other authors of our Recommendations. Also, while there are clear differences of opinions, we believe these will foster more thoughtful and collegial discourse and will promote targeted and collaborative research to achieve improved evidence-based recommendations and guidelines for fetal echocardiography in singleton pregnancies.

We agree that we made an error in the Abstract by referring to the four-group classification as the Polish classification of fetal cardiac defects. This classification is from Poland and is used in the Department of Prenatal Cardiology, at the Polish Mother's Memorial Hospital Research Institute, in Łódź. However, we stress that our classification is very similar to that used in the USA by Pruez and Donofrio, and is very well accepted by our

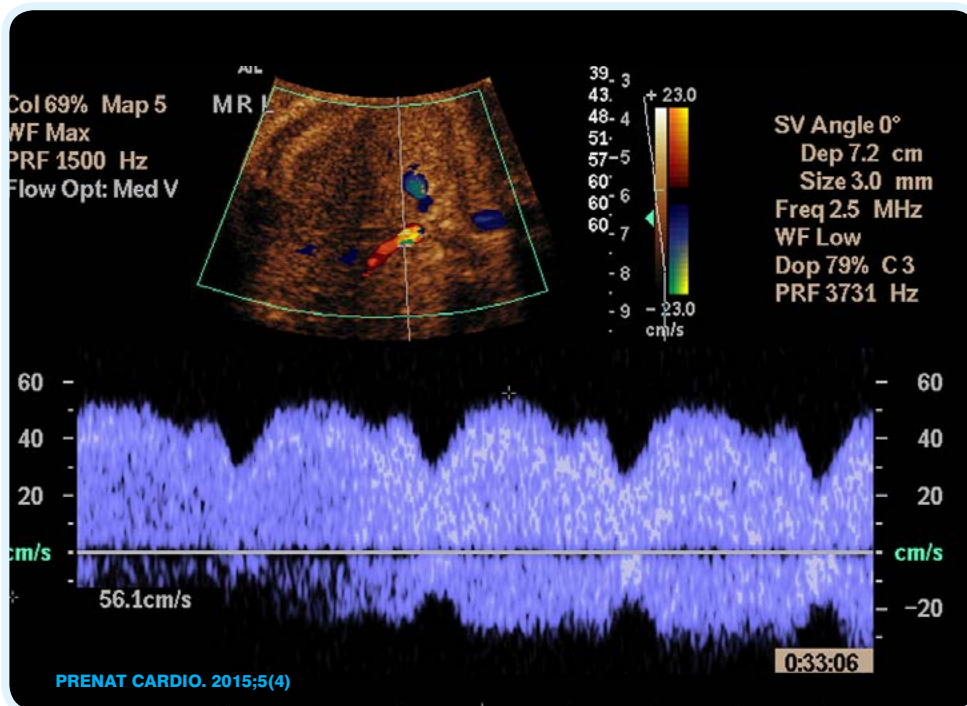


Fig. 1 Normal two-phasic ductus venosus flow

colleagues in different parts of Poland, as well as by the National Database for Fetal Cardiac Anomalies (manuscript in this issue).

As stated, our recommendations are aimed at guiding experienced fetal cardiologists and practitioners at tertiary centers in prenatal diagnosis and parental counseling of congenital cardiac defects. Importantly, the article represents a multi-national best-practices position paper and is not limited to the practices and guidelines of a single institution in Poland or elsewhere.

Also, contrary to the opinion of the letter's authors, the first author, Dr. M. Respondek-Liberska, is a Professor of

Corresponding author: maciejslodki@op.pl

Submitted: 2015-12-20; accepted: 2015-12-21

pediatrics, with a “Belweder” title from the President of Poland more than 14 years ago, based on her publications in fetal cardiology. Moreover, she has been engaged in fetal cardiology for her entire professional life, and currently has nine doctoral fellows.

1. We wrote that DV pulsatility should be biphasic, but Dr. Szymkiewicz-Dangel prefers to call it triphasic.

In the nr 1 image in this letter, a normal DV biphasic flow is shown.

2. We also wrote, “The heart should then be imaged to show its location within the central left thorax above the stomach. This insures normal situs”. It also help to focus on the position of the aorta and IVC (Fig.2)

According to Dr. Szymkiewicz-Dangel and colleagues, “situs describes atrias and visceras”.

Our first step in the fetal heart exam is to always start from the fetus position, next to find the stomach position and visceral organs and comparing with the apex position. At the Polish Mother’s Memorial Hospital in Łódź, Poland, we start our fetal echocardiography results with the statement, for instance: Fetal cephalic position, type I, Situs solitus (stomach on the left) and levocardia (apex on the left)

3. In performing fetal echocardiography for heart defects, we always have to use a segmental approach. Otherwise, we would not be capable of describing complex heart defects with problems at the atrial level, ventricular level, ventriculoarterial connections, etc.

4. According to the opinion of Dr. Szymkiewicz-Dangel and colleagues, we did not clearly state what to look for and how to look at it. A re-reading of the text might resolve this issue.

5. We stated that in cases of potential heart failure, additional detailed Doppler evaluation (such as cardiovascular profile score, tissue Doppler or 3D/4D fetal cardiac imaging) might be indicated. But Dr. Szymkiewicz-Dangel and colleagues contend that the “usefulness of 3D/4D for fetuses with heart failure is rather little”. We believe our future manuscripts, now in preparation, regarding left ventricle aneurysm, right atrium aneurysm or interventricular septum aneurysm, along with heart failure, would convince the Warsaw group that in complicated fetal cases all fetal echocardiographic modalities would be very useful

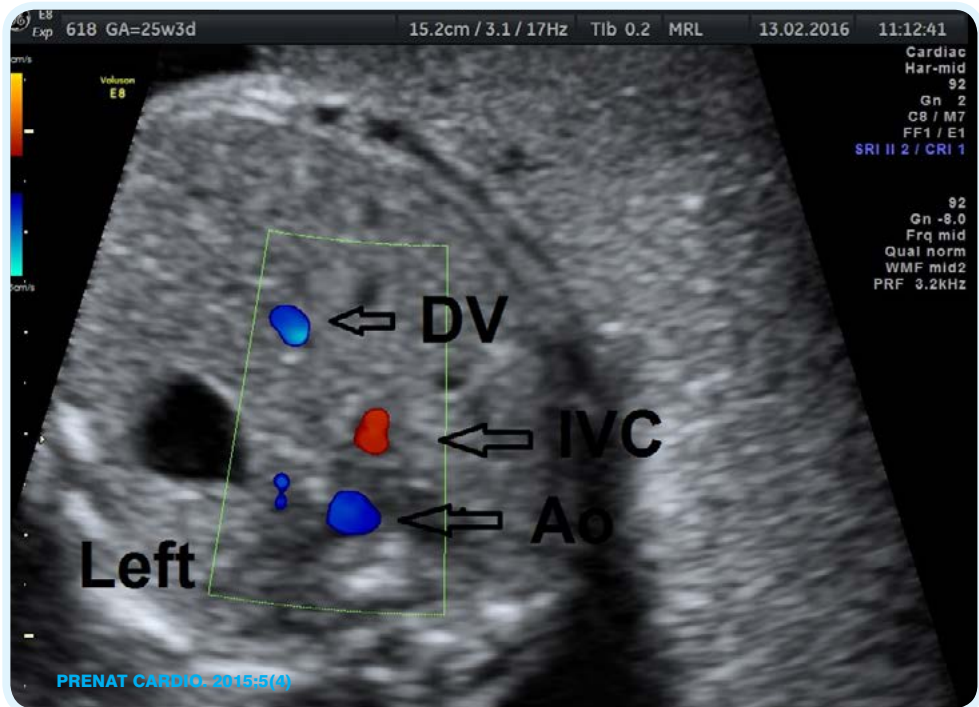


Fig.2. To start fetal echo one needs to check fetal position and laterality of his internal organs: here stomach on the left, aorta descending on the left...situs solitus

6. Close serial monitoring should be performed for certain cases, optimally starting at 4-week intervals, through 3-, 2-week intervals up to the time of delivery in order to identify those fetuses at risk for restriction at the foramen ovale and/or constriction of the ductus.

In the present article, our recommendations did not touch on arrhythmias. In a future article, our recommendations will be shared with our readers on how to assess fetal heart arrhythmias as well as the causes of arrhythmias because pediatric cardiology does not cover specific prenatal situations connected with such fetal abnormalities.

Our recommendation also do not concern fetal echocardiogram in first trimester. We do not state that it is not important but we wanted to focus on, in our opinion more important part of prenatal care on CHD fetuses, the third trimester fetal echocardiograms. Dr. Szymkiewicz-Dangel and colleagues list the types of fetal cardiac interventions available in Warsaw. Curiously, however, no mention is made about the patients we previously referred to the Warsaw center for fetal balloon valvuloplasty and their follow up. By contrast, during the past five years, every one of the 4 to 5 cases per year referred to our center for neonatal valvuloplasty following delivery was discharged in excellent clinical condition. That is, there have been no neonatal deaths following balloon valvuloplasty at our center in Łódź.

Based on the Warsaw experience, Dr. Szymkiewicz-Dangel and colleagues claim that a dedicated special delivery room is not necessary. And all that is required is an organized team of experienced neonatologists to attend the delivery of neonates with critical cardiac lesions. We and some international expert do not agree

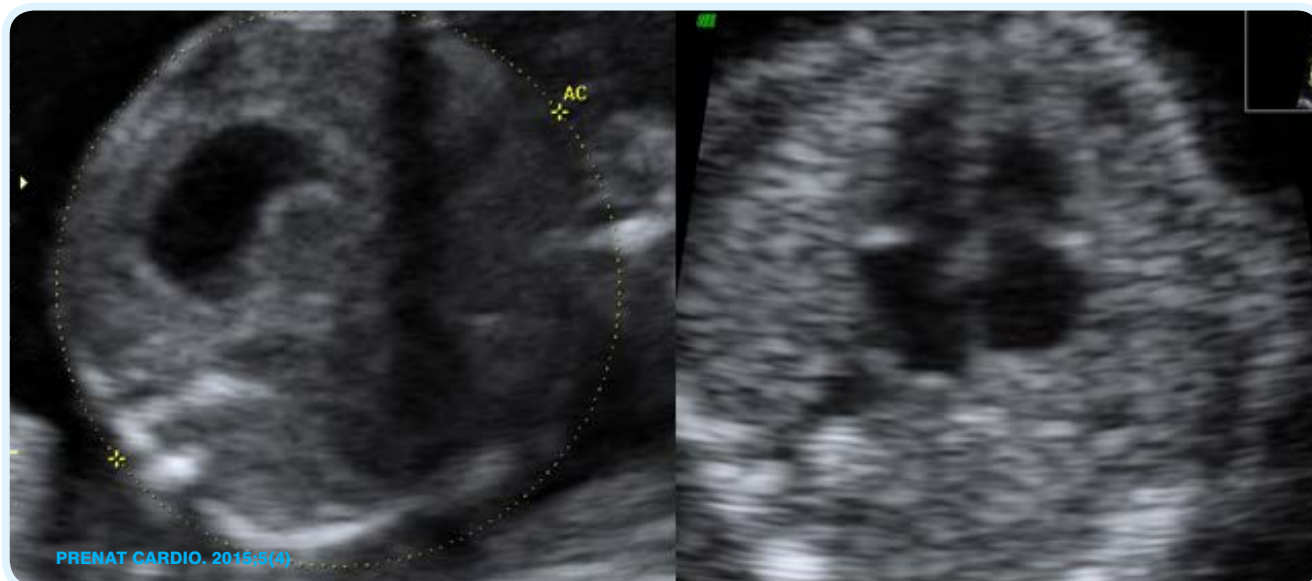

Fig.3. Fetal heart apex on the same side as stomach: meaning in this case levocardia and normal heart size. Next step is to evaluate fetal heart anatomy

that a dedicated special delivery room is unnecessary. Our state of art article with international cooperation are now in press in one of the Thomson Reuters journal.

On the other hand, we completely agree with their statement, “The aim for fetal cardiology is to diagnose CRITICAL HEART DEFECTS which are SILENT clinically” but our definition of Critical Heart Defects is different than definition of pediatric cardiologist and dr Szymkiewicz-Dangel. Our opinion is based on developing of fetal cardiology and we state that time to changes has come. For the past 30 years when lecturing on fetal cardiology, the first author has always shown a perfect “healthy” newborn during delivery – without any cardiac signs – despite having HLHS. Our new point of view is presented in our article in press mentioned earlier.

A final point is about who is a fetal cardiologist. In our collective opinion, we agreed that “only well-trained or experienced pediatric cardiologists, maternal-fetal medicine specialists, obstetrician or radiologists, who have acquired the appropriate knowledge base and skills, should supervise and perform fetal echocardiography. Beside fetal echocardiograms, prenatal cardiologists can also predict neonatal management and qualify CHD to appropriate groups of one of the new CHD classification.

Dr. Szymkiewicz-Dangel and co-workers state: A fetal echocardiographer can perform fetal echo, however they are not prepared for full prenatal cardiac counseling. But does this mean that the pediatric cardiologist is trained and adequately prepared to counsel a pregnant woman about when and how she should deliver a baby with HLHS? Or how she should be prepared for vaginal delivery or cesarean section? Or should she receive steroids at 32 weeks of gestation? Or what to do in the event of premature contractions? Or what to do in the case of hypertension and preeclampsia? Are these tasks for the pediatric cardiologist? Or are these tasks for the obstetrician? Or perhaps tasks for a dedicated fetal heart team within a special delivery cardio-obstetrical center?

AEPC is a pediatric cardiology society dealing with fetal heart defects. In the main journal of this society, “The Cardiology in the Young”, the number of papers during the first half of 2015 was 218, of which less than 5% was dedicated to fetal cardiology. We believe this is because currently in pediatric cardiology, invasive cardiology and neonatal cardiac surgery there is so much new data that pediatric cardiologists nowadays have only very limited exposure to the problems of fetal cardiology.

The first author of the article, who trained in pediatric and fetal cardiology at the Children’s Hospital of Philadelphia, has personally performed or supervised more than 30,000 fetal echocardiograms. And in 2004, she and Dr. Szymkiewicz-Dangel started the National Polish Registry of Fetal Cardiac Anomalies. Results from this registry have been presented in Europe, USA, India and Poland. Continued collaboration and partnership across Poland and beyond will lead to further refinements in the recommendations for fetal echocardiography in singleton pregnancies, and to improved outcomes for mothers, babies and their families.

**Additional sentence from Dennis Wood from Philadelphia:**

*Different places work differently. We discuss every in utero patient in conference both at Jefferson and at duPont and these patients are published on the duPont Numours fetal list monthly. All parents are counseled multiple times by the obstetrician, the MFM, by the pediatric cardiologist and all meet the cardiac surgeon before delivery. Second opinions are always offered. We have 3 children's hospitals in Philadelphia. CHOP wants all cases referred after 30 weeks to them for possible delivery at CHOP. DuPont and St. Christopher's will have delivery of ductal dependent lesions delivery at a tertiary care center and then transferred after stability to their hospital. Many of the best known practitioners of perinatal cardiology are indeed Maternal Fetal Medicine physicians, ie. DeVore, Copel, Abuhammed.*