

Eotaxin (CCL11), TARC [thymus and activation-regulated chemokine (CCL17)], MCP-1 (CCL2) and CCR-1, CXCR-1, CXCR-2 expression in dermatitis herpetiformis and bullous pemphigoid

Agnieszka Żebrowska¹, Anna Erkiert-Polguj², Małgorzata Wągrowaska-Danilewicz³, Marian Danilewicz³, Rafał Pawliczak⁴, Anna Sysa-Jędrzejowska¹, Elżbieta Waszczykowska²

¹Department of Dermatology and Venereology, Medical University of Lodz, Poland

²Laboratory of Immunodermatology, Department of Dermatology and Venereology, Medical University of Lodz, Poland

³Department of Nephropathology of Medical University of Lodz, Poland

⁴Department of Immunopathology, Faculty of Biomedical Sciences and Postgraduate Training, Medical University of Lodz, Poland

Submitted: 13 November 2008

Accepted: 3 February 2009

Arch Med Sci 2009; 5, 3: 475-485

Copyright © 2009 Termedia & Banach

Corresponding author:

Dr Agnieszka Żebrowska,
MD, PhD

Department of Dermatology
and Venereology

Medical University of Lodz
5 Krzemieniecka St.

94-017 Lodz, Poland

Phone/fax: +48 42 686 45 65

E-mail: zebrowskaaga@wp.pl

Abstract

Introduction: Bullous pemphigoid (BP) and dermatitis herpetiformis (DH) are skin diseases associated with eosinophilic and neutrophilic infiltrations. Although chemokines are critical for the selective attraction and activation of various leukocyte subsets in the inflammatory process, there are few findings concerning the link between chemokines and their receptors and pathogenesis of autoimmune blistering disease.

Material and methods: Skin biopsies were taken from 10 patients with DH, 14 with BP and from 10 healthy subjects. The localization and expression of eotaxin, TARC, MCP-1, CCR-1, CXCR-1 and CXCR-2 in skin lesions and perilesional skin were examined by immunohistochemistry. In addition, the serum concentration of selected cytokines was measured by immunoassays method.

Results: Expression of eotaxin and TARC was detected in skin biopsies from BP and DH patients both in the epidermis and in inflammatory influx cells of dermis. Expression of MCP-1 was observed in the same areas, however exclusively in specimens for BP patients. Chemokines expression was detected in both perilesional and lesional skin areas but it was much lower in the former one. CCR-1, CXCR-1 and CXCR-2 expression was confirmed in lesional as well as perilesional skin. The expression of the examined chemokines and their receptors was not observed in biopsies from healthy people.

Conclusions: Our research leads to the assumption that chemokines may play a role in the activating and recruiting eosinophils and neutrophils and suggest that difference in chemokine expression pattern may contribute to variations of the cellular infiltration and tissue damage in DH and BP patients.

Key words: chemokines, chemokine receptors, pemphigoid, dermatitis herpetiformis.

Introduction

Dermatitis herpetiformis (DH) is one of the subepidermal autoimmune bullous diseases (ABD) characterized by polymorphic skin lesions include accompanied by severe pruritus [1]. Diagnosis of DH is established on the results of direct immunofluorescence test (DIF) revealing of IgA granular

deposits in the papillae and the presence of IgA circulating antibodies against endomysium and/or tissue and epidermal transglutaminase (tTG, eTG) [2, 3]. Skin lesions in DH are histologically characterized by neutrophilic infiltration leading to destruction of basement membrane zone (BMZ), anchoring fibers and to blister formation [4-6].

Bullous pemphigoid (BP) is a blistering disease, characterized by inflammatory infiltrate on the dermis, presence of IgG and C3 deposits along the basement membrane zone and circulating IgG autoantibodies. Autoantibodies binding to autoantigens (glycoproteins: 230 kD – BPAG1 and 180 kD – BPAG2) localized in the basement membrane of the epidermis activate a series of immunological and enzymatic phenomena leading to destruction of basement membrane components and anchoring fibers and to blister formation as in DH [7, 8].

Ultrastructural studies confirmed also the presence of intensive inflammatory infiltration at dermo-epidermal junction, as well as destruction of hemidesmosomes and components of extracellular matrix [9].

Formation of influx is preceded by early accumulation of leukocytes, depending on activity of adhesion molecules. The complex of autoantibodies and antigens triggers activation of keratinocytes which release interleukin 6 and interleukin 8. It also activates C5 component of the complement and metalloproteinases – the enzymes produced by eosinophiles and neutrophiles attracted to the basement membrane by selectins and integrins and chemokines [10, 11]. Chemokines are important chemoattractants for both eosinophiles and neutrophiles and take part in many processes through their receptors. Some of them are highly specific whereas others may interact with more than one ligand [12, 13].

Only a few studies available suggested the chemokines' role in generating the inflammatory influx in autoimmune blistering diseases. Eotaxin (CCL11) is a chemoattractant for eosinophils, predominant in the skin lesions in BP [14]. Receptors for the other chemokine – TARC (thymus and activation-regulated chemokine/CCL17) are located e.g. on neutrophiles, which are the are main influx cells in skin lesions in DH [15]. MCP-1 (monocyte chemoattractant protein-1, CCL-2) is vital for monocytes, lymphocytes and basophiles function [16]. For our research we have chosen the following chemokines' receptors: CCR-1 receptor for RANTES (CCL5/RANTES – regulated upon activation normal T lymphocyte expressed and secreted) [17], CXCR-1 and CXCR-2 – receptors for IL-8 [18]. There are literature data confirming contribution of RANTES and IL-8 in pathogenesis BP and DH [11, 16, 18]. That is why we haven't focused on it in our studies.

The goal of this study was to assess aforementioned chemokines and chemokines receptors expression in skin lesions and perilesional area in patients with BP and DH. The recruitment and activation of leukocytes in the skin lesions are thought to be a critical stage in the pathogenesis of BP and DH diseases. As chemokines are specific and potent leukocyte chemoattractants, they make good candidates to be the molecular regulators responsible for attracting the specific immune autoantigen and for activating leukocyte influx in the skin.

Material and methods

Patients

Twenty four patients with newly diagnosed disease were included in the study (10 with DH and 14 with BP). Ten untreated patients with DH (5 women, 5 men average 44.8 years; ranging: 18-58 years) were in an active stage of the disease. Eight out of 10 patients had skin lesions characterized by vesicles and itching papules, the others had erythematous papules. In all cases histological pictures showed perivascular neutrophilic infiltration, presence of Pierrard's abscesses, and in all patients small subepidermal blisters. In 8 out of 10 samples large unilocular blisters displaying multiple neutrophilic papillary microabscesses were found. The histopathologic findings in all cases were fully in accordance with Ackerman criteria as unilocular blisters along with influx and small vesicles were founded [19]. Direct immunofluorescence tests revealed the presence of granular deposits of IgA in skin papillae and indirect immunofluorescence test were positive for IgAEmA (Oesophagus monkey IgAEmA, Medizinische Labordiagnostica) in all the patients (titer 1 : 10 – 1 : 320, average 1 : 40). Anti-tissue transglutaminase antibodies measured using an immunoassay (Celikey, Pharmacia & Upjohn) were present in 6 out of 10 cases (average 4.3 IU/ml (range: 0.0-156.3 IU/ml). Diagnosis of DH was established based on both the clinical presentation and results of histological and immunological examination.

Fourteen untreated patients (6 women, 8 men, average 68,5 years, ranging: 58-84) with BP entered the study. Pemphigoid was diagnosed based on clinical picture, and histological and immunological findings [7]. The patients were at an active stage of the disease. In 12 out of 14 patients skin blisters, vesicles and itching papules were observed, whereas the others had only small vesicles and urticarial papules. Typical histological features of BP, including neutrophilic infiltration, eosinophiles, lymphocytes and in 12 cases – subepidermal blisters supported the

clinical diagnosis. In all the patients direct immunofluorescence test revealed IgG/C3 linear deposits along BMZ. In the salt split test, deposits were observed in epidermal part of the blister. Using the indirect immunofluorescence test, circulating IgG antibodies were found in all 14/14 patients however ELISA test showed the anti-NC16 a autoantibodies (MBL, Nagoya, Japan) present in the serum in 12 out of 14 patients.

The control group consisted of 10 healthy persons (5 women and 5 men, age range between 19 and 49 years, average: 42 years). These subjects were carefully matched both patient groups as far as the age and sex.

All the patients were fully informed before signing a prior to entering the study and the study protocol (RNN/132/07/KB) was approved by The Local Ethical Committee of the Medical University of Lodz.

Tissue specimens

The biopsies were taken from the buttock or trunk skin before administration of any (topical or systemic) treatment. The skin lesions had been developing for a period ranking from 2 weeks to 3 months. The biopsy specimens were taken from buttock skin of the healthy volunteers too.

Immunohistochemistry

Paraffin-embedded sections (3-4 μm thick) were used for routine H+E staining and for immunohistochemistry with DAKO EnVision detection system using immunoperoxidase method. The following primary monoclonal antibodies were used: anti-eotaxin (clone 43911), TARC (clone 124302), MCP-1 (clone 23002), CCR-1 (clone 53504), CXCR-1 (clone 42705) and CXCR-2 (clone 48311); all of them obtained from R&D, United Kingdom.

For immunohistochemistry, the paraffin-embedded sections were placed on adhesive plates and dried at 56°C for 24 h, later deparaffinated in a series of xylenes and alcohols with decreasing concentrations (96, 80, 70, 60%). Activity of endogenous peroxidase was inhibited with 3% hydrogen peroxide solution in methanol for 5 min.

In order to retrieve the antigenicity of tissues and allow them to react with antibodies, specific procedures were used for each of the tested antibody, according to the manufacturer's instructions. After incubation with diluted antibodies for 60 min at room temperature, they were washed with TRIS buffer twice. DAKO EnVision double-step visualization system was then applied in order to visualize the antigen-antibody reaction. In cases of positive immunohistochemical reaction cellular nuclei were stained with Meyer haematoxylin for 2 min. After dehydration and processing through series of

acetones and xylenes the sections were fixed in Canadian balm.

Semiquantitative analysis

In each specimen staining intensity of eotaxin, in the epidermis and inflammatory infiltrations and CCR-1, CXCR-1 as well as CXCR-2 in inflammatory infiltrations were recorded by two independent observers in 7-10 adjacent high power fields and graded on the scale from 0 (staining not detectable) through 1 (minimal immunostaining in some cells) and 2 (weak immunostaining intensity in all cells) to 3 (strong staining in all cells). The mean grade was calculated by averaging grades assigned by the two authors and approximating the arithmetical mean to the nearest unity.

Morphometry

Histological morphometry of the immun-expression of TARC, in epidermal and inflammatory cells and MCP-1 in inflammatory cells only was performed by using an image analysis system consisting of a PC computer equipped with an optical mouse, Indeo Fast card (frame grabber, true-colour, real-time), produced by Indeo (Taiwan), and colour TV camera Panasonic (Japan) coupled to a Carl Zeiss Jena microscope (Germany). This system was programmed (MultiScan 8.08 software, produced by Computer Scanning Systems, Poland) to calculate:

- the number of objects (semi-automatic function),
- the surface area of a structure using stereological net (with regulated number of points).

The percentage of TARC and MCP-1 immunopositive inflammatory cells was estimated by counting in each slide 100-120 inflammatory cells in 7-10 adjacent high power fields (semi-automatic function). The staining for TARC in epidermal cells was measured using point-counting method, which is an adaptation of the principles of Weibel [20]. The point spacing was 16 μm . The total number of the points of a net was 169, and the total area was 36864 sq. μm . Under the net described above, 7-10 randomly selected adjacent fields of the epidermis were investigated. The percentage of TARC positive staining was an expression of the number of points overlying TARC positive areas as a percentage of the total points counted.

Serum chemokine levels

Selected chemokine levels were measured in the serum of all patients and the healthy controls who had undergone skin biopsy. Five cm^3 of venous blood were drawn from the ulnar vein and after centrifugation the serum was stored at -20°C for an immunoassay procedure. Protease inhibitor was added to sera after their collection

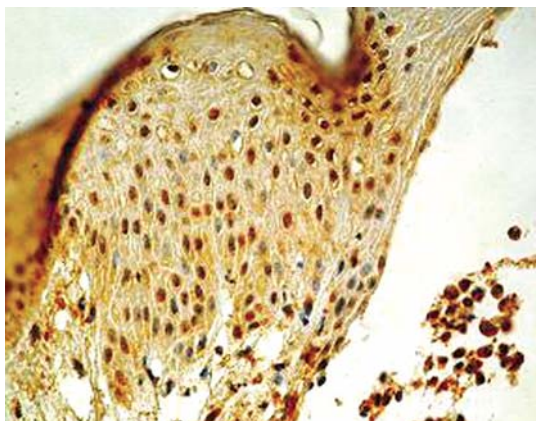


Figure 1A. Expression of eotaxin in lesional skin of bullous pemphigoid. Original magnification 400×

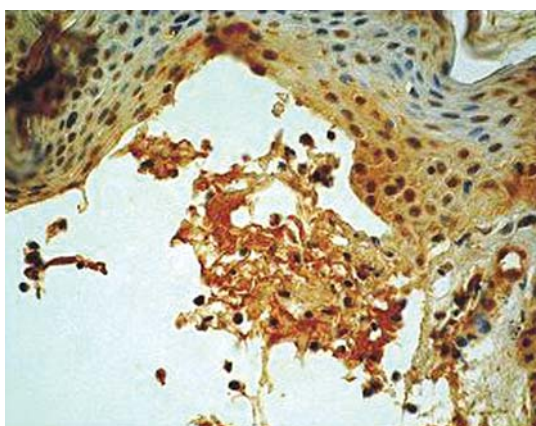


Figure 1B. Expression of eotaxin in lesional skin of dermatitis herpetiformis. Original magnification 400×

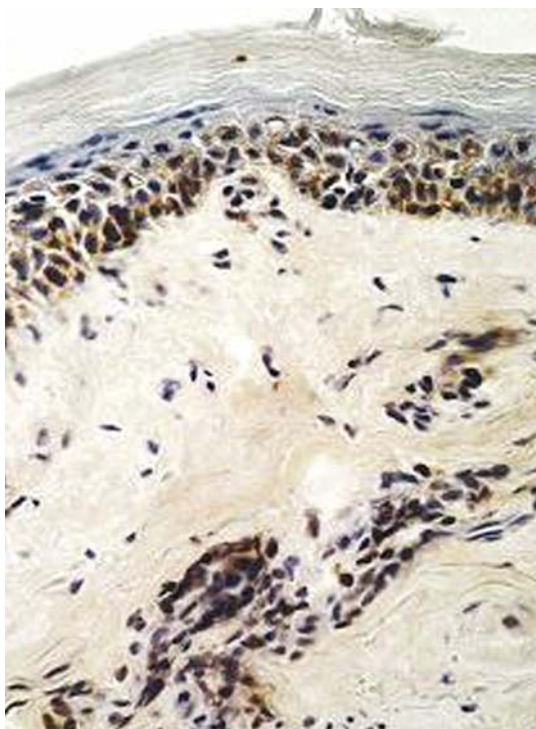


Figure 1C. Expression of eotaxin in perilesional skin of bullous pemphigoid. Original magnification 400×

(Protease Inhibitor Cocktail, Calbiochem, San Diego, USA).

The enzyme-linked immunoassays were used to measure TARC, MCP-1 and eotaxin. Immunoassays were obtained from R&D, United Kingdom.

Statistical analysis

Parametric data were expressed as mean \pm SD whereas nonparametric data as median (low and upper quartile). Differences between groups were tested using unpaired Student's t-test preceded by evaluation of normality and Levene's test. The Mann-Whitney U test was used where appropriate. Results were considered statistically significant when $p < 0.05$.

Results

Chemokine expression in skin biopsies

In skin lesion biopsies, most of BP patients revealed strong expression of eotaxin ($n = 9$) (mean 0.92 , \pm SD 0.78). In five patients eotaxin expression was assessed as moderate (Figure 1A).

In biopsies of perilesional skin, eotaxin expression was present in all patients with BP (mean 0.27 , \pm SD 0.17). In majority of patients ($n = 8$) moderate intensity of eotaxin expression was present, whereas in six patients strong eotaxin expression was observed.

Similar data were obtained from lesion biopsies in patients with DH (mean 0.82 , \pm SD 0.94). Although eotaxin expression was present in all

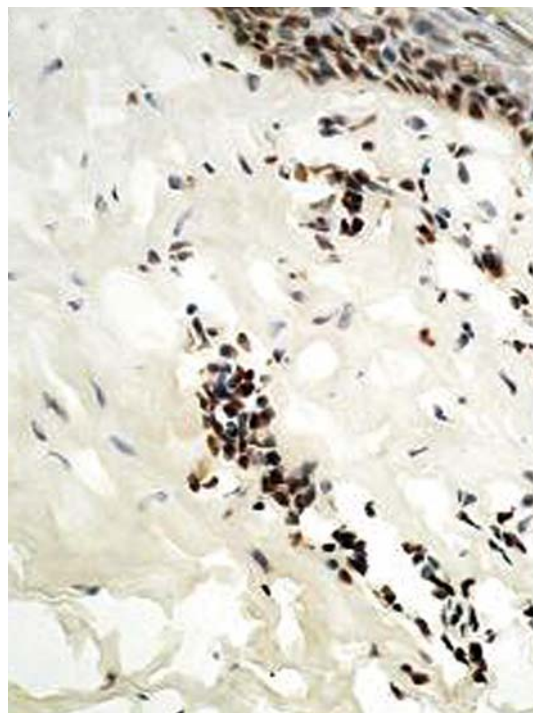

Figure 1D. Expression of eotaxin in perilesional skin of dermatitis herpetiformis. Original magnification 400×

patients, in all but one patient the expression was low (Figure 1B). Eotaxin expression was detected predominantly in subepidermis area, especially in damaged tissues.

In skin biopsies of perilesional area taken from patients with DH, eotaxin expression was much weaker than in patients with BP (mean 0.14, \pm SD 0.2, $p = 0.46$) (Figure 1C, 1D). Eotaxin expression in perilesional skin was present only in 3 out of 10 patients. Eotaxin expression was limited to lower parts of epidermis and to influxed inflammatory cells in the dermis. In skin biopsies from patients with BP and DH eotaxin expression was detected both in epidermal cells and in influxed inflammatory cells located mostly in dermis.

Eotaxin expression was not present in skin biopsies from healthy individuals.

In patients with DH, TARC expression was much lower than in patients with BP (mean $3.8 \pm$ SD 8.7, $p < 0.05$) (Figure 2A). In biopsies taken within area of the lesions, TARC expression was low and detected in keratinocytes in two patients and strongly detected in keratinocytes and inflammatory cells in one out of 10 patients. When skin biopsies from perilesional skin were analyzed in 3 out of 10 patients TARC expression in keartinocytes was low (one patient showed low TARC expression only in inflammatory cells).

In 10 out of 14 biopsies taken within skin lesions areas TARC expression was present in cells

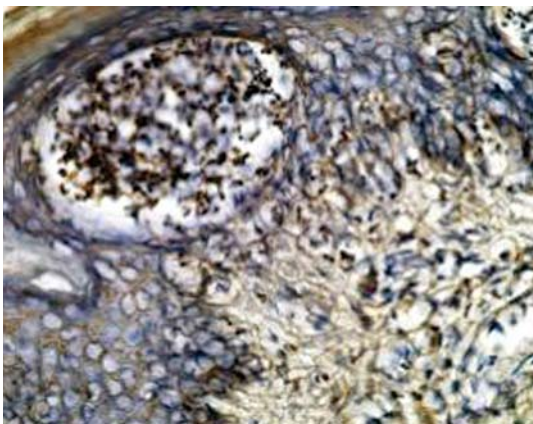


Figure 2A. Expression of TARC in lesional skin in dermatitis herpetiformis. Original magnification 400 \times

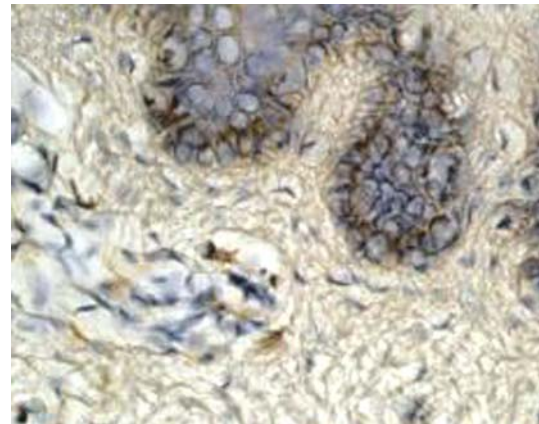


Figure 2C. Expression of TARC in perilesional skin in dermatitis herpetiformis. Original magnification 400 \times

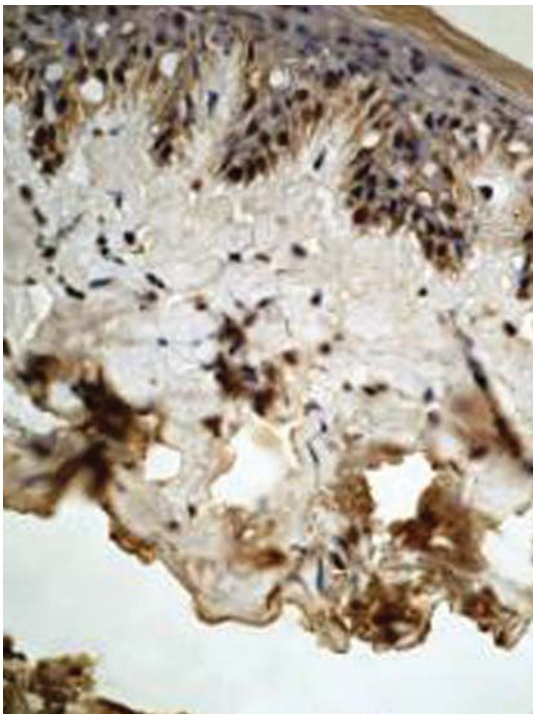


Figure 2B. Expression of TARC in lesional skin in bullous pemphigoid. Original magnification 400 \times

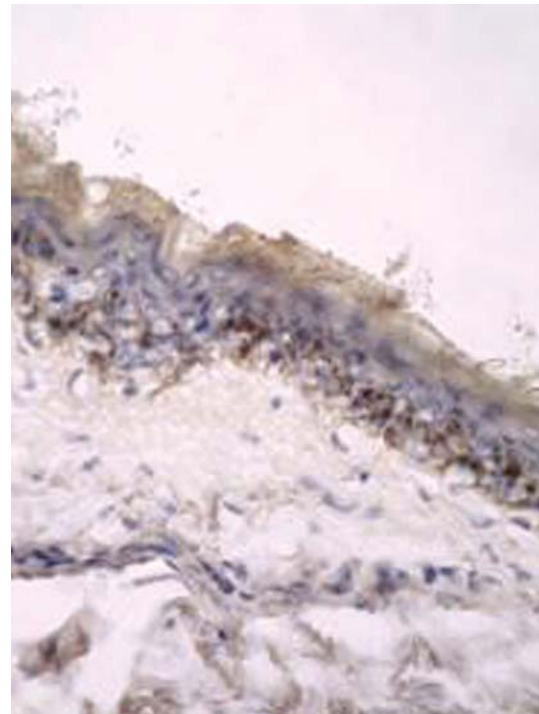


Figure 2D. Expression of TARC in perilesional skin in bullous pemphigoid. Original magnification 400 \times

located in lower part of epidermis (mean $11.64 \pm$ SD 1.9). In 6 out of 14 patients with BP TARC expression was also present in single inflammatory cells located in the subepidermis (Figure 2B). In skin biopsies taken from skin in regions surrounding the lesions in BP patients, low TARC expression was found. TARC expression was not limited to keratinocytes but also was present in subepidermal inflammatory cells (Figure 2C, 2D).

TARC expression in healthy subjects was very low, localized mostly in single keratinocytes in lower part of the epidermis.

Strong MCP-1 expression was present in 2 out of 14 patients with BP and moderate expression was detected in 4 out of 14 individuals in skin lesions (mean $7.7 \pm$ SD 10.9). In patients with BP in perilesional skin, MCP-1 was strongly expressed in inflammatory cells in 2 out of 14 patients and the moderate expression was detected in 3 out of 14 patients.

MCP-1 expression was not detected in any patients with DH neither in perilesional area and was very low in skin lesions (BP vs. DH, $p = 0.63$) (Figure 3A, 3B). MCP-1 expression was not present in healthy individuals.

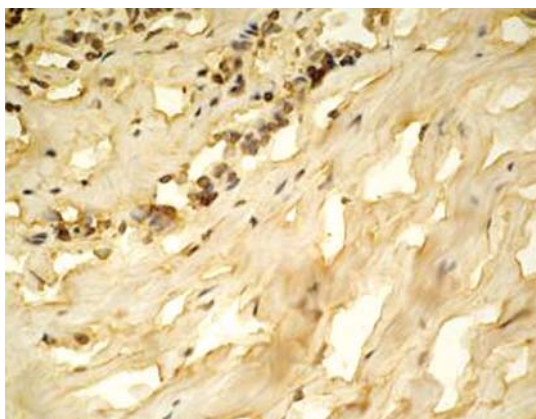


Figure 3A. Expression of MCP-1 in lesional skin in dermatitis herpetiformis. Original magnification 400×

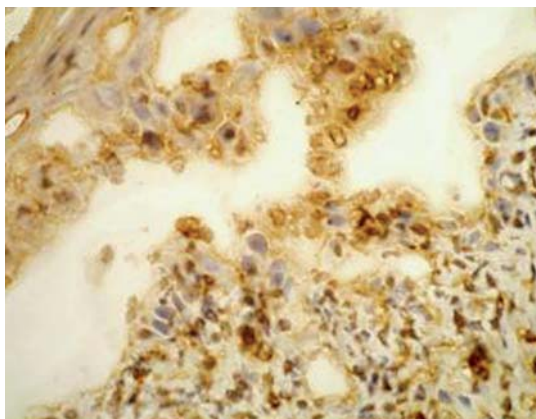


Figure 3B. Expression of MCP-1 in lesional skin in bullous pemphigoid. Original magnification 400×

Chemokine receptors expression

In patients with DH, CXCR-1 expression was higher (Figure 4A). CXCR-1 was expressed in all patients when lesions areas were studied and in 5 out of 10 patients with DH in perilesional areas. One DH patient revealed high CXCR-1 expression as assessed by a pathologist.

CXCR-1 positive cells were found in lesion areas in 8 out of 14 BP patients (Figure 4B). Some CXCR-1 positive cells were found in perilesional areas in biopsies from BP patients, however expression of CXCR-1 was weak.

Patients with DH revealed much higher CXCR-1, expression in skin lesions as compared to BP subjects (0.67 ± 0.18 vs. 0.15 ± 0.24 respectively, $p < 0.001$) as shown in Figure 4C. None of the healthy subjects revealed CXCR-1 expression.

In skin lesions in patients with BP, CXCR-2 expression was found in all patients and was assessed as a strong one in one patient (Figure 5A). In patients with BP only few cells revealing CXCR-2 expression were found in biopsies taken from lesions surrounding areas.

When biopsies taken in areas of skin lesions were analyzed, CXCR-2 expression was present in all subjects, and was assessed as strong in half of patients with DH (Figure 5B). Only 4 patients with DH revealed weak CXCR-2 expression in areas surrounding lesions.

CXCR-2 expression was not found in any tissue obtained from healthy subjects (Figure 5C). Patients with DH revealed much higher CXCR-2 expression in skin lesions as compared to BP subjects (1.1 ± 0.87 vs. 0.31 ± 0.24 , respectively, $p < 0.001$) as shown in Figure 5D.

CCR-1 expression was weak in cells from skin in biopsies taken from areas containing lesions (5 out of 14 patients) (Figure 6A) and similarly in patients with BP perilesional skin (4 patients out of 14 studied) ($p = 0.4$).

Patients with DH had even lower CCR-1 expression (Figure 6B). CCR-1 expression was detected in two cases when biopsies from lesions were investigated, and in one patient out of 10- when areas surrounding lesions were studied.

CCR-1 expression was not detected in any tissue specimens obtained from healthy subjects.

Serum chemokines levels

These nonparametric data were expressed as a median (upper and lower quartile) The TARC levels were similar in DH and BP patients as well as in healthy controls (220 pg/ml, 14.6-438.5 vs. 249.4 pg/ml, 174.7-454.8 and 158.6 pg/ml, 93.4-276.6) respectively. MCP-1 levels were statistically higher in BP patients (368.0 pg/ml, 274.0-466) as compared to patients with dermatitis herpetiformis

(301.6 pg/ml, 189.4-367.1 respectively, $p < 0.05$) (Figure 7), although no differences as compared to healthy subjects were detected. Both the patient groups (DH and BP) and healthy controls did not differ in eotaxin serum concentrations (148.0 pg/ml, 108.9-196.2 vs. 157.9 pg/ml, 117.8-207.0 vs. 119.4 pg/ml, 112.2-136.8, $p > 0.05$).

Discussion

Pathogenesis of bullous diseases is not well known, although several aspects of their pathogenesis has already been elucidated [1, 3, 7, 10]. BP and DH are diseases characterized by inflammatory changes in the area surrounding skin

lesions typical for the disease including (but not limiting to) an increase of adhesion molecules expression, in vessel and connective tissue, an influx of various inflammatory cells, and local increase in proinflammatory cytokine synthesis. Due to differences in composition of inflammatory cells in both DH and BP, it was of interest to analyze the chosen chemokines and chemokine receptors expression in skin lesions, which might play an important role in selective recruitment of leukocytes to the skin.

In this paper we were investigating the expression of selected chemokines and its receptors in the well described patients with BP and DH. We compared the patients' results with healthy

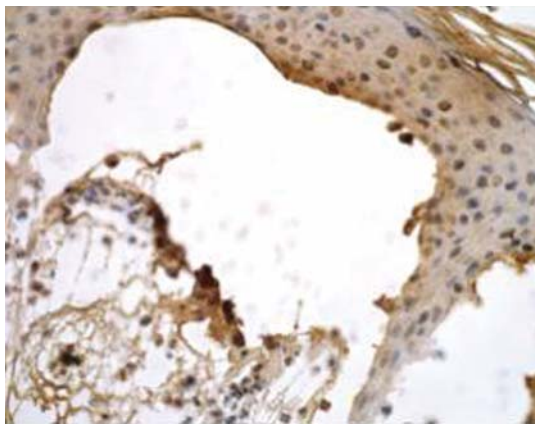


Figure 4A. Expression of CXCR-1 in lesional skin in dermatitis herpetiformis. Original magnification 400×

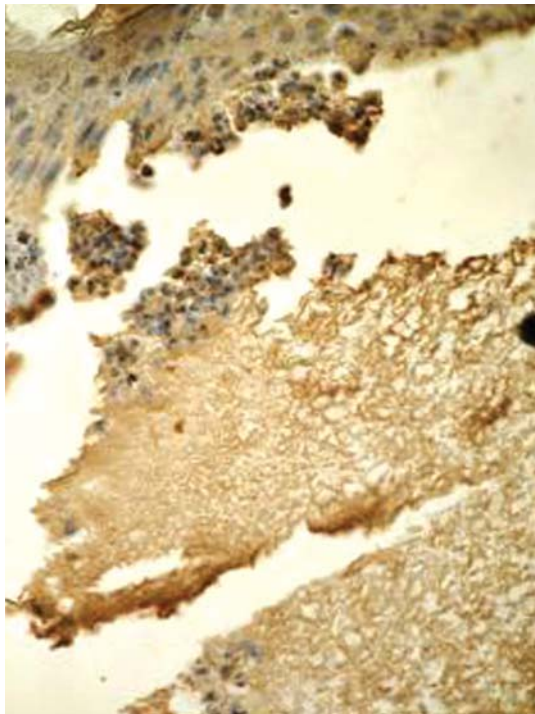


Figure 4B. Expression of CXCR-1 in lesional skin in bullous pemphigoid. Original magnification 400×

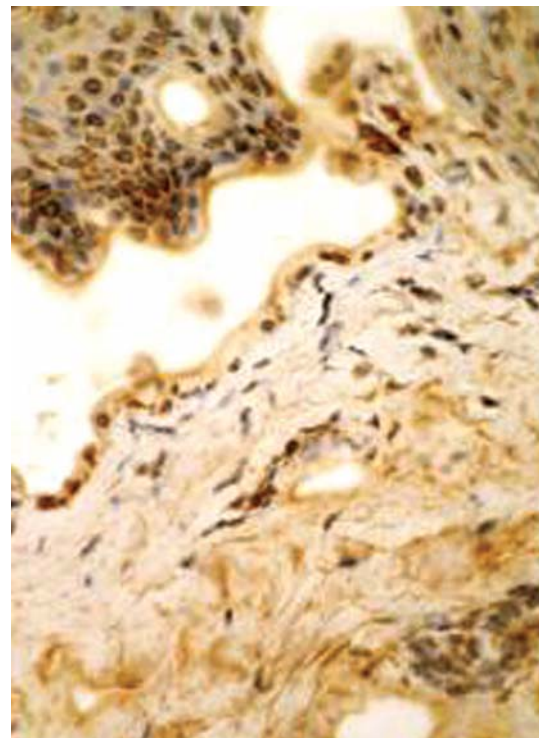


Figure 5A. Expression of CXCR-2 in lesional skin in bullous pemphigoid. Original magnification 400×

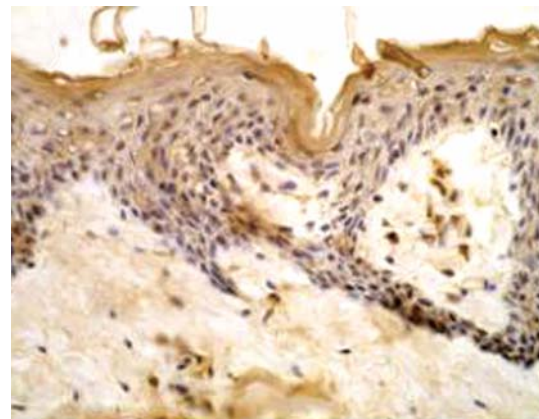


Figure 5B. Expression of CXCR-2 in lesional skin in dermatitis herpetiformis. Original magnification 400×

subjects. In our study only TARC expression was detected in the healthy subjects, because TARC (Thymus and activation-regulated chemokine/CCL17), SLC (secondary lymphoid tissue chemokine), BCA-1 (B-cell activating chemokine 1) and MDC (macrophage-derived chemokine) are constitutive chemokines [21, 22]. Noteworthy, its expression was very weak and limited to single keratinocytes in the lower part of epidermis. All these data put together, may suggest that chemokines and chemokine receptors expression is localized within the area of skin lesions and it is tightly regulated.

Eotaxin (CCL11) involvement in pathology of BP and DH was studied by several authors [14, 23-26]. Typical inflammatory changes in BP involve eosinophiles and neutrophiles accumulation within skin lesions. Eotaxin probably is the chemokine responsible for eosinophiles presence. Its expression in tissue and presence in bullous fluid was investigated by Wakugawa *et al.* [14], Abdelilah *et al.* [23] and Frezzolini *et al.* [24]. Our data may

suggest that eotaxin expression is higher in patients with BP as compared to patients with DH. The immunoreactivity for eotaxin was found to be localized mostly in the upper dermis of lesional and, to a lesser extent, perilesional skin. Eotaxin immunostaining was observed to be expressed by both eosinophiles and lymphocytes at perivascular sites and was also widespread throughout the upper and middle dermis. This phenomenon is probably connected with eosinophilic influx characteristic for BP. Although eotaxin was also found in skin biopsies from patients with DH, some authors did not find its increase in serum obtained from patients with DH as compared to healthy subjects [25, 26].

Some researches show that eotaxin serum concentration is elevated in BP patients [16, 24, 27] but our results are different. Frezzolini *et al.* [24] and Shrikhande *et al.* [27] used ELISA the same method as ours, but the groups were smaller than ours. Nakashima *et al.* [16] however they used a different method a sandwich immunoassay-based protein array system, had the biggest group (38 BP patients). Large amounts of eotaxin were detected both in serum and blister fluids of BP patients in Frezzolini *et al.* results. In this paper mean serum levels of eotaxin in BP were significantly increased when compared to both healthy and pemphigus vulgaris donors. In our results both the patients and control groups did not differ in eotaxin serum concentrations. More studies on bigger groups are needed in our opinion.

There is a vast amount of data supporting the role of TARC in pathogenesis of Th2 – like diseases (e.g. atopic dermatitis [21]). In our study TARC expression was higher in patients with BP as compared to patients with DH. Kakinuma *et al.* [15] delivered similar data studying TARC expression in epidermal keratinocytes. Our findings are in contrast with Kakinuma *et al.* [15] data concerning TARC concentration in sera in patients with BP in comparison to patients suffering from pemphigus vulgaris and in healthy subjects. Although the same method (ELISA) was used, but from other manufacturer (Genzyme Corp., USA), in our study there was no significant difference in serum concentration between BP patients and control group.

According to our knowledge, no published data are available about TARC expression in DH. In our patients with DH TARC expression was very low and mostly limited to single keratinocytes and influx inflammatory cells.

We have found MCP-1 expression only in patients with BP and in none of the subjects suffering from DH. Monocyte chemoattractant protein-1 (MCP-1) is a member of the CC family and is a potent agonist for monocytes, T lymphocytes, natural killer cells, and basophiles but not neutrophiles [22]. Nakashima *et al.* [16] report serum

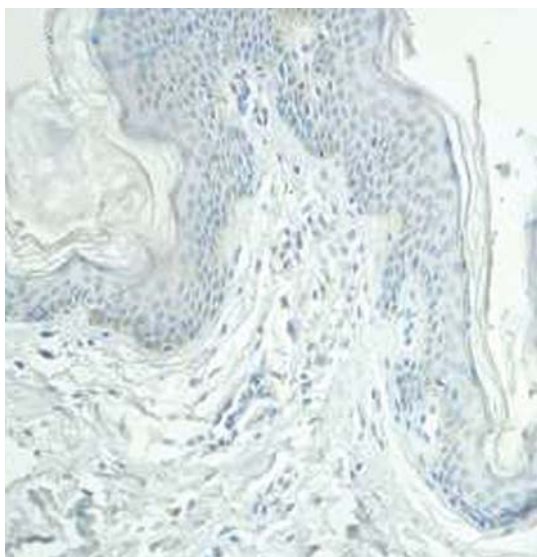


Figure 5C. Expression of CXCR-2 in healthy subjects. Original magnification 100x

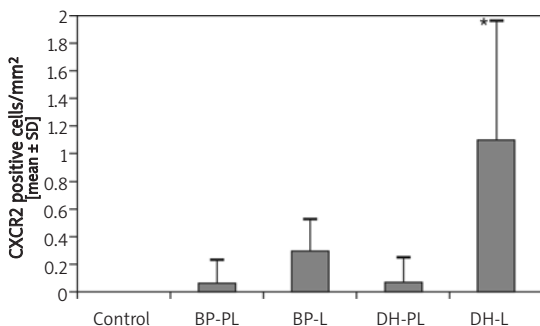


Figure 5D. Expression of CXCR-2 in patients with BP and DH. Morphometric analysis. PL – perilesional skin, L – skin lesions. Data from 11 patients with BP, 7 patients with DH and 4 healthy volunteers
* $p < 0.02$ as compared to BP

levels of chemokines, including RANTES, eotaxin, MCP-1, MCP-2 and MCP-3 in patients with BP. In their paper serum levels of MCP-1 were significantly increased in patients with BP as compared to healthy controls. Furthermore, serum levels of IP-10 (interferon-inducible protein-10), MIG (monokine induced by IFN- γ), MCP-1 and eotaxin in patients with BP significantly increased depending on the disease severity and the volume of affected skin area. This study suggests that, while various chemokines are involved in the pathomechanism of BP, MCP-1 has a significant contribution in eosinophiles and leucocytes recruitment [16]. In DH the infiltration consists of neutrophils which can be related to the absence of MCP-1 in skin lesions.

CCR1 is a chemokine receptor for RANTES. RANTES seems to be involved in BP pathogenesis mostly due to its chemotactic activity of attracting the eosinophiles [12, 13]. Prominent CCR1 expression in skin lesions and surrounding area in patients with BP may directly suggest both RANTES and CCR1 role in BP pathogenesis. Our finding goes along with the earlier data suggesting RANTES prominent role in skin inflammatory changes in BP [17]. Interestingly CCR1 is far less expressed in skin lesions in DH as compared to BP. This may suggest that eosinophilic infiltration present in both BP and DH [14], has a different underlying mechanism. RANTES is one of many cytokines and chemokines [e.g. IL-2 (interleukin-2), IL-3, IL-8, MCP-2, MCP-3, MCP-4] acting as eosinophiles chemoattractants [12].

CXCR1 is one of a few receptors for IL-8 (CXCL8). The role of IL-8 in pathogenesis of BP has been validated in several papers [18, 28-31]. Albeit, the role of IL-8 is well documented in DH, there are some controversial data regarding its synthesis [31-33]. We clearly demonstrated that the CXCR1 expression pattern is higher in DH than in patients with BP in skin lesions and in perilesional skin.

IL-8 is a major ligand for CXCR2 [36]. In our paper similarly as for CXCR1, CXCR2 expression was similar in perilesional skin in patients with BP and DH but much higher in skin lesions in patients with DH. Again this may suggest that aforementioned diseases may differ not in IL-8 expression but in IL-8 receptor expression in lesion area. IL-8 is a major chemoattractant for neutrophils, present in skin lesions in both BP and DH. This also may suggest a role of other than IL-8 cytokines in an inflammatory influx in DH and BP.

In conclusion, BP and DH are diseases with unknown pathogenesis, varying in clinical presentation and have many common issues regarding the inflammatory changes in skin lesions. MCP-1 is a chemoattractant and activator of monocytes, lymphocytes and basophiles, but is not active towards neutrophils and eosinophiles [34, 35]. Because CCR-2 – receptor of MCP-1 – is

increased in chronically inflamed skin lesions in psoriasis and atopic dermatitis [36], Nakashima *et al.* suggest that MCP-1 may play an essential role in prolonged inflammation of BP lesions [16].

Inflammatory changes in skin in both studied diseases are probably related not only to neutrophilic influx but also to eosinophiles aggregation within the area of involved skin [19]. Several papers discussed the role of various factors in eosinophilic infiltration. Our data may suggest

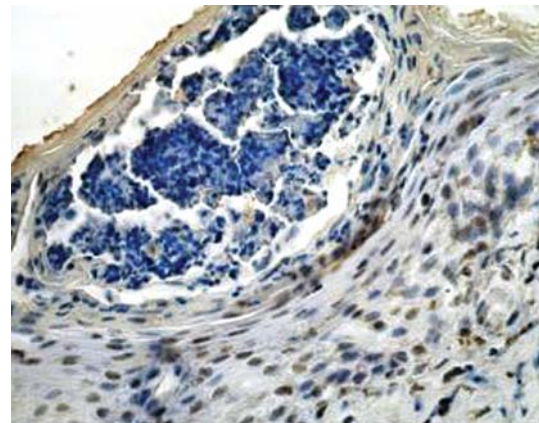


Figure 6A. Expression of CCR-1 in lesional skin in bullous pemphigoid. Original magnification 400 \times

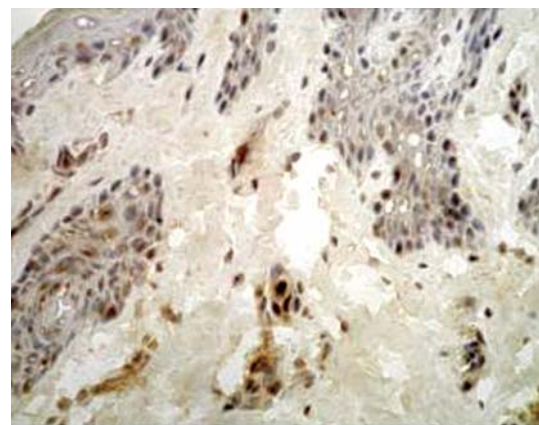


Figure 6B. Expression of CCR-1 in lesional skin in dermatitis herpetiformis. Original magnification 400 \times

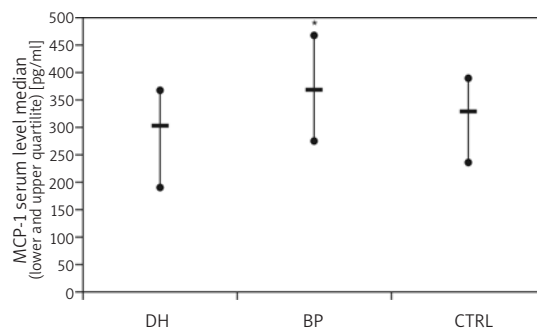


Figure 7. Serum levels of MCP-1. Data expressed as means \pm SD

* $p < 0.05$ as compared to DH

that different CCR1 expression may take part in eosinophiles infiltration in BP.

Due to the fact that many cytokine and chemokines are involved in BP and DH pathogenesis further studies are needed to elucidate the role of soluble proteins and against chemokines antibodies and their receptors in pathogenesis of bullous diseases.

Acknowledgments

The study was funded by the research projects of Medical University of Lodz: 503-8019-1, 502-18-521 and Ministry of Science and Higher Education: 507-18-007 and 2 P05B 223 29

References

1. Karpati S. Dermatitis herpetiformis: close to unravelling a disease. *J Dermatol Sci* 2004; 34: 83-90.
2. Sárdy M, Kárpáti S, Merkl B, Paulsson M, Smyth N. Epidermal transglutaminase (Tgase3) is the autoantigen in dermatitis herpetiformis. *J Exp Med* 2002; 195: 747-57.
3. Dieterich W, Laag E, Bruckner-Tuderman L, et al. Antibodies to tissue transglutaminase as serologic markers in patients with dermatitis herpetiformis. *J Invest Dermatol* 1999; 113: 133-6.
4. Hendrix JD, Magnum KL, Zone JJ, Gammon WR. Cutaneous IgA deposits in bullous diseases function as ligands to mediate adherence of activated neutrophils. *J Invest Dermatol* 1990; 94: 667-72.
5. Dahl MV, Falk RJ, Carpenter R, Michael AF. Membrane attack complex of complement in dermatitis herpetiformis. *Arch Dermatol* 1985; 121: 70-2.
6. Airola K, Vaalamo M, Reunala T, Saarialho-Kere UK. Enhanced expression of interstitial collagenase, stromelysin-1, and urokinase plasminogen activator in lesions of dermatitis herpetiformis. *J Invest Dermatol* 1995; 105: 184-9.
7. Ghohestani RF, Novotney J, Chaudhary M, Agah RS. Bullous pemphigoid: from the bedside to the research laboratory. *Clin Dermatol* 2001; 19: 690-6.
8. Stanley JR. Cell adhesion molecules as targets of autoantibodies in pemphigus and pemphigoid, bullous diseases due to defective epidermal cell adhesion. *Adv Immunol* 1992; 53: 291-325.
9. Jordan RE. Basement zone antibodies in bullous pemphigoid. *JAMA* 1967; 200: 751-6.
10. Schmidt E, Reimer S, Kruse N, Bröcker EB, Zillikens D. Autoantibodies to BP 180 associated with bullous pemphigoid release interleukin-6 and interleukin-8 from cultured human keratinocytes. *J Invest Dermatol* 2000; 115: 842-8.
11. Grando SA, Glukhenky BT, Drannik GN, Epshtein EV, Kostromin AP, Korostash TA. Mediators of inflammation in blister fluids from patients with pemphigus vulgaris and bullous pemphigoid. *Arch Dermatol* 1989; 125: 925-30.
12. Baggiolini M. Chemokines in pathology and medicine. *J Inter Med* 2001; 250: 91-104.
13. Wong MR, Fish EN. Chemokines: attractive mediators of the immune response. *Sem Immunol* 2003; 15: 5-14.
14. Wakugawa M, Nakamura K, Hino H, et al. Elevated levels of eotaxin and interleukin-5 in blister fluid of bullous pemphigoid: correlation with tissue eosinophilia. *Br J Dermatol* 2000; 143: 112-6.
15. Kakinuma T, Wakugawa M, Nakamura K, Hino H, Matsushima K, Tamaki K. High level of thymus and activation-regulated chemokine in blister fluid and sera of patients with bullous pemphigoid. *Br J Dermatol* 2003; 148: 203-10.
16. Nakashima H, Fujimoto M, Asashima N, et al. Serum chemokine profile in patients with bullous pemphigoid. *Br J Dermatol* 2007; 156: 454-59.
17. D'Auria L, Pietravalle M, Cordiali-Fei P, Ameglio F. Increased tryptase and myeloperoxidase levels in blister fluids of patients with bullous pemphigoid: correlation with cytokines, adhesion molecules and anti-basement membrane zone antibodies. *Exp Dermatol* 2000; 9: 131-7.
18. Schmidt E, Ambach A, Bastion B, Bröcker EB, Zillikens D. Elevated levels of interleukin-8 in blister fluid of bullous pemphigoid compared with suction blisters of healthy control subjects. *J Am Acad Dermatol* 1996; 34: 310-2.
19. Ackerman AB, Chongchitnant N, Sanchez J, et al. Histologic diagnosis of inflammatory skin disease: a algorithmic method based on pattern analysis. 2nd ed. Williams & Wilkins, Baltimore 1997.
20. Weibel ER. Point counting methods. In: Weibel ER. *Stereological methods*. Academic Press, London 1979; 101-59.
21. Saeki H, Tamaki K. Thymus and activation regulated chemokine (TARC)/CCL17 and skin diseases. *J Dermatol Science* 2006; 43: 75-84.
22. Zlotnik A, Yoshie O. Chemokines. A new classification system and their role in immunity. *Immunity* 2000; 12: 121-7.
23. Abdelilah GS, Wellemans V, Aqouli M, et al. Increased expression of Th2-associated chemokines in bullous pemphigoid disease. Role of eosinophils in the production and release of these cytokines. *Clin Immunol* 2006; 120: 220-31.
24. Frezzolini A, Teofoli P, Cianchini G, et al. Increased expression of eotaxin and its specific receptor CCR3 in bullous pemphigoid. *Eur J Dermatol* 2002; 12: 27-31.
25. Amerio P, Verdolini R, Giangiacomi M, et al. Expression of eotaxin, interleukin 13 and tumor necrosis factor-alpha in dermatitis herpetiformis. *Br J Dermatol* 2000; 143: 974-8.
26. Caproni M, Cardinali C, D'Agata A, Selvaggi W. Serum eosinophil cationic protein, myeloperoxidase, tryptase, eotaxin and Th2-like cytokines in dermatitis herpetiformis. *Int Arch Allergy Immunol* 2002; 128: 67-72.
27. Shrinkhande M, Hunziker T, Braathen LR, Pichler WJ, Dahinden CA, Yawalkar N. Increased coexpression of eotaxin and interleukin 5 in bullous pemphigoid. *Acta Derm Venereol* 2000; 80: 277-80.
28. Kuhns DB, DeCarlo E, Hawk DM, Gallin JI. Dynamics of the cellular and humoral components of the inflammatory response elicited in skin blisters in humans. *J Clin Invest* 1992; 89: 1734-40.
29. Ameglio F, D'Auria L, Bonifati C, Ferraro C, Mastroianni A, Giacalone B. Cytokine pattern in blister fluid and serum of patients with bullous pemphigoid: relationships with disease intensity. *Br J Dermatol* 1998; 138: 611-4.
30. Kristensen M, Larsen CG, Jorgensen P, Paludan K. RNA purification from epidermal suction blisters. *Acta Derm Venereol* 1991; 71: 423-6.
31. Bornscheuer E, Zillikens D, Schröder JM, Sticherling M. Lack of expression of interleukin 8 and RANTES in autoimmune bullous skin diseases. *Dermatology* 1999; 198: 118-21.
32. Graeber M, Baker BS, Garioch JJ, Valdimarsson H, Leonard JN, Fry L. The role of cytokines in the generation of skin lesions in dermatitis herpetiformis. *Br J Dermatol* 1993; 129: 530-2.

33. Hall RP, Takeuchi F, Benbenisty KM, Streilein RD. Cutaneous endothelial cell activation in normal skin of patients with dermatitis herpetiformis associated with increased serum levels of IL-8, sE-selectin, and TNF-alpha. *J Invest Dermatol* 2006; 126: 1331-7.
34. Yoshimura T, Robinson EA, Tanaka S, Appella E, Kuratsu J, Leonard EJ. Purification and amino acid analysis of two human glioma-derived monocyte chemoattractants *J Exp Med* 1989; 169: 1449-59.
35. Proost P, Wuyts A, van Damme J. Human monocyte chemotactic proteins -2 and-3: structural and functional comparison with MCP-1. *J Leukoc Biol* 1996; 59: 67-74.
36. Vestergaard C, Just H, Baumgartner Nielsen J, Thestrup-Pedersen K, Deleuran M. Expression of CCR2 on monocytes and macrophages in chronically inflamed skin in atopic dermatitis and psoriasis. *Acta Derm Venereol* 2004; 84: 353-8.