

# Chronic mucocutaneous candidiasis with endocrinopathy – case report

Aleksandra Lesiak<sup>1</sup>, Anna Erkiert-Polguj<sup>2</sup>, Bożena Dziańkowska-Bartkowiak<sup>2</sup>, Anna Sysa-Jędrzejowska<sup>1</sup>, Joanna Narbutt<sup>1</sup>

<sup>1</sup>Department of Dermatology and Venereology, Medical University of Lodz, Poland

<sup>2</sup>Laboratory of Immunodermatology, Department of Dermatology, Medical University of Lodz, Poland

**Submitted:** 15 February 2009

**Accepted:** 24 April 2009

Arch Med Sci 2010; 6, 3: 464-467

DOI: 10.5114/aoms.2010.14273

Copyright © 2010 Termedia & Banach

**Corresponding author:**

Dr Aleksandra Lesiak  
Department of Dermatology  
Medical University of Lodz  
Krzemieniecka 5  
94-017 Lodz, Poland  
Phone/fax: +48 42 686 79 81/  
+48 42 688 45 65  
E-mail: lesiak\_ola@interia.pl

## Abstract

Chronic mucocutaneous candidiasis (CMC) is characterized by *Candida* infection of the mucous membrane, scalp, skin and nails. We present a case of a 42-year-old man who was treated twice in the Dermatological Department. He was admitted the first time as a 7-year-old boy because of skin and mucosal lesions and then the diagnosis of *granuloma candidamyceticum* was established. Thirty-one years later he was admitted again with a history of facial skin lesions and blepharitis. For a couple of years he had suffered from diabetes and hypothyroidism. The diagnosis of CMC with endocrinopathy was established in our patient.

**Key words:** chronic mucocutaneous candidiasis, *Candida albicans*, endocrinopathy, hypothyroidism.

## Introduction

Chronic mucocutaneous candidiasis (CMC) refers to a heterogeneous group of disorders characterized by recurrent or persistent superficial infections of the skin, mucous membranes, and nails with *Candida* organisms, usually *C. albicans* [1-3]. Classification criteria are based on the association with other diseases, type of inheritance and disease onset and were categorized by Coleman and Hay (Table I) [1]. Provisional diagnosis of CMC can be established based on the clinical findings. Microscopy and culture of skin swabs and scrapings confirm the presence of microorganisms [4].

We present a rare case of a 42-year-old male patient with CMC and hypothyroidism with the coexistence of diabetes mellitus. The patient gave written informed consent for his case report to be published.

## Case report

A 7-year-old Caucasian boy was admitted to the Department of Dermatology in 1974 with a history of recurrent whitish plaque in the oral cavity and skin lesions since eight months of life. From his first months of life he suffered from recurrent pulmonary infections. On admission he presented with decreased growth for his age, below the 5<sup>th</sup> percentile.

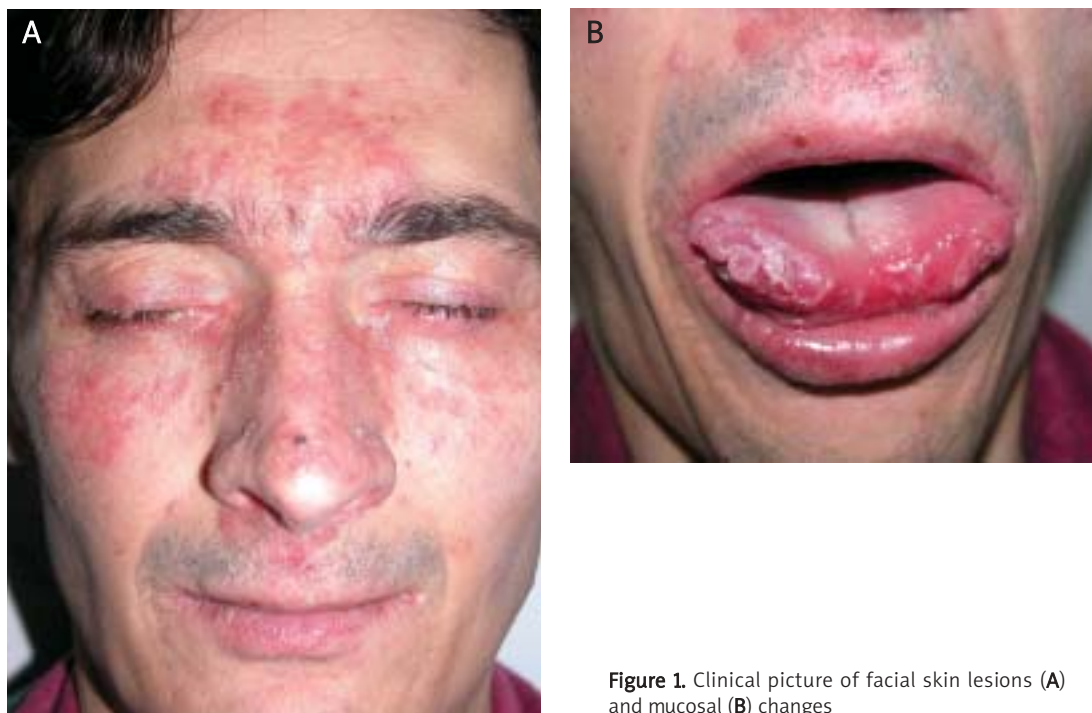Table I. Types of CMC

Association with other disease	Pattern of inheritance	Onset
Without endocrinopathy	Recessive	Childhood
With endocrinopathy autoimmune polyendocrinopathy	Recessive	Childhood
Without endocrinopathy	Dominant	Childhood
With endocrinopathy with hypothyroidism	Dominant	Childhood
Sporadic CMC	Unknown	Childhood
CMC with keratitis	Unknown	Childhood
Late-onset CMC with thymoma	Unknown	Adult

Erythematous-squamous serpiginous plaques were observed on the trunk and legs, and erythematous, hyperkeratotic skin lesions were located on the scalp. Examination of the oral cavity revealed angular cheilitis. The fingernails were thickened, fragmented, discoloured, with significant oedema and erythema of the surrounding periungual tissue. No changes were observed within the toenails. Familial history for genetic pathologies or immunodeficiency was negative. Scrapings from the infected site showed the presence of yeast cells and pseudohyphae. Culture for fungi in Sabouraud's agar presented growth of *C. albicans*. Blood count analysis showed anaemia, leukocytosis and glycaemia. Thyroid hormones, calcium and phosphorus were normal. Only a very high level of total cholesterol was noted (480 mg%). IgG1 and IgA values were above normal. Intradermal cutaneous test with tardive reading was strongly positive for candidin from 24-72 h and negative for trichophytin. The blast transformation of the patient's lymphocytes with phytohaemagglutinin was 80% of functional capacity against a control, demonstrating a slight decrease in the functional capacity of the lymphocytes. The mitotic index was lower than in normal controls (47%). The patient was diagnosed with *granuloma candidamyceticum*. Treatment was initiated with oral natamycin (50 mg every 6 h) and with topical antifungal specimens (clotrimazole cream 3 times a day). Because of pharyngitis he was treated with sulphonamides (sulfamerazine and sulphaproxyline in suspension 9 ml/twice daily). A satisfactory result was obtained, with disappearance of the lesions after 2 weeks of treatment. Thirty-one years later he was admitted once again to our department with a 4-month history of persistent scaling, erythematous facial skin lesions and blepharitis. He had suffered from diabetes type 1 for 11 years and was being treated with insulin (dose dependent on glycaemia level). Two years before admission arterial hypertension (enalapril 5 mg/twice daily) and autoimmune hypothyroidism (L-thyroxine 100 µg/day) were diagnosed. Temporarily he suffered from respiratory

tract infections and recurrent mucous membrane lesions which required treatment with topical antifungal agents and fluconazole. Within this period the patient was being treated by a GP and was not hospitalized in a dermatological unit. Oral cavity examination revealed white patches scattered over buccal, palatal and labial mucosa and a fissured tongue. The diagnosis of acute atrophic and pseudomembranous candidiasis of the oral cavity was established (Figure 1). Fingernails of both hands showed onycholysis, onychorrhexis and onychodystrophy. No periungual inflammatory lesions were noted. Toenails were unchanged. KOH examination from skin lesions (forehead, eyelids) and oral mucosal membranes (tongue and buccae) was positive for yeast cells. The culture was positive for *C. albicans*. Mycological samples (KOH and culture) from nails were negative. Blood count showed slight anaemia (RBC –  $3.5 \times 10^6/\text{mm}^3$ , HGB – 10.6 g/dl, HCT – 34.2%) and hyperglycaemia (134 mg/dl). The patient is being followed up in the Diabetic Outpatient Department and the disease is partially controlled. On admission to our department the patient was administered with L-thyroxine and no abnormalities in total cholesterol, liver enzymes or T3, T4 and TSH levels were found. Also antithyroid autoantibodies were within the normal range. HIV test was negative. The blast transformation of the patient's lymphocytes with phytohaemagglutinin and the mitotic index were as in normal controls. Endocrine screening tests including prolactin, testosterone and parathyroid-stimulating hormone were within normal levels. In the evaluation of humoral immunity, the following serum levels were obtained: IgG1 = 17.6 g/l (7-14 g/l), IgM = 0.9 g/l (0.4-2.3 g/l), IgA = 4.6 g/l (0.7-4 g/l).

Treatment with fluconazole and topical antifungal medications was unsuccessful. After 2 months of itraconazole therapy (100 mg/daily) disappearance of the lesions was noted (Figure 2). The patient was followed up to three years without recurrence. The patient is a bachelor and has no children.



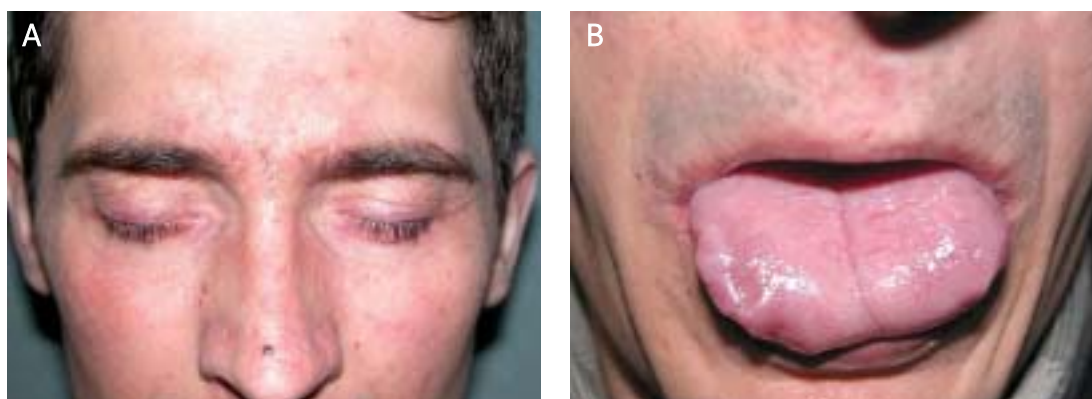
**Figure 1.** Clinical picture of facial skin lesions (A) and mucosal (B) changes

## Discussion

Coleman and Hay [1] described 2 families with a new syndrome characterized by hypothyroidism and CMC with dominant inheritance. Myhre *et al.* [5] also described 2 families with CMC (with main manifestations of facial seborrhoeic dermatitis, generalized folliculitis and scaling dermatitis) and hypothyroidism, which became evident during childhood. In contrast, the presented patient developed similar facial lesions and thyroid gland insufficiency only in adulthood. Spanish authors described CMC in an uncommon form of candidiasis granuloma and hypothyroidism [6]. In our patient also *granuloma candidamyceticum* was diagnosed during childhood, but then it was not accompanied by internal organ failure. Atkinson *et al.* [7] described a family with a combination of CMC and

thyroid disease, segregating as an autosomal dominant trait with reduced penetrance. In our patient genetic tests were not performed; however, based on the medical history a genetic background may be excluded.

The pathomechanism of CMC is still not fully known. Complement function, neutrophil phagocytosis and intracellular killing are believed to be among the factors involved in disease development. Patients may have high titres of IgG1 and IgA, with or without IgG2 subclass deficiency, which was noted in our patient. The blastic transformation test of the patient's lymphocytes and mitotic index demonstrated a slight decrease in the functional capacity of the lymphocytes in childhood while in adulthood they were not observed. Immunological studies of patients with CMC often reveal defects related to cell-mediated



**Figure 2.** Clinical picture of the face (A) and oral cavity (B) after 2 months of treatment with itraconazole

immunity, but the defects themselves vary widely. The true details of the defects associated with CMC syndrome remain poorly understood. Results from cellular immunity tests, such as the prick-test with *Candida* antigens, may be negative, but in our patient the intradermal cutaneous test with tardive reading was strongly positive for candidin, which may suggest no defects in cell-mediated immunity [8].

Literature data indicate that in response to *Candida* antigen patients with CMC have impaired cytokine synthesis, with insufficient production of Th1-derived cytokines rather than overproduction of type 2 [3, 9]. Treatment with topical and systemic antimycotic drugs results in temporary recovery, but it is unable to reach a complete remission [10]. In the presented case therapy with itraconazole resulted in a 3-year remission of skin and mucosal lesions.

Based on the clinical picture and laboratory findings the diagnosis of CMC with endocrinopathy was established in our patient. The presented case also shows that a childhood onset of skin lesions typical for CMC may be the first sign of subsequent development of endocrine failure.

Patients and their families should be informed of the chronic and recurrent nature of the disease and the necessity of frequent antifungal treatment.

### Acknowledgments

The study was funded by internal grants from the Medical University of Lodz no. 503-1019-1 and 503-8019-1. The authors declare no conflict of interest.

### References

1. Coleman R, Hay RJ. Chronic mucocutaneous candidiasis associated with hypothyroidism: a distinct syndrome? *Br J Dermatol* 1997; 136: 24-9.
2. Collins SM, Dominguez M, Ilmarinen T, Costigan C, Irvine AD. Dermatological manifestations of autoimmune polyendocrinopathy-candidiasis-ectodermal dystrophy syndrome. *Br J Dermatol* 2006; 154: 1088-93.
3. De Moraes-Vaconcelos D, Orii NM, Romano CC, Iqueoka RY, Duarte AJ. Characterization of cellular immune function of patients with chronic mucocutaneous candidiasis. *Clin Exp Immunol* 2001; 123: 247-53.
4. Masi M, De Vinci C, Baricordi OR. Transfer factor in chronic mucocutaneous candidiasis. *Biotherapy* 1996; 9: 97-103.
5. Myhre AG, Stray-Pedersen A, Spangen S, et al. Chronic mucocutaneous candidiasis and primary hypothyroidism in two families. *Eur J Pediatr* 2004; 163: 604-11.
6. Jimenez Alonso J, Torres Serrano F, Jaimez L, et al. Candidiasis granuloma associated to hypothyroidism. *Med Clin (Barc)* 1981; 77: 220-3.
7. Atkinson TP, Schaffer AA, Grimbacher B, et al. An immune defect causing dominant chronic mucocutaneous candidiasis and thyroid disease maps to chromosome 2p in a single family. *Am J Hum Genet* 2001; 69: 791-803.
8. Kirkpatrick CH. Chronic mucocutaneous candidiasis. *J Amer Acad Dermatol* 1994; 31 (Suppl 2): S14-7.
9. Lilić D, Gravenor I. Immunology of chronic mucocutaneous candidiasis. *J Clin Pathol* 2001; 54: 81-3.
10. Polizzi B, Origgi L, Zuccaro G, Matti P, Scorza R. Successful treatment with cimetidine and zinc sulphate in chronic mucocutaneous candidiasis. *Am J Med Sci* 1996; 311: 189-90.