

Endovascular repair of thoracic aortic aneurysm

Ibrahim Akin*, Stephan Kische*, Tim C. Rehders, Christoph A. Nienaber, Mathias Rauchhaus, Hüseyin Ince

Department of Medicine I, Divisions of Cardiology, Pulmonology and Intensive Care Unit, University Hospital Rostock, Rostock School of Medicine, Rostock, Germany

*Both authors contributed equally to this manuscript.

Submitted: 07 November 2009

Accepted: 31 December 2009

Arch Med Sci 2010; 6, 5: 646-652

DOI: 10.5114/aoms.2010.17075

Copyright © 2010 Termedia & Banach

Corresponding author:

Prof. Hüseyin Ince MD
Department of Medicine I
Divisions of Cardiology,
Pulmonology and Intensive
Care Unit
University Hospital Rostock
Rostock School of Medicine
Ernst-Heydemann-Str. 6
18057 Rostock, Germany
Phone: +49 (0)381 494 77 97
Fax: +49 (0)381 494 77 02
E-mail: hueseyin.ince@
med.uni-rostock.de

Abstract

A thoracic aortic aneurysm (TAA) is a potentially life-threatening condition with structural weakness of the aortic wall, which can progress to arterial dilatation and rupture. Today, both an increasing awareness of vascular disease and the access to tomographic imaging facilitate the diagnosis of TAA even in an asymptomatic stage. The risk of rupture for untreated aneurysms beyond a diameter of 5.6 cm ranges from 46% to 74% and the two-year mortality rate is greater than 70%, with most deaths resulting from rupture. Treatment options include surgical and non-surgical repair to prevent aneurysm enlargement and rupture. While most cases of ascending aortic involvement are subject to surgical repair (partially with valve-preserving techniques), aneurysm of the distal arch and descending thoracic aorta are amenable to emerging endovascular techniques as an alternative to classic open repair or to a hybrid approach (combining debranching surgery with stent grafting) in an attempt to improve outcomes.

Key words: stent graft, thoracic aortic aneurysm, thoracic aortic dissection, Crawford.

Introduction

Over the past 30 years, the reported incidence of thoracic aortic aneurysm (TAA) has increased with better diagnostics and with more patients living to advanced age. Little is known, however, about the true prevalence and mortality rate of TAA in a particular population [1, 2]. A population-based study in Rochester, Minnesota reported an age- and gender-adjusted incidence of 5.9 new aneurysms per 100 000 person-years in a Midwestern community over a 30-year period with median ages of 65 years for men and 77 years for women and a distribution of aortic segments as follows: the ascending aorta was involved in 51%, the arch in 11%, and the descending thoracic aorta in 38% [3, 4]. The pathogenesis of aortic aneurysms has not been established fully, but it is believed to be multifactorial and include atherosclerosis, increased tissue protease activity, antiprotease deficiency, mechanical factors, inflammatory disorders, infection and genetic collagen defects such as Marfan syndrome and type IV Ehlers-Danlos syndrome. Up to 20% of patients with an aneurysm have a first-degree relative with the same disorder, which suggests a genetic link [5]. The aetiology of TAA is most often aortic dissection in 53%, arteriosclerosis in 29%, aortitis in 8%, cystic medial necrosis in 6%, and syphilis in 4% [6]. The natural history

of thoracic aortic aneurysms has not been sufficiently defined. One reason for this is that both the aetiology and location of an aneurysm may affect its rate of growth and propensity for dissection or rupture. The Yale group showed in their longitudinal data that the mean rate of growth for all thoracic aneurysms was significantly lower (0.1 cm/y) than that of abdominal aneurysms (0.2-0.5 cm/y) [2]. The rate of growth, however, was greater for aneurysms of the descending aorta versus the ascending aorta, was greater for dissected versus non-dissected aneurysms, and was most pronounced in Marfan syndrome [2]. Initial size can also be an important predictor of the rate of thoracic aneurysm growth; a study based on 721 patients supported the fact that TAA size had a profound impact on risk for rupture, with an annual rate of 2% in aneurysms < 5 cm, 3% in aneurysms 5-5.9 cm, and 7% for aneurysms over 6 cm in diameter. Therefore the risk appears to rise abruptly as thoracic aneurysms reach a size of 6 cm [7, 8]. In several series aneurysm rupture occurred in 32% to 68% of medically treated patients and rupture accounted for 32% to 47% of deaths; thus the 1-, 3- and 5-year survival rate of thoracic aneurysms left without repair was 65%, 36% and 20%, respectively [9, 10]. While most cases of ascending aortic involvement are subject to surgical repair (partially with valve-preserving techniques), aneurysms of the distal arch and descending thoracic aorta are amenable to emerging endovascular techniques as an alternative to classic open repair or to a hybrid approach (combining debranching surgery with stent grafting) in an attempt to improve outcomes.

Endovascular repair

Endovascular treatment of thoracic aortic aneurysms is achieved by transluminal placement of one or more stent-graft devices across the longitudinal extent of the lesion. The prosthesis bridges the aneurismal sac to exclude it from high-pressure aortic blood flow, thereby allowing for sac thrombosis around the stent graft and possible remodelling of the aortic wall (Figure 1). Thoracotomy, aortic cross-clamping, left-heart bypass, and single-lung ventilation are all avoided with an endovascular aortic procedure. The use of stent grafts was first reported by Volodos *et al.* in 1986 in a patient with post-traumatic pseudoaneurysm of the thoracic aorta [11]. With technology proceeding at a fast pace, both custom-designed and commercially available stent grafts are available for treating thoracic aortic disease (Figure 2). By now, several institutions have substantiated both the safety and the effectiveness of stent grafts for the repair of thoracic aortic aneurysms [12-14]. With increasing endovascular experience numerous other aortic diseases, such as aortic dissection, penetrating atherosclerotic ulcers, aortopulmonary fistulas, acute aortic rupture from blunt chest trauma, and mycotic aneurysms, have been investigated as a potential indication for endovascular treatment.

Technique

Currently, there is ongoing controversy over which patients should be treated by endovascular means (Table I). The long-term durability of aortic stent grafts is not yet known, and therefore

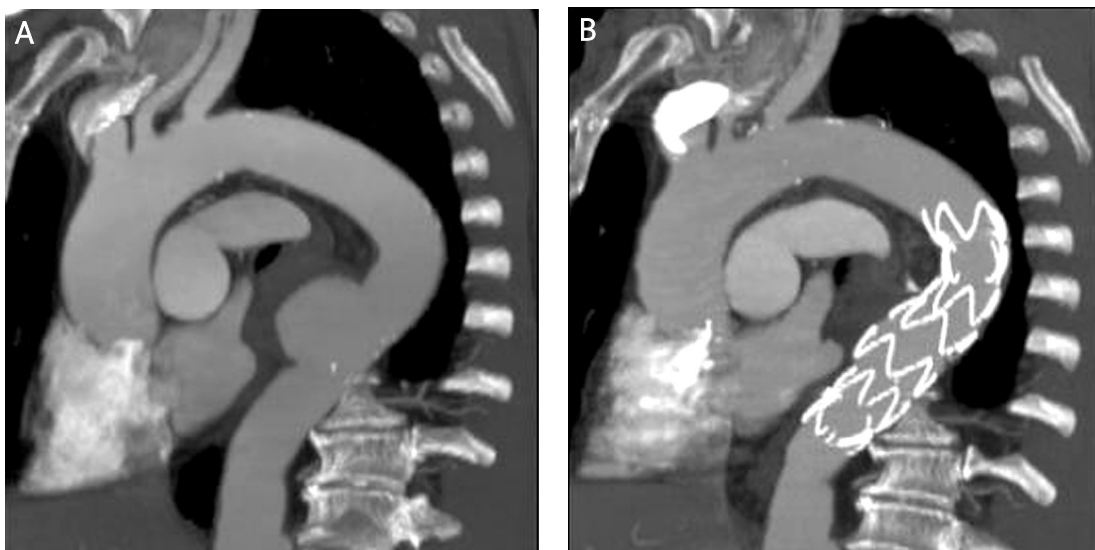


Figure 1. (A) CT angiogram showing a circumscribed aneurysm of the descending thoracic aorta in a middle-aged male patient selected for endografting. (B) 1-year follow-up after successful endovascular exclusion of the aneurysm by stent-graft placement demonstrates marked shrinkage of periprosthesis aneurysm and optimal wall apposition of the stent graft




Figure 2. A selection of thoracic stent grafts currently available for endoluminal repair. Zenith TX2 by Cook Medical (A), TAG by GORE (B); Valiant by Medtronic AVE (C); Relay Thoracic Stent-Graft by Bolton Medical (D); EndoFit by LeMaitre Vascular (E)

cautious patient selection is advocated. The suitability of a given patient for endovascular repair is based on both clinical and anatomical considerations. At present, stent grafts are routinely used to treat patients with thoracic aneurysms distal to the aortic arch. Inoue *et al.* have performed aortic arch reconstructions using transluminally placed endovascular branched stent grafts to treat aneurysms involving the aortic arch. This concept, however, was a failure, with many complications, and was not embraced in the community. Successful TAA exclusion requires normal segments of native aorta at both ends of the lesion of at least 15 mm to 25 mm to ensure adequate launching and contact between the stent graft and the aortic wall with a tight circumferential seal. Devices are oversized by 10% in diameter to provide sufficient radial force for adequate fixation [15]. The preferred and most common site (41-58%) of vascular access is the common femoral artery [16, 17]. Less frequently, access to the iliac artery (9-44%) via an extra-peritoneal approach is required. Retroperitoneal exposure to the abdominal aorta is necessary in 14-30% of cases, especially in small, elderly women [16, 17]. In patients with multiple aortic aneurysms involving both the thoracic and abdominal aorta a combination of conventional abdominal aortic replacement with endovascular stent-graft placement into the thoracic aorta under

fluoroscopic guidance is feasible [18]. Care must be taken not to occlude major arterial branches or to bypass them prior to stent-graft placement. A rational approach to endovascular treatment of aortic aneurysms with a short proximal neck is transposition of the left subclavian artery prior to stent-graft placement. After deployment short inflation of a latex balloon should be performed to improve apposition of the stent struts to the aortic wall. Post-procedurally, both Doppler-ultrasound and contrast fluoroscopy should be performed to document the immediate result. After removing the sheath and guide wire the access sites can be closed in standard surgical fashion.

Hybrid procedures for aortic arch pathologies

The aortic arch morphology is challenging because of angulations and the proximity of the supra-aortic branches, which need to be preserved. Traditional open arch reconstruction using hypothermic cardiac arrest, extracorporeal circulation and selective cerebral perfusion has been demonstrated to effectively manage aortic arch pathologies. However, this current standard procedure for any arch pathology carries significant mortality (2-9%) and risk of paraplegia and cerebral stroke in 4-13% of cases [19]. Therefore, open repair is often reserved for low-risk patients. Hybrid arch procedures (HAP) are a combination of debranching

bypass (supra-aortic vessel transposition) to establish cerebral perfusion and subsequent thoracic endografting to provide patient-centred solutions for complex aortic arch lesions (Figure 3). HAP is performed without hypothermic circulatory arrest and extracorporeal circulation and could expand the treatment group to older patients with severe comorbidities and redo-surgery currently ineligible for open surgical intervention. There are two different hybrid approaches with either extra-anatomic or intrathoracic supra-aortic vessel transposition. To treat distal arch aneurysms involving both the left subclavian and the left common carotid artery, those vessels can be translocated upstream to the right common carotid artery approached via cervical access (hemi-arch debranching) [20]. For arch aneurysms extending to the innominate artery the ascending aorta can be used, via sternotomy, as a donor site to revascularize all three supra-aortic arteries (total arch debranching). The key to success is the quality of the unimpaird ascending aorta as a donor site for the debranching bypass and proximal landing zone for the stent grafts.

Follow-up

When a thoracic aortic aneurysm is first detected its growth rate is not known yet. It is therefore appropriate to obtain a repeated imaging study 6 months after the initial study. If the aneurysm is unchanged in size, it is then reasonable to obtain an imaging study on an annual basis in most cases. In non-Marfan patients and in the absence of acute aortitis, thoracic aortic aneurysms tend to grow slowly and annual imaging is sufficient for surveillance. However, should there be a significant increase in aortic size per year (> 0.5 cm per year), action is required or at least shorter imaging follow-up. Follow-up examinations should be performed at discharge, 6 and 12 months and annually thereafter. Imaging studies include helical CT and 3D reconstruction, or if endotension is suspected, MR angiography is the preferred method of evaluation.

Results from the literature

Primary technical success was generally defined as complete exclusion of the TAA, stent-graft patency, and restoration of normal blood flow immediately after endovascular repair (EVR). Secondary technical success was defined as complete TAA exclusion, graft patency, and restoration of blood flow within 30 days of stent-graft placement. Several studies have reported high success rates with 85% to 100% of procedures in successful deployment and functional exclusion of the aneurysm. Major complications occurred in

Table I. Current indications for endovascular treatment of thoracic aortic disease

Disease aetiology
Aortic aneurysms
Atherosclerotic/degenerative
Post-traumatic
Mycotic
Anastomotic
Cystic medial necrosis
Aortitis
Stanford type B aortic dissection
Acute
Chronic
Giant penetrating ulcer
Traumatic aortic tear
Aortopulmonary fistula
Marfan syndrome
Aneurysm morphology
Aneurysm of the descending aorta
Proximal neck length = 2 cm
< 2 cm if supra-aortic vessels have been transposed prior to stent-graft placement
Distal neck length = 2 cm
Diameter > 6 cm
Patient condition
Preferentially older age
Unfit for open surgical repair or high-risk patients
Chronic obstructive pulmonary disease
Severe coronary heart disease
Severe carotid artery disease
Renal insufficiency
Suitable vascular access site
Life expectancy of more than 6 months

14-18% of patients depending on the acuity at presentation, with very low incidence of paraplegia. In the recent literature, different groups had periprocedural stroke rates of 0% to 7% [17, 21] and incidence rates for paraplegia between 0% and 5% [17, 21-23]. Although low, these rates remain significant, especially because it is impossible to re-implant intercostal arteries in this setting. Endoleak is the Achilles heel of endovascular stent-graft procedures. The rate of endoleak immediately after TAA stent-graft placement has been reported to be between 4% and 24% [23, 24].

Early and late mortality rate ranged from 0 to 14% and is usually attributable to the preoperative status of the patients. Most studies showed

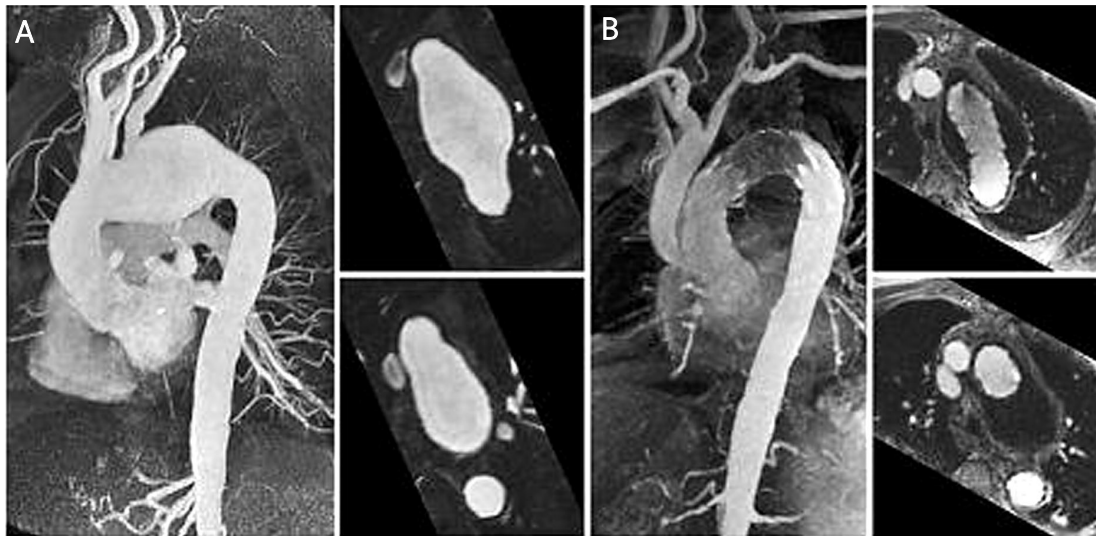


Figure 3. Contrast-medium enhanced MR angiography of the aorta in a case of aortic arch aneurysm. **A** – aneurysm of the aortic arch involving the supra-aortic branches. **B** – post-interventional/surgical result after hybrid procedure with debranching of the supra-aortic vessels and stent-graft implantation in the aortic arch

Table II. Overview of published data regarding endovascular treatment of thoracic aortic aneurysm

Author, year	N	Follow-up [month]	Technical success [%]	30-day mortality [%]	Paraplegia [%]	Endoleak [%]	Long-term survival [%]	Devices
Dake, 1998 [17]	103	22	83	9	3	24	73 (2 years)	Homemade
Ehrlich, 1998 [23]	10	NA	80	10	0	20	NA	Talent
Cartes-Zumelzu, 2000 [24]	32	16	90.6	9.4	3.1	15.4	90.2 (32 months)	Excluder, Talent
Grabenwoger, 2000 [30]	21	NA	100	9.5	0	14.3	NA	Talent, Prograft
Najibi, 2002 [31]	24	12	94.7	5.3	0	0	89.5 (1 year)	Excluder, Talent
Heijmen, 2002 [32]	28	21	96.4	0	0	28.6	96.4 (21 months)	Talent, Excluder
Schoder, 2003 [33]	28	22.7	100	0	0	25	80.2 (3 years)	Excluder
Bell, 2003 [34]	67	17	NA	2	4	4.8	89 (1 year)	Gore, Talent
Lepore, 2003 [35]	21	12	100	9.5	4.8	19	76.2 (1 year)	Excluder, Talent
Ouriel, 2003 [36]	31	6	NA	12.9	6.5	32.3	81.6 (6 months)	Excluder, Talent
Czerny, 2004 [37]	54	38	94.4	9.3	0	27.8	63 (3 years)	Excluder, Talent
Makaroun, 2004 [38]	142	29.6	97.9	1.5	3.5	8.8	75 (2 years)	TAG
Leurs, 2004 [39]	249	32	87	10.4	4	4.2	80.1 (1 year)	Excluder, Talent, Zenith, Endofit
Glade, 2005 [40]	42	15	NA	NA	2	NA	NA	Gore, Talent
Greenberg, 2005 [41]	100	14	NA	NA	1	6	83 (1 year)	Zenith
Riesenmann, 2005 [42]	50	9	96	NA	0	10	79.4 (1 year)	Talent
Ricco, 2006 [43]	166	NA	NA	5	3.6	16.2	NA	Gore, Talent
Wheatley, 2006 [44]	156	21.5	98.7	3.8	0.6	11.5	76.6 (1 year)	Gore
Bavaria, 2007 [45]	140	24	98	2.1	2.9	10	NA	Gore
Qu, 2008 [46]	46	15.2	100	9.2	3.4	5.8	88.5 (2 years)	EndoFit
Ting, 2009 [47]	24	21	98	NA	0	NA	75 (2 years)	AneuRx, Talent, Zenith, Excluder

a patient survival rate of 70-80% at 1, 3 and 5 years. (Table II) [17, 21-47]. Data from 457 patients treated with stent grafts and collected in a registry (113 emergency and 344 elective cases) revealed that among 422 patients who survived the interventional procedure (in-hospital mortality 5%), mortality during follow-up was 8.5% (36 patients), of which 11 patients had died from the aortic disease; persistent endoleak was reported in 64 cases, of which 44 were primary (9.6%) and 21 occurred during follow-up (4.9%) [25]. Kaplan-Meier overall survival estimate at 1, 3 and 5 years was 90.9%, 85.4% and 77.5%. At the same intervals, freedom from a second procedure (either open conversion or endovascular) was 92.5%, 81.3%, and 70.0%, respectively [25]. At Stanford University first-generation thoracic aortic grafting was performed in 103 patients from 1992 to 1997. Of these patients, 60% were deemed unsuitable for open standard aortic replacement [26]. The average diameter of the aneurysms was 6 cm (range 4-11 cm), and the length varied from 1 cm in post-traumatic aneurysm to 22 cm. In 8 patients a preoperative subclavian-to-carotid bypass or transposition was performed to allow the orifice of the subclavian artery to be covered with the stent graft without obstructing flow to the arm. The mortality rate in this pioneering study was 9%, with a 3% incidence of paraplegia. Complete exclusion of the aneurysm occurred in 84% of patients and endoleaks were observed in 25 patients (24%); these were subsequently successfully treated in 11 patients by a combination of overstenting and coiling. The survival rate was 81% at 1 year and 73% at 2 years. Late rupture occurred in 2% of patients at 22-month average follow-up [26]. A 6-year prospective case series involving 84 patients was completed by Ellozy *et al.* [29]. Primary technical success was achieved in 90%, and successful exclusion of the aneurysm was achieved in 82%. However, major procedure-related or device-related complications occurred in 38%, including proximal attachment failure (8%), distal attachment failure (6%), mechanical device failure (3%), periprocedural death (6%), and late aneurysm rupture (6%). More encouraging was the fact that only 3% suffered persistent neurological complications [29].

For aneurysm disease encompassing the descending thoracic aorta and in selected cases the distal aortic arch, use of endovascular stent grafts for repair of suitable anatomical conditions is a promising, non-surgical alternative; however, morphology and graft sizing are paramount in case selection.

References

1. Crawford ES, DeNatale RW. Thoracoabdominal aortic aneurysms: observations regarding the natural course of the disease. *J Vasc Surg* 1986; 3: 578-82.
2. Lilienfeld DE, Gunderson PD, Sprafka JM, Vargas C. Epidemiology of aortic aneurysms. Mortality trends in the United States, 1951 to 1981. *Arteriosclerosis* 1987; 7: 637-43.
3. Clouse WD, Hallett JW, Schaff HV, Gayari MM, Ilstrup DM, Melton LJ 3rd. Improved prognosis of thoracic aortic aneurysms: a population-based study. *JAMA* 1998; 280: 1926-9.
4. Svenjo S, Bengtsson H, Bergqvist D. Thoracic and thoraco-abdominal aortic aneurysm and dissection: an investigation based on autopsy. *Br J Surg* 1996; 83: 68-71.
5. Thomson MM, Bell PR. ABC of arterial and venous disease: arterial aneurysms. *BMJ* 2000; 320: 1193-6.
6. Panneton JM, Hollier LH. Nondissecting thoracoabdominal aortic aneurysms: Part I. *Ann Vasc Surg* 1995; 9: 503-14.
7. Davies RR, Goldstein LJ, Coady MA, et al. Yearly rupture or dissections rate for thoracic aortic aneurysms: simple prediction based on size. *Ann Thorac Surg* 2002; 73: 17-27.
8. Eleftriades JA. Natural history of thoracic aneurysms: indications for surgery, and surgical versus nonsurgical risk. *Ann Thorac Surg* 2002; 74: S1877-80.
9. Coady MA, Rizzo JA, Goldstein LJ, Eleftriades JA. Natural history, pathogenesis, and etiology of thoracic aortic aneurysms and dissection. *Cardiol Clin* 1999; 17: 615-35.
10. Cronenwett JL, Murphy TF, Zelenock GB, et al. Actuarial analysis of variables associated with rupture of small abdominal aortic aneurysms. *Surgery* 1985; 98: 472-83.
11. Volodos NL, Karpovich IP, Troyan VI. Clinical experience of the use of self-fixing synthetic prostheses for remote endoprosthetics of the thoracic and the abdominal aorta and iliac arteries through the femoral artery and as intraoperative endoprosthesis for aorta reconstruction. *Vasa Suppl* 1991; 33: 93-5.
12. Dake MD, Miller DC, Semba CP, Mitchell RS, Walker PJ, Liddell RP. Transluminal placement of endovascular stent-grafts for the treatment of descending thoracic aneurysms. *N Engl J Med* 1994; 33: 1729-34.
13. Mitchell RS, Dake MD, Semba CP, et al. Endovascular stent-graft repair of thoracic aortic aneurysms. *J Thorac Cardiovasc Surg* 1996; 111: 1054-62.
14. Kato M, Ohnishi K, Kaneko M, et al. A new graft-implanting method for thoracic aortic aneurysm or dissection with a stent-graft. *Circulation* 1996; 94: 188-93.
15. Akin I, Ince H, Kische S, Nienaber CA. Implication of thoracic aortic stent-graft conformability on clinical outcome. *Acta Chir Belg* 2009; 109: 20-6.
16. Ince H, Nienaber CA. Etiology, pathogenesis and management of thoracic aortic aneurysms. *Nat Clin Pract Cardiovasc Med* 2007; 4: 418-27.
17. Dake MD, Miller DC, Mitchell RS, Semba CP, Moore KA, Sakai T. The "first generation" of endovascular stent-grafts for patients with aneurysms of the descending thoracic aorta. *J Thorac Cardiovasc Surg* 1998; 116: 689-703.
18. Moon MR, Mitchell RS, Dake MD, Zarins CK, Fann JJ, Miller DC. Simultaneous abdominal aortic replacement and thoracic stent-graft placement for multilevel aortic disease. *J Vasc Surg* 1997; 25: 332-40.
19. Nakai M, Shimamoto M, Yamazaki F, et al. Long-term results after surgery for aortic nondissection aneurysm. *Kyobu Geka* 2002; 55: 280-4.
20. Kische S, Akin I, Ince H, Rehders TC, Ortak J, Nienaber CA. Stent-graft repair in acute and chronic diseases of the thoracic aorta. *Rev Esp Cardiol* 2008; 61: 1070-86.
21. Fattori R, Napoli G, Lovato L, et al. Descending thoracic aortic diseases: stent-graft repair. *Radiology* 2003; 229: 176-83.

22. Cambria RP, Brewster DC, Lauterbach SR, et al. Evolving experience with thoracic aortic stent-graft repair. *J Vasc Surg* 2002; 35: 1129-36.
23. White RA, Donayre CE, Walot I, et al. Endovascular exclusion of descending thoracic aortic aneurysms and chronic dissections: initial clinical results with the AneuRx device. *J Vasc Surg* 2001; 33: 927-34.
24. Greenberg R, Resh T, Nyman U, et al. Endovascular aortic repair of descending thoracic aortic aneurysms: an early experience with intermediate-term follow-up. *J Vasc Surg* 2000; 31: 147-56.
25. Fattori R, Nienaber CA, Rousseau H, et al. Talent Thoracic Retrospective Registry. Results of endovascular repair of the thoracic aorta with the Talent Thoracic stent graft: the Talent Thoracic Retrospective Registry. *J Thorac Cardiovasc Surg* 2006; 132: 332-9.
26. Mitchell RS, Miller DC, Dake MD, Semba CP, Moore KA, Sakai T. Thoracic aortic aneurysm repair with an endovascular stent graft: the "first generation". *Ann Thorac Surg* 1999; 67: 1971-4.
27. Ehrlich M, Grabenwoeger M, Cartes-Zumelzu F, et al. Endovascular stent-graft repair for aneurysms on the descending thoracic aorta. *Ann Thorac Surg* 1998; 66: 19-24.
28. Cartes-Zumelzu F, Lammer J, Kretschmer G, et al. Endovascular repair of thoracic aortic aneurysms. *Semin Interv Cardiol* 2000; 5: 53-7.
29. Ellozy SH, Carroccio A, Minor M, et al. Challenges of endovascular tube graft repair of thoracic aortic aneurysm: midterm follow-up and lesson learned. *J Vasc Surg* 2003; 38: 676-83.
30. Grabenwöger M, Hutschala D, Ehrlich MP, et al. Thoracic aortic aneurysm: treatment with endovascular self-expandable stent grafts. *Ann Thorac Surg* 2000; 69: 441-5.
31. Najibi S, Terramani TT, Weiss VJ, et al. Endoluminal versus open treatment of descending thoracic aortic aneurysms. *J Vasc Surg* 2002; 36: 732-7.
32. Heijmen RH, Deblieck IG, Moll FL, et al. Endovascular stent-grafting for descending thoracic aortic aneurysms. *Eur J Cardiothorac Surg* 2002; 21: 5-9.
33. Schoder M, Cartes-Zumelzu F, Grabenwoeger M, et al. Elective endovascular stent-graft repair of atherosclerotic thoracic aortic aneurysms: Clinical results and midterm follow-up. *Am J Roentgenol* 2003; 180: 709-15.
34. Bell RE, Taylor PR, Aukett M, et al. Mid-term results for second-generation thoracic stent-grafts. *Br J Surg* 2003; 90: 811-7.
35. Lepore V, Lonn L, Delle M, et al. Treatment of descending thoracic aneurysms by endovascular stent grafting. *J Card Surg* 2003; 18: 416-23.
36. Ouriel K, Greenberg RK. Endovascular treatment of thoracic aortic aneurysms. *J Card Surg* 2003; 18: 455-63.
37. Czerny M, Cejna M, Hutschala D, et al. Stent-graft placement in atherosclerotic descending thoracic aortic aneurysms: Midterm results. *J Endovasc Ther* 2004; 11: 26-32.
38. Makaroun MS, Dillavou ED, Kee ST, et al. Endovascular treatment of thoracic aortic aneurysms: Results of the phase II multicenter trial of the GORE TAG thoracic endoprosthesis. *J Vasc Surg* 2005; 41: 1-9.
39. Leurs LJ, Bell R, Degrieck Y, et al. Endovascular treatment of thoracic aortic disease: Combined experience from the EUROSTAR and United Kingdom Thoracic Endograft registries. *J Vasc Surg* 2004; 40: 670-9.
40. Glade GJ, Vahl AC, Wisselink W, et al. Mid-term survival and cost of treatment of patients with descending thoracic aortic aneurysms; endovascular versus open repair: a case-control study. *Eur J Vasc Endovasc Surg* 2005; 29: 28-34.
41. Greenberg RK, O'Neill S, Walker E, et al. Endovascular repair of thoracic aortic lesions with the Zenith TX1 and TX2 thoracic grafts; intermediate-term results. *J Vasc Surg* 2005; 41: 589-96.
42. Riesenman PJ, Farber MA, Mendes RR, et al. Endovascular repair of lesions involving the descending thoracic aorta. *J Vasc Surg* 2005; 42: 1063-74.
43. Ricco JB, Cau J, Marchand C, et al. Stent-graft repair for thoracic aortic disease: results of an independent nationwide study in France from 1999 to 2001. *J Thorac Cardiovasc Surg* 2006; 131: 131-7.
44. Wheatley GH III, Gurbuz AT, Rodriguez-Lopez JA, et al. Midterm outcome in 158 consecutive Gore TAG thoracic endoprotheses: single center experience. *Ann Thorac Surg* 2006; 81: 1570-7.
45. Bavaria JE, Appoo JJ, Makaroun MS, et al. Endovascular stent-grafting versus open surgical repair of descending thoracic aortic aneurysms in low-risk patients: a multicenter comparative trial. *J Thorac Cardiovasc Surg* 2007; 133: 369-77.
46. Qu L, Raihel D. Two-year single-center experience with thoracic endovascular repair with the EndoFit thoracic stent-graft. *J Endovasc Ther* 2008; 15: 530-8.
47. Ting AC, Cheng SW, Ho P, et al. Endovascular repair for thoracic aortic pathologies – early and midterm results. *Asian J Surg* 2009; 32: 39-46.