

# Absence of superficial palmar arch with associated anomaly of ulnar artery and nerve: a case report with clinical implications

---

Shipra Paul, Srijit Das

Department of Anatomy, Maulana Azad Medical College, New Delhi, India

**Submitted:** 12 October 2006

**Accepted:** 5 March 2007

Arch Med Sci 2007; 3, 1: 79-81

Copyright © 2007 Termedia & Banach

**Corresponding author:**

Prof. Shipra Paul, MBBS, MD

FIMSA, MINAMS

D-II/A-75, Nanak Pura

Moti Bagh South

New Delhi 110021, India

Phone: 91 11 261 197 51

E-mail: drshipra14@yahoo.com

## Abstract

Normally the ulnar artery and the ulnar nerve pass superficial to the flexor retinaculum of the wrist. In the present study, we describe an ulnar artery and ulnar nerve which passed deep to the flexor retinaculum and an absent superficial palmar arch. Abnormal course of ulnar nerve and ulnar artery passing deep to the flexor retinaculum with absence of a characteristic superficial palmar arch is a rare finding. The ulnar vessels and nerves when passing deep to the flexor retinaculum are vulnerable to compression and may be important for clinicians diagnosing compressive neuropathies and surgeons operating on the wrist.

**Key words:** ulnar artery, nerve, course, anomaly, variation, flexor retinaculum.

---

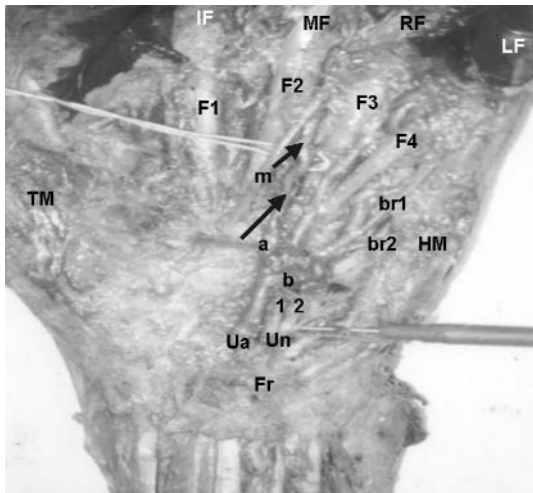
## Introduction

The flexor retinaculum, a strong fibrous band, lies in front of the carpus and converts it into an osseoponeurotic tunnel. The tendon of the palmaris longus, the palmar cutaneous branch of the median nerve, the ulnar vessels, the ulnar nerve and its palmar cutaneous branch cross superficial to it [1]. The superficial part of the flexor retinaculum forms Guyon's canal through which the ulnar nerve passes and may undergo compression [1].

The ulnar artery crosses superficial to the flexor retinaculum, medial to the pisiform bone, and thereby takes a curve laterally to form the superficial palmar arch which may be completed in one third of cases by a superficial branch from the radial artery or a branch from the arteria radialis indicis [1]. The superficial palmar arch has been reported to have numerous variations and may be absent [2]. Gellman et al., 2001, reported 84.4% incidence of existence of the superficial palmar arch [3]. Ulnar artery and ulnar nerve passing deep to the flexor retinaculum along with absence of usual superficial palmar arch, as seen in the present case, is a rare finding which may result in compression and occupational injuries. Surgeons operating on the hand should be aware of such anomalies in order to check any inadvertent injury.

## Case report

During routine dissection of cadavers for undergraduate medical teaching we detected anomalous arrangement of the neurovascular structures in relation to the flexor retinaculum. The structures were carefully dissected and the specimen was photographed (Figure 1).



**Figure 1.** Photograph of dissected left palm showing:

- Fr:** Flexor retinaculum
- Un:** Ulnar nerve
- Ua:** Ulnar artery
- 1 & 2:** Two branches from ulnar nerve
- a & b:** Two branches from ulnar artery
- br1:** Branch to little finger
- br2:** Branch to hypothenar muscles
- m:** Median nerve
- HM:** Hypothenar muscles
- TM:** Thenar muscles
- If:** Index finger
- RF:** Ring finger
- MF:** Middle finger
- RF:** Ring finger
- LF:** Little finger

The flexor tendons are numbered F1, F2, F3, F4.

The tortuosity of the ulnar artery is shown with arrows (^)

The ulnar artery and ulnar nerve had a course deep to the flexor retinaculum. On careful observation, we found that a proper superficial palmar arch was absent except for a small contribution from a branch of the radial artery.

The ulnar artery was tortuous and at the distal border of the flexor retinaculum divided into medial and lateral branches. The lateral branch traversed along the radial side of the ring finger with the flexor tendon of the same finger on its medial side, accompanied by a branch of the median nerve. The tortuosity of the vessel was obvious. The medial thicker branch turned medially for a short horizontal course, then turned distally along the medial border of the little finger, itself being crossed by a branch of the ulnar nerve. The thickness and tortuosity remained the same throughout its course.

The ulnar nerve passed deep to the flexor retinaculum, lying medial to the ulnar artery. The ulnar nerve divided at the distal border of the flexor retinaculum into lateral and medial divisions. The medial division again divided into two branches. A lateral thicker branch gave cutaneous branches to the medial one and half digits and a medial thinner branch supplied the hypothenar muscles.

## Discussion

Classically, the ulnar nerve enters the palm through Guyon's canal, a common site for entrapment neuropathy [1]. Recent studies on the arborization patterns of the ulnar artery in Guyon's canal have also investigated the relationship between the hypothenar muscles and ulnar artery [4]. Konig et al., 1994, described the division of the ulnar nerve into three branches before entering Guyon's canal, with one of the branches passing deep to the flexor retinaculum, similar to that observed in the present case [5].

Variations of the superficial palmar arch are quite frequent [6]. Only 85-90% of cases have a complete superficial palmar arch [3]. Interestingly, in 52% of cases the palmar arterial patterns were observed by Doppler ultrasonic flow meter and were found to be different between the hands of the same person [7]. The incidence of such variations of the superficial palmar arch makes it more important for any academic and clinical purpose.

In the present case, the superficial palmar arch had a small contribution from the radial artery through the 1<sup>st</sup> dorsal interosseous space. The use of the radial artery as an arterial conduit for coronary angiography is becoming more popular day by day. It poses great risk of ischaemia of the soft tissues of the hand [8]. Thus a thorough anatomical knowledge of the variations of the superficial palmar arch may be clinically important for vascular surgeons.

The ulnar nerve deep to the flexor retinaculum can be detected by sonographic studies [9]. Any nerve compression needs proper understanding of the topographical anatomy of the ulnar nerve in relation to the flexor retinaculum. Variations of the ulnar nerve and its course may often confuse operating surgeons and radiologists interpreting sonograms of the wrist. There are reports of development of painful neuromas of the ramus communicans (the communicating branch of the ulnar and sensory branches) developing as a result of inadvertent injury during carpal tunnel release procedures [10, 11].

## Conclusions

To summarize, we report the absence of a superficial palmar arch which was not completely formed with the ulnar artery and the ulnar nerve passing deep to the flexor retinaculum. The unusual arrangement of the neurovascular structures in relation to the flexor retinaculum may be of great significance for hand surgeons, clinicians and radiologists.

## References

1. Standring S (ed.). Gray's Anatomy: The Anatomical Basis of Clinical Practice. 39<sup>th</sup> ed. Elsevier Churchill Livingstone, New York 2005.

2. Tcacencu I. A rare human variation: a major branch of the ulnar artery found in the carpal tunnel. *Surg Radiol Anat* 2001; 23: 359-60.
3. Gellman H, Botte MJ, Shankwiler J, Gelberman RH. Arterial patterns of the deep and superficial palmar arches. *Clin Orthop Relat Res* 2001; 383: 41-6.
4. Murata K, Tamai M, Gupta A. Anatomic study of arborization patterns of the ulnar artery in Guyon's canal. *J Hand Surg [Am]* 2006; 31: 258-63.
5. Konig PS, Hage JJ, Bloem JJ, Prose LP. Variations of the ulnar nerve and ulnar artery in Guyon's canal: a cadaveric study. *J Hand Surg [Am]* 1994; 19: 617-22.
6. Onderoglu S, Basar R, Erbil KM, Cumhuri M. Complex variation of the superficial palmar arch – case report. *Surg Radiol Anat* 1997; 19: 123-5.
7. Al-Turk M, Metcalf WK. A study of the superficial palmar arteries using the Doppler Ultrasonic Flowmeter. *J Anat* 1984; 138: 27-32.
8. Loukas M, Holdman D, Holdman S. Anatomical variations of the superficial and deep palmar arches. *Folia Morphol (Warsz)* 2005; 64: 78-83.
9. Lee JC, Healy JC. Normal sonographic anatomy of the wrist and hand. *Radiographics* 2005; 25: 1577-90.
10. May JW Jr, Rosen H. Division of the sensory ramus communicans between the ulnar and median nerves: a complication following carpal tunnel release. A case report. *J Bone Joint Surg Am* 1981; 63: 836-8.
11. Das S, Paul S, Mandal AK. Anomalous musculoskeletal morphology of anterior chest wall: a case report. *Arch Med Sci* 2006; 2, 4: 289-91.