

Rhabdomyolysis following severe hypokalemia caused by Conn's syndrome

Anna Gonerska-Szadkowska¹, Joanna Witych-Długosz², Jacek Makarewicz¹, Mirosław Szmidt², Andrzej Lewiński³

¹Department of Nuclear Medicine and Oncological Endocrinology, Chair of Endocrinology and Metabolic Diseases, Medical University, Lodz, Poland

²Department of Internal Medicine and Allergology, Medical University, Lodz, Poland

³Department of Endocrinology and Metabolic Diseases, Medical University, Lodz, Poland

Submitted: 20 April 2007

Accepted: 28 August 2007

Arch Med Sci 2007; 3, 3: 274-277

Copyright © 2007 Termedia & Banach

Corresponding author:

Prof. Andrzej Lewiński, MD, PhD

Chair and Department of Endocrinology and Metabolic Diseases

Medical University of Lodz

Polish Mother's Memorial

Hospital-Research Institute

Rzgowska St. No. 281/289

93-338 Lodz, Poland

Phone: +48 42 271 17 15

Fax: +48 42 271 13 43

E-mail: alewin@csk.umed.lodz.pl

Abstract

Rhabdomyolysis denotes a clinical and laboratory syndrome that results from a rapid breakdown of skeletal muscle cells. This releases potentially toxic muscle cell components into the circulation which may cause life-threatening complications including myoglobinuric acute renal failure, cardiac arrest or disseminated intravascular coagulation. During rhabdomyolysis the injured muscle leaks potassium leading to hyperkalemia. In primary aldosteronism, mineralocorticoid activity leads to hypokalemia which can be severe enough to cause rhabdomyolysis. We report an unusual case of rhabdomyolysis with hypokalemia due to Conn's syndrome.

Key words: rhabdomyolysis, hypokalemia, Conn's syndrome.

Introduction

Rhabdomyolysis denotes a clinical and laboratory syndrome that results from a rapid breakdown of skeletal muscle cells. This releases potentially toxic muscle cell components into the circulation which may cause life-threatening complications including myoglobinuric acute renal failure, cardiac arrest or disseminated intravascular coagulation. As rhabdomyolysis develops, the injured muscles leak potassium. When combined with renal failure, this can lead to hyperkalemia. Rhabdomyolysis can result from damage to muscles following mechanical, physical or chemical insults, among which hypokalemia is one of the less common.

Conn's syndrome is characterized by excessive aldosterone production, due to either adrenal gland adenoma or hyperplasia of the gland [1]. Hyperaldosteronism causes retention of sodium, followed by increased intravascular volume, increased potassium urine excretion and the suppression of renin activity. Although hypokalemia is usually mild it may sometimes be life threatening, as it can cause cardiac arrhythmias. Renal and muscular dysfunction may also occur.

We report, an unusual case of rhabdomyolysis caused by severe hypokalemia, which in turn was the result of long-lasting, untreated Conn's syndrome.

Case report

A 50-year-old woman was admitted to the Department of Internal Medicine and Allergology complaining of muscular weakness involving predominantly her thighs, calves and arms. This progressed to paralysis, involving all the extremities. Beside severe weakness, the patient also had myalgia, muscle cramps and stiffness. The symptoms had appeared five days prior to admission, without any history of alcohol abuse, drugs ingestion, viral infection or trauma. A year previously, the patient had had similar symptoms which had resolved after an unknown treatment. The patient had been treated with amlodipine for arterial hypertension for four years. There was no the relevant history. On examination, the patient was pale and afebrile. She was hypertensive with a blood pressure of 180/70 mmHg. The patient had weakness of proximal muscles in both thighs (3/5 Medical Research Council scale), the hip flexors (3/5), the extensors of the both knee (4/5) and the flexors of the ankle (3/5 on the right and 4/5 on the left). Laboratory investigations demonstrated severe hypokalemia with a metabolic alkalosis and markedly elevated creatine phosphokinase (Table I). Urinary excretion of potassium was elevated. The patient's urine was negative for hemoglobin. Other results, including total blood count and renal function tests, were normal.

Based on the severe myalgia, muscle weakness and marked elevation of serum CK (creatine phosphokinase) and CK-MB (creatine phosphoki-

nase muscle brain), rhabdomyolysis – resulting probably from hypokalemia – was diagnosed.

An infusion of KCl, initially at 120 mmol/day, and then 80 mmol/day was applied. Spironolactone was started at of 200 mg/day. Her plasma potassium concentration normalized and hypertension resolved. Following dexamethasone being given at 8 mg/day followed by prednisone at 60 mg/day, her muscle pain completely resolved.

Histological examination of the quadriceps muscle performed on the day 20, was normal.

Severe hypokalemia and hypertension suggested primary hyperaldosteronism. That suspicion was confirmed by an elevated aldosterone level with suppressed serum renin concentration. After stimulation with furosemide (40 mg, orally) and 4 hours of upright position, plasma renin concentration increased to 3.3 pg/mL, whereas aldosterone level fell to 16.7 ng/dL (Table II).

Abdominal ultrasound revealed a tumour of 17 mm in diameter, localized in the right adrenal gland. CT scan confirmed the presence of an oval, hypodense lesion, 17×19 mm, with contrast enhancement up to 33 HU (Hounsfield Unit) with a fast loss of contrast (Figure 1).

After blood pressure reduction and normalisation of the serum potassium concentration the patient was subjected to surgery. A total right adrenalectomy was performed. Microscopic examination of surgical specimens revealed nodular hyperplasia of the right adrenal gland.

The patient is currently asymptomatic one year after the operation with a normal blood pressure

Table I. The major biochemical abnormalities

Laboratory test	Value	Normal range
Serum potassium (K ⁺)	1.95 mmol/l	3.5-5.5 mmol/l
Serum creatine phosphokinase (CPK)	9546 U/l	5-167 U/l
CPK-MB isoenzyme	247.6 U/l	5-24 U/l
Alanine transaminase (ALT)	78 U/l	5-31
Aspartate transaminase (AST)	278 U/l	5-32
pH	7.53	7.35-7.45
BE	12.7	(-)2.5-(+)2.5
Potassium urinary excretion (24 h)	40.43 mmol/24 h	11-32 mmol/24 h

Table II. Basic and stimulated aldosterone levels and plasma renin concentration

Laboratory test	Value	Normal range
Aldosterone (ZenTech, Angleur, Belgium)	62.2 ng/dl	1-16 ng/dl
Renin (DSL, Webster, Tex., USA)	0.3 pg/ml	2.4-21.9 pg/ml
Aldosterone after furosemide	16.7 ng/dl	
Renin after furosemide	3.3 pg/ml	

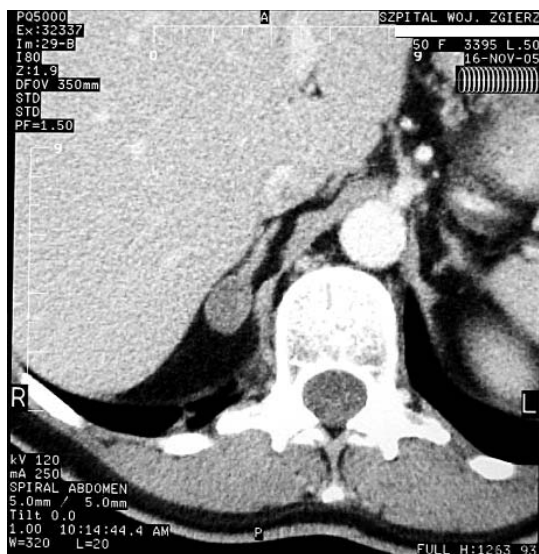


Figure 1. CT scan with right adrenal gland tumour

and normal serum potassium level on a low dose of spironolactone (25 mg/d).

Discussion

Rhabdomyolysis is a relatively common disorder which may result from a large variety of diseases, that damage skeletal muscles [2-4]. Hereditary conditions which can set off rhabdomyolysis include; enzyme deficiencies affecting carbohydrate metabolism and mitochondrial lipid metabolism [5], malignant hyperthermia [5, 6] and the neuroleptic malignant syndrome [7]. Acquired causes of rhabdomyolysis include: toxins (alcohol, drugs, other toxins), excessive muscle exercise (military training, epileptic state, asthmatic state, convulsions, prolonged myoclonus, acute dystonia), direct muscle injury (crush, freezing), ischemic injury (compression, vascular occlusion), metabolic disorders (diabetic ketoacidosis, nonketototic hyperosmolar coma, hypothyroidism, thyrotoxicosis, hypophosphatemia, hyponatremia, hypokalemia), infections (bacterial, viral), heat stroke and inflammatory myopathies (polymyositis, dermatomyositis) [3].

Although the causes of rhabdomyolysis are diverse, they ultimately lead to muscle necrosis and the release of muscle components into the circulation.

The main clinical symptoms of rhabdomyolysis include: muscle pain, weakness, and tenderness of the calves and the lower back. Some patients however are completely asymptomatic.

The primary diagnostic indicator of rhabdomyolysis is an elevated CK level to, at least, five times of the upper normal value [3]. Clinical features are often nonspecific, and a tea-coloured urine caused by myoglobinuria is, sometimes, the first symptom of rhabdomyolysis. As myoglobin is released into the circulation from necrotic muscle

cells, it becomes detectable in urine and induces visible pigmenturia (classically, "coca-cola" coloured urine) at concentrations above 250 ng/ml [10]. When massive amounts of myoglobin are released, the binding capacity of the plasma protein is exceeded. Myoglobin is then filtered by the glomeruli and reaches the tubules, where it may cause obstruction and renal dysfunction [8]. In our case, testing for myoglobin levels in blood and urine was not performed, but its substitute – urine hemoglobin dipstick – was negative.

Other important biochemical findings in rhabdomyolysis include hyperkalemia [3] and a high anion gap acidosis as a consequence of the release of organic acids from necrotic muscles [11]. In our case, a less typical hypokalemic alkalosis was found which raised the suspicion of primary aldosteronism.

Histological picture of muscles affected by rhabdomyolysis usually shows necrosis of scattered muscle cells, pale and hyaline cytoplasm and foci of atrophied fibres [12]. Normal pathological findings in our patient can probably be explained by the relatively benign course of the illness and the long time period from the onset of the disease.

Primary aldosteronism is characterized by aldosterone overproduction and suppressed plasma renin activity. Mineralocorticoid activity of aldosterone leads to hypokalemia which infrequently, is severe enough to cause rhabdomyolysis.

Hypokalemia-induced rhabdomyolysis may be the result of impairment of the physiological vasodilatory effects mediated by the local release of potassium by skeletal muscle cells. The final result is an increased cellular permeability to sodium ions, due to either plasma membrane disruption or to reduced cellular energy (ATP) production [2]. Sodium accumulation in the cytoplasm leads to increased intracellular calcium levels [3]. Depletion of ATP also directly contributes to calcium accumulation, due to reduction in the activity of the Ca^{+2} -ATPase. The common pathogenetic feature of rhabdomyolysis causing processes is an acute rise of cytosolic and mitochondrial calcium concentrations. This ultimately leads to activation of degradative enzymes, such as phospholipase A_2 and natural proteases, inducing myofibril damage [4].

Hypokalemic paralysis should be considered in any patient, presenting with a sudden onset of areflexic, pure motor weakness, involving one or more limbs, without alteration in the level of consciousness [13]. The following diseases ought to be considered in the differential diagnosis of rhabdomyolysis with accompanying hypokalemia: familiar periodic paralysis, thyrotoxic periodic paralysis, thyrotoxic periodic paralysis, renal disorders (water intoxications, nephrotic syndrome, diuretic

phase of acute tubular necrosis, Liddle's syndrome, Bartter's syndrome), pseudohyperaldosteronism induced by glycyrrhizic acid, barium poisoning. Hypokalemic paralysis may be associated also with gastrointestinal disorders, such as acute gastroenteritis, coeliac disease, tropical sprue and malabsorption, due to short bowel syndrome. Liddle's syndrome differs from primary hyperaldosteronism in that a low plasma aldosterone concentration is typically present. Chronic ingestion of liquorice induces a syndrome with findings similar to those of primary hyperaldosteronism. This syndrome is characterized by sodium retention, hypertension, hypokalemia and metabolic alkalosis but, both, plasma renin activity and aldosterone levels are below the level of normal. Bartter's syndrome is characterized by elevated urinary excretion of potassium, metabolic alkalosis and polyuria. Blood pressure is usually normal but plasma renin activity and aldosterone levels are both elevated.

Conclusions

Despite rhabdomyolysis as a result of hypokalaemia caused by Conn's syndrome being rare, the latter should be considered, when severe hypokalemia, atypical for rhabdomyolysis from other causes, is detected.

References

1. Conn JW, Louis LH. Primary aldosteronism: a new clinical entity. *Trans Assoc Am Physicans* 1955; 68: 215-31.
2. Knochel JP. Mechanisms of rhabdomyolysis. *Curr Opin Rheumatol* 1993; 5: 725-31.
3. Polels PJE, Gabreëls FJ. Rhabdomyolysis: a review of the literature. *Clin Neurol Neurosurg* 1993; 95: 175-92.
4. Zager RA. Rhabdomyolysis and myohemoglobinuric acute renal failure. *Kidney Int* 1996; 49: 314-26.
5. Brumback RA, Feeback DL, Leech RW. Rhabdomyolysis in childhood. A primer on normal muscle function and selected metabolic myopathies characterized by disordered energy production. *Pediatr Clin North Am* 1992; 39: 821-58.
6. Gronert GA. Malignant Hyperthermia. In: Engel AG, Banker BQ (eds). *Myology*. Vol 2. New York, McGraw-Hill 1986; 1763-84.
7. Guzé BH, Baxter LR Jr. Current concepts. Neuroleptic malignant syndrome. *N Engl J Med* 1985; 313: 163-6.
8. Ward MM. Factors predictive of acute renal failure in rhabdomyolysis. *Arch Intern Med* 1988; 148: 1553-7.
9. Dayer-Berenson L. Rhabdomyolysis: a comprehensive guide. *ANNA J* 1994; 21: 15-8.
10. Penn AS. Myoglobinuria. In: Engel AG, Banker BQ (eds). *Myology*, Vol. 2. New York, McGraw-Hill 1986: 1785-805.
11. Gabow PA, Kaehny WD, Kelleher SP. The spectrum of rhabdomyolysis. *Medicine* 1982; 61: 141-52.
12. Prat G, Petrognani R, Diatta B, Dufau JP, Theobald X. Hypokalemia causing rhabdomyolysis and precordialgia. *Intensive Care Med* 2001; 27: 1096.
13. Ahlawat SK, Sachdev A. Hypokalaemic paralysis. *Postgrad Med J* 1999; 75: 193-7.