

# Computed tomography for detection of vulnerable coronary plaque – A Cassandra’s dream?

Maksymilian P. Opolski, Cezary Kęпка, Witold Rużyłto

Institute of Cardiology, Warsaw, Poland

Postęp Kardiol Inter 2014; 10, 3 (37): 147–152  
DOI: 10.5114/pwki.2014.45139

The majority of acute coronary syndromes occur without warning due to rupture of coronary atherosclerotic plaques. Coronary lesions prone to rupture reveal several high-risk features that can be identified before the development of devastating clinical events, using modern imaging modalities. Recent advances in coronary computed tomography angiography (CCTA) allow the identification, quantification, and risk stratification of coronary plaques. Unquestionably, attempts to identify high-risk plaques by CCTA provide a unique opportunity to implement targeted preventive measures and improve prognosis. This review highlights insights into the ability of CCTA for the identification of vulnerable plaque and prediction of future coronary events that might affect future diagnosis and management of coronary artery disease.

## The concept of vulnerable plaque

The concept of vulnerable plaque is based on the premise that certain coronary plaques are more prone to disruption or thrombosis than others, leading to a symptomatic acute coronary event [1]. Histological investigations have revealed two main features of coronary plaques associated with acute thrombus formation, i.e. plaque rupture (in about 70% of cases) and plaque erosion (in about 30% of cases) [1, 2]. Ruptured plaques are characterised by a large lipid pool of cholesterol-rich necrotic core covered by a thin layer of fibrous cap infiltrated with macrophages and T-lymphocytes. These plaques are supplied by an abundant vasa vasorum penetrating into the plaque intima from the adventitia [2]. Conversely, the more infrequent plaque erosion is characterised by an absent or disrupted endothelial lining and greater proliferation of smooth muscle than inflammatory cells. Of note, plaque erosions often lack the large lipid pool and/or thin fibrous cap, and appear to be more common in younger women [2].

It is assumed that plaques vulnerable to rupture share the same morphological features as ruptured plaques, but with an intact thin fibrous cap of < 65  $\mu\text{m}$  [3]. These lesions are termed thin-cap fibroatheroma (TCFA) and are considered to be the requisite precondition for subsequent plaque rupture [1]. Interestingly, a serial angiographic study showed that the actual size of plaques responsible for the infarction was only moderate, with the majority of lesions having less than 50% luminal narrowing before the event (which does not necessarily imply that high-grade stenoses are always “innocent” and unlikely to rupture, but are rather less frequently represented compared with mild lesions) [4]. Furthermore, an intravascular ultrasound (IVUS) study showed that rupture-prone plaques have large plaque burden expanding into the outer layer of the vessel wall, as reflected by positive remodeling [5]. Thus, these plaques are often clinically silent (without inducing anginal symptoms or myocardial ischaemia) before the acute coronary event occurs [6].

To date, the multicentre Providing Regional Observations to Study Predictors of Events in the Coronary Tree (PROSPECT) trial was the first and largest natural-history study of atherosclerosis, using invasive angiography and IVUS among 697 patients with acute coronary syndrome (ACS) to identify plaques prone to rupture [7]. For the first time it was demonstrated that the independent predictors of future events were the coronary plaque burden of  $\geq 70\%$ , the coronary minimal luminal area of  $\leq 4.0 \text{ mm}^2$ , or the presence of TCFA [7]. Of note, all of these characteristics were invisible to the coronary angiography but easily identifiable by IVUS.

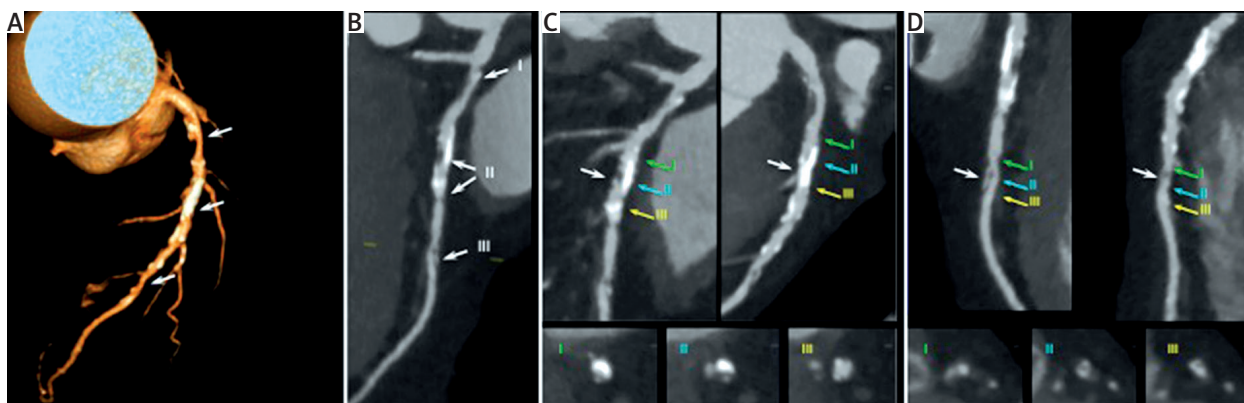
Attempts to identify and localise such vulnerable coronary plaques would be beneficial. A number of preventive measures, such as intensive lipid-lowering or antiplatelet treatment, as well as plaque sealing with coronary stents, could be implemented to effectively reduce

---

### Corresponding author:

Maksymilian P. Opolski MD, PhD, Department of Interventional Cardiology and Angiology, Institute of Cardiology, 42 Alpejska St, 04-628 Warsaw, Poland, phone: +48 501 444 303, fax: +48 22 343 4506, e-mail: maxopol@gmail.com

Received: 15.08.2014, accepted: 25.08.2014.



**Figure 1.** Non-invasive vulnerable plaque imaging by coronary computed tomography. 62-year-old patient with stable clinical symptoms. Atherosclerotic lesions in ostium, proximal and mid segments of the left anterior descending artery (LAD) were diagnosed. **A** – Three-dimensional volume-rendered image of the LAD. Lesions (arrows) and calcifications (white areas) can be clearly seen. **B** – Curved MPR image of the same artery. Atherosclerotic lesions in ostium (I), mid segment (II) and distal segment (III) can be easily identified. **C, D** – Different longitudinal views of LAD (curved MPR images in upper part of both panels) with corresponding cross-sectional views (lower part of both panels, coloured arrows): significant stenosis with positive remodeling, low attenuation areas and spotty calcifications in mid LAD (panel C, white arrows), and distally located lesion with positive remodeling, low attenuation areas and no calcifications (panel D, white arrows). This patient was referred to percutaneous coronary revascularisation

the risk of future coronary events [6]. To this end, there is a particular interest in developing a reliable non-invasive imaging method for the detection of vulnerable plaque, and CCTA is one of the leading candidates (Figure 1).

### The rationale for the identification of vulnerable plaque by coronary computed tomography angiography

Histological features that have been identified to be associated with vulnerable plaque include a large necrotic core and a thin fibrous cap, plaque size and positive remodeling, plaque vascularisation, and macrophage infiltration [1]. The limited spatial resolution of current CT technology ( $\approx 400 \mu\text{m}$ ) precludes the direct visualisation of macrophage infiltration or the thickness of the fibrous cap [8]. Similarly, although plaque vascularisation may theoretically be assessed by quantitation of vasa vasorum density using micro-computed tomography, this novel technology is still in its infancy and is currently unavailable for clinical use [8]. For this reason, quantitative measurement of plaque size (defined by plaque burden and plaque remodeling) seems to be the most practical approach for the identification of potentially vulnerable plaques by CCTA [3, 8]. This can be further substantiated by the histopathological investigations showing that (1) the mean length of the TCFA's necrotic core is 8 mm, and (2) the area of the necrotic core is most often  $> 1.0 \text{ mm}^2$  – both of which are over the plaque detection threshold ( $> 1 \text{ mm}$  plaque thickness) for current CT scanners [3]. Another strategy for the detection of vulnerable plaque by CCTA includes qualitative assessment of large

lipid pool of cholesterol-rich necrotic core as determined by low attenuation or napkin-ring sign [6, 8]. Moreover, the majority of TCFA occur in the proximal segments of the main coronary arteries corresponding to the largest vessel diameter where CCTA has the highest accuracy for plaque identification [9]. Thus, both the quantitative and qualitative analysis of vulnerable plaques by CCTA seems technically justified and feasible.

### Coronary plaque burden

Based on the sub-millimetre isotropic spatial resolution and the attenuation-derived tissue characterisation, CCTA enables the quantification of total coronary plaque burden and individual plaque components [10]. This has been corroborated by Schepis *et al.*, who showed moderate-to-high correlation of CCTA-derived plaque areas and plaque volume as compared with IVUS [11]. Similar findings were encountered in an *ex-vivo* heart model by Knollman *et al.*, who demonstrated a significant correlation between the total plaque area measured by CCTA and histology [12]. Of note, none of these studies found a particularly close agreement of CCTA with the true plaque dimensions with significant over- or underestimation of the total plaque burden and non-calcified or calcified plaque components by CCTA [3, 8].

The feasibility of non-invasive CCTA to detect vulnerable plaque can be assessed based on two separate designs of clinical investigations, namely (1) the cross-sectional comparative studies of lesion characteristics in patients with ACS and stable angina, and (2) longitudinal trials exploring the natural history and prognostic value

of coronary plaques before subsequent clinical events [3]. The first approach was undertaken by Pflederer *et al.*, who demonstrated that the culprit plaques in patients with ACS have larger plaque volume than stable lesions in patients with stable angina [13]. Similar results were replicated by Madder *et al.*, who showed that lesions with morphological features of plaque disruption in patients with unstable angina had larger total plaque volumes as well as more low-attenuation components characteristic to lipid-rich plaques than undisrupted plaques [14].

The second approach has been widely investigated by longitudinal clinical studies showing a strong prognostic value of CCTA-derived plaque burden for the occurrence of future coronary events. In a study of 1,059 patients with stable chest pain, Motoyama *et al.* found that the total plaque volume and the ratio of low-attenuation plaque to total plaque area were both significantly higher in patients who subsequently developed ACS than in those who did not, during a mean follow-up period of 27 months [15]. This observation was further confirmed by employing a semi-automatic CCTA plaque quantification algorithm leading to enhanced prognostic value over clinical risk factors and traditional CCTA reading for prediction of ACS [16]. Moreover, the ability of CCTA-derived plaque volume for the prediction of recurrent coronary events was also demonstrated among patients with non-ST segment elevation myocardial infarction [3]. Of note, neither the Agatston score nor the calcified plaque volume were associated with an increased risk of coronary event in this subpopulation [3].

### Low attenuation plaque

Traditionally, CCTA can effectively identify the presence or absence of calcified components, thereby differentiating between calcified, partially calcified, and non-calcified plaques [10]. Further classification of non-calcified plaque into the lipid-rich and fibrous tissue is based on density measurements using X-ray attenuation defined by Hounsfield units [10]. Voros *et al.* compared plaque composition by CCTA and the reference standard IVUS, and reported low CT attenuation for lipid-rich plaques [17]. Conversely, non-calcified plaques with high CT attenuation correlated predominantly with fibrous tissue [3, 10]. Nevertheless, the variability of CT densities within different scan conditions and plaque types is wide, resulting in a substantial overlap of attenuation values and potentially impaired sub-classification of non-calcified plaque by CCTA [10]. This can be further complicated by several confounding factors such as “beam hardening” or “partial volume effect” artefacts and the variable concentration of intraluminal iodinated contrast agent [10]. Thus, the precise differentiation between lipid-rich and fibrous tissue components performed solely on the basis of CT attenuation is not feasible with current technology.

Despite these limitations, several studies have indicated that CCTA-derived low attenuation plaque seems to be a consistent feature of “vulnerability”. Indeed, low-density plaques, defined by < 30 Hounsfield units average attenuation, were more often seen in patients with ACS than in individuals with stable angina [13, 14, 18]. Similarly, lower CT densities were more frequently measured in TCFA identified by optical coherence tomography as compared with stable lesions [3]. Furthermore, in a landmark study by Motoyama *et al.* the presence of low CT attenuation plaque along with positive remodeling conferred a 22% risk for subsequent coronary event within 1–3 years [15] – a similar rate to those with a 3-feature positive plaque determined by radiofrequency backscatter IVUS in the PROSPECT trial [7]. Finally, the documented association between the volume of low-attenuation plaques and subsequent coronary events constitutes direct evidence that lipid-rich plaque as depicted by CCTA is an established feature of high-risk morphology [15].

### Positive remodeling

The remodeling index is calculated as the ratio of vessel cross-sectional area at the site of maximal stenosis to the average of proximal and distal reference segment vessel cross-sectional areas [19]. Current automated and semi-automated software tools permit the reliable and time-efficient calculation of the remodeling index by CCTA [17]. Of note, the remodeling index assessed by CCTA correlates well with IVUS with only a slight overestimation by CCTA [3, 10]. Thus, a more conservative remodeling index threshold of  $\geq 1.1$  was advocated for the definition of positive remodeling by CCTA over the previously used IVUS-derived cut-off points of  $\geq 1.05$  or  $> 1.0$  [3].

In accordance with prior histopathological data, the CCTA-derived remodeling index was significantly higher in TCFA compared with non-TCFA lesions classified by optical coherence tomography [20]. Several cross-sectional studies consistently showed that culprit lesions in ACS had a higher proportion of positive remodeling and higher remodeling index compared with lesions in stable angina [13, 14, 18]. Indeed, Motoyama *et al.* demonstrated that positive remodeling index had the best diagnostic performance (sensitivity 87%; specificity 88%) among other vulnerable CT plaque characteristics (i.e. low attenuation and spotty calcification) to identify the culprit lesions in patients with ACS [18]. Again, remodeling index and/or low plaque attenuation was an independent predictor of ACS in a latter prospective longitudinal study [15].

### Napkin-ring sign

Recently, a pattern-based plaque scheme has been introduced that classifies non-calcified plaques into homogeneous or heterogeneous with further stratification of heterogeneous plaque according to the presence of a napkin-ring sign [21]. Specifically, the napkin-ring sign

is a qualitative feature of non-calcified plaque, characterised by the presence of low-attenuation central core (adjacent to the lumen) surrounded by a ring-like area of higher attenuation, potentially representing TCFA [21]. Of note, the napkin-ring sign is present in both contrast-enhanced and non-contrast-enhanced *ex-vivo* CT images [3], suggesting that this heterogeneous feature is the result of differences in CT attenuation between the large necrotic core (central low attenuation area) and fibrous plaque tissue (ring-like area of higher attenuation).

The focus on napkin-ring morphology was undertaken by an elegant study showing a close relationship between the napkin-ring sign finding on CCTA and TCFA on optical coherence tomography [20]. Of note, the napkin-ring sign was highly specific for the prediction of TCFA; however, at the cost of lower sensitivity [20]. Moreover, the napkin-ring sign was more prevalent among patients experiencing ACS than among those with stable angina [13]. Finally, the napkin-ring sign was an independent predictor of ACS (along with positive remodeling and low attenuation) in a prospective study of 895 patients during a mean of 2.3 years [22]. However, despite these promising results, further validation studies are warranted to maximise both the accuracy and reproducibility for the identification of napkin-ring sign.

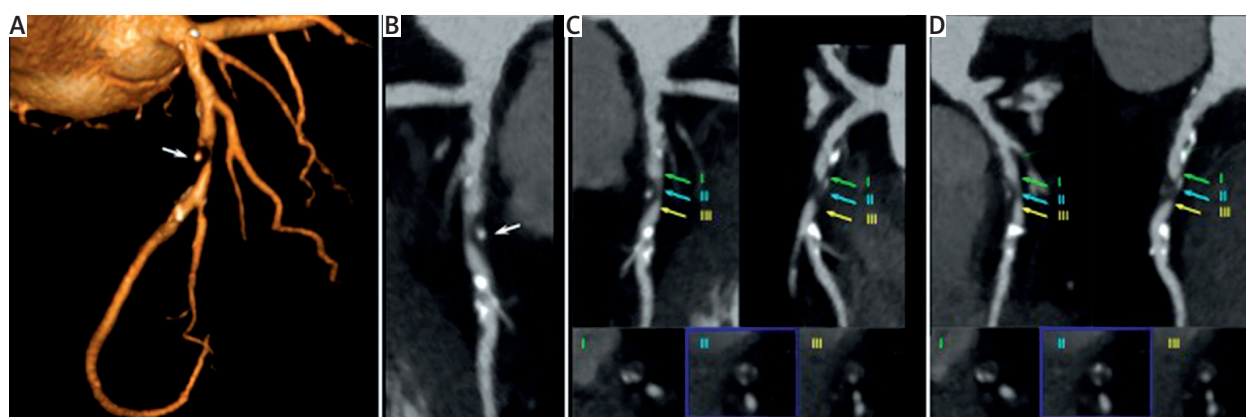
### Spotty calcification

According to autopsy studies, the majority of vulnerable plaques contain mild or moderate microcalcification [1]. The presence of spotty (small) calcification was primarily described by Ehara *et al.* by using IVUS as the typical calcification pattern of vulnerable plaques in patients presenting with acute myocardial infarction [23]. On CCTA, spotty calcification is defined as a small, dense

(> 130 Hounsfield units) plaque component surrounded by non-calcified plaque tissue [18]. Spotty calcification can be further sub-classified according to its length on curved multiplanar reconstruction into small (< 1 mm), intermediate (1–3 mm), and large calcifications (≥ 3 mm) [3]. Importantly, it has been suggested that only small spotty calcification may be related to high-risk features of coronary plaque [3, 18]. To date, the association of spotty calcification with culprit lesions in ACS has been suggested by several cross-sectional and longitudinal CCTA investigations [15, 18]. However, as there are conflicting results among different studies [3], the role of calcification in determining the stability of coronary plaque is still controversial (Figure 2).

### Future directions and clinical implications for coronary computed tomography angiography

It is indisputable that non-invasive CCTA has the ability to identify multiple high-risk features of coronary plaque (such as large plaque burden, positive remodeling, and low attenuation), thus indicating an increased risk for a subsequent acute cardiovascular event [15, 18]. This received attention in the latest guidelines on the management of stable coronary artery disease from the European Society of Cardiology [24]. The potential clinical application of CCTA for the detection of vulnerable plaques would require the development of effective preventive measures mitigating the risk of subsequent plaque rupture [6, 8]. One approach could be the use of intense medical therapy such as antiplatelet drugs (aspirin and/or thienopyridine) or lipid-lowering agents (statins), although the risk of potential side effects from the prolonged use and cost-effectiveness ratio must be



**Figure 2.** Non-invasive vulnerable plaque imaging by coronary computed tomography. 56-year-old patient without coronary clinical symptoms and non-conclusive exercise test. Critical stenosis in mid segment of the left anterior descending artery (LAD). **A** – Three-dimensional volume-rendered image of the LAD – short significant stenosis in mid LAD (arrow). **B** – Curved MPR image of the same artery. **C, D** – Different longitudinal views of LAD (curved MPR images in upper part of both panels) with corresponding cross-sectional views (lower part of both panels, coloured arrows). All features of vulnerable plaque (positive remodeling, spotty calcifications, low attenuation areas) can be identified

considered. Another fascinating approach of preventive plaque sealing with coronary stents or biodegradable vascular scaffolds emerges as a potentially curable therapeutic intervention that might revolutionise the field of interventional cardiology in the foreseeable future. Indeed, the concept of sealing the high-risk TCFA (as defined by optical coherence tomography) with a dedicated nitinol self-expanding vShield device has already been tested in a small feasibility study meeting the safety criteria at 6-month follow-up [25]. More importantly, recently a randomised PROSPECT ABSORB trial has been launched to evaluate, for the first time, the efficacy of a biodegradable scaffold in preventing future major adverse cardiovascular events arising from vulnerable plaques which appear to be angiographically innocuous.

Nevertheless, given the dynamic and multifocal nature of coronary artery disease, and the limited agreement of CCTA quantitative plaque analysis with histological findings, assessment of total plaque burden may be a much more reasonable approach for risk stratification than pinpointing a single vulnerable plaque, for the time being [8]. To this end, fully automated and standardised plaque assessment tools should become commonly available to provide 3-dimensional volumetric information on global plaque burden in a time-efficient manner [3, 10]. Moreover, further efforts to maximise both the accuracy and reproducibility of CCTA quantitative plaque analysis are required. Should it become possible, there is no doubt that CCTA will go far beyond ruling out coronary stenosis. The “Cassandra’s dream” of non-invasive identification of vulnerable plaque has never been more within reach than it is today.

## Acknowledgments

The authors report no conflicts of interest. Dr Opolski received a scholarship from the Foundation for Polish Science.

## References

- Virmani R, Burke AP, Farb A, et al. Pathology of the vulnerable plaque. *J Am Coll Cardiol* 2006; 47: C13-8.
- Ambrose JA, Srikanth S. Vulnerable plaques and patients: improving prediction of future coronary events. *Am J Med* 2010; 123: 10-6.
- Maurovich-Horvat P, Ferencik M, Voros S, et al. Comprehensive plaque assessment by coronary CT angiography. *Nat Rev Cardiol* 2014; 11: 390-402.
- Little WC, Constantinescu M, Applegate RJ, et al. Can coronary angiography predict the site of a subsequent myocardial infarction in patients with mild to moderate coronary artery disease? *Circulation* 1988; 78: 1157-66.
- Yamagishi M, Terashima M, Awano K, et al. Morphology of vulnerable coronary plaque: insights from follow-up of patients examined by intravascular ultrasound before an acute coronary syndrome. *J Am Coll Cardiol* 2000; 35: 106-11.
- Braunwald E. Noninvasive detection of vulnerable coronary plaques: locking the barn door before the horse is stolen. *J Am Coll Cardiol* 2009; 54: 58-9.
- Stone GW, Maehara A, Lansky AJ, et al.; PROSPECT Investigators. A prospective natural – history study of coronary atherosclerosis. *N Engl J Med* 2011; 364: 226-35.
- Achenbach S. Can CT detect the vulnerable coronary plaque? *Int J Cardiovasc Imaging* 2008; 24: 311-2.
- Hoffmann U, Ferencik M, Cury RC, Pena AJ. Coronary CT angiography. *J Nucl Med* 2006; 47: 797-806.
- Hecht HS. Applications of multislice coronary computed tomographic angiography to percutaneous coronary intervention: how did we ever do without it? *Catheter Cardiovasc Interv* 2008; 71: 490-503.
- Schepis T, Marwan M, Pflederer T, et al. Quantification of non-calcified coronary atherosclerotic plaques with dual-source computed tomography: comparison with intravascular ultrasound. *Heart* 2010; 96: 610-5.
- Knollmann F, Ducke F, Krist L, et al. Quantification of atherosclerotic coronary plaque components by submillimeter computed tomography. *Int J Cardiovasc Imaging* 2008; 24: 301-10.
- Pflederer T, Marwan M, Schepis T, et al. Characterization of culprit lesions in acute coronary syndromes using coronary dual-source CT angiography. *Atherosclerosis* 2010; 211: 437-44.
- Madder RD, Chinnaiyan KM, Marandici AM, et al. Features of disrupted plaques by coronary computed tomographic angiography: correlates with invasively proven complex lesions. *Circ Cardiovasc Imaging* 2011; 4: 105-13.
- Motoyama S, Sarai M, Harigaya H, et al. Computed tomographic angiography characteristics of atherosclerotic plaques subsequently resulting in acute coronary syndrome. *J Am Coll Cardiol* 2009; 54: 49-57.
- Versteyleen MO, Kietselaer BL, Dagnelie PC, et al. Additive value of semiautomated quantification of coronary artery disease using cardiac computed tomographic angiography to predict future acute coronary syndrome. *J Am Coll Cardiol* 2013; 61: 2296-305.
- Voros S, Rinehart S, Qian Z, et al. Prospective validation of standardized, 3-dimensional, quantitative coronary computed tomographic plaque measurements using radiofrequency backscatter intravascular ultrasound as reference standard in intermediate coronary arterial lesions: results from the ATLANTA (assessment of tissue characteristics, lesion morphology, and hemodynamics by angiography with fractional flow reserve, intravascular ultrasound and virtual histology, and noninvasive computed tomography in atherosclerotic plaques) I study. *JACC Cardiovasc Interv* 2011; 4: 198-208.
- Motoyama S, Kondo T, Sarai M, et al. Multislice computed tomographic characteristics of coronary lesions in acute coronary syndromes. *J Am Coll Cardiol* 2007; 50: 319-26.
- Mintz GS, Nissen SE, Anderson WD, et al. American College of Cardiology Clinical Expert Consensus Document on Standards for Acquisition, Measurement and Reporting of Intravascular Ultrasound Studies (IVUS). A report of the American College of Cardiology Task Force on Clinical Expert Consensus Documents. *J Am Coll Cardiol* 2001; 37: 1478-92.
- Kashiwagi M, Tanaka A, Kitabata H, et al. Feasibility of noninvasive assessment of thin-cap fibroatheroma by multidetector computed tomography. *J Am Coll Cardiol* 2009; 2: 1412-9.
- Maurovich-Horvat P, Schlett CL, Alkadhi H, et al. The napkin-ring sign indicates advanced atherosclerotic lesions in coronary CT angiography. *JACC Cardiovasc Imaging* 2012; 5: 1243-52.

22. Otsuka K, Fukuda S, Tanaka A, et al. Napkin-ring sign on coronary CT angiography for the prediction of acute coronary syndrome. *JACC Cardiovasc Imaging* 2013; 6: 448-57.
23. Ehara S, Kobayashi Y, Yoshiyama M, et al. Spotty calcification typifies the culprit plaque in patients with acute myocardial infarction: an intravascular ultrasound study. *Circulation* 2004; 110: 3424-9.
24. Montalescot G, Sechtem U, Achenbach S, et al. 2013 ESC guidelines on the management of stable coronary artery disease: the Task Force on the management of stable coronary artery disease of the European Society of Cardiology. *Eur Heart J* 2013; 34: 2949-3003.
25. Wykrzykowska JJ, Diletti R, Gutierrez-Chico JL, et al. Plaque sealing and passivation with a mechanical self-expanding low outward force nitinol vShield device for the treatment of IVUS and OCT-derived thin cap fibroatheromas (TCFAs) in native coronary arteries: report of the pilot study vShield Evaluated at Cardiac hospital in Rotterdam for Investigation and Treatment of TCFA (SECRITT). *EuroIntervention* 2012; 8: 945-54.