

Stent loss in the radial artery – surgical vs. interventional approach – report of two cases

Artur Baszko¹, Wojciech Telec¹, Eryk Naumowicz², Tomasz Siminiak³, Piotr Katmucki³

¹2nd Department of Cardiology, Poznan University of Medical Sciences, Poznan, Poland

²Department of Surgery with Section of Vascular Surgery in HCP Medical Center, Poznan, Poland

³Department of Cardiovascular Disease Prevention, Poznan University of Medical Sciences, Poznan, Poland

Postep Kardiol Inter 2015; 11, 1 (39): 50–54

DOI: 10.5114/pwki.2015.49186

Abstract

Stent loss during coronary angioplasty is a complication that can be managed in various manners; however, transradial access limits the options available. We describe two coronary interventions complicated by stent dislodgement, initially managed by pulling the stent back to the radial artery. Both stents were unwillingly lost on different levels in radial arteries. The first case was managed with a direct radial artery cut-down because distal location made it a quick and straightforward procedure. In the second case a partially deployed stent was lost in the proximal part of the radial artery. It was rewired, deployed, and post-dilated with a larger balloon. This enabled continuation of the procedure using the same access. Both cases were asymptomatic during 24 months of follow-up. It is crucial to avoid leaving artificial bodies in arteries supplying vital organs because stent-related thrombosis or stenosis may seriously compromise blood flow. Removing the stent via the introducer sheath should be considered the optimal treatment. Unfortunately it is common that a partially expanded stent will not pass through the sheath. The superficial location of the distal radial artery segment facilitates surgical cut-down with local anaesthesia. When dislodgement occurs in deeper segments of the radial artery, the benefits from cut-down seem to be less because the procedure might take more time and be more difficult – as in the presented case in which we decided to rewire and fully expand the stent in situ. Retrieval of the stent at all costs might have led to further complications; hence stent deployment may be a good alternative to retrieval in such cases.

Key words: percutaneous coronary intervention, coronary stent dislodgement, stent loss, stent retrieval.

Introduction

Stent loss during interventional treatment of coronary disease is a relatively rare complication, but it may have serious consequences. In femoral access stent dislodgement occurs in up to 1% of procedures [1–3]. The rescue solutions used include crushing the lost stent with a newly deployed one, withdrawing the stent with the help of a small balloon serving as an anchor, different snare tools, or forceps. However, frequent up-sizing of the guide catheter up to 11 Fr is necessary in order to succeed. The transradial technique is gaining broad acceptance due to a lower complication rate and better survival in patients with elective and emergency procedures. However, this approach imposes some limitations related to smaller artery size, which limits the number of techniques for dislodged stents. There are only a few reports on stent loss during transradial procedures [4, 5].

We report two cases in which two different techniques were used reflecting different clinical situations.

Case reports

Case 1

A 58-year-old patient with a history of hypertension, hypercholesterolaemia, previous left circumflex artery (LCx) angioplasty (2007), and an attempt of percutaneous coronary intervention (PCI) to the right coronary artery (RCA) (2008) presented with progressive unstable angina despite optimal medical treatment. In the emergency room the patient presented with ST segment depression on electrocardiogram (ECG), but cTnT was negative. After preparing the patient with aspirin 300 mg and clopidogrel 600 mg transradial coronary angiography (6 Fr Sheath, Terumo) revealed noncritical, multisegmental lesions in the left anterior descending artery (LAD),

Corresponding author:

Wojciech Telec MD, 2nd Department of Cardiology, Poznan University of Medical Sciences, 28 Czerwca 1956 r. 194, 61-465 Poznan, Poland, phone: +48 666 296 733, e-mail: telec@ump.edu.pl

Received: 19.10.2014, **accepted:** 8.01.2015.

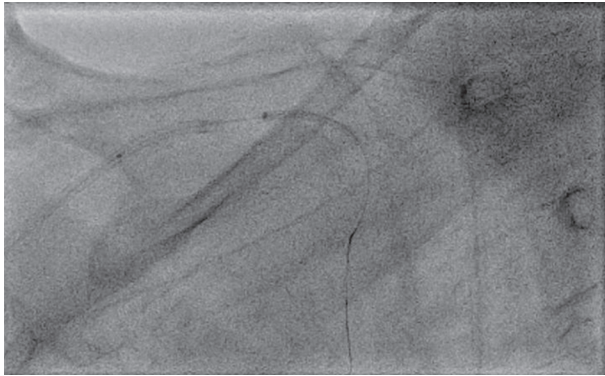


Figure 1. Stent pullback at the level of right subclavian artery

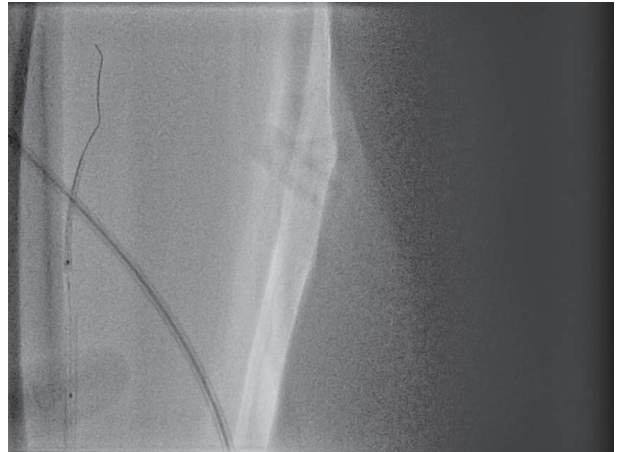


Figure 2. Stent held by the tip of the balloon in the area of puncture site. Vascular sheath visible

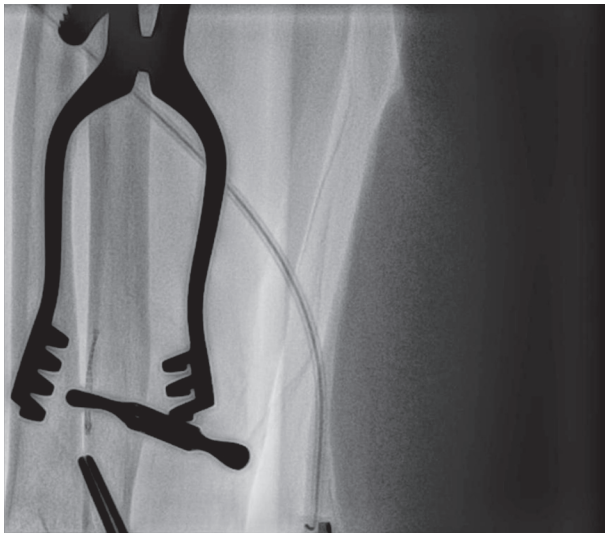

Figure 3. Stent during direct radial artery cut-down

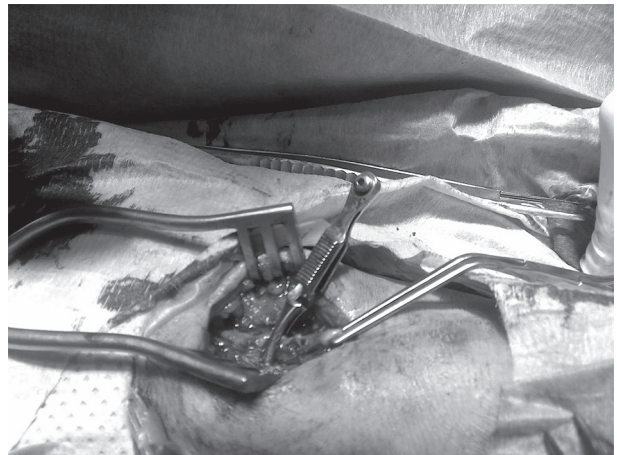


Figure 4. Surgical approach to the distal segment of radial artery

occluded distal LCx, and long critical, eccentric narrowing in the mid-to-distal part of the RCA with hardly any visible calcifications.

The procedure of PCI of the RCA was attempted. A Whisper ES (Whisper ES, Abbott) guidewire was inserted and several predilations were performed using 2.0 × 20 mm and 2.5 × 20 mm angioplasty balloons (Sprinter Legend, Medtronic). The drug eluting stent did not cross the distal calcified lesion (Xience Prime 3.5 × 28 mm, Abbott). During the stent pullback to the guiding catheter it slipped out leaving an approximately 2–3 mm margin covering the distal part of the balloon. The stent could not be advanced again, and an attempt to remove it was made. In order to do so, the balloon was inflated to 6 atm to fixate the stent. The stent, along with the inflated balloon and catheter, were pulled back together into the sheath (Figures 1–2). As we could not get the stent into the sheath the entire assembly was removed en bloc, unfortunately leaving the stent in the radial artery in

the wrist region. Light compression was applied to stop bleeding, and under X-ray the location of the stent was confirmed at the level of artery puncture.

A vascular surgeon was asked for consultation and it was decided to perform a radial artery cut-down to surgically remove the stent (Figures 3–5). This was done under local anaesthesia without complications.

As the patient experienced chest discomfort due to RCA dissection the procedure was continued using the transfemoral approach. The procedure required using two extra support guidewires, non-compliant balloons, and stronger support with an AL1 guiding catheter. Finally the stent was deployed (Xience Prime 3.0 × 28 mm) and additional post-dilation with a 3.5 × 15 mm balloon (NC Sprinter RX, Medtronic) resulted in a very good angiographic effect. During hospitalisation there was a slight oedema of the operated hand, but pulses on both radial and ulnar arteries were maintained. A further 18-month follow-up was uneventful.

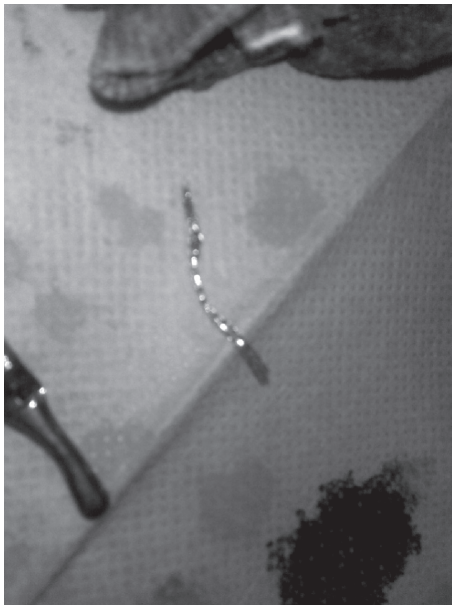

Figure 5. Distorted, unexpanded stent successfully removed from radial artery

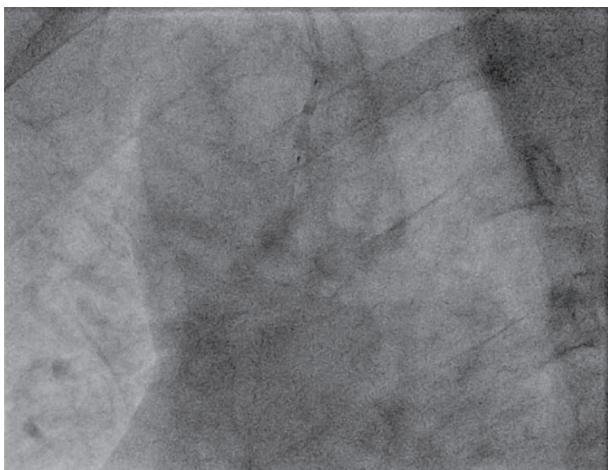


Figure 7. Partially expanded stent during pullback at the level of ascending aorta

Case 2

A 53-year-old patient presented with chest pain and ST segment elevation consistent with inferior infarction. Previous history revealed hypertension treated with ramipril. The patient received aspirin 300 mg, clopidogrel 600 mg, and 5000 U of unfractionated heparin in the emergency room and was sent for urgent angiography. The procedure was performed transradially (6 Fr sheath, Terrumo) and revealed 65% narrowing in mid RCA suitable for “direct stenting”.

The Whisper MS guidewire was inserted and a stent (3.0 × 15 mm Xience Prime, Abbott) was positioned (Figure 6). During the attempt to deploy the stent, a pressure rise on the pump pressure gauge was not observed. Close

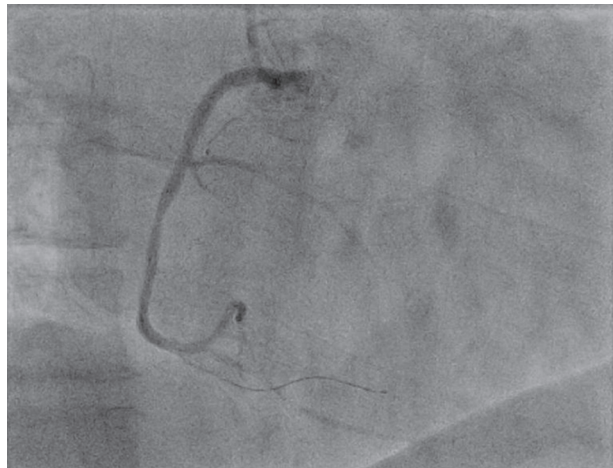

Figure 6. Stent positioning in mid-RCA lesion

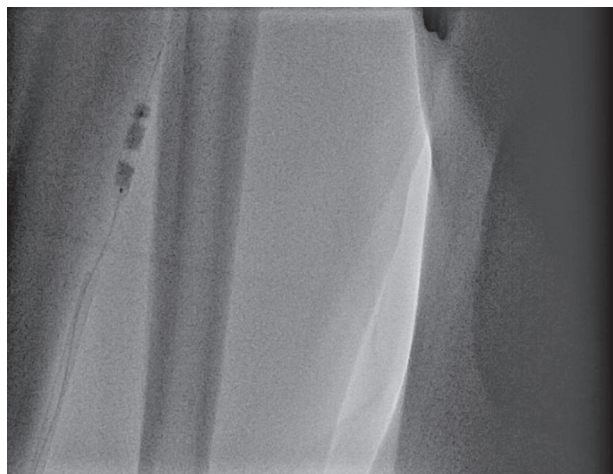


Figure 8. Stent deployment in the proximal segment of radial artery

inspection revealed a broken three-way cock connecting the pump with the balloon catheter. The connector was replaced. During this manoeuvre the stent was moved proximally to the lesion. An attempt to push it across the lesion failed, and an attempt to pull it back into the guiding catheter was performed. It was also impossible probably due to a slight but invisible inflation of the balloon during the first attempt to deploy the stent. On the second attempt the stent went into the guiding catheter. The balloon was partially inflated (6 atm) to press the stent against the catheter wall. Thereafter the catheter, the trapped stent, and the wire were removed slowly towards the sheath (Figure 7). After completing the pull back, there was no stent remaining in the catheter. Inspection under X-ray showed that the stent was lost in the proximal segments of the radial artery. The stent was rewired and deployed in situ using 3.5 × 15 mm and 4.0 × 15 mm balloons (Figure 8). Because a good result was obtained, the PCI was continued using the same ap-

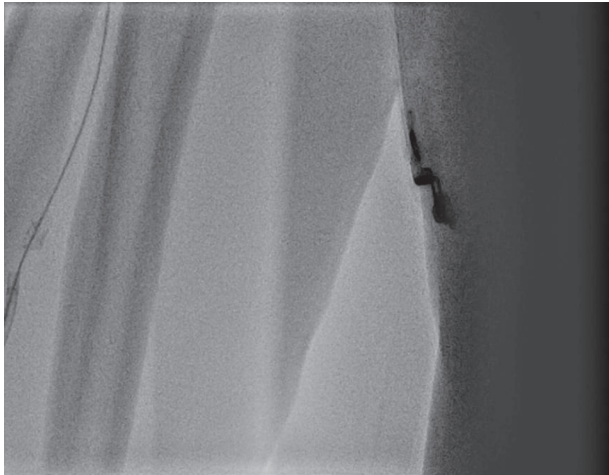

Figure 9. Stent distorted by 6 Fr guiding catheter

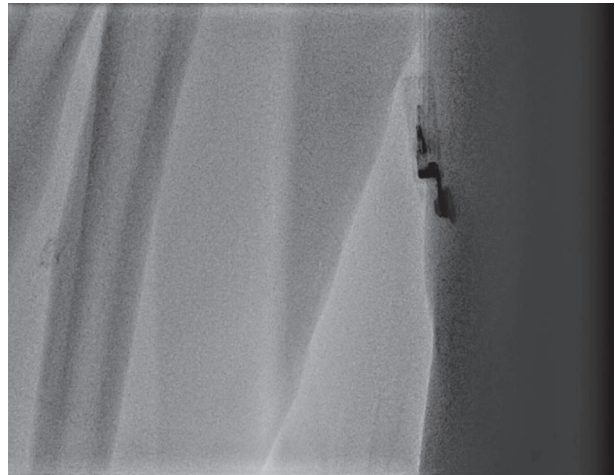

Figure 10. Distorted stent in radial artery




Figure 11. Balloon crossing through the distorted stent

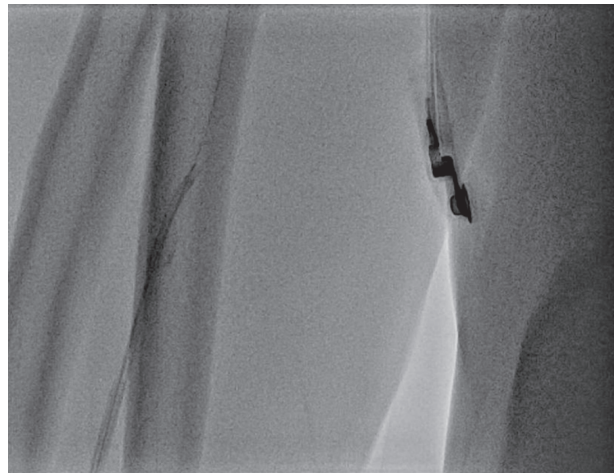


Figure 12. Stent successfully crossed by 5 Fr guiding catheter

proach. Introducing the 6 Fr guiding catheter led to stent distortion (Figures 9–10), and another 4.0 × 15 balloon was used to reshape it properly (Figure 11). After this, the guiding catheter was replaced with a 5 Fr catheter (Figure 12) and the procedure was completed without further complications. The next 14 months of patient follow-up were uneventful.

Discussion

Stent loss can be related to several factors such as: inserting while the balloon is exposed to negative pressure, inserting the stent through a previously deployed stent, advancing the stent through calcified, tortuous lesions or during withdrawal of the stent to the guiding catheter while the proximal struts are damaged [2, 3]. An artificial body left in the vascular system may lead to thrombosis, but in most sites it is benign unless the stent is within the central nervous system, heart, or arteries supplying

vital organs. Embolisation of stents in coronary arteries has a hazardous potential for the patient and should be avoided due to high risk of complications [6].

The procedure performed through the radial artery creates some challenges, but it also offers some possibilities to deal with lost stents. We have presented two cases of stent loss. In the first case it was due to serious underestimation of calcifications, and in the second after an attempt to withdraw a partially inflated stent. Both stents were still within the coronary artery. Deploying the lost stent within the coronary artery was one option, which was proven to be easy and safe, and it did not disrupt the completion of the case. We decided to remove stents into the catheter because part of the balloon was still within the stent. The partially inflated balloon was used to anchor the stent to the wall of the catheter. However, in both cases stents were lost within the radial artery. The difference in stent position led to

different approaches. In the first situation there was significant resistance at the entry to the sheath, and finally we attempted to remove the entire assembly (sheath, catheter, balloon, and stent) en block. The stent, however, slipped into the radial artery at the site of puncture, which was confirmed under fluoroscopy. This was an optimal situation for surgical intervention, which was performed immediately. In a similar case reported recently, when radial cut-down stent retrieval was performed, the PCI was postponed for several days [5]. In our case, the patient had chest pain due to the dissection of the artery. This is why we decided to perform radial artery cut-down on heparin and then continue with angioplasty. The patient was on a triple therapy (aspirin, clopidogrel, and unfractionated heparin), and this did not cause any post-surgical complications. This is in line with the observation of pacemaker patients who were on dual or triple therapy during surgery [7].

In the second case the stent was lost very high in the forearm – this location was not ideal for surgical intervention. We decided to deploy the stent with 3.5 and 4.0 mm balloons, and the procedure was continued by passing the stent with the use of a guidewire. Another useful technique that could be used in this case was a snare and guiding catheter, as described by Deftereos *et al.* [8]. In our case the stent was initially inflated in the proximal part, which could make the stent too large to insert into the guiding catheter.

Conclusions

In our opinion, deploying a lost stent within the coronary artery in a healthy segment should not be performed as long as a chance to remove it exists. Having the stent fixed with the tip of the balloon gives the opportunity to remove it to the radial artery. Surgical extraction or deployment of the stent in the radial artery was successful in both cases, which enabled us to complete the case, and it had no negative impact during long-term follow-up.

Conflict of interest

The authors declare no conflict of interest.

References

1. Dunning DW, Kahn JK, O'Neill WW. The long-term consequences of lost intracoronary stents. *J Interv Cardiol* 2002; 15: 345-8.
2. Brialakis ES, Best PJ, Elesber AA, et al. Incidence, retrieval methods, and outcomes of stent lost during percutaneous coronary intervention: a large single-center experience. *Catheter Cardiovasc Interv* 2005; 55: 333-40.
3. Iturbe JM, Abdel-karim AR, Papayannis A, et al. Frequency, treatment, and consequences of device loss and entrapment in contemporary percutaneous coronary interventions. *J Invasive Cardiol* 2012; 24: 215-21.
4. Ahmar W, Malaiapan Y, Meredith IT. Transradial retrieval of dislodged stent from the left coronary artery. *J Invasive Cardiol* 2008; 20: 545-7.
5. Cha KS. Surgical retrieval of dislodged stent during transradial coronary intervention. *J Invasive Cardiol* 2012; 24: E179-81.
6. Eggerbrecht H, Haude M, von Birgelen C, et al. Nonsurgical retrieval of embolized coronary artery stents. *Catheter Cardiovasc Interv* 2000; 51: 432-40.
7. Ghanbari H, Phard WS, Al-Ameri H, et al. Meta-analysis of safety and efficacy of uninterrupted warfarin compared to heparin-based bridging therapy during implantation of cardiac rhythm devices. *Am J Cardiol* 2012; 110: 1482-8.
8. Deftereos S, Raisakis K, Giannopoulos G, et al. Successful retrieval of coronary stent dislodged in the brachial artery by means of improvised snare and guiding catheter. *Int J Angiol* 2011; 20: 55-8.