

Diffuse coronary artery aneurysms involving three major vessels in a patient with Behçet's disease

Emre Gurel¹, Ender Ozal¹, Halil Atas²

¹Pendik State Hospital, Istanbul, Turkey

²Marmara University Hospital, Istanbul, Turkey

Adv Interv Cardiol 2016; 12, 2 (44): 179–180
DOI: 10.5114/aic.2016.59372

Behçet's disease (BD) is a multiorgan vasculitis of unknown origin, with characteristic skin lesions, recurrent uveitis and neurological manifestations [1–3]. Here we present a case of diffuse coronary artery aneurysms involving three major vessels and its appropriate medical treatment.

A 45-year-old man visited our cardiology outpatient clinic with a 2-month history of progressive exertional chest pain (Canadian Cardiovascular Society Class III). The patient had a history of BD, which had been diagnosed 15 years ago, and he was not routinely followed up in our rheumatology clinic due to social reasons. He had no cardiac risk factor. On physical examination he was afebrile, pulse rate was 85 per minute and blood pressure was 130/80 mm Hg. The electrocardiogram revealed normal sinus rhythm. Laboratory tests showed normal high-sensitivity C-reactive protein and negative troponin-T level. Transthoracic echocardiography revealed no abnormality. Exercise stress test showed ST segment depression in leads I, aVL and V4–6, and a coronary angiogram was performed. It demonstrated diffuse fusiform aneurysms located on the left anterior descending (LAD), circumflex (Cx) and right coronary (RCA) arteries with extensive coronary slow flow (Figure 1 A–C). Maximal coronary aneurysm diameter was measured as 6.4 mm for the LAD, 6.8 mm for the Cx and 8.3 mm for the RCA in coronary computed tomography (CT) angiography (Figure 1 D). The patient was treated with anti-ischemic agents, including acetylsalicylic acid, a β -blocker, a statin, an ACE inhibitor and oral nitrates. Thereafter, rheumatology consultation was requested. Intravenous cyclophosphamide 1 g/month and methylprednisolone 1 mg/kg/day (with gradual dose tapering) were initiated as the immunosuppressive (IS) treatment. During the hospital course the patient did not complain of any chest pain,

and he was discharged with the same anti-ischemic and IS treatment. One month after discharge, his functional class had decreased to CCS Class I–II. As the patient's symptoms regressed with proper medical treatment, surgical or endovascular interventions were not considered. Three months after discharge, coronary CT angiography revealed no increase in the size of each aneurysm. The patient has been in the regular outpatient clinic follow-up for 1 year, without any increase in his symptoms.

Behçet's disease is a chronic autoimmune vasculitis that may cause single or multiple coronary aneurysms. Patients may be asymptomatic or present with stable angina or acute coronary syndrome, irrespective of the involved vessels [1, 2, 4]. Since no atherosclerotic coronary stenosis or thrombus formation was detected, relative ischemia due to coronary slow flow was the probable cause of exertional angina in our case. Current practice for the management of coronary artery aneurysms in BD is based on a limited number of case reports. For asymptomatic patients, observation may be considered. Acute or pending rupture, enlarging aneurysms, and severe recurrent ischemia unresponsive to medical treatment, however, necessitate surgical procedures such as aneurysm resection, aneurysm ligation and coronary artery bypass grafting. Percutaneous stenting has been reported but has also been associated with a high risk of thrombosis and pseudoaneurysm formation [3]. In the literature, treatment approaches have not differed between single and multiple coronary aneurysms. In only 2 patients with BD previously reported, the diagnosis was stable angina pectoris, and surgical or endovascular interventions were not performed in either [1, 2]. However, this case highlights the importance of a conservative approach with optimal anti-ischemic and IS therapy in extensive aneurysmatic involvement of coronary arteries due to BD.

Corresponding author:

Emre Gurel MD, Pendik State Hospital, Istanbul, Turkey, phone: +90 533423215, e-mail: emregurelctf@yahoo.com

Received: 8.05.2015, **accepted:** 10.08.2015.

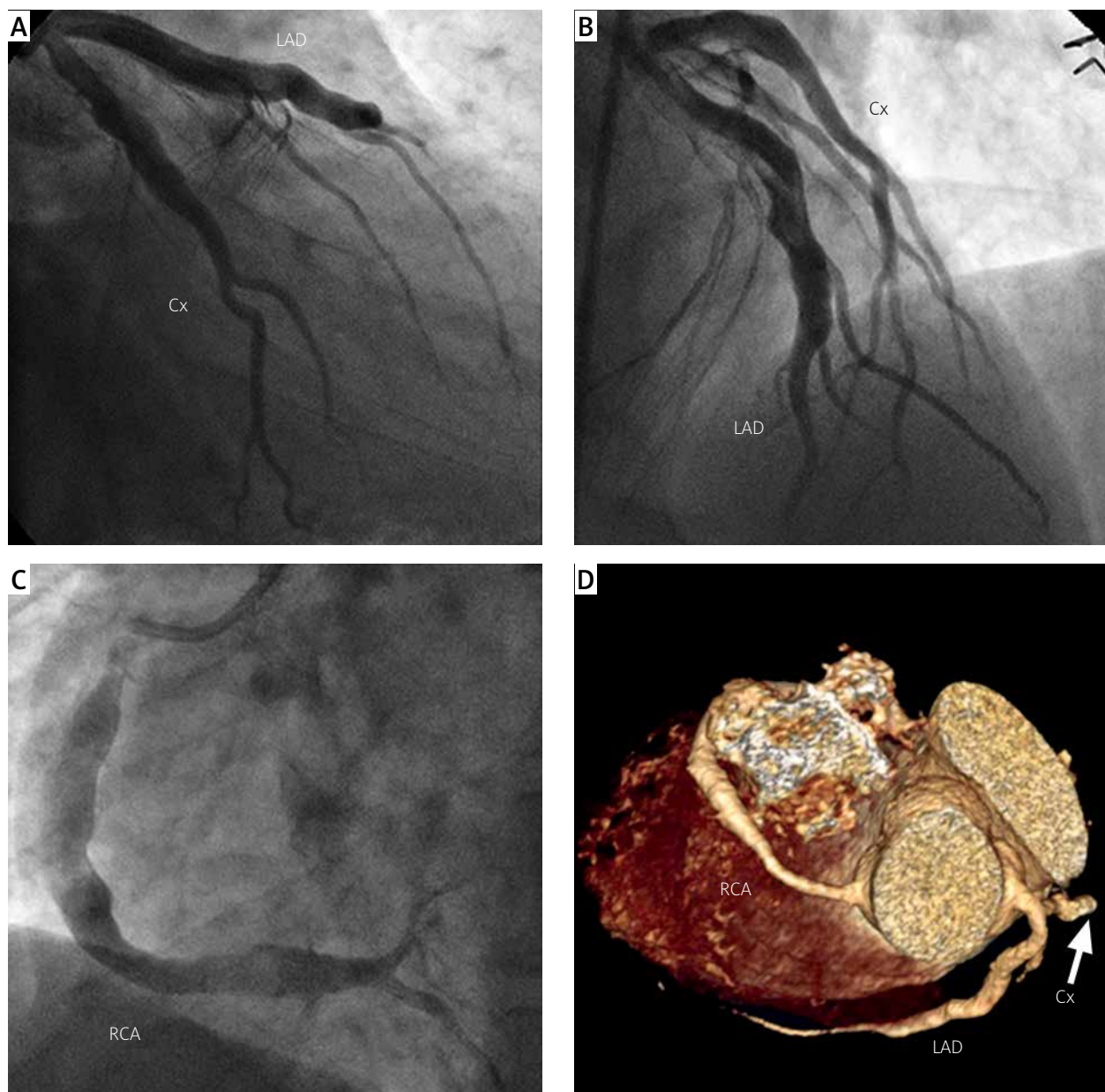


Figure 1. Diffuse coronary artery aneurysms involving the left anterior descending, circumflex (A, B) and right coronary artery (C). Computed tomography angiography confirmed three-vessel involvement (D)

Conflict of interest

The authors declare no conflict of interest.

References

1. Cevik C, Otahbachi M, Nugent K, et al. Coronary artery aneurysms in Behçet's disease. *Cardiovasc Revasc Med* 2009; 10: 128-9.
2. Tatli E, Surucu H, Aktoz M, Buyuklu M. Coronary artery ectasia in a patient with Behçet's disease. *Saudi Med J* 2007; 28: 1281-2.
3. Soofi MA, Abdulhak AB, Alsamadi F, et al. Stenting for huge coronary artery aneurysm and stenosis in a patient with Behçet's disease presenting with non-ST segment elevation myocardial infarction. *J Cardiol Cases* 2013; 8: e3-6.
4. Sokhanvar S, Karimi M, Esmail-Zadeh A. Recurrent acute myocardial infarction with coronary artery aneurysm in a patient with Behçet's disease: a case report. *J Med Case Rep* 2009; 3: 8869.