

Do we need invasive confirmation of cardiac magnetic resonance results?

Paweł Siastala, Jacek Kądziała, Łukasz A. Małek, Mateusz Śpiewak, Katarzyna Lech, Adam Witkowski

Department of Interventional Cardiology and Angiology, Institute of Cardiology, Warsaw, Poland

Adv Interv Cardiol 2017; 13, 1 (47): 26–31
DOI: <https://doi.org/10.5114/aic.2017.66183>

Abstract

Introduction: Coronary artery revascularization is indicated in patients with documented significant obstruction of coronary blood flow associated with a large area of myocardial ischemia and/or untreatable symptoms. There are a few invasive or noninvasive methods that can provide information about the functional results of coronary artery narrowing. The application of more than one method of ischemia detection in one patient to reevaluate the indications for revascularization is used in case of atypical or no symptoms and/or borderline stenosis.

Aim: To evaluate whether the results of cardiac magnetic resonance need to be reconfirmed by the invasive functional method.

Material and methods: The hospital database revealed 25 consecutive patients with 29 stenoses who underwent cardiac magnetic resonance (CMR) and fractional flow reserve (FFR) between the end of 2010 and the end of 2014. The maximal time interval between CMR and FFR was 6 months. None of the patients experienced any clinical events or underwent procedures on coronary arteries between the studies.

Results: According to the analysis, the agreement of CMR perfusion with the FFR method was at the level of 89.7%. Assuming that FFR is the gold standard in assessing the severity of stenoses, the sensitivity of CMR perfusion was 90.9%. The percentage of non-severe lesions which were correctly identified in CMR was 88.9%.

Conclusions: The study shows that CMR perfusion is a highly sensitive method to detect hemodynamically significant CAD and exclude nonsevere lesions. With FFR as the reference standard, the diagnostic accuracy of MR perfusion to detect ischemic CAD is high.

Key words: coronary artery disease, functional assessment, magnetic resonance, fractional flow reserve.

Introduction

Coronary artery revascularization with either percutaneous coronary intervention (PCI) or coronary artery bypass graft surgery (CABG) is indicated in patients with documented significant obstruction of coronary blood flow associated with a large area of myocardial ischemia and/or untreatable symptoms [1].

There are few invasive or noninvasive methods that can provide information about the functional results of coronary artery narrowing [2]. Fractional flow reserve (FFR) is a common invasive method considered the gold standard of ischemia detection [3, 4]. The FFR represents the ratio between the maximal achievable blood flow in a narrowed coronary artery and the theoretical maximal flow in a normal non-obiterated artery. Non-invasive methods include single photon emission computed tomography (SPECT), stress echocardiography and cardiac magnetic resonance

(CMR). One of the non-invasive methods is CMR stress perfusion, which can show areas of reversible perfusion deficit during stress induced by drug infusion [4]. Both FFR and CMR stress perfusion are frequently used to document ischemia in qualification for coronary revascularization [5].

The application of more than one method of ischemia detection in one patient to reevaluate the indications for revascularization is sometimes used in case of atypical or no symptoms and/or borderline stenosis [6]. According to this strategy, some patients who underwent CMR may undergo FFR during planned PCI. A second subset of patients undergoing multiple functional studies consists of patients who had a negative result of FFR and were followed up with CMR.

We decided to use the data of multimethod ischemia detection from the hospital registry to compare results of testing with two methods, CMR and FFR.

Corresponding author:

Paweł Siastala MD, Department of Interventional Cardiology and Angiology, Institute of Cardiology, 42 Alpejska St, 04-628 Warsaw, Poland, phone: +48 509 844 357, e-mail: pawel.siaastala@gmail.com

Received: 14.05.2016, **accepted:** 19.08.2016.

Aim

The purpose of this study was to evaluate the agreement of cardiac magnetic stress perfusion with FFR as the gold standard in assessing the severity of stenoses in coronary artery disease.

Material and methods

Study group

The search of the hospital database revealed 25 consecutive patients with 29 stenoses who underwent CMR and FFR between the end of 2010 and the end of 2014. The maximal time interval between CMR and FFR was 6 months. None of the patients underwent any clinical events or procedures on coronary arteries between the studies. Four patients from this group underwent analysis of two lesions in different arteries.

The analysis of the study revealed the presence of two subsets of patients. The first subset (group I) included 15 patients who had a positive CMR stress perfusion test. During coronary angiography following CMR assessment their lesions were defined as borderline (40–80%); therefore FFR was performed to reconfirm the presence of ischemia. The second subset (group II) included 9 patients with negative FFR examination. Due to persisting nonspecific anginal symptoms those patients were qualified for CMR perfusion as a noninvasive method of further assessment.

Results were analyzed in the context of risk factors such as hypertension, dyslipidaemia, diabetes mellitus, previous myocardial infarction, atrial fibrillation, the extent of the atherosclerosis and cigarette smoking.

Informed consent for both CMR and FFR studies was obtained from each participating patient.

Fractional flow reserve

Fractional flow reserve was measured as the ratio of the pressure distally to the lesion to pressure proximal to the narrowing performed with a dedicated 0.014 inch pressure wire during maximal hyperemia (Figure 1 A). To obtain hyperemic conditions, a maximal vasodilatory stimulus with intravenous adenosine 140 µg/kg/min infusion through the antecubital vein was used. According to the guidelines FFR lower than 0.80 was generally considered as associated with significant myocardial ischemia [7]. In all patient Radi Medical System, Sweden was used with St. Jude Medical, USA wires (in 2008 St. Jude Medical acquired Radi Medical System). All patients were told to avoid for 24 h before the examination products containing caffeine such as coffee, tea, cola, or chocolate that may interfere with adenosine and diminish the hyperemic effect.

Coronary angiography was performed from the femoral or radial approach. The heart rate and arterial pressure were continuously monitored throughout the pro-

cedure and the electrocardiogram was simultaneously recorded.

Cardiac magnetic resonance

All patients underwent a CMR scan by means of a 1.5 Tesla scanner (Magnetom Avanto, Siemens, Erlangen, Germany) (Figures 1 B–D). Scout images and electrocardiographic gated breath-hold steady state free precession (SSFP) cine images in 2- and 4-chamber views were registered to set up final short axis imaging planes. Systolic function assessment was based on SSFP images from the mitral valve insertion point to the apex to encompass the entire left ventricle (LV). Imaging parameters were as follows: field of view 28 × 34 cm, matrix 416 × 512, effective repetition time 33 to 54 ms, echo time 1.2 ms, flip angle 64 to 79°, slice thickness 8 mm, gap 1.6 mm, in-plane image resolution 1.6 × 1.6 mm to 1.8 × 1.8 mm, temporal resolution 25 to 40 phases per cardiac cycle.

This was followed by first-pass stress perfusion using a saturation-recovery echo gradient sequence registered in 3 short axis slices (basal, mid-ventricular, peri-apical) after intravenous administration of 0.1 mmol/kg of gadolinium contrast agent at 3.5 ml/s (gadobutrol – Gadovist, Bayer Schering Pharma AG, Berlin, Germany) and flushed with 30 ml of isotonic saline. Hyperemia was obtained with 4-minute infusion of 0.73 mg/kg of dipyridamole. Imaging parameters were as follows: field of view 27 × 36 cm, matrix 94 × 192, effective repetition time 165 ms; echo time 1.08 ms; flip angle 12°, slice thickness 10 mm, in-plane image resolution 2.9 × 1.9 mm.

Delayed enhancement (DE) images were obtained with a breath-hold segmented inversion recovery sequence performed 10 min after contrast injection and acquired in the same orientation as the cine images. Imaging parameters were as follows: field of view 28 × 34 cm, matrix 154 × 256, effective repetition time 700 ms, echo time 4.9 ms, flip angle 30°, slice thickness 8 mm, gap 1.6 mm, in-plane image resolution 1.7 × 1.3 mm. The inversion time was adjusted to completely null normal myocardium (typically between 250 and 350 ms).

Cardiac magnetic resonance image analysis

Cardiac magnetic resonance cine images were analyzed using dedicated software (MASS 6.2.1, Medis, Leiden, the Netherlands). Initially, short axis images were previewed from the base to the apex in a cinematic mode, then endocardial and epicardial contours for end-diastole and end-systole were manually traced. Delineated contours were used for the quantification of end-diastolic and end-systolic volumes normalized to body surface area (BSA) and ejection fraction (LVEF).

Stress perfusion deficit at first pass of gadolinium contrast perfusion through the myocardium indicative of ischemia was defined as a lack of perfusion in at least

one myocardial segment, present for at least five dynamic cycles after a maximal myocardial signal intensity increase, calculated by means of the Mean Curve software of the Siemens working station and not corresponding to area of DE. Rest perfusion following stress perfusion was performed at the discretion of the physician and only in some patients, mainly for the differentiation of artifacts and true stress perfusion deficits. Stress perfusion deficits not corresponding directly to DE and below half of the segment thickness were calculated as 3% of the LV mass and those above half of the segment thickness as 6% of the LV mass [8]. Significant ischemia in CMR was defined as ischemia of at least 10% of LV mass supplied

by the analyzed artery. In patients with two narrowed arteries, FFR in examined vessels was analyzed in the context of CMR results according to supplied areas.

Statistical analysis

All results for categorical variables were presented as numbers and percentages and for continuous variables as mean and standard deviation (SD) or median and interquartile range (IQR), depending on the normality of distribution assessed using the Kolmogorov-Smirnov test. Pearson's or Spearman's test was applied to assess any correlations, including the correlation between FFR and CMR results, depending on the normality of distribu-

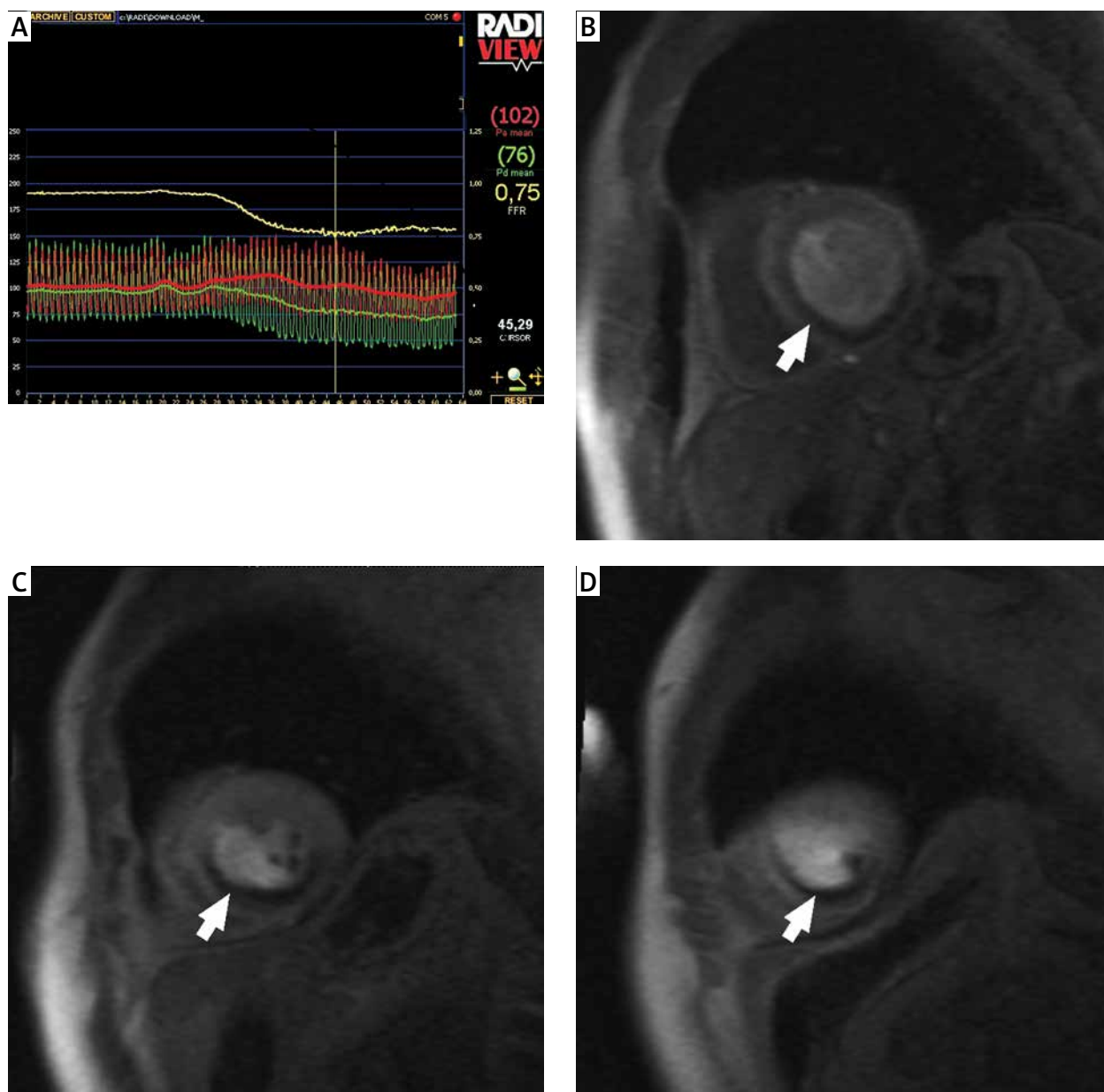


Figure 1. A – Fractional flow reserve measurement in right coronary artery. B–D – Cardiac magnetic resonance stress perfusion images demonstrating large perfusion deficits (arrow) in the right coronary artery territory extending from basal slice (B) through mid-ventricular slice (C) to apical slice (D)

tion. All tests were two-sided with the significance level of $p < 0.05$. Statistical analyses were performed with MedCalc statistical software 10.0.2.0 (MedCalc, Mariakerke, Belgium).

Results

Mean age in the analyzed group was 66 years (68% males) (Table I). Mean FFR in the whole group of patients was 0.82, while the average FFR was 0.69 in group I and 0.9 in group II. The median ischemia size in CMR perfusion was 7.7% (0–15). The median ischemia size in CMR perfusion in group I was 14.5, whereas in group II it was 2.8 ($p = 0.18$).

According to the analysis the agreement of CMR perfusion with the FFR method was at the level of 89.7% (26 of 29 analyzed stenoses). The correlation between the FFR result and CMR result was negative (Figure 2). Assuming that FFR is the gold standard in assessing the severity of stenoses, the sensitivity of CMR perfusion was 90.9% (10 of 11 analyzed stenoses). The percentage of non-severe lesions which were correctly identified in CMR was 88.9% (16 of 18 analyzed stenoses). The positive predictive value (PPV) characterizing CMR perfusion in assessing the significance of cardiac ischemia was 83.3% (10 of 12 analyzed stenoses). The percentage of lesions which tested negatively in CMR perfusion and truly were non-severe was 94.2% (16 out of 17 analyzed stenoses).

The average size of ischemia in CMR perfusion in patients with a positive FFR result in the analyzed artery was 14.5%, whereas in patients with negative FFR it was 2.8%. Mean FFR in the whole group of patients was 0.82, while the average positive FFR was 0.69 and the average negative FFR was 0.9.

Results in 3 of 29 analyzed arteries were inconsistent in FFR and CMR. Considering FFR as the gold standard, in CMR perfusion we obtained 2 false-positive results and 1 false-negative. FFR in 1 of 2 patients with false-positive CMR perfusion was 0.9 and the size of ischemia

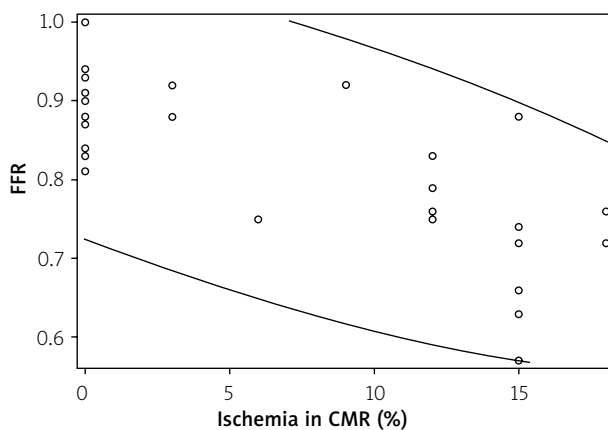


Figure 2. The negative correlation between the results of FFR and CMR

Table I. Characteristics of study group

| Parameter | Result |
|--|-----------------|
| General information: | |
| Age [years] | 63 ±16 |
| Male, n (%) | 17 (68) |
| Previous MI, n (%) | 8 (32) |
| BMI [cm/m ²] | 28.6 ±5 |
| BSA [m ²] | 1.89 ±0.17 |
| LVEF | 61 (23–84)* |
| FFR | 0.82 (0.57–1.0) |
| Number of patients | 25 |
| Number of analyzed arteries | 29 |
| Angina class according to CCS, n (%): | |
| CCS 0 | 17/25 (68) |
| CCS 1–2 | 5/25 (20) |
| CCS 3–4 | 3/25 (12) |
| Risk factors of CAD, n (%): | |
| Hypertension | 19/25 (76) |
| Multilevel atherosclerosis | 4/25 (16) |
| Diabetes mellitus type 2 | 10/25 (40) |
| Dyslipidemia | 18/25 (72) |
| Atrial fibrillation | 7/25 (28) |
| Cigarette smoking | 11/25 (44) |
| Past history of CAD, n (%): | |
| Multivessel disease | 13/25 (52) |
| Previous PCI | 9/25 (36) |
| Previous CABG | 2/25 (8) |
| Angiographic data, n (%): | |
| Previous PCI of the analyzed vessel | 6/29 (20.7) |
| Analyzed arteries, n (%): | |
| LM | 2/29 (7) |
| LAD | 16/29 (55) |
| Dg | 3/29 (10) |
| Cx | 4/29 (14) |
| RCA | 4/29 (14) |
| CMR results: | |
| Ischemia in the analyzed territory, n (%) | 12 (41) |
| Ischemia size in the analyzed territory, % | 7.7 (0–15)* |
| Ischemia in other territories, n (%) | 9 (31) |
| Ischemia size in other territories, % | 9.4 (6–18)* |

*Median (IQR), BMI – body mass index, BSA – body surface area, CABG – coronary artery bypass graft, CAD – coronary artery disease, CCS – Canadian Cardiovascular Society grading of angina pectoris, CMR – cardiac magnetic resonance, Cx – circumflex branch of left coronary artery, Dg – diagonal branch of left coronary artery, FFR – fractional flow reserve, LAD – left anterior descending coronary artery, LM – left main coronary artery, LVEF – left ventricular ejection fraction, MI – myocardial infarction, PCI – percutaneous coronary intervention, RCA – right coronary artery.

was 12%. In the second false positive result FFR 0.84 and CMR ischemia 18% were obtained. The patient with a false-negative CMR perfusion result had 0.76 FFR and 9% ischemia.

Discussion

Myocardial perfusion is critical to the supply of oxygen and substrate for contractile function [9]. Generally, low myocardial perfusion can be caused by epicardial coronary artery stenosis as well as abnormal coronary microcirculation [10]. Accurate measurement of ischemic stenoses of the epicardial coronary arteries is essential for reasonable revascularization.

Previous studies have shown the usefulness of qualitative assessment of CMR perfusion imaging for the diagnosis of coronary artery disease (CAD) [11, 12]. The FFR represents one of the most objective methods to determine the hemodynamic significance of CAD [13].

Our study has shown that there is undoubtedly a correlation between the result of CMR perfusion and the invasive functional method FFR (Figure 1). There is no need to perform invasive FFR to confirm or exclude the severity of lesions which were qualified based on CMR perfusion. Moreover, CMR offers an overall assessment of the myocardial tissue including myocardial vitality [14]. Our research enhances the results of previous reports confirming the adequacy and consistency of both methods [15]. However, as mentioned, 3 of 29 results of FFR and CMR perfusion were not consistent. A false-positive test result was related to patients with multivessel coronary artery disease. Moreover, one of them had severe multilevel atherosclerosis and diabetes mellitus type 2, which is associated with failure of the microvascular circulation that probably resulted in a negative invasive functional test in the left anterior descending artery and finally a truly positive CMR perfusion result but recognized in the microcirculation of the myocardium. On the other hand, a false-negative result was obtained in a patient with distal narrowing of the circumflex artery which resulted in multisegment subendocardial stress ischemia that did not reach the level of significance in CMR perfusion.

Ebersberger *et al.* studied 116 patients and demonstrated the accuracy of cardiac CMR perfusion in comparison to FFR as a reference standard, being an adequate method to detect ischemia in lesions with FFR values ≤ 0.80 , with 75% sensitivity, 95% specificity, 86% PPV, and 90% negative predictive value. Myocardial perfusion CMR was demonstrated to be a robust imaging technique in the evaluation of significant coronary lesions [16].

Moreover in 2014, Li *et al.* [2] performed a systemic review and meta-analysis. Their investigation proved the accuracy and reliability of CMR perfusion. They identified 14 studies evaluating 1073 arteries and 650 patients. The pooled sensitivity and specificity were 0.90 and 0.87.

There are some limitations of this study. Our study is retrospective. FFR and CMR perfusion were not performed at the same time but with an interval of 6 months maximum. Moreover, to trigger hyperemia two different medications were used. In CMR perfusion we used dipyridamole, whereas during the FFR procedure we used adenosine.

Conclusions

The present study tried to show that CMR perfusion could be a highly sensitive method to detect hemodynamically significant CAD and potentially can exclude nonsevere lesions. With FFR as the reference standard, the diagnostic accuracy of CMR perfusion to detect ischemic CAD seems to be high. For patients with a high pre-test probability of CAD, CMR perfusion may be applied as a confirmatory test. Nevertheless, these patients are generally recommended for invasive testing regardless of the presence of troublesome symptoms or clinical findings. Consequently, CMR perfusion appears to be the most clinically useful method in patients with an intermediate pre-test probability of CAD [17].

Conflict of interest

The authors declare no conflict of interest.

References

- Chiribiri A, Hautvast GL, Lockie T, et al. Assessment of coronary artery stenosis and location. *JACC Cardiovasc Imaging* 2013; 6: 600-9.
- Li M, Zhou T, Yang L, et al. Diagnostic accuracy of myocardial magnetic resonance perfusion to diagnose ischemic stenosis with fractional flow reserve as reference. *JACC Cardiovasc Imaging* 2014; 7: 1099-105.
- Yang Z, Zheng H, Zhou T, et al. Diagnostic performance of myocardial perfusion imaging with SPECT, CT and MR compared to fractional flow reserve as reference standard. *Int J Cardiol* 2015; 190: 103-5.
- Qayyum A, Kastrup J. Measuring myocardial perfusion: the role of PET, MRI and CT. *Clin Radiol* 2015; 70: 576-84.
- Costa MA, Shoemaker S, Futamatsu H, et al. Quantitative magnetic resonance perfusion imaging detects anatomic and physiologic coronary artery disease as measured by coronary angiography and fractional flow reserve. *J Am Coll Cardiol* 2007; 50: 514-22.
- Pan J, Huang S, Lu A, et al. Comparison of myocardial transmural perfusion gradient by magnetic resonance imaging to fractional flow reserve in patients with suspected coronary artery disease. *Am J Cardiol* 2015; 115: 1333-40.
- Windecker S, Kolh P, Alfonso F, et al. 2014 ESC/EACTS Guidelines on myocardial revascularization. *Eur Heart J* 2014; 35: 2541-619.
- Hussain ST, Paul M, Plein S, et al. Design and rationale of the MR-INFORM study: stress perfusion cardiovascular magnetic resonance imaging to guide the management of patients with stable coronary artery disease. *J Cardiovasc Magn Reson* 2012; 14: 65.
- Braunwald E. Control of myocardial oxygen consumption: physiologic and clinical considerations. *Am J Cardiol* 1971; 27: 416-32.

10. Knaapen P, Camici P, Marques KM, et al. Coronary microvascular resistance: methods for its quantification in humans. *Basic Res Cardiol* 2009; 104: 485-98.
11. Shoemaker S, Costa M, Futamatsu H, et al. Quantitative myocardial magnetic resonance perfusion: comparison with invasive physiologic assessments and quantitative coronary angiography. *J Am Coll Cardiol* 2006; 47: 145.
12. Cerqueira MD, Weissman NJ, Dilsizian V, et al. Standardized myocardial segmentation and nomenclature for tomographic imaging of the heart: a statement for healthcare professionals from the Cardiac Imaging Committee of the Council on Clinical Cardiology of the American Heart Association. *Circulation* 2002; 105: 539-42.
13. Pijls N, De Bruyne B, Peels K, et al. Measurement of fractional flow reserve to assess the functional severity of coronary-artery stenoses. *N Engl J Med* 1996; 334: 1703-8.
14. Okur A, Kantarci M, Karaca L, et al. The utility of cardiac magnetic resonance imaging in Kounis syndrome. *Postep Kardiol Interw* 2015; 11: 218-23.
15. Takx R, Blomberg B, Aidi H, et al. Diagnostic accuracy of stress myocardial perfusion imaging compared to invasive coronary angiography with fractional flow reserve meta-analysis. *Circ Cardiovasc Imaging* 2015; 8: pii: e002666. DOI: 10.1161/CIRCIMAGING.114.002666.
16. Ebersberger U, Makowski MR, Schoepf UJ, et al. Magnetic resonance myocardial perfusion imaging at 3.0 Tesla for the identification of myocardial ischaemia: comparison with coronary catheter angiography and fractional flow reserve measurements. *EHI Cardiovasc Imaging* 2013; 14: 1174-80.
17. Fihn SD, Gardin JM, Abrams J, et al. 2012 ACCF/AHA/ACP/AATS/PCNA/SCAI/STS guideline for the diagnosis and management of patients with stable ischemic heart disease. *J Am Coll Cardiol* 2012; 60: e44-164.