

Right heart catheterization procedures in patients with suspicion of pulmonary hypertension – experiences of a tertiary center

Maciej Grymuza¹, Katarzyna Małaczyńska-Rajpold¹, Stanisław Jankiewicz¹, Andrzej Siniawski², Marek Grygier², Przemysław Mitkowski², Marta Kałużna-Oleksy², Maciej Lesiak², Tatiana Mularek-Kubzdela², Aleksander Araszkievicz²

¹Department of Cardiology, University Hospital of Lord's Transfiguration, Poznan, Poland

²Department of Cardiology, Poznan University of Medical Sciences, Poznan, Poland

Adv Interv Cardiol 2017; 13, 4 (50): 295–301
DOI: <https://doi.org/10.5114/aic.2017.71610>

Abstract

Introduction: Right heart catheterization (RHC) is an invasive procedure providing direct and accurate measurements of hemodynamics of the cardiovascular system. Acute pulmonary vasoreactivity testing (APVT) following basal RHC in some patients is an established tool evaluating the reversibility of hypertension in the pulmonary vasculature.

Aim: We sought to assess the most common indications, vascular approaches and complications during RHC in a single high-volume center.

Material and methods: A total of 534 RHC procedures in 348 patients (64% male) were performed. The prospective registry was carried out for 28 months. Collected data included indications for RHC, vascular approaches, hemodynamic and clinical data, complications and response of pulmonary vessels in APVT.

Results: In 401 (75%) procedures pulmonary hypertension (mean pulmonary artery pressure (mPAP) \geq 25 mm Hg) was confirmed. Left heart failure was the most common indication (55.8%), mainly ischemic (26%) or dilated cardiomyopathy (19.9%). Other indications included a suspicion of arterial (21.7%), or chronic thromboembolic pulmonary hypertension (14.6%). The right internal jugular vein approach was used in 89.1% of procedures. Acute pulmonary vasoreactivity testing was performed in 143 patients, and it was positive in 67 (46.9%) cases. Complications occurred in 21 (3.9%) procedures and included pulmonary edema (0.2%), pneumothorax (0.2%) and puncture of the artery followed by the insertion of a vascular sheath (0.4%), atrial arrhythmia (0.2%), superior vena cava dissection (0.2%), incidental artery puncture (1.1%) and local hematoma (2.2%).

Conclusions: The most frequent indication for RHC was left heart failure, and the most common approach was the right internal jugular vein. RHC is safe procedure with a low rate of major complications.

Key words: complications, indications, acute pulmonary vasoreactivity testing.

Introduction

Right heart catheterization (RHC) is widely used in cardiology, cardiac and thoracic surgery, pulmonology and intensive care, as it provides useful data concerning hemodynamics of the cardiovascular system. This examination was carried out for the first time by Forssmann in 1929, and then further developed by Cournand and Richards [1]. Right heart catheterization is an invasive procedure that enables direct and accurate measurement of the condition of the right heart and pulmonary vessels and indirectly provides information about the left heart [2].

Indications for this examination in adults comprise: 1) diagnosis of pulmonary hypertension, establishing its type, severity and further monitoring, 2) evaluation prior to correction of cardiac shunt defects and 3) eligibility for heart and/or lung transplantation [3]. In some cases baseline hemodynamic evaluation is followed by acute pulmonary vasoreactivity testing (APVT). It assesses the ability of pulmonary arteries to dilate after the administration of a vasodilating drug (e.g. inhaled nitric oxide or iloprost, intravenous nitroglycerin or sodium nitroprusside) [4–7]. Depending on the underlying condition, the purpose of APVT varies from the indication for use

Corresponding author:

Aleksander Araszkievicz MD, PhD, Department of Cardiology, Poznan University of Medical Sciences, 1/2 Długa St, 61-848 Poznan, Poland, phone: +48 608 574 375, fax: +48 61 854 90 94, e-mail: aaraszkievicz@interia.pl

Received: 29.08.2017, **accepted:** 13.10.2017.

of calcium channel blockers in pulmonary arterial hypertension, through the evaluation for correction of cardiac shunt defects to heart and/or lung transplantation [8]. The catheter is placed in the right heart mostly through a central vein [9]. Right heart catheterization is rarely associated with any serious complications; however, its rate is dependent on the clinical status of patients and the operator's and center's experience. Numerous conditions lead to elevation of the pressure in pulmonary arteries and become indications for RHC; their frequency varies in the literature, as does the number of complications [10–14].

Aim

We sought to assess the indications for RHC, as well as occurrence of adverse events, especially serious ones. This study reports the results of RHC procedures in a tertiary hospital taking into consideration the most common underlying conditions, vascular approaches and safety of this procedure.

Material and methods

A single-center prospective registry was carried out from January 2015 to May 2017. Fully informed, written consent for the procedure was obtained from each patient. Three hundred and forty-eight (64% male) patients at the mean age of 54.6 ± 12.4 years with suspicion of pulmonary hypertension had RHC using a Swan-Ganz catheter performed. Collected data included basic demographic data (gender, age) and clinical data such as body surface area, heart rate, systemic blood pressure, comorbidities, pharmacological treatment, indications for RHC, vascular approaches and complications of the procedure. Routes of access were the internal jugular vein, venous angle, depending on the operator's preference, and the femoral vein, if additional conditions were present. Adverse events were classified as major – pulmonary edema, pneumothorax and puncture of carotid artery followed by the insertion of a vascular sheath – and minor: atrial arrhythmia, superior vena cava dissection, incidental artery puncture and local hematoma. Each complication was observed and intervention was undertaken, if necessary. Catheterizations were carried out in the catheterization laboratory, mostly by 5 experienced operators. Some patients were on anticoagulant therapy; it was stopped before the procedure without bridging and started again after 6 h, if no complications occurred. Right heart catheterization was postponed if international normalized ratio (INR) > 2 . Strict aseptic technique and local anaesthesia with lidocaine 2% were used. A 7 Fr sheath was introduced with the modified Seldinger technique. Ultrasound guidance was used prior to 34% of procedures; more often the position of the catheter was confirmed in fluoroscopy. Measured parameters concerning pulmonary circulation were as follows:

mean right atrium pressure, right ventricle pressure (systolic, diastolic and end-diastolic), pulmonary artery pressure (systolic, diastolic and mean), and wedge pressure obtained after catheter balloon inflation at the end of expiration. Cardiac output (CO) was measured with thermodilution with cold saline or the direct Fick method for patients with intracardiac shunts, whereas the cardiac index (CI), pulmonary (PVR), systemic vascular resistance (SVR) and transpulmonary gradient (TPG) were estimated based on previous measurements. After removal of the sheath, pressure was applied to the site and an occlusive dressing was used. The diagnosis of pulmonary hypertension was established if mean pulmonary artery pressure equaled or exceeded 25 mm Hg. Some patients had an acute pulmonary vasoreactivity test with iloprost or nitroglycerin performed. APVT was performed in all patients with idiopathic or familial pulmonary (pre-capillary) hypertension if pulmonary vascular resistance was ≥ 2.5 Wood's units or transpulmonary gradient > 12 mm Hg in patients with pulmonary hypertension due to left heart diseases. Iloprost was administered in the dose of 5 μ g inhaled within about 7 min, and nitroglycerin was administered according to the protocol: in 10-minute IV infusion of 0.2 mg/ml concentration with 20 ml/h flow, which resulted in the total dose of 0.67 ± 0.13 mg being given. The administration was stopped if the systemic systolic blood pressure fell below 85 mm Hg. Measurements were repeated again 10–15 min after administration of a vasodilator. Depending on the underlying condition the response of the vessels was assessed according to current guidelines. In precapillary pulmonary hypertension positive criteria for APVT were as follows: mean pulmonary artery pressure decrease of at least 10 mm Hg and below 40 mm Hg with increased or unchanged cardiac output. For postcapillary pulmonary hypertension PVR and TPG were taken into assessment and the APVT was considered positive if they decreased to < 2.5 WU and < 12 mm Hg respectively, without a systemic systolic blood pressure drop below 85 mm Hg. Continuous variables are expressed as mean or median and categorical data are reported as frequencies and percentages.

Statistical analysis

Descriptive statistics were completed using Statistica 12, Statistica, USA, Oklahoma, Tulsa.

Results

Five hundred and thirty-four right heart catheterizations were carried out comprising 6% of all procedures in our catheterization laboratory. Those procedures were performed in 348 patients (64% male). One hundred and eight patients had more than one RHC performed (2–6 procedures). Serial assessment were required in: 1) monitoring and requirement of modifications of treatment and aggravations of pulmonary arterial hyperten-

sion (PAH) as well as 2) according to ISHLT guidelines, monitoring of patients (every 3–6 months) on hold for heart transplantation [15]. Pulmonary hypertension was confirmed in 75% (*n* = 401) of procedures and in 10% (*n* = 56) of cases mean pulmonary artery pressure of unclear significance ($25 \text{ mm Hg} < \text{mPAP} \leq 21 \text{ mm Hg}$) was present. The results of RHC are shown below (Table I). Only in one case was the examination not performed due to pulmonary valve stenosis. To estimate cardiac output the thermodilution method was used in 97% (*n* = 518) of catheterizations, and the direct Fick method in 3% (*n* = 16) of procedures. Arterial blood gases were taken before CO measurement in 36% (*n* = 194) of catheterizations from patients who suffered from pulmonary arterial hypertension or chronic thromboembolic pulmonary hypertension. At the time of 53% (*n* = 281) of procedures patients were on chronic anticoagulant therapy, which was stopped before and introduced after the procedure as described previously. 3.7% (*n* = 20) of procedures were managed, while clopidogrel therapy was applied, without stopping. Pulmonary circulation targeted therapy was given in 230 patients and 38% (*n* = 204) of interventions; the drugs were sildenafil, treprostinil, bosentan, eprospatenol, iloprost, riociguat, macitentan single or combined. Dopamine and dobutamine were administered during examination in 1.3% (*n* = 7) of cases, and in 1.1% (*n* = 6) of cases one of those drugs was given.

All procedures were elective, done in an inpatient setting. The most frequent indication was left heart failure: 55.8% (*n* = 298) of all procedures (Figure 1). The etiology of this condition was ischemic cardiomyopathy in 26% (*n* = 139) of cases, then dilated cardiomyopathy in 19.9% (*n* = 106) and hypertrophic cardiomyopathy in 3.6% (*n* = 19) (Figure 2). In this group elevated pulmonary pressure was present after heart transplantation in 2% (*n* = 11) of patients. Other indications were: suspicion of arterial 21.7% (*n* = 116), and chronic thromboembolic pulmonary hypertension 14.6% (*n* = 78). Much less common were interstitial lung diseases: idiopathic pulmonary fibrosis in 3.6% (*n* = 19) and systemic sclerosis in 3.4% (*n* = 18) (Figure 3).

The vascular approach of choice was the right internal jugular vein in 89.1% (*n* = 476) with limited participation of the venous angle in 9.2% (*n* = 49), and only minimal use of the femoral vein (1.1%, *n* = 6) and left internal jugular vein (0.6%, *n* = 3).

Acute vasoreactivity testing of pulmonary vessels was performed in 143 procedures, 62% (*n* = 89) with iloprost and 38% (*n* = 54) with nitroglycerin. Positive criteria for APVT were noted in 45.4% (*n* = 65) of cases regardless of the underlying condition or applied drug. This examination was carried out in 80.4% (*n* = 115) of patients with postcapillary pulmonary hypertension, who were evaluated for heart transplantation and in 19.6% (*n* = 28) of patients with precapillary pulmonary hypertension to de-

Table I. Mean values and standard deviation of parameters obtained during RHC

Parameter	Mean value	Standard deviation
Heart rate [1/min]	75.1	12.9
Systemic blood pressure [mm Hg]	95.6	15.6
Mean right atrium pressure [mm Hg]	8.6	6.8
Right ventricle pressure [mm Hg]:		
Systolic	55.4	40.2
Diastolic	7.1	7.5
Mean	13.1	7.9
Pulmonary artery pressure [mm Hg]:		
Systolic	53.7	22.9
Diastolic	24.7	10.9
Mean	36.8	14.8
Wedge pressure [mm Hg]	15.6	8.5
Transpulmonary gradient [mm Hg]	21.3	15.4
Cardiac output [l/min]	5.5	1.7
Cardiac index [l/min]	2.9	0.8
Pulmonary vascular resistance [dyn · s/cm ⁵ · m ²]	333.5	317.4
Systemic vascular resistance [dyn · s/cm ⁵ · m ²]	1336.4	451

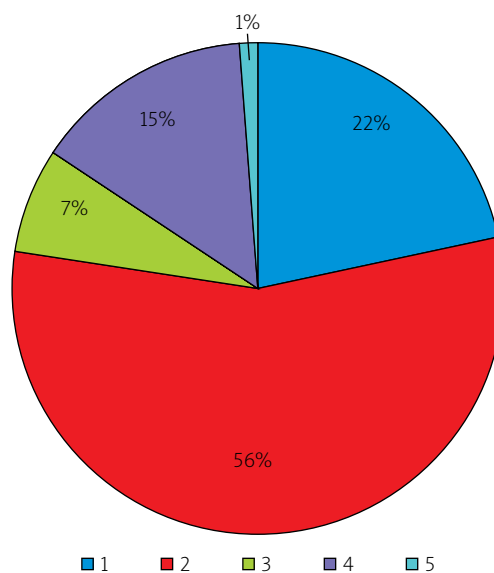


Figure 1. Classes of pulmonary hypertension diagnosed in examined patients. Class 1 – pulmonary arterial hypertension, class 2 – pulmonary hypertension due to left heart disease, class 3 – pulmonary hypertension due to lung diseases and/or hypoxia, class 4 – chronic thromboembolic pulmonary hypertension, class 5 – pulmonary hypertension with unclear mechanism

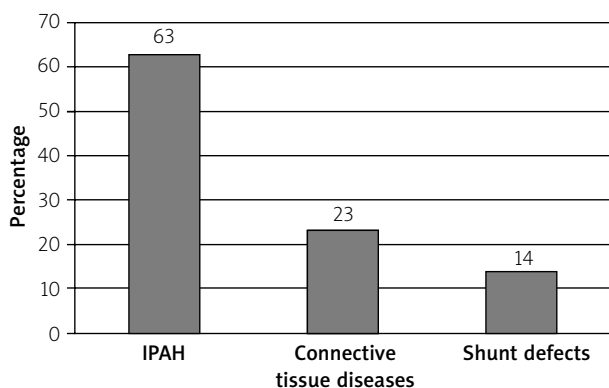


Figure 2. Conditions qualified as class 1 PH (pre-capillary PH). Connective tissue diseases are systemic sclerosis, systemic lupus erythematosus, Sjögren disease and rheumatoid arthritis. Shunt defects are atrial septal defect, ventricular septal defect, patent ductus arteriosus and atrioventricular septal defect

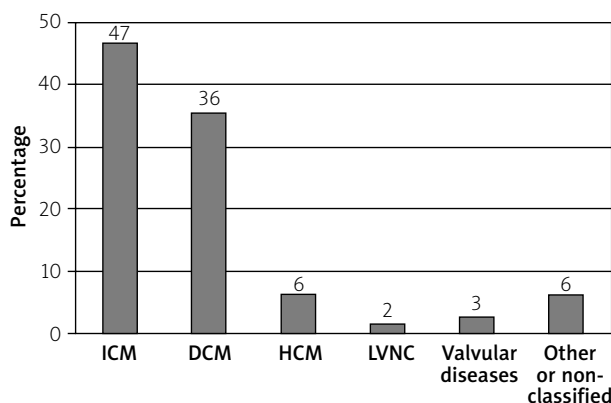


Figure 3. Conditions qualified as class 2 PH (post-capillary PH)

ICM – ischemic cardiomyopathy, DCM – dilated cardiomyopathy, HCM – hypertrophic cardiomyopathy, LVNC – left ventricular non-compaction cardiomyopathy.

termine the indication for treatment with calcium channel blockers. Positive criteria were noted in 53% ($n = 61$) and 14.3% ($n = 4$) of procedures, respectively (Table II).

Complications were noted in 21 (3.9%) interventions. The major ones were as follows: pulmonary edema, pneumothorax occurring in one patient each and puncture of the artery followed by the insertion of a vascular sheath in two cases; one was the carotid artery and the other the subclavian artery. Those complications caused discontinuation of the procedure. In the first case hypertrophic cardiomyopathy was the underlying condition of a 56-year-old patient, who developed pulmonary edema during acute vasoreactivity testing with iloprost. Introduced management included diuretics, oxygen, morphine and prolonged hospitalization. Artery puncture with the insertion of a 7 Fr vascular sheath in one case was closed with the StarClose SE Vascular Closure

System (Abbott Vascular, Santa Clara, CA, USA) and verified with angiography, while in another case the sheath was removed and prolonged manual compression was applied. None of those patients presented any neurological defects or hematoma at the injection site. Despite those complications, examinations were completed after the patient’s stabilization, during the same hospitalization. Pneumothorax was diagnosed after venous angle puncture. The patient was intubated due to respiratory failure, drugs were applied (oxygen, theophylline, morphine, salbutamol), drained and he was transferred to the intensive care unit. Minor complications were present in 17 procedures and included mild, spontaneously resolved arrhythmia in 1 (0.2%) procedure, superior vena cava dissection in 1 (0.2%) procedure, local hematoma in 9 (1.7%) patients, which were of minimal danger and did not require any intervention, and incidental artery puncture in 3 (0.6%) patients; in those cases the needle was immediately removed and compression was applied. In 3 (0.6%) cases both hematoma and artery puncture were present in one patient. Superior vena cava dissection was noted after right internal jugular vein puncture and catheter introduction. Dissection reached the right atrium, did not bring any other complications and the procedure was continued. We did not observe more frequent complications if repetitive catheterizations were performed. No patient presented pulmonary hemorrhage, pulmonary artery rupture, air embolism or infection. No deaths directly associated with RHC or its complications were noted.

Table II. Response to APVT according to applied drug and type of pulmonary hypertension

Parameter	Iloprost	Nitroglycerin
Precapillary PH:		
Number of patients	26 (93%)	2 (7%)
Percentage of positive criteria of APVT	15.4% ($n = 4$)	0
Percentage of negative criteria of APVT	84.6% ($n = 22$)	100% ($n = 2$)
Postcapillary PH:		
Number of patients	63 (55%)	52 (45%)
Percentage of positive criteria of APVT	46% ($n = 29$)	61.5% ($n = 32$)
Percentage of negative criteria of APVT	54% ($n = 34$)	38.5% ($n = 20$)

Discussion

The main findings of this study are as follows: 1) Left heart diseases are the most common reasons for performing RHC in our center, 2) The right internal jugu-

lar vein is a safe and easily reached access, 3. RHC performed in our center does not lead to fatal complications and major complications are rare.

In the vast majority of cases in which right heart catheterization was performed, there were underlying cardiology conditions: heart failure, and to a lesser degree pulmonary arterial hypertension and chronic thromboembolic pulmonary hypertension (cTEPH). Indications presented by other authors vary to a great extent. In a large, multicenter study diagnosis of left heart failure was present in less than 10%, and other studies report this condition in less than 20% [10–12, 14]. Furthermore, frequency of pulmonary arterial hypertension fluctuates in other research from 3.5% to 66%, being particularly similar to our in the study of Lee [10–12, 14, 16]. The RHC is also obligatory in diagnosis of CTEPH; this condition is quite infrequent, yet as an indication for RHC in our center the frequency is similar to others (13% vs. 14.6%) [11, 17]. Frequency of evaluation of intracardiac shunts in the literature varies from 3% to 60%; our results are comparable to the research of Shah *et al.* (2.9% vs. 3%) [12, 16]. This variety in percentage of indications occurs as different reports present various groups of patients dependent on center type and profile (its reference, transplant center), wards where RHC was carried out (cardiology, intensive care unit, pulmonology), patients' condition: RHC acute or planned performance, in- or out-patient RHC, and number of patients.

The results of the present study indicate that the most common approach was the right internal jugular vein; this approach is suggested in ESC as well as in local recommendations [3, 18]. Concerning this aspect, our study can be compared to other analyses. Ranu *et al.* used this access in 330 out of 349 patients in their analysis, the only alternative access was the left internal jugular vein [19]. Some centers adopt the subclavian vein as often as the femoral vein, but still they point out that the latter is associated with greater risk of infectious and thrombotic complications [20]. In another group of 295 right heart catheterizations there was a slight preference for neck access (174) over arm access (121) [10]. In the prospective arm of a large, multicenter study, which included 1491 patients, the internal jugular vein was used in more than 70% of procedures; less common were brachial, femoral and subclavian accesses [14]. Basilic veins were not used in any patient in our center. However, some centers prefer this access to others, but even then the femoral vein is also adopted [11, 16]. The right internal jugular vein is a reasonable approach regarding recommendations as well as previous studies.

A vasoreactivity test was carried out in 143 patients; 45.5% of them were classified as responders, 37.1% with iloprost and 59.3% with nitroglycerin. The latter is not standard recommended vasodilator, although it was used in APVT in previous studies on small groups of patients and is mentioned in some local guidelines

[5, 21]. The percentage of reversibility achieved in other studies is comparable to ours, but the agents applied differ, as nitric oxide and nifedipine were also administered [22, 23]. Concerning patients suffering from PAH, iloprost is rarely used as a vasodilator; in some analyses its effectiveness is similar to the present study (14% vs. 15.4%). Another compound, epoprostenol, is reported to be a more potent agent, reaching 31% reversibility [6, 24]. The study of Hoepfer *et al.* characterized iloprost to be more efficient than nitric oxide [25]. Nonetheless, some research on candidates for heart transplantation reported the use of not only nitroglycerin and prostacyclin, but also sodium nitroprusside, which was not assessed in the present study [26]. Comparable outcomes were achieved by Torres Macho *et al.* – almost 50% of patients who happened to be responders (vs. 53% in this study) used vasodilators including nitroglycerin, sodium nitroprusside and prostacyclin, but no significant differences between groups in response to the vasoreactivity test were noted [5]. Some studies carried out on small groups of patients with slightly different vasodilators show a higher percentage of reversibility of this type of pulmonary hypertension – almost 80% [26].

The frequency of complications noted in the present study was nearly 4%; it is more than in the study by Hoepfer *et al.*, who noted about 1% complications, and some other studies with a similar frequency of adverse events, which is 0.6–1.8% [10–12, 19]. However, our results in terms of percentage of complications are comparable to some others, reaching 3–6% [27–29]. McGee and Gould in their review noted frequency of complications even up to 20%, depending on the access site [13]. Frequency of puncture of the artery followed by the insertion of a vascular sheath is noted in the literature at less than 1%. In a retrospective 11-year-long study, Bechara *et al.* noted this complication 12 times. Similarly to ours, they were followed by neither neurological defect nor other events, and management of this complication in their study was comparable to ours [30]. Pneumothorax is an uncommon complication, but more likely to be present if subclavian access is used [13]. A review reports this event in the mentioned approach at about 1.5–3.1%; thus it is more than in our study and almost identical to Hoepfer's [13, 14]. Pulmonary edema after pulmonary vasoreactivity testing with a prostacyclin analogue is rarely mentioned in literature [31] and superior vena cava dissection during RHC has not been reported so far.

Artery puncture is a common difficulty, especially in patients with severe hypoxemia and low CO as the arterial blood color and flow resemble venous ones. In observational studies, the frequency ranges from 0.1% to 9%, and a review reported about 6.3–9.4% of all procedures in which the access site was the internal jugular vein [10, 13, 20, 27, 32]. This complication is more common in femoral access and infrequent in antecubital access [10, 20]. Local hematoma is also a common complication and our experience is comparable to others. In the present study

it appeared in 2%, while rates given in the literature are 0.1–2.2% [13, 14]. Likewise, arrhythmias are reported in previous studies in a similar percentage [14]. Frequency of adverse events, especially more serious, appear mainly in research in which a greater number of patients was taken into consideration [9, 13, 14, 33]. Complications such as artery puncture with/without insertion of a vascular sheath depend on access site and operator's experience. Hematomas are usually not serious, but difficult to avoid and appear in most studies with similar commonness. This registry does not differ from previous studies in terms of the number of complications. Serious ones were properly managed, and did not lead to permanent disability. Remarkably, we did not observe some serious events present in other studies, such as vagal reaction, vein thrombosis, pulmonary artery rupture or transient ischemic attack and deaths associated directly with RHC.

Conclusions

Right heart catheterization is carried out in numerous conditions, particularly it is carried out in patients suffering from left heart failure, chronic thromboembolic pulmonary hypertension and pulmonary arterial hypertension, which contributes to the indications for RHC. Central venous access seems to have an acceptable safety and feasibility profile. The RHC is a harmless procedure, and complications are rare, especially when ultrasound- and/or fluoroscopy-guided. Caution is required when performing APVT in patients with left heart failure with severe restriction of the left ventricle.

Conflict of interest

The authors declare no conflict of interest.

References

1. Chatterjee K. The Swan-Ganz catheters: past, present, and future: a viewpoint. *Circulation* 2009; 119: 147-52.
2. Kałużna-Oleksy M, Araszkievicz A, Migaj J, et al. "From right to left": the role of right heart catheterization in the diagnosis and management of left heart diseases. *Adv Clin Exp Med* 2017; 26: 135-41.
3. Galiè N, Humbert M, Vachiéry JL, et al. 2015 ESC/ERS Guidelines for the diagnosis and treatment of pulmonary hypertension. *Eur Heart J* 2015; 37: 67-119.
4. Costard-Jackle A, Fowler MB. Influence of preoperative pulmonary artery pressure on mortality after heart transplantation: testing of potential reversibility of pulmonary hypertension with nitroprusside is useful in defining a high risk group. *J Am Coll Cardiol* 1992; 19: 48-54.
5. Torres Macho J, Delgado Jimenez JF, Sanz Salvo J, et al. Effect of different pharmacologic agents to reverse severe pulmonary hypertension among end-stage heart failure patients. *Transplant Proc* 2009; 41: 2477-9.
6. Jing ZC, Jiang X, Han ZY, et al. Iloprost for pulmonary vasodilator testing in idiopathic pulmonary arterial hypertension. *Eur Respir J* 2009; 33: 1354-60.
7. Semigran MJ, Cockrill BA, Kacmarek R, et al. Hemodynamic effects of inhaled nitric oxide in heart failure. *J Am Coll Cardiol* 1994; 24: 982-8.
8. Kurzyna M, Araszkievicz A, Błaszczak P, et al. Summary of recommendations for the haemodynamic and angiographic assessment of the pulmonary circulation. Joint statement of the Polish Cardiac Society's Working group on pulmonary circulation and association of cardiovascular interventions. *Kardiologia Pol* 2015; 73: 63-8.
9. Kalińczuk Ł, Chmielak Z, Dębski A, et al. Percutaneous retrieval of centrally embolized fragments of central venous access devices or knotted Swan-Ganz catheters. Clinical report of 14 retrievals with detailed angiographic analysis and review of procedural aspects. *Adv Interv Cardiol* 2016; 12: 140-55.
10. Harwani N, Chukwu E, Alvarez M, Thohan V. Comparison of brachial vein versus internal jugular vein approach for access to the right side of the heart with or without myocardial biopsy. *Am J Cardiol* 2015; 116: 740-3.
11. Roule V, Ailem S, Legallois D, et al. Antecubital vs femoral venous access for right heart catheterization: benefits of a flashback. *Can J Cardiol* 2015; 31: 1497.e1-6.
12. Shah S, Boyd G, Pyne CT, et al. Right heart catheterization using antecubital venous access: feasibility, safety and adoption rate in a tertiary center. *Catheter Cardiovasc Interv* 2014; 84: 70-4.
13. McGee D, Gould M. Preventing complications of central venous catheterization. *N Engl J Med* 2003; 348: 2684-6.
14. Hoepfer MM, Lee SH, Voswinckel R, et al. Complications of right heart catheterization procedures in patients with pulmonary hypertension in experienced centers. *J Am Coll Cardiol* 2006; 48: 2546-52.
15. Mehra MR, Kobashigawa J, Starling R, et al. Listing criteria for heart transplantation: International Society for Heart and Lung Transplantation Guidelines for the Care of Cardiac Transplant Candidates-2006. *J Hear Lung Transplant* 2006; 25: 1024-42.
16. Lee SH, Chun KJ, Lee DS, et al. Right cardiac catheterization using the antecubital fossa vein in Korean patients. *Korean Circ J* 2016; 46: 207-12.
17. Kurzyna M, Darocha S, Koteja A, et al. Balloon pulmonary angioplasty for chronic thromboembolic pulmonary hypertension. *Postępy Kardiologii Interwencyjnej* 2015; 11: 1-4.
18. Kurzyna M, Araszkievicz A, Błaszczak P, et al. Standardy hemodynamicznej i angiograficznej oceny krążenia płucnego. *Kardiologia Pol* 2014; 72 Suppl I: 45-64.
19. Ranu H, Smith K, Nimako K, et al. A retrospective review to evaluate the safety of right heart catheterization via the internal jugular vein in the assessment of pulmonary hypertension. *Clin Cardiol* 2010; 33: 303-6.
20. Merrer J, De Jonghe B, Golliot F, et al. Complications of femoral and subclavian venous catheterization in critically ill patients: a randomized trial. *JAMA* 2001; 286: 700-7.
21. de Jonge N, Kirkels JH, Klöpping C, et al. Guidelines for heart transplantation. *Neth Heart J* 2008; 16: 79-87.
22. Sitbon O, Brenot F, Denjean A, et al. Inhaled nitric oxide as a screening vasodilator agent in primary pulmonary hypertension: a dose-response study and comparison with prostacyclin. *Am J Respir Crit Care Med* 1995; 151: 384-9.
23. Ricciardi MJ, Knight BP, Martinez FJ, Rubenfire M. Inhaled nitric oxide in primary pulmonary hypertension: a safe and effective agent for predicting response to nifedipine. *J Am Coll Cardiol* 1998; 32: 1068-73.

24. Grignola JC, Domingo E, Aguilar R, et al. Acute absolute vasodilatation is associated with a lower vascular wall stiffness in pulmonary arterial hypertension. *Int J Cardiol* 2013; 164: 227-31.
25. Hoeper MM, Olschewski H, Ghofrani HA, et al. A comparison of the acute hemodynamic effects of inhaled nitric oxide and aerosolized iloprost in primary pulmonary hypertension. *J Am Coll Cardiol* 2000; 35: 176-82.
26. Murali S, Uretsky BF, Armitage JM, et al. Utility of prostaglandin E1 in the pretransplantation evaluation of heart failure patients with significant pulmonary hypertension. *J Heart Lung Transplant* 1992; 11: 716-723.
27. Rich S, Dantzker DR, Ayres SM, et al. Primary pulmonary hypertension. A national prospective study. 1987; 107: 216-23.
28. Elliott CG, Zimmerman GA, Clemmer TP. Complications of pulmonary artery catheterization in the care of critically ill patients. A prospective study. *Chest J* 1979; 76: 647-52.
29. Mark S, Calderon-Artero P, Kakinami L, et al. Review of ambulatory pulmonary artery catheterization in the management of advanced heart failure. *Congest Heart Fail* 2012; 18: 173-8.
30. Bechara CF, Barshes NR, Pisimisis G, et al. Management of inadvertent carotid artery sheath insertion during central venous catheter placement. *JAMA Surg* 2013; 148: 1063-6.
31. Strange C, Bolster M, Mazur J, et al. Hemodynamic effects of epoprostenol in patients with systemic sclerosis and pulmonary hypertension. *Chest* 2000; 118: 1077-82.
32. Richard C, Anguel N, Deye N, Combes A. Early use of the pulmonary artery catheter and outcomes in patients with shock. *JAMA* 2003; 290: 2713-20.
33. Rudziński PN, Henzel J, Dzielińska Z, et al. Pulmonary artery rupture as a complication of Swan-Ganz catheter application. Diagnosis and endovascular treatment: a single centre's experience. *Adv Interv Cardiol* 2016; 12: 135-9.