

The PENUMBRA Lightning 12 system for treatment of acute intermediate-high pulmonary embolism. Initial experience in Pulmonary Circulation Center Krakow, Poland

Jakub Stępniewski^{1,2,3}, Wojciech Magoń^{1,2,3}, Piotr Podolec³, Grzegorz Kopeć^{1,3}

¹Pulmonary Circulation Centre, Jagiellonian University Medical College, Krakow, Poland

²Department of Medical Education, Jagiellonian University Medical College, Krakow, Poland

³Department of Cardiac and Vascular Diseases, John Paul II Hospital, Krakow, Poland

Adv Interv Cardiol 2022; 18, 3 (69): 314–316
DOI: <https://doi.org/10.5114/aic.2022.120974>

Lightning 12 is a next-generation catheter-directed aspiration thrombectomy system, which has recently been introduced to the European market for the reperfusion treatment of acute pulmonary embolism (PE) [1]. Larger size, 12 French embolectomy catheters and the innovative computer-aided aspiration system potentially translate into improved efficacy and safety. As yet, little evidence has been collected.

We aim to share our first experience with the use of this device.

A 61-year-old man with no identifiable venous thromboembolism risk factors was admitted to a district hospital emergency room due to sudden dyspnea with syncope. He had a four-day history of right limb deep venous thrombosis and progressing decrease of exercise capacity. At admission he was normotensive with systolic blood pressure (SBP) of 110 mm Hg, had tachycardia of 120–150 beats per minute (bpm) and hypoxemia with arterial blood oxygen saturation (SatO₂) of 80% improving to 88% on mask oxygen supplementation. Computed tomography pulmonary angiography (CTPA) showed bilateral, central clots and a right-to-left ventricular ratio (RV/LV ratio) of 2.0 (Figure 1). Simplified Pulmonary Embolism Severity Index of 2 with radiological and laboratory signs of the RV dysfunction (blood level of high-sensitivity troponin T levels was 0.107 ng/ml (N < 0.014)) indicated intermediate-high risk of early death according to the European Society of Cardiology guidelines [2]. Low-molecular weighted heparin was the initial treatment. As there was no improvement in the clinical status, vital signs, or RV function during 12 h of anticoagulation together with increasing blood levels of troponins,

the patient was transferred to the John Paul II Hospital Pulmonary Embolism Response Team (PERT) in Krakow. The indication for reperfusion therapy was determined by the PERT, composed of a PE invasive specialist and cardiac surgeon, and the patient underwent an urgent catheter-directed procedure. Mechanical thrombectomy using the Lightning 12 system, Indigo 12 XTORQ aspiration catheter and Separator 12 was performed from femoral vein access aiming for rapid RV debulking. Right and left pulmonary intermediate arteries and segmental arteries of the lower, middle and upper lobes of the right and lower lobes of the left lung were targeted, leading to evacuation of massive clots (Figure 1). Hemodynamic parameters including right atrial and pulmonary artery pressures improved from 14 to 13 mm Hg and 65/24/39 to 44/21/29 mm Hg respectively. Radiation dose was 145 mGy, contrast media 180 ml and the blood loss did not exceed 350 ml with a maximal postprocedural hemoglobin decrease from 12 to 11 g/dl. No complications occurred. N-terminal proBNP level improved from 14425 pg/ml to 10705 pg/ml (5 h after the procedure) and to 2520 pg/ml (48 h after the procedure). The CTPA RV/LV ratio improved to 1.15. The patient was mobilized on the second post-procedural day and discharged home on the 7th on rivaroxaban with no exertional dyspnea.

The Lightning 12 system proved to be feasible and safe for rapid RV function improvement. Apart from the larger lumen and improved steerability of the catheter, an important innovation compared to the former version is an intelligent, computer-aided aspiration system, which supports more complete thrombus removal and protects against excessive blood loss. Still, however, blood loss,

Corresponding author:

Jakub Stępniewski MD, PhD, Pulmonary Circulation Centre, Department of Cardiac and Vascular Diseases, Jagiellonian University Medical College, John Paul II Hospital, Department of Medical Education, Jagiellonian University Medical College, Krakow, Poland,
e-mail: jakub.stepniewski@gmail.com

Received: 12.09.2022, accepted: 11.10.2022.

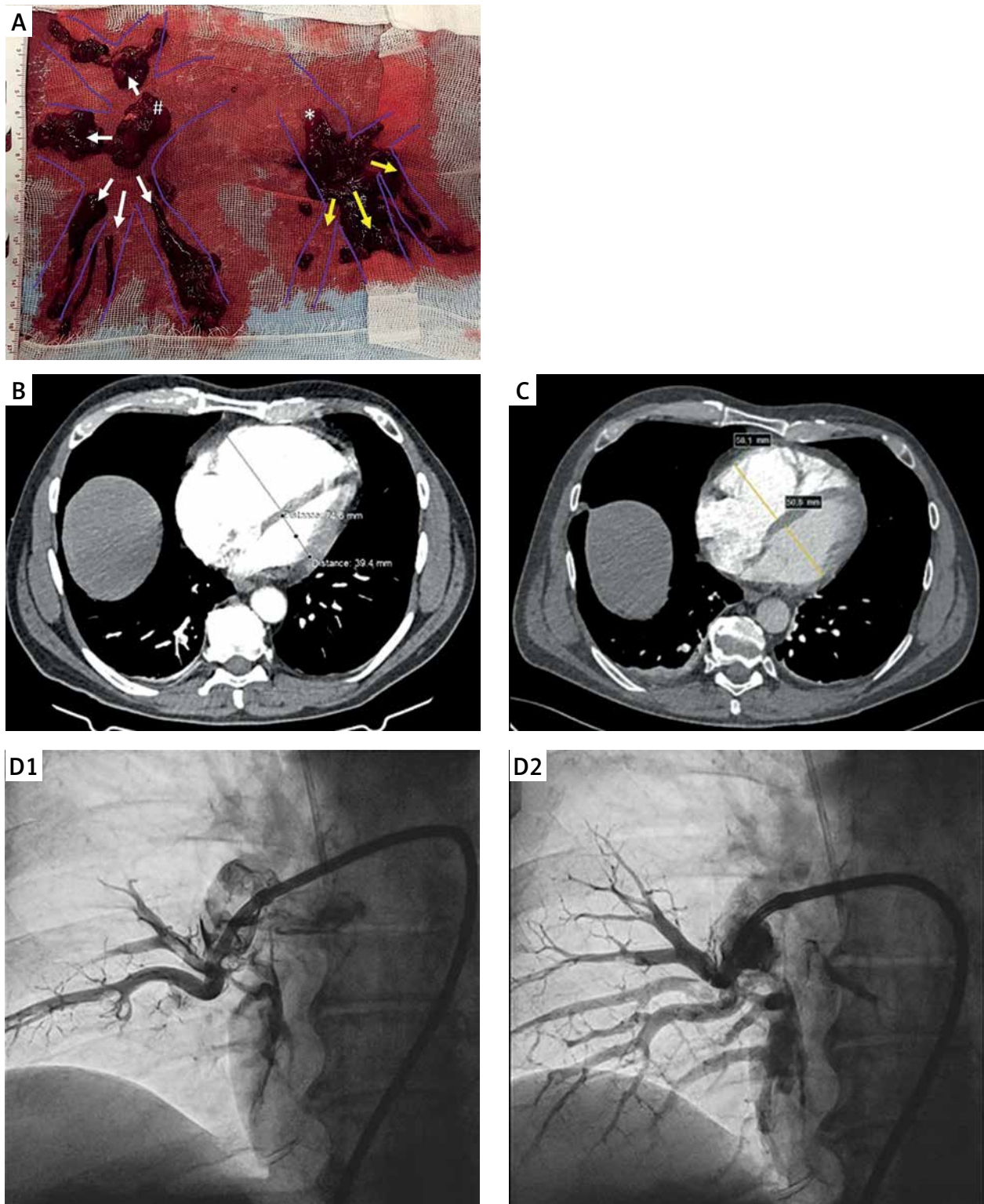


Figure 1. A – Evacuated clots from the right (#) and left (*) pulmonary intermediate arteries, segmental arteries of the lower, middle and upper lobes of the right (white arrows) and lower lobes of the left (yellow arrows) lung using the PENUMBRA Lightning 12 system in a patient with intermediate-high risk acute pulmonary embolism refractory to parenteral anticoagulation leading to a rapid right ventricular function improvement with a decrease in the right-to-left ventricular ratio (RV/LV ratio) from 2.0 (B) to 1.15 (C) and improvement in right (D1 and D2)

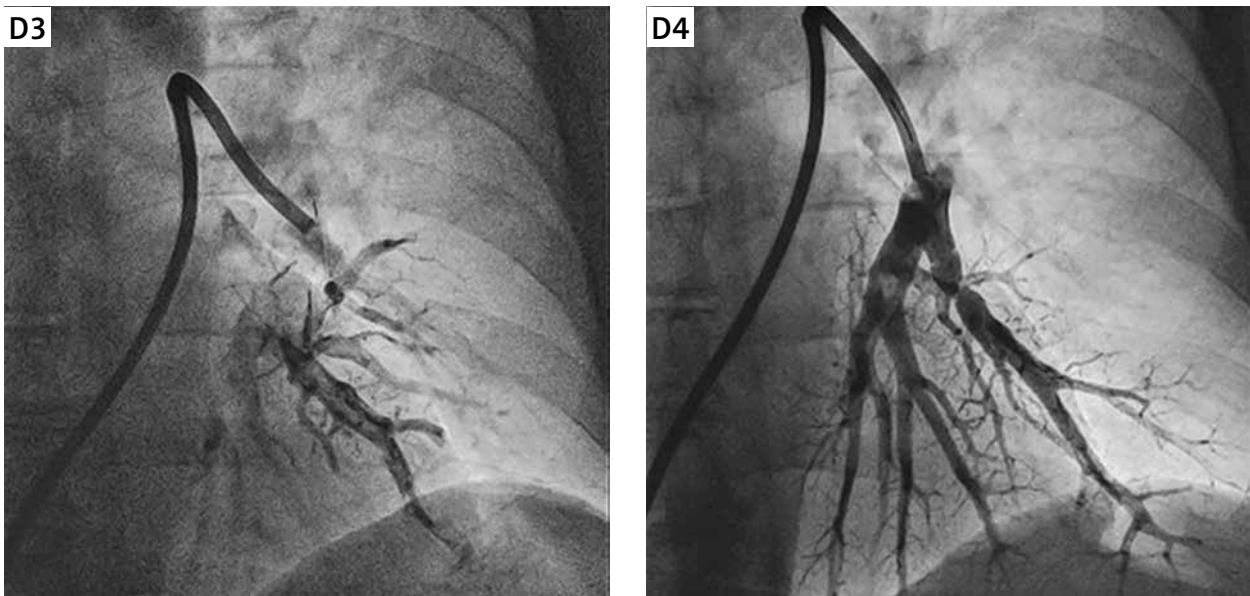


Figure 1. Cont. (D3 and D4) pulmonary artery perfusion in angiography

which depends on multiple factors such as thrombus location, its susceptibility to aspiration or the operator's experience, may limit the result of this procedure. The Lightning 12 system is, together with catheter-directed low-dose local thrombolysis, one of the important pulmonary artery reperfusion techniques currently available [3, 4].

Acknowledgments

This article was supported by the science fund of the John Paul II Hospital, Cracow, Poland (no. FN/07/2022 to J.S.).

Conflict of interest

The authors declare no conflict of interest.

References

1. Araszkiwicz A, Sławek-Szmyt S, Jankiewicz S, et al. Lightning 12 – a new player in the field of pulmonary percutaneous mechanical thrombectomy. *Kardiologia Polska* 2022; 80: 956-7.
2. Konstantinides SV, Meyer G. The 2019 ESC Guidelines on the diagnosis and management of acute pulmonary embolism. *Eur Heart J* 2019; 40: 3453-5.
3. Stepniewski J, Kopeć G, Musiatek P, et al. Hemodynamic effects of ultrasound-assisted, catheter-directed, very low-dose, short-time duration thrombolysis in acute intermediate-high risk pulmonary embolism (from the EKOS-PL Study). *Am J Cardiol* 2021; 141: 133-9.
4. Łabek A, Potępa M, Jermakow M, et al. One-day experience of pulmonary embolism response team (PERT) during the COVID-19 pandemic: three urgent percutaneous pulmonary embolectomies in acute pulmonary embolism. *Adv Interv Cardiol* 2021; 17: 109-11.