

SILS cholecystectomy – our first experiences

Waldemar Kurpiewski, Wiesław Pesta, Marek Kowalczyk, Leszek Głowacki, Wit Juśkiewicz

Department of General and Minimally Invasive Surgery, University Hospital and Clinics, Olsztyn

Videosurgery and other miniinvasive techniques 2009; 4 (3): 91-94

Abstract

Introduction: Persistent urge to minimize operative trauma and improve the cosmetic effect after surgical treatment in recent years has contributed to the introduction of new minimally invasive techniques such as NOTES and SILS.

Aim: To present our first experience with SILS cholecystectomy performed via single access through the navel.

Material and methods: From February to June 2009, twenty-five SILS cholecystectomies were carried out using three 5 mm trocars inserted into the peritoneal cavity through a 2.5 cm-transverse incision in the umbilicus. Regular laparoscopic instruments were used.

Results: The average time of operation was 74.2 min. In one case, conversion to classic 4 trocar laparoscopy was necessary, for pressure could not be maintained due to dilation of trocars. In one patient an additional trocar was introduced in the right epigastrium due to difficulty in preparation of Calot's triangle. Laparotomy was necessary in one case for biliary peritonitis as a consequence of Luschka duct overlooked during open surgery.

Conclusions: In our experience SILS cholecystectomy is a procedure that can be safely performed with existing laparoscopic instruments. The main benefit of this technique is a very good cosmetic effect, as the scar after the procedure is hardly visible.

Key words: SILS, laparoscopy, cholecystectomy.

Introduction

Acknowledging laparoscopic cholecystectomy as a gold standard for gallbladder removal in 1992 has started an array of trials to improve laparoscopic technique. Another issue was amelioration of the cosmetic effect, minimization of post-operative pain and shortening of the recovery of normal function [1]. Since size of the surgical incision is known to determine patient recovery after a correctly performed procedure, reduction of the number of performed incisions became an important goal. At the beginning of the 21st century this gave rise to the idea of NOTES – natural orifice transluminal endoscopic surgery. However, soon after SAGES (the Society of American Gastrointestinal and Endoscopic Surgeons) announced, at the beginning of 2005, the

NOTES era which was supposed to be a successor of laparoscopy, the lack of appropriate endoscopic instruments, high cost, long learning curve and risk of severe complications proved to be severe limitations to popularization of this method at its present stage [2].

Single incision laparoscopic surgery (SILS) has become an alternative or rather a transitional step between classic laparoscopy and NOTES. Its biggest advantages are that existing laparoscopic appliances are sufficient to perform the surgery and that it does not need any particular, additional skills from the surgeon, thus resulting in a very short learning curve. In fact, Giuseppe Navarra in 1997 was the very first to accomplish cholecystectomy from a single incision in the navel with two 10 mm trocars and 3 trans-gumental sutures retracting the fundus and neck of

Address for correspondence:

Waldemar Kurpiewski, Department of General and Minimally Invasive Surgery, University Hospital and Clinics, 30 Warszawska St, 10-082 Olsztyn, fax +48 89 542 32 34, e-mail: wkurpiewski@interia.pl

the gallbladder, yet despite better achieved cosmetic effect, the longer duration of the surgery, similar post-op pain and more frequent hernia in umbilical cicatrices all severely weakened his enthusiasm. He believed this method was of only marginal importance. For the following 10 years, Navarra applied it in isolated cases only [3]. The true heyday of SILS occurred in 2007-2008, when the first trials to remove the gallbladder from a single small incision in the navel were described [1, 4, 5].

Material and methods

A group of 25 patients with ultrasound-diagnosed gallstones and treated with SILS cholecystectomy between 24 February and 9 June 2009 were included in the study. To ensure uniformity of the data, two patients operated on with a Covidien SILS port were not included in the study. The group consisted of 22 women and 3 men, with mean age of 43.7 years (range: 21-73). Mean BMI in the group was 26.5 kg/m² (range: 18.59-37.92). In spite of the general rule to qualify only patients for non-emergency surgery, two patients with acute cholecystitis underwent SILS cholecystectomy. Patients with ASA III or more were not scheduled for this type of surgery.

Operative technique

In the supine patient position the umbilicus was grabbed with Kocher forceps, turned inside out and cut transversally 2 cm long. After the skin was incised, the scar was cut off the fascia, which allowed for easier introduction of trocars. Pneumoperitoneum was inflated up to 12 mm Hg with carbon dioxide through the Veress needle, and three 5 mm trocars were placed. The first one, 100 mm long (Genicon Europe Ltd), was introduced in the midline, exactly where the umbilicus used to be, and the two remaining trocars (first 65 mm, then 80 mm, Covidien) were placed at its sides, sparing 5 mm thick tissue bridges. Ports were placed in the same nearly-transverse line making sure their location minimizes collision while manoeuvring tools. An optical 100 mm trocar was placed topmost in the midline. All patients were laid in an anti-Trendelenburg position with 20° table rotation to the left. Then, the fundus and neck of the gallbladder were suspended with two trans-tegumental straight-needle 60 cm Monosof 2-0 (Tyco) sutures. The first suture was placed in the right

midclavicular line in the 7th intercostal space. A second suture was applied in 8 patients and its location was dependent on anatomical conditions and size of the gallbladder. When the sutures were tightened and Calot's triangle exposed, the cystic duct and cystic artery were isolated from the structures of Calot's triangle with standard direct or reticular tools (Endodissect Roticulator and Endograsp Roticulator, Autosuture) when necessary. Each of the structures was closed with 3 clips (Endoclip III 5 mm, Autosuture) and cross-sectioned, leaving 2 clips on each stump. The gallbladder was removed typically from its neck towards the fundus with a monopolar electrocoagulation hook. Immediately before liberation of the gallbladder from the liver, haemostasis was controlled, and the infrahepatic area was rinsed, as usually there was a small bile leak from the suspension sutures. After the discharge was suctioned out, in two procedures only (2nd and 4th) drainage was introduced via the wound in the navel. No drainage was used later on. The gallbladder was removed through the umbilicus after cutting one or two (depending on the size of gallstones) of the previously spared tissue bridges. After reconstruction of the fascia, the umbilicus was repaired with one or two submerged Polysorb 3-0 sutures fixing it to the fascia. The skin was not stitched.

Patients were administered one scheme of analgesia: 100 mg pethidine IM immediately after surgery, then 4 ml metamizole IV as required.

Results

Mean operation time was 74.2 min (45-125 min). Our very first SILS cholecystectomy lasted 2 h and 5 min. Duration of subsequent procedures shortened quickly and after approximately the 10th operation stabilized at 50-70 min. In one case (2nd operation) conversion to classical laparoscopic cholecystectomy with 4 trocars (two 10 mm and two 5 mm placed in a standard manner) was necessary. Impossibility to maintain intraperitoneal pressure due to air leakage from trocar channels and incorrect – as it turned out later – diagnosis of arterial bleeding from Calot's triangle. An additional 5 mm port was once placed (21st procedure), yet it might have resulted from insufficient experience of the team which performed this surgery. The patient after the 24th of our procedures was operated on in another hospital for biliary peritonitis on day 6 after SILS chole-

cystectomy. The cause of peritonitis was bile leak from an unnoticed and not ligated Luschka duct.

No complications other than the aforementioned were seen. Twenty-three patients were given 100 mg IM pethidine immediately after surgery. In two patients the anaesthesiologist administered 100 mg ketoprophen IV after completion of the surgery. Later on, patients were administered analgesics on demand. Two patients did not need any painkillers, 16 patients required a single dose, 3 patients required 2 doses, and two patients 3 doses of 4 ml metamizole IV. Thirteen patients were discharged on the first day post-op, and 12 patients on the second day. All patients but the one who underwent laparotomy on day 7 were controlled in surgical outpatient clinics for wound healing. One patient had necrosis of the skin margin and necrectomy was necessary. Finally, the wound healed with satisfactory cosmetic effect. No umbilical wound infection was seen in the whole group.

Discussion

Our first 10 SILS procedures differed one from another as to surgical technique, as we were then testing for optimal technical solutions, eliminating difficulties resulting from lack of experience and imperfectness of the equipment and laparoscopic tools. After gaining experience in single umbilical access surgery we were able to develop the technique described above in a relatively short time.

During an offset of umbilical access procedures we feared wound infectious complications. This concern was raised by long-term experience with laparoscopic surgery, where complications of umbilical wound healing were not unusual. However, these concerns proved groundless. Standard skin preparation with Skinsept Color (Ecolab), turning out of the umbilicus and repeat washing of the incision line with the same preparation secures skin disinfection comparable to other regions of the body. Although all of the removed gallbladders were removed via an umbilical incision without any protective bag or antibiotic prophylaxis, no single case of wound infection was seen in the study group. An appropriate surgical incision is of extreme importance for wound healing. We believe a transverse incision from the apex to the base of the everted umbilicus is an optimal one (Figures 1, 2). Such an incision allows for easy trocar placement

with maintenance of necessary tissue bridges securing upkeep of the pneumoperitoneum (Figure 3). Too small incision causes crossing of the lateral trocars and trying to accomplish the procedure in such circumstances inevitably results in crushing of the wound edges and marginal skin necrosis, which was seen in one of our patients. To restore the shape of the navel and avoid a visible scar, which is one of the main goals of SILS, shortening of free skin flaps before umbilicus reconstruction is usually necessary (Figure 4).

Adequate suture placement for suspending the fundus of gallbladder to the abdominal wall is crucial for efficient surgery. Trans-tegumental needle placement immediately below the right costal arch is not sufficient. To appropriately retract the fundus of gallbladder and show Calot's triangle, this suture ought to be placed in the 7th intercostal space in the right midclavicular line or, when required by the

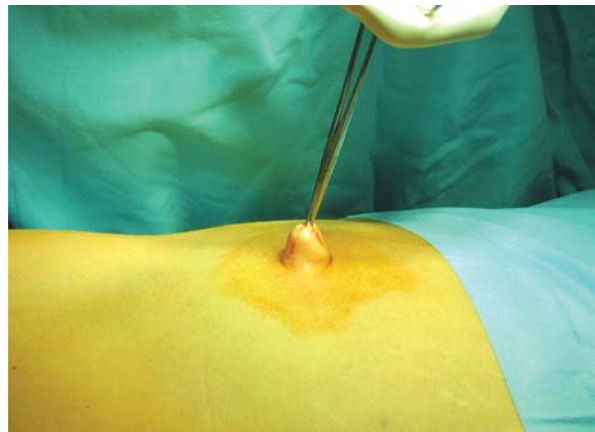


Figure 1. Eversion of the navel

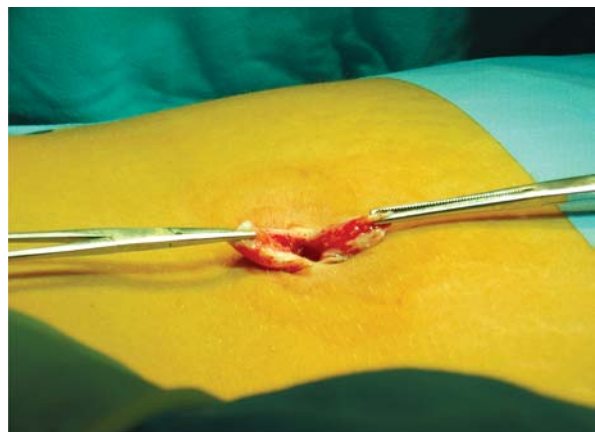

Figure 2. Incision within the umbilicus

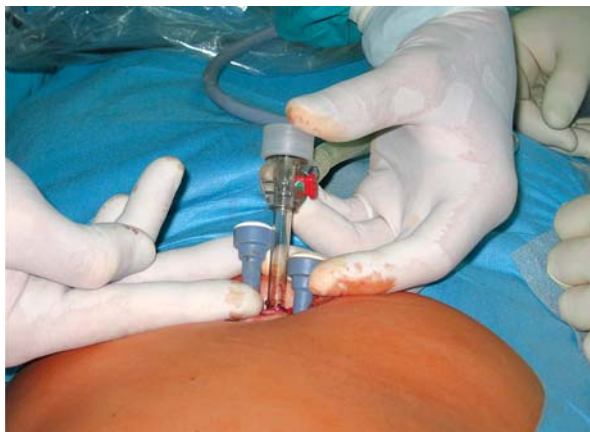

Figure 3. Positioning of the trocars in the incision

anatomical situation, laterally from this line. With such position of this suture and favourable local conditions, another suture retracting the neck of the gallbladder is not always necessary.

In our first SILS procedures we used reticular tools, yet with growing experience and the high cost of these tools we deemed them expendable. Straight, readily available laparoscopic instruments allow safe and efficient execution of surgery without unnecessarily prolonging its duration. In our experience effectiveness and safety of SILS procedures were not determined by the type of instruments but by the adroitness, perfect cooperation and understanding of the surgical team. Mean duration of the procedure in the presented group is significantly longer than classical laparoscopic cholecystectomy, yet in our study it mostly resulted from inclusion of new technique learning curve cases and involvement of all surgeons employed in the department in execution of these procedures.

Initially we assumed that only patients with ultrasound documented gallstones with BMI below 30 kg/m² qualified for planned surgery would be included in the study. However, with increasing experience we decided that dogmatically sticking to these rules might not be necessary. In four patients BMI exceeded 30 and it was not a significant obstacle to accomplishing the procedure. Likewise, 2 patients with gallbladder hydrops were operated on. After the gallbladder content was aspirated transdermally with a 150 mm long puncture needle inserted in the right hypochondriac area, the rest of the procedure was uneventful. Aspiration did not

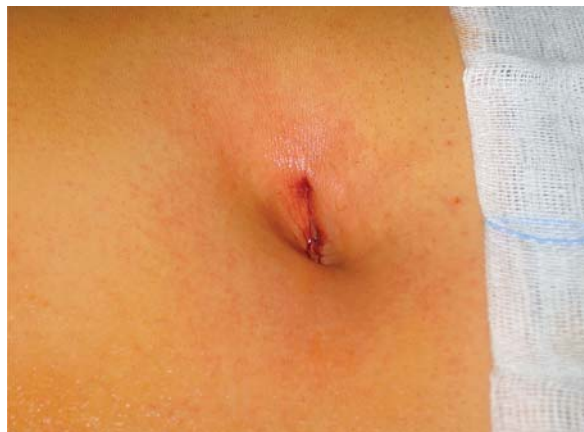

Figure 4. The umbilicus immediately after reconstruction

affect surgery duration. Aspiration with a typical laparoscopic puncture needle was attempted, yet it proved inconvenient due to the needle direction enforced by trocar location, preventing complete gallbladder emptying and resulting in uncontrolled spillage into the peritoneal cavity.

Our observations that less painkillers are needed after SILS cholecystectomy and hospital stay is shortened are primary. The too small number of patients does not allow for analysis of this variable. In our experience SILS cholecystectomy is a procedure which can be safely done with available laparoscopic appliances. The primary advantage of this method is a very good cosmetic effect, as there is actually no visible scar after surgery. Assessment of potential benefits such as shorter hospital stay, lesser need for postoperative analgesia or shortening of full recovery time need to be confirmed in larger cohorts.

References

1. Tacchino R, Greco F, Matera D. Single-incision laparoscopic cholecystectomy: surgery without a visible scar. *Surg Endosc* 2008; 23: 896-9.
2. Michalik M, Frask A, Orłowski M. NOTES (Natural Orifice Transluminal Endoscopic Surgery) – operacje przez naturalne otwory ciała. *Videosurgery and other miniinvasive techniques* 2007; 2: 98-102.
3. Navarra G, La Malfa G, Bartolotta G, et al. The invisible cholecystectomy: a different way. *Surg Endosc* 2008; 22: 2103.
4. Cuesta MA, Berends F, Veenhof AF. The invisible cholecystectomy: a transumbilical laparoscopic operation without a scar. *Surg Endosc* 2008; 22: 1211-3.
5. Rao PP, Bhagwat SM, Rane A, Rao PP. The feasibility of single port laparoscopic cholecystectomy: a pilot study of 20 cases. *HPB* 2008; 10: 336-40.