

Argon plasma coagulation (APC) for treatment of Barrett's oesophagus

Marcin Migaczewski, Andrzej Budzyński, Kazimierz Rembiasz

2nd Department of General Surgery, *Collegium Medicum* of the Jagiellonian University, Cracow

Videosurgery and other miniinvasive techniques 2009; 4 (3): 102-109

Abstract

Introduction: Barrett's oesophagus (BE) is a columnar metaplasia caused by chronic gastroesophageal reflux associated with increased risk of developing adenocarcinoma. There are three main goals of treatment for BE – to provide control of reflux syndrome, eradication of metaplastic tissue, and to provide a new antireflux barrier for long-term pH stabilization. Ablative therapy with argon plasma coagulation in BE patients leads to removal of metaplastic and dysplastic cells.

Aim: To determine in a prospective study the efficacy of endoscopic argon plasma coagulation (APC) in combination with proton pump inhibitors (PPIs) for ablation of Barrett's oesophagus with or without low grade dysplasia.

Material and methods: Between January 2005 and December 2008, thirty patients (19 men, 11 women; mean age 54.9 years) with histologically proven BE were treated with APC in combination with 80 mg/day pantoprazole. All patients underwent endoscopy at 12 months.

Results: After 12 months, 22 of 30 patients (73.3%) had complete regression of Barrett's oesophagus. Regeneration of squamous epithelium was observed after a median of 1.78 sessions (range: 1 to 4). The number of sessions depends on the extent and histological type of metaplasia.

Conclusions: Argon plasma coagulation offers a safe, minimally invasive method, which gave complete regression of metaplasia and low grade dysplasia usually in more than 70% of patients with Barrett's oesophagus. Our results show that combination of APC and PPIs is an effective treatment option for most patients with BE.

Key words: Barrett's oesophagus, argon plasma coagulation, gastroesophageal reflux disease.

Introduction

Barrett's oesophagus (BE) is a condition in which the mucosa, due to chronic irritation with gastric or gastro-duodenal content, undergoes adaptive rearrangement with columnar cells' proliferation pushing the Z line away from the upper margin of the gastric folds. Barrett's oesophagus is considered to be a precancerous state, due to increased risk of adenocarcinoma in these patients. Risk of dysplasia in patients with BE varies from 2 to 25%, according to different sources. Adenocarcinoma of the oesophagus develops in 0.5-1% of cases.

The opinion that glandular metaplasia of the gastroesophageal junction and risk of adenocarcinoma of the oesophagus are closely correlated is commonly accepted, yet mechanisms of this relation have not been completely understood. Establishing connections of these phenomena is essential to define groups of patients at risk of oesophageal adenocarcinoma.

Treatment of BE patients involves both methods typically applied in non-complicated GERD and BE-specific techniques [1, 2]. The ultimate goal of treatment of BE patients is to control symptoms of reflux disease, remove tissues at risk of adeno-

Address for correspondence:

Marcin Migaczewski, MD, 2nd Department of General Surgery of *Collegium Medicum* of Jagiellonian University, 21 Kopernika St, 31-234 Cracow, phone +48 12 424 82 01, +48 502 714 639, fax +48 12 421 34 56, e-mail: marcinmigaczewski@onet.pl

carcinoma development, and finally, effective prevention of reflux content from contacting mucosa of the distal oesophagus. Hence, pharmacological therapy ought to be supplemented with endoscopic methods. An aim of endoscopic ablation is to destroy both Barrett's epithelium and any dysplasia present, allowing for squamous re-epithelialization. The most popular methods include: argon plasma coagulation (APC), laser thermoablation, photo-dynamic therapy (PDT), and multipolar electro-coagulation (MPEC).

Aim

The goal of this study was to establish a diagnostic and therapeutic APC-based algorithm for patients with BE without high-grade dysplasia and to assess the efficacy of metaplastic lower oesophagus mucosa destruction with argon plasma ablation.

Material and methods

Thirty patients with histologically confirmed Barrett's oesophagus, treated in the 2nd Department of General Surgery of the Jagiellonian University Collegium Medicum between January 2005 and December 2008 were included in the study. Follow-up time of each and every patient was 12 months from complete removal of columnar metaplasia. The group included 19 men and 11 women. Average age was 54.9 years, respectively in women 55.3 and in men 54.6 years. Mean length of circumferential extent (C extent) was 1.2 cm and maximal 3 cm. Maximum reach of Barrett's epithelium (M extent) was 5 cm and mean 3.06 cm. In the majority of patients,

metaplastic epithelium could be found in more than one quadrant of the oesophagus (Figure 1). Two (12 patients, 40%) or just one (10 – 33.3% of patients) quadrant involvement prevailed.

Foci of glandular metaplasia were found most often within the 2nd quadrant of the oesophagus (21 patients). Barrett's oesophagus was found in the 1st quadrant in 17 patients and in 15 patients in quadrant 3. Involvement of the 4th quadrant was the least common (Figure 2).

Three types of columnar metaplasia were found in the analyzed group (Figure 3). Patients with complete intestinal metaplasia without dysplasia (21-70% of patients) prevailed, with incomplete intestinal metaplasia without dysplasia seen in 4 patients (13%) and complete dysplasia in 5 (17%).

Low-grade dysplasia was present in 3 and moderate in 2 of 30 patients from the analyzed group. In 17% *Helicobacter pylori* infection was seen and treated with the standard eradication scheme.

Every patient qualified for this research programme had baseline gastroscopy performed for macroscopic assessment of lesions in mucosa of the distal oesophagus, sampling biopsy specimens for histology and rapid urease test for *H. pylori*. Proximal shift of Z line was diagnostic of endoscopically suspected oesophageal metaplasia (ESEM), and hence raised suspicion of columnar metaplasia of the oesophagus. Biopsies were taken from 4 quadrants of the oesophagus at 1 cm intervals due to the patchy nature of BE disease and the need for accurate localization of the metaplasia foci before ablative treatment. On the

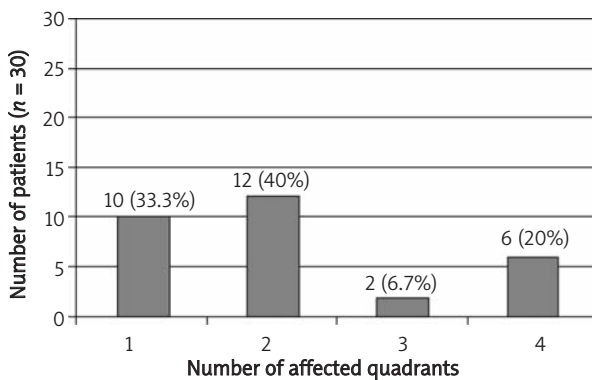


Figure 1. Number of quadrants of the oesophagus affected with columnar metaplasia prior to treatment

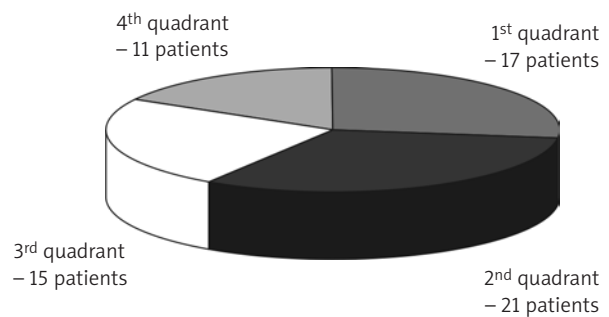


Figure 2. Involvement of individual quadrants of the lower oesophagus with columnar metaplasia prior to treatment

same occasion, the extent of metaplasia was assessed according to the widely accepted Prague criteria, i.e. C and M. In this system measurement is done with accuracy of 1 cm of circumferential extent (C) and maximum extent (M) of metaplastic inserts within mucosa. Results are shown as C_xM_y, where x and y are respective measurement true values [3].

Basic inclusion criteria were: presence of glandular cells in the distal oesophagus in baseline histology and informed consent of the patient. After metaplasia had been confirmed, patients underwent argon plasma ablation in affected quadrants. The procedure was accomplished with ERBOTOM ICC 350 electrosurgical diathermy with argon APC 300 add-on and flexible coagulation probe with front lumen. Power was adjusted at 60 W with argon flow of 1.8 l/min. Most of the patients were hospitalized until the following day. During one session, no more than 2 quadrants were treated with argon plasma ablation. When metaplasia extended into 3 or 4 quadrants, the procedure was repeated after 4-6 weeks. The first endoscopic control with biopsy was performed 6 weeks following the final ablation procedure. During the whole treatment period patients were administered 40 mg pantoprazole bid. When cylindrical epithelium was still present in the oesophageal mucosa during control endoscopy, the whole procedure was repeated until the desired effect was attained. The next control endoscopy was done 12 months after completion of ablative treatment.

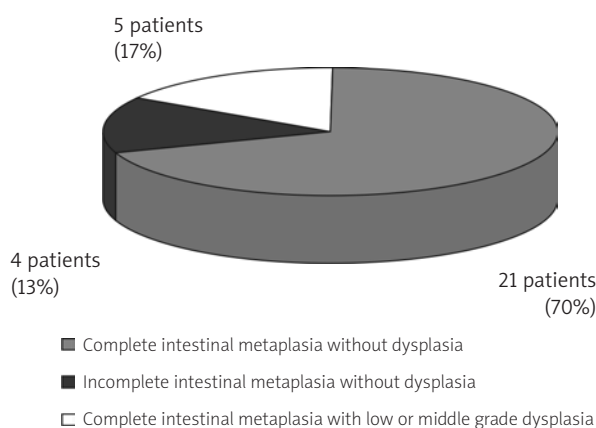


Figure 3. Histological types of columnar metaplasia

Results

No complications of the applied treatment were seen in any of the patients. Combination of PPI and endoscopic argon beam ablation was well tolerated. During the whole study period no side-effects of the treatment were seen. There was no need to stop the therapy in any of the treated patients.

Effectiveness of endoscopic ablation procedures was dependant on the extent of mucosal lesions and the initial type of columnar metaplasia. Mean number of argon ablation sessions needed to obtain re-epithelialization with squamous cells was proportional to the circumferential extent of metaplasia – C feature of Prague classification (Figure 4). In patients with BE manifested by only an inset of metaplastic epithelium (C0 in Prague classification) mean number of coagulation sessions per patient was 1.22. When height of the circumferential segment was 3 cm, it was necessary to perform 2.25 ablation procedures to end up with re-epithelialization with squamous cells (Figure 4).

A similar relation was found with maximum extent (measured in cm) of Barrett’s epithelium (M feature of the Prague criteria) and the number of necessary argon ablations (Figure 5). Patients with the smallest, i.e. 2 cm, extent of metaplasia needed on average 1.33 coagulation sessions to attain planocellular re-epithelialization. In patients with the maximal extent seen in the group (5 cm), the number of APCs needed increased more than twofold (Figure 5).

Significant reduction of columnar metaplasia in the distal oesophagus was seen in every patient

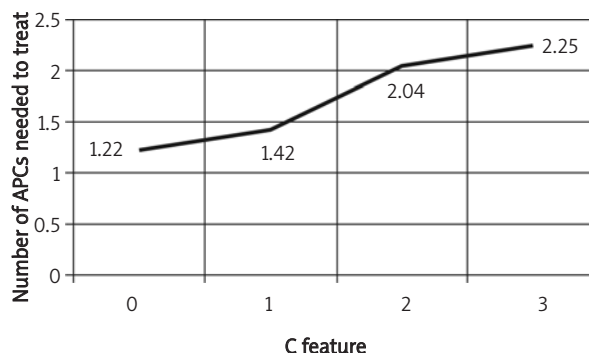


Figure 4. Mean number of ablation sessions with argon plasma needed to obtain squamous cell re-epithelialization in correlation to circumferential extent (cm) of metaplasia (C trait of the Prague criteria)

after argon plasma during 12-month follow-up. Highest efficacy of ablation was achieved for quadrants 3 and 2, yet the difference was not significant (Figure 6).

Average efficacy of argon plasma coagulation in combination with 80 mg pantoprazole, regardless of the extent of pathological lesions, allowed complete squamous re-epithelialization to be obtained and maintained in more than 78% of patients (Table I).

A difference in argon plasma coagulation efficacy in various types of metaplasia was found in the analyzed group of patients. Only patients with incomplete intestinal metaplasia could enjoy complete, i.e. 100%, efficacy of APC (Figure 7). Mean effectiveness of this therapeutic method in all types of metaplasia was 73.3% (Table II).

Based on these results, the following conclusions were formulated:

- argon plasma ablation results in efficient removal of metaplastic epithelium in patients with Barrett's oesophagus,
- combination of ablation therapy and anti-secretory pharmacotherapy with above-standard dosage of PPIs allows planocellular reepithelialization to be established in almost 80% of patients – the technique of argon plasma ablation at normalized pH in the lower oesophagus is a safe and highly efficient method,
- effectiveness of ablation depends on the extent and histological grade of columnar metaplasia,
- perfection of endoscopic ablation techniques in the future can reduce the risk of adenocarcinoma of the oesophagus from Barrett's oesophagus.

Discussion

Mucosal lesions now classified as Barrett's oesophagus were described as early as the beginning of the 19th century. In the first place, peptic ulcers of the oesophagus drew attention. The oesophagus was lined with mucosa morphologically not different from gastric mucosa. In 1950 Norman Barrett described this condition in "Chronic peptic ulcer of the oesophagus and oesophagitis", which he believed was a complication of inflammation of the gastric mucosa shifted into the thorax. The disease was thought to result from congenital shortening of the oesophagus. In 1953 Allison and Johnston in their studies confirmed that, unlike the stomach, the affected part of the GI tract is not covered with peritoneum and its

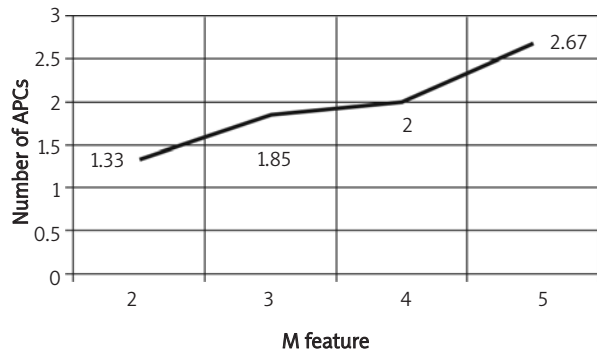


Figure 5. Mean number of argon plasma ablation sessions necessary for planocellular re-epithelialization in regard to maximum length (in cm) of metaplasia (M feature of the Prague criteria)

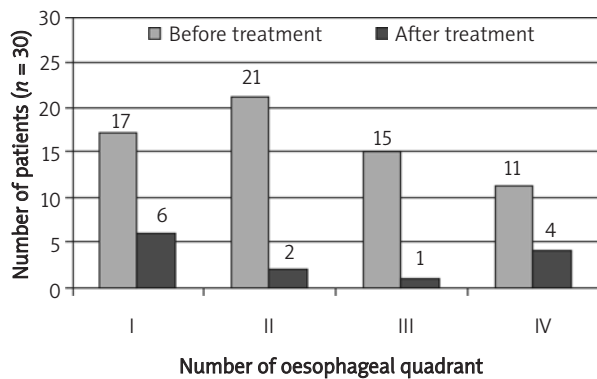
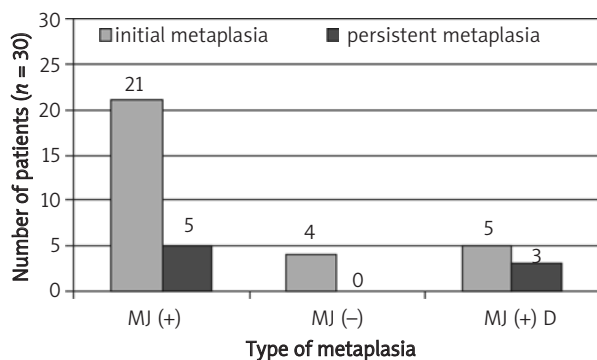


Figure 6. Efficacy of argon plasma coagulation (APC) in each quadrant of the oesophagus



MJ (+) – complete intestinal metaplasia without dysplasia
 MJ (-) – incomplete intestinal metaplasia without dysplasia
 MJ (+) D – complete intestinal metaplasia with low- or middle-grade dysplasia

Figure 7. Efficacy of argon plasma ablation in different types of columnar metaplasia

Table I. Efficacy of argon plasma ablation according to the extent of metaplasia

Affected quadrant of the oesophagus	Prior to treatment	After treatment and follow-up	Efficacy [%]
1	17	6	64.7
2	21	2	90.5
3	15	1	93.3
4	11	4	63.6
Mean 78.1%			

Table II. Efficacy of argon plasma ablation in different types of columnar metaplasia

Histological type	Initial number of patients	Number of patients with residual metaplasia	APC efficacy [%]
Complete intestinal metaplasia MJ (+)	21	5	76.2
Incomplete intestinal metaplasia MJ (-)	4	0	100
Complete intestinal metaplasia with dysplasia MJ (+) D	5	3	40
			average 73.3

wall has a structure typical for the oesophagus. Hence, Barrett’s earlier theory proved false.

The true turning point in the concept of reflux disease and Barrett’s oesophagus were theses published at the end of 2006 as the so-called Montreal consensus. In this collection of experts’ opinions, contemporary knowledge on Barrett’s oesophagus was summarized in 9 points [4]. The quoted consensus once more underlined strict correlation of columnar metaplasia with oesophageal adenocarcinoma development. Presence of a pre-cancerous condition (which Barrett’s oesophagus really is) determines the need for treatment in this group of patients. No universal therapeutic algorithm has been developed so far. What is more, the contradictory notions on the effectiveness of various techniques often met in the literature make figuring out such an algorithm even less likely. Most authors emphasize the efficacy of endoscopic ablative procedures in supplementation of anti-secretory pharmacotherapy in patients with BE.

APC technique has been broadly applied in endoscopic treatment of many GI tract pathologies. Classical application of this method is to control haemorrhage, especially from non-resectable malignant tumours. Argon plasma coagulation is also used for destruction of pathological tissue,

both in curative and palliative treatment. In patients with Barrett’s oesophagus APC technique is used to ablate foci of metaplasia with controlled coagulation. A monopolar no-touch electrode spreads high frequency electric current in an argon sheath. The result of the procedure is coagulation of tissue at a depth limited to 1-3 mm. Depth of penetration depends on the generated power (range: 0-155 W), argon flow (range: 0.5-7 l/min), distance from electrode to tissue (range: 2-8 mm) and application time (0.5-2 s or continuous ablation). In ablation of Barrett’s metaplasia power of 30-90 W is used with argon flow of 1-2 l/min [5]. The procedure is usually conducted under intravenous sedation with benzodiazepines.

APC technique remains the best studied and a commonly accepted method of endoscopic ablation of metaplasia in oesophageal mucosa in patients without dysplasia [5]. The popularity of this method stems from its ease of application. The low cost of APC must also be considered. In the department where the study was conducted the device was used for other therapeutic purposes than treatment of BE patients. Ablation of metaplasia in BE with argon plasma is a safe procedure with efficacy approaching 90% and is not inferior to photodynamic technique [6]. Complications after this method are rare and not

life-threatening in the majority of cases. Typical complications include chest pain and odynophagia. Stricture, haemorrhage and perforation of the oesophagus that can lead to mediastinitis and, eventually, to the patient's death are severe complications [7, 8]. Only two deaths directly attributable to iatrogenic oesophagus injury during argon plasma ablation have been described in the literature. Notions of microperforation with pleural effusion and fever are more frequent [9].

In our group of 30 patients procedures were conducted with an argon beam coagulator. Squamous re-epithelialization was preserved for 12 months in 22 patients (73.3%). Our results are similar to data found in the literature, where a similar effect was observed in 68-100% of argon plasma ablation cases [10]. As in Morris and Madisch's studies including respectively 173 and 280 patients in our study no dysplasia or adenocarcinoma developed during 12-month follow-up [7].

The described ablative technique, although very efficient, does not permanently prevent recurrence of Barrett's metaplasia, when the oesophagus is constantly exposed to reflux content. Anti-secretory therapy with PPIs causes temporary pH normalization when acidic reflux dominates. In non-acidic reflux the effectiveness of such treatment obviously falls. Another negative feature of long-term PPI therapy is the fact that in patients with *Helicobacter pylori* infection it can cause spreading of infection to the stomach body, causing atrophic gastritis [11]. A way to achieve lasting pH normalization is permanent treatment with anti-secretory pharmacotherapy or surgical correction of the anti-reflux mechanism. In Basu's studies a higher percentage of metaplasia recurrence was seen in patients on reduced PPIs dose, which indicates the need for above-standard dosage [10].

Rules of qualification of patients with BE without high grade dysplasia for treatment remain controversial. In the analyzed group of patients the maximum extent of metaplasia was 5 cm with mean of 3.06 cm. In Dulai's study 24 patients with BE and mean length of metaplasia of 4 cm and neither high grade dysplasia nor cancer were subjected to argon ablation supplemented with 80 mg/day pantoprazole [12]. In 35% of these patients residual Barrett's metaplasia could be found, which is not much different from our result. The quoted analysis indicates higher therapeutic

value of APC technique when compared to the other popular method of ablation, multipolar electrocoagulation (MPEC). The simplicity of the former method is another argument to use it. According to the literature, more than one ablation session is usually necessary to completely remove columnar metaplasia and achieve squamous re-epithelialization of the oesophagus [9, 13]. For successful ablation of metaplastic mucosa of the gastroesophageal junction, and hence squamous re-epithelialization, two to five ablation sessions are usually needed. According to some authors, a single procedure with the argon beam coagulator results in complete removal of pathological tissue in 55-100% of cases. In our study, 1.78 ablation procedures were done per patient. The number of sessions depended on the extent of metaplasia. Patients with 2 cm extent of Barrett's epithelium (M feature in the Prague criteria) on average required 1.33 procedures, while those with the greatest (5 cm) extent needed twice as many APC sessions. Circular extent (C feature) of metaplasia proved no less important. In patients with lesions affecting a single column (C = 0) the average number of APC sessions was 1.22. In patients with the largest, 3-cm circular extent a mean of 2.25 ablations of metaplastic mucosa were conducted. Another factor affecting the number of necessary ablation sessions was histological type of columnar metaplasia. In the most numerous group of patients with complete columnar metaplasia without dysplasia, the average number of procedures needed was 1.72, which is comparable to data from other authors [9, 14]. In patients with incomplete intestinal metaplasia this number was 1.5 sessions. In patients with complete intestinal metaplasia with low or middle grade dysplasia, the number of required sessions increased to 2. These results show an influence of the initial grade of histological changes within the BE mucosa on the course of ablative treatment.

The possibility of overlooking foci of metaplasia in deeper layers of the oesophageal wall is another disadvantage of the method described in the literature. Yet destruction of the main mass of pathological tissue is believed to bring about a wipeout to the bulk of aberrant DNA, which significantly reduces the risk of malignancy [15]. In spite of the notions of development of oesophageal adenocarcinoma in patients with BE after APC treatment, large cohort studies clearly show that the

described thermoablation method has more advantages than drawbacks [16].

The efficacy of argon thermoablation is believed to increase proportionally to the power of coagulation [9]. Such modification combined with high dose PPI increases both the effectiveness of the method and the risk of severe complications, especially perforation of the oesophagus wall. We used fixed 60 W power of argon ablation and did not observe any complications during 12-month follow-up. Schultz applied 90 W argon ablation with 120 mg of omeprazole a day. After mean follow-up of 12 months no Barrett's metaplasia was detected in 69 of 70 patients (98.6%) [13]. An average of 2 APC sessions were done (range: 1-5). In this study, stricture of the oesophagus was found in 3 patients and was successfully treated with a single endoscopic balloon dilatation procedure. According to numerous authors, application of high-power ablation brings about similarly satisfactory long-term results, and the latest publications prove the reduced risk of the method, which is attributable to increasing experience of the centre [17]. Thus, application of high-power ablation in selected, refractory cases of Barrett's metaplasia seems reasonable, yet one must not forget the growing risk of complications.

In some patients after argon plasma ablation cylindrical cells are found during control biopsy. In our study it occurred in 8 patients. No dysplasia or cancer was seen. There were unique cases of oesophageal adenocarcinoma described to rise from Barrett's metaplasia located beneath the layer of post-ablation squamous re-epithelialization [4, 16]. Presence of residual metaplasia can be explained by two theories. The first one indicates too shallow penetration of ablation energy into the oesophageal wall. According to the other, patchy metaplasia contributes to incorrect assessment of extent and identification of Barrett's epithelium foci, which leads to exclusion of this area from being biopsied. Limited reliability of macroscopic diagnosis of metaplasia of the gastro-oesophageal junction in classic endoscopy is of clinical importance.

Barrett's oesophagus is a late complication of reflux disease. Pharmacological treatment temporarily improves pH of the gastro-oesophageal junction without regulating efficiency of the physiological anti-reflux barrier. In patients subjected to ablation of metaplastic mucosa, it is necessary to tailor the influence of regurgitated gastric content on

the oesophagus in the long run to maintain the therapeutic effect of squamous re-epithelialization.

References

1. Wróblewski T, Skalski M, Ziarkiewicz-Wróblewska B, et al. Postępy w leczeniu chirurgicznym choroby refluksowej. *Videosurgery and other miniinvasive techniques* 2006; 1: 121-4.
2. Wróblewski T, Grodzicki M, Ziarkiewicz-Wróblewska B, et al. Aspekty techniczne i wyniki laparoskopowej fundoplikacji sposobem Toupet w leczeniu zaawansowanej postaci refluksu żołądkowo-przełykowego (GERD). *Videosurgery and other miniinvasive techniques* 2006; 1: 6-9.
3. Sharma P, Dent J, Armstrong D, et al. The development and validation of an endoscopic grading system for Barrett's esophagus: the Prague C & M criteria. *Gastroenterology* 2006; 131: 1392-9.
4. Vakil N, van Zanten SV, Kahrilas P, et al.; Global Consensus Group. The Montreal definition and classification of gastro-oesophageal reflux disease: a global evidence-based consensus. *Am J Gastroenterol* 2006; 101: 1900-20.
5. Ginsberg GG, Barkun AN, Bosco JJ, et al. The argon plasma coagulator: 2002. *Gastrointest Endosc* 2002; 55: 807-10.
6. Morino M, Rebecchi F, Giaccone C, et al. Endoscopic ablation of Barrett's esophagus using argon plasma coagulation (APC) following surgical laparoscopic fundoplication. *Surg Endosc* 2003; 17: 539-42.
7. Morris CD, Byrne JP, Armstrong GR, Attwood SE. Prevention of the neoplastic progression of Barrett's oesophagus by endoscopic argon beam plasma ablation. *Br J Surg* 2001; 88: 1357-62.
8. Sampliner RE, Faigel D, Fennerty MB, et al. Effective and safe endoscopic reversal of nondysplastic Barrett's esophagus with thermal electrocoagulation combined with high-dose acid inhibition: a multicenter study. *Gastrointest Endosc* 2001; 53: 554-8.
9. Pereira-Lima JC, Busnello JV, Saul C, et al. High power setting argon plasma coagulation for the eradication of Barrett's esophagus. *Am J Gastroenterol* 2001; 96: 1662-3.
10. Basu KK, Pick B, Bale R, et al. Efficacy and one year follow up of argon plasma coagulation therapy for ablation of Barrett's oesophagus: factors determining persistence and recurrence of Barrett's epithelium. *Gut* 2002; 51: 776-80.
11. Rembiasz K. Zanikowe zapalenie błony śluzowej żołądka. Model diagnostyczny i możliwości leczenia. Rozprawa habilitacyjna. Uniwersytet Jagielloński Collegium Medicum, Kraków 2003.
12. Dulai GS, Jensen DM, Cortina G, et al. Randomized trial of argon plasma coagulation vs. multipolar electrocoagulation for ablation of Barrett's esophagus. *Gastrointest Endosc* 2005; 61: 232-40.
13. Schulz H, Miehle S, Antos D, et al. Ablation of Barrett's epithelium by endoscopic argon plasma coagulation in combination with high-dose omeprazole. *Gastrointest Endosc* 2000; 51: 659-63.
14. Grade AJ, Shah IA, Medlin SM, Ramirez FC. The efficacy and safety of argon plasma coagulation therapy in Barrett's esophagus. *Gastrointest Endosc* 1999; 50: 18-22.

15. Ackroyd R, Kelty CJ, Brown NJ, et al. Eradication of dysplastic Barrett's oesophagus using photodynamic therapy: long-term follow-up. *Endoscopy* 2003; 35: 496-501.
16. Shand A, Dallal H, Palmer K, et al. Adenocarcinoma arising in columnar lined oesophagus following treatment with argon plasma coagulation. *Gut* 2001; 48: 580-1.
17. Pedrazzani C, Catalano F, Festini M, et al. Endoscopic ablation of Barrett's esophagus using high power setting argon plasma coagulation: a prospective study. *World J Gastroenterol* 2005; 11: 1872-5.