

# Laparoscopic distal pancreatectomy in children with solid pseudopapillary tumour (Frantz tumour) – a report of two cases and review of the literature

Wojciech Korlacki, Józef Dzielicki, Andrzej Grabowski

Department of Paediatric Surgery, Medical University of Silesia, Zabrze, Poland

Videosurgery and other miniinvasive techniques 2010; 5 (2): 65-69

DOI: 10.5114/wiitm.2010.14206

## Abstract

*Solid pseudopapillary tumour (Frantz tumour) is a rare primary neoplasm of the pancreas. We report our experience with LDP in two cases of children with Frantz tumour. Two patient cases were reviewed. In both laparoscopy was carried out. There were no intraoperative complications or conversions in both cases. In both children the postoperative course was uneventful. Ultrasound and computed tomography after surgery showed the healed pancreatic stump without fluid collection or abscess either around the stump or in the abdominal cavity. In both cases solid pseudopapillary neoplasm (Frantz tumour) was established on histopathological examination. Metastases, local recurrences, and endocrine and abdominal symptoms were not observed at the follow-up evaluation respectively 7 months and 1 year after surgery. In both cases laparoscopic resection was feasible and curative though the procedure itself was a hard task. The method could be favourable in experienced hands.*

**Key words:** tumours of the pancreas, laparoscopy, solid pseudopapillary tumour.

## Introduction

Solid pseudopapillary tumour, first described by Frantz in 1959, is a rare primary neoplasm of the pancreas with a low malignant potential which tends to occur primarily in young women [1, 2]. In most cases complete tumour resection preserving as much pancreatic tissue as possible is the treatment of choice [2, 3]. Laparoscopic distal pancreatectomy (LDP) is recently recommended in adult patients with benign tumour of the pancreas body and tail [4, 5]. We report our experience with two cases of LDP in children with Frantz tumour.

tion there was a palpable mass in her mid abdomen and no other symptoms. Abdominal ultrasound revealed a heterogenic structure 7 cm in diameter lying in the tail and partly in the body of the pancreas, and splenomegaly. The tumour spread from the hilum of the spleen to the prerenal fascia and displaced the ventricle. It was firmly connected with the splenic vein, but no infiltration of the adjacent organs was visible. A computed tomography (CT) scan disclosed an oval, well defined mass of mixed density and supported the connection with the splenic vein. The spleen was enlarged but homogeneous. There was no evidence of a tumour before the surgery.

## Case reports

### Case 1

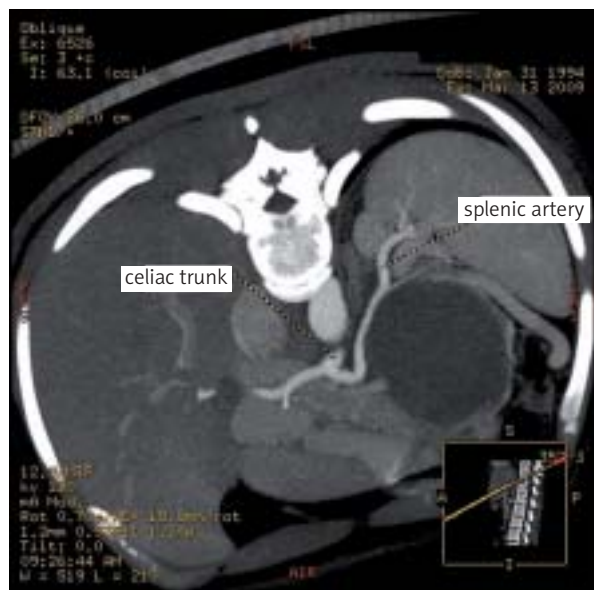
A previously healthy 15-year-old girl was examined because of mild abdominal pain. On examina-

### Case 2

A 15-year-old girl was admitted to the emergency ward due to acute abdominal pain. Examination revealed a painful mid abdomen but without tender-

#### Address for correspondence:

Wojciech Korlacki, MD, PhD, 9d/7 Nowy Świat Str., 41-800 Zabrze, Poland, phone +48 32 335 58 24, fax +48 32 271 47 18, e-mail: woko@plusnet.pl



**Figure 1.** Case 2 – computed tomographic scan of the lesion

ness, and with no palpable mass. Serum amylase was slightly elevated, urine amylase three times higher than reference values. Abdominal ultrasound (US) examination revealed a sharply delimited, mixed echogenic round tumour of the tail of the pancreas, 5.5 cm in diameter, adjacent vessels displaced, no vessels visible in Power Doppler option inside the tumour. The rest of the pancreatic parenchyma was in US examination without pathological findings. Computed tomography scan findings: in the tail of the pancreas a tumour of the density of the organ, surrounded with normal pancreatic parenchyma, 63 × 68 × 74 mm (Figure 1). It constricted the splenic vein with small flow through it and presence of collateral circulation through internal epigastric veins following to the IMV. The spleen was homogeneous, measuring 95 × 50 mm. The radiologist suggested a solid pseudopapillary tumour as the diagnosis.

### Operative technique

Prior to surgery patients were immunized against *Streptococcus pneumoniae* and *Neisseria meningitidis*. The procedure was carried out under general anaesthesia, in supine and reverse Trendelenburg position with the operator on the right side of the patient and the assistant on the left side. Five trocars were used (2-10 mm, 3-5 mm) one of them as a static liver retractor. All dissection was performed with

a harmonic scalpel (SonoSurg, Olympus) or with a Liga-Sure device (Covidien). The procedure started with division of the gastro-colic ligament to expose the lesser sac. The stomach was lifted. In both cases the tumour was clearly visible in the gland due to its size but completely surrounded with the pancreatic parenchyma. The tissue at the inferior border of the pancreas was opened and a retropancreatic tunnel was developed, which made visible the posterior wall of the gland. Simultaneously the gland was separated from tissues on its anterior side. During the preparation in both cases no splenic vein was visible, and the splenic artery was identified at the upper margin but in firm connection with the mass. In the first case the tumour spread into the splenic hilum, in the second there were enlarged vessels of collateral circulation. Both such circumstances made splenectomy inevitable. Dissection of the pancreas was made through its normal body parenchyma with a linear stapler without preparation of the splenic vessels (Figure 2). The main part of the pancreas body was transected with an Endo-GIA tissue stapler (3.5 mm), the upper border with splenic vessels with an Endo-GIA vascular stapler (2.5 mm). After the dissection the splenic artery stump was ensured with the Endo-loop in both cases. Then splenectomy was performed in the ordinary manner, starting with short gastric vessels dissection. In the first case the pancreatic specimen and spleen were inserted into an endo-bag and extracted through the original umbilical trocar incision, which was only slightly enlarged. The spleen was morcellated manually in the extraction bag. In the second case due to the incompressible mass of specimen and preoperative suspicion of (low) malignancy we were forced to make an additional incision in the epigastrium for specimen retrieval. The silastic drain was placed in both cases in the space near the margin of the distal pancreas through one port site (Figure 2).

There were no intraoperative complications or conversions in both cases. Operative time was 180 min in the first and 190 in the second case. In both children the postoperative course was uneventful. Serum amylase level was normal on the second day after the surgery, urine amylase slightly elevated in the second patient. The drain collection was respectively 50 and 95 ml. The drains were drawn out on postoperative days 3 and 5. Oral alimentation was introduced on days 2 and 4. Intravenous analgesia was continued until the second day. The first girl was discharged on day 4, the second on day 6 after the

surgery. Ultrasound examination done in the fourth postoperative week and CT taken 3 months after surgery showed the healed pancreatic stump without fluid collection or abscess either around the stump or in the abdominal cavity. Both girls were well at the follow-up evaluation respectively 7 months and 1 year after surgery. Metastases, local recurrences, and endocrine and abdominal symptoms were not observed.

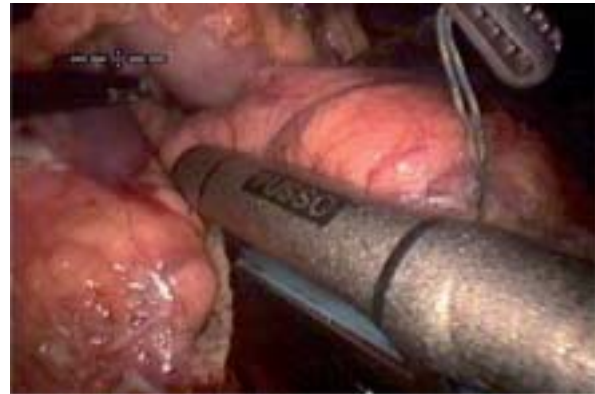In the first case 7 cm in diameter and in the second case 5 cm in diameter tumour of the pancreas tail with necrosis and haemorrhagic focuses inside was recognized. In both cases solid pseudopapillary neoplasm (Frantz tumour) was established on histopathological examination.

## Discussion

Solid tumours of the pancreas are extremely rare in children. One of them is solid pseudopapillary tumour (Frantz tumour). It is usually large and encapsulated and has a slow evolution. Although it has low malignant potential, it can invade locally or metastasize. While the tumour can occur in any part of the gland, it is slightly more frequent in the body and tail.

The recommended treatment for Frantz tumour seems to be settled: distal pancreatectomy (DP) or pancreatoduodenectomy depending on the location of the tumour. Open DP, involving resection of the pancreas to the left of the superior mesenteric vessels, is performed for a range of benign and malignant lesions, trauma and inflammation [6]. In recent years, DP has been increasingly performed by a minimally invasive laparoscopic approach [4, 7-10]. However, the number of publications and published series is small, especially in children [11, 12]. This can be explained by the technical difficulty due to the complex location of the organ in the retroperitoneum, its relation to surrounding organs and major vascular structures, and to the precarious pancreatic physiology and the high risk of postoperative complications, especially pancreatic leak [10, 13]. Additionally, many surgeons do not have extensive experience in pancreatic and laparoscopic surgery [14, 15].

Concerning LDP, the need for splenectomy is debated. Splenectomy with distal pancreatectomy is clearly indicated in most patients with adenocarcinoma of the pancreas. However, for benign lesions or tumours with low-grade malignant potential, the issue of splenectomy has remained controversial. To



**Figure 2.** Distal pancreatectomy performed with a laparoscopic linear stapler

reduce the risk of post-splenectomy sepsis and haematological disorders, several authors have emphasized the benefits of spleen preservation [16, 17]. The best option is conservation of both the splenic vessel and the spleen for the optimal function of the organ [15, 18]. On the other hand, spleen preservation adds another level of complexity to an already difficult laparoscopic procedure. The procedure is more difficult, time-consuming, and is associated with increased blood loss from small venous tributaries especially when the splenic vein and artery are involved [2].

Warshaw described an alternative approach which involves ligation of the splenic artery and vein [16, 19, 20]. Splenic blood supply is provided from the short gastric vessels and left gastroepiploic artery. The procedure is considered to be faster, less technically demanding and with less blood loss than splenic vessel preservation, but with the potential risk of splenic infarction and abscess, and residual splenic function remains unproven [10]. However, this manoeuvre should be avoided if splenic size is greater than normal or there is paucity or other abnormal conditions of gastric vessels [15, 20].

In both our cases the splenectomies were done due to unclear aetiology of solid tumour and preoperatively recognized splenic vessel infiltration confirmed intraoperatively. Additionally, in the first case there was splenomegaly and tumour penetration to the splenic hilum, and in the second, insufficiency of short gastric vessels with enlarged collateral circulation to epigastric vessels.

Overall morbidity of laparoscopic procedures concerning pancreatic resections is comparable with

open series and ranges from 23% to 47%, and that mortality is less than 5% [7, 21, 22]. Bleeding is the most common intraoperative complication. Gentle dissection of the pancreas body using modern devices (Liga-Sure, harmonic scalpel) is advised to avoid it. Special attention should be paid to sealing of splenic vessels. Some authors advise separating the vessels and ligature or clipping them before pancreas transection [10, 21]. In our cases the main part of the pancreas body was transected with an Endo-GIA tissue stapler (3.5 mm), and the upper border with splenic vessels with an Endo-GIA vascular stapler (2.5 mm). After stapler transection splenic vessels were additionally ligated with an Endo-Loop. There was no observation of bleeding in both cases.

The main problems after surgery of the pancreas are pancreatic fistula, sterile collection, abscess and wound disruption, all of them believed to be due to pancreatic leakage from the stump and reaching an incidence rate of 11-27% [4, 7, 8, 13, 15, 20, 23]. Stapler transection of the pancreas body is the most preferred in laparoscopic pancreatic surgery [5, 6, 9, 13, 24, 25]. Various other methods of pancreatic transection have been described in the literature: separate ligation of the pancreatic duct, over-sewing the pancreatic stump, mesh reinforcement of a stapled transection line, fibrin glue sealing of the stump, sealing of the parenchyma of the pancreatic stump with a radiofrequency device, patching the pancreatic stump with an omental plug or a patch taken from the falciform ligament, and the use of an ultrasonic or harmonic scalpel for tissue dissection have been advocated as successful [23-25]. However, a pancreatic fistula can occur independently of the method of pancreatic tissue resection [23]. In both our cases an Endo-GIA stapler was used and fortunately we did not observe leakage in the postoperative period.

Treatment by complete resection in most cases with Frantz tumour is curative, with a 5-year survival rate of about 95%. There are no data about differences according to the approach [2]. Breaking the mass during LDP and at the time of specimen removal must be avoided to minimize the risk of recurrence and peritoneal carcinomatosis. In this study we resected tumours in the limits of normal tissue, avoiding excessive preparation and tumour squeezing, and extracted the specimen in a nylon bag.

Laparoscopic distal pancreatectomy is equivalent to open distal pancreatectomy in procedure time,

rate of transfusions, complications, and mortality [21, 22]. However, after LDP hospital stay and convalescence are shorter and the cosmetic effect is better [21, 26]. Operative time (3 h) and hospital stay (4 and 6 days) in our cases were shorter compared with adult patients [7, 10, 18]. On the other hand, shorter operative time is described in some recently published series, which can be explained by the increasing experience of surgeons and advances in surgical instrumentation [4, 9].

We can conclude that the technique of LDP used for our cases is clear and does not differ from that advised in the literature for adult patients. The procedure is safe and gives good functional and cosmetic results, though the procedure itself is a hard task. The procedure has all the advantages of minimally invasive procedures and can be advised for distal pancreatectomy in children for surgeons experienced in laparoscopy.

## References

1. Bostanoglu S, Otan E, Akturan S, et al. Frantz's tumor (solid pseudopapillary tumor) of the pancreas: a case report. *J Pancreas* 2009; 10: 209-11.
2. Casadei R, Santini D, Calculli L, et al. Pancreatic solid-cystic papillary tumor: clinical features, imaging findings and operative management. *JOP J Pancreas* 2006; 7: 137-44.
3. Huang HL, Shih SC, Chang WH, et al. Solid-pseudopapillary tumor of the pancreas: clinical experience and literature review. *World J Gastroenterol* 2005; 11: 1403-9.
4. Corcione F, Marzano E, Cuccurullo D, et al. Distal pancreas surgery: outcome for 19 cases managed with a laparoscopic approach. *Surg Endosc* 2006; 20: 1729-32.
5. Shimizu S, Tanaka M, Konomi H, et al. Laparoscopic pancreatic surgery: current indications and surgical results. *Surg Endosc* 2004; 18: 402-6.
6. Stutchfield BM, Joseph S, Duckworth AD, et al. Distal pancreatectomy: what is the standard for laparoscopic surgery? *HPB* 2009; 11: 210-4.
7. Fabre JM, Dulucq JL, Vacher C, et al. Is laparoscopic left pancreatic resection justified? *Surg Endosc* 2002; 16: 1358-61.
8. Melotti G, Butturini G, Piccoli M, et al. Laparoscopic distal pancreatectomy: results on a consecutive series of 58 patients. *Ann Surg* 2007; 246: 77-82.
9. Taylor C, O'Rourke NO, Nathanson L, et al. Laparoscopic distal pancreatectomy: the Brisbane experience of forty-six cases. *HPB* 2008; 10: 38-42.
10. Palanivelu C, Shetty R, Jani K, et al. Laparoscopic distal pancreatectomy: results of a prospective non-randomized study from a tertiary center. *Surg Endosc* 2007; 21: 373-7.
11. Carricaburu E, Enezian G, Bonnard A, et al. Laparoscopic distal pancreatectomy for Frantz's tumor in a child. *Surg Endosc* 2003; 17: 2028-31.

12. Melotti G, Cavallini A, Butturini G, et al. Laparoscopic distal pancreatectomy in children: case report and review of the literature. *Ann Surg Oncol* 2007; 14: 1065-9.
13. Pierce RA, Spittler JA, Hawkins WG. Outcomes analysis of laparoscopic resection of pancreatic neoplasms. *Surg Endosc* 2007; 21: 579-86.
14. Edwin B, Mala T, Mathisen O, et al. Laparoscopic resection of the pancreas: a feasibility study of the short-term outcome. *Surg Endosc* 2004; 18: 407-11.
15. Fernandez-Cruz L, Orduna D, Cesar-Borges G, Lopez-Boada MA. Distal pancreatectomy: en-bloc splenectomy vs spleen-preserving pancreatectomy. *HPB* 2005; 7: 93-8.
16. Carrere N, Abid S, Julio C, et al. Spleen-preserving distal pancreatectomy with excision of splenic artery and vein: a case-matched comparison with conventional distal pancreatectomy with splenectomy. *World J Surg* 2007; 31: 375-82.
17. Koukoutsis I, Tamijmarane A, Bellagamba R, et al. The impact of splenectomy on outcomes after distal and total pancreatectomy. *World J Surg Oncol* 2007; 5: 61-5.
18. Han HS, Min SK, Lee HK, et al. Laparoscopic distal pancreatectomy with preservation of the spleen and splenic vessels for benign pancreas neoplasm. *Surg Endosc* 2005; 19: 1367-9.
19. Warshaw AL. Conservation of the spleen with distal pancreatectomy. *Arch Surg* 1988; 123: 550-3.
20. Rodriguez JR, Madanat MG, Healy BC, et al. Distal pancreatectomy with splenic preservation revisited. *Surgery* 2007; 141: 619-25.
21. Kim SC, Park KT, Hwang JW, et al. Comparative analysis of clinical outcomes for laparoscopic distal pancreatic resection and open distal pancreatic resection at a single institution. *Surg Endosc* 2008; 22: 2261-8.
22. Eom BW, Jang JY, Lee SE, et al. Clinical outcomes compared between laparoscopic and open distal pancreatectomy. *Surg Endosc* 2008; 22: 1334-8.
23. Ridolfini MP, Alfieri S, Gourgiotis S, et al. Risk factors associated with pancreatic fistula after distal pancreatectomy. Which technique of pancreatic stump closure is more beneficial? *World J Gastroenterol* 2007; 13: 5096-100.
24. Lorenz U, Maier M, Steger U, et al. Analysis of closure of the pancreatic remnant after distal pancreatic resection. *HPB* 2007; 9: 302-7.
25. Mc Johnston F, Cavataio A, Strasberg SM, et al. The effect of mesh reinforcement of a stapled transection line on the rate of pancreatic occlusion failure after distal pancreatectomy: review of a single institution's experience. *HPB* 2009; 11: 25-31.
26. Kooby DA, Gillespie T, Bentre D, et al. Left-sided pancreatectomy a multicenter comparison of laparoscopic and open approaches. *Ann Surg* 2008; 248: 438-46.