

A complex case of abdominal pain in a patient with pelviureteric junction obstruction

Przemysław Wolak^{1,2}, Tomasz Golabek³, Mateusz Obarzanowski⁴, Piotr Chłosta³

¹Institute of Nursing and Obstetrics, Faculty of Health Sciences, Jan Kochanowski University, Kielce, Poland

²Department of Pediatric Surgery, Urology and Traumatology, Władysław Buszkowski Children's Hospital, Kielce, Poland

³Department of Urology, Medical College Jagiellonian University, Krakow, Poland

⁴Department of Urology, Institute of Oncology, Kielce, Poland

Videosurgery Miniinv 2014; 9 (2): 273–275

DOI: 10.5114/wiitm.2014.41599

Abstract

Pelviureteric junction (PUJ) obstruction is a condition frequently encountered in both adult and pediatric patients. Congenital abnormalities and crossing lower-pole renal vessels are the most common underlying pathologies in both men and women. This report presents a case of a young woman who was complaining of intermittent abdominal pain in whom right-sided hydronephrosis was diagnosed. The patient was scheduled for a laparoscopic right-sided Anderson-Hynes pyeloplasty. During the procedure a partly extraperitoneal appendix, with extensive adhesions to the posterior abdominal wall abutting on the ureter just below the obstructed PUJ, was identified. The patient underwent dismembered laparoscopic Anderson-Hynes pyeloplasty with concurrent appendectomy for likely dual pathologies being responsible for her symptoms.

Key words: laparoscopic pyeloplasty, pelviureteric junction obstruction, incidental appendectomy, abdominal pain.

Introduction

Dismembered laparoscopic Anderson-Hynes pyeloplasty is an established alternative to traditional treatment of pelviureteric junction (PUJ) obstruction [1, 2]. The superiority of the laparoscopic approach includes precise dissection and therefore a minimal surgical trauma, as well as blood loss, which in turn result in short hospitalization and prompt recovery [3, 4]. Hydronephrosis can be either asymptomatic and be only detected incidentally while performing abdominal ultrasound for other reasons, or the patient may complain of abdominal or flank pain of variable degree often associated with urinary tract infection [5]. Hydronephrosis may coexist with other abdominal pathologies.

This report presents a case of a young woman who was complaining of intermittent abdominal pain in whom right-sided hydronephrosis was diag-

nosed. The patient was scheduled for a laparoscopic right-sided Anderson-Hynes pyeloplasty. During the procedure a partly extraperitoneal appendix, with extensive adhesions to the posterior abdominal wall abutting on the ureter just below the obstructed PUJ, was identified. The patient underwent dismembered laparoscopic Anderson-Hynes pyeloplasty with concurrent appendectomy.

Case report

A 23-year-old female, who presented with a 2-year history of intermittent right flank pain radiating to the right iliac fossa and the groin, was diagnosed with right-sided hydronephrosis based on the ultrasound examination. Subsequent intravenous urography (IVU) revealed delayed right kidney urine excretion. Additionally, a dilated pyelocalyceal system with a maximal caliceal diameter of 26 mm was

Address for correspondence:

Tomasz Golabek MD, PhD, Department of Urology, Medical College Jagiellonian University, 18 Grzegorzewska St, 31-531 Krakow, Poland, phone: +48 690 999 122, e-mail: elementare@op.pl

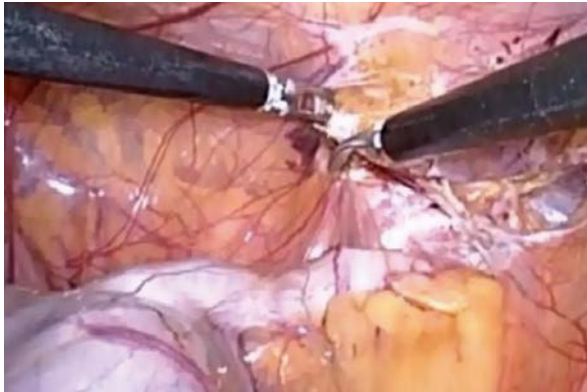


Photo 1. Partly extraperitoneal appendix with adhesions to the posterior abdominal wall

visible. However, nondilated ureter and no renal or ureteric stones were found on IVU. The ^{99m}Tc -DT-PA renal scan with furosemide showed split renal function of 30% on the right and 70% on the left. It also confirmed presence of the right-sided moderate-grade PUJ obstruction. The patient's urinalysis was unremarkable. There was no bacterial growth in the urine. Serum urea, creatinine and electrolyte concentrations were all within the reference range. Dismembered laparoscopic Anderson-Hynes pyeloplasty was offered to the patient. During the procedure a partly extraperitoneal appendix, with extensive adhesions to the posterior abdominal wall abutting in the close vicinity of the right ureter just below the obstructed PUJ, was found (Photo 1). However, there were no features of acute appendicitis present. An accessory renal vessel supplying the lower pole of the right kidney and compressing the PUJ was identified (Photo 2). Dismembered laparoscopic Anderson-Hynes pyeloplasty with preservation of the accessory renal vessel and concurrent appendectomy were performed. The patient's postoperative recovery was uneventful and she was discharged home on the 7th day after the surgery. The follow-up ultrasound of the upper urinary tract showed no abnormalities and the patient continues to be asymptomatic since the surgery.

Discussion

In 1993 Schuessler first performed successful dismembered laparoscopic pyeloplasty of a pelvi-ureteric junction obstruction in an adult [6]. Following introduction of robotic surgery with robot-assisted techniques and other minimally invasive techniques, dismembered laparoscopic pyeloplasty

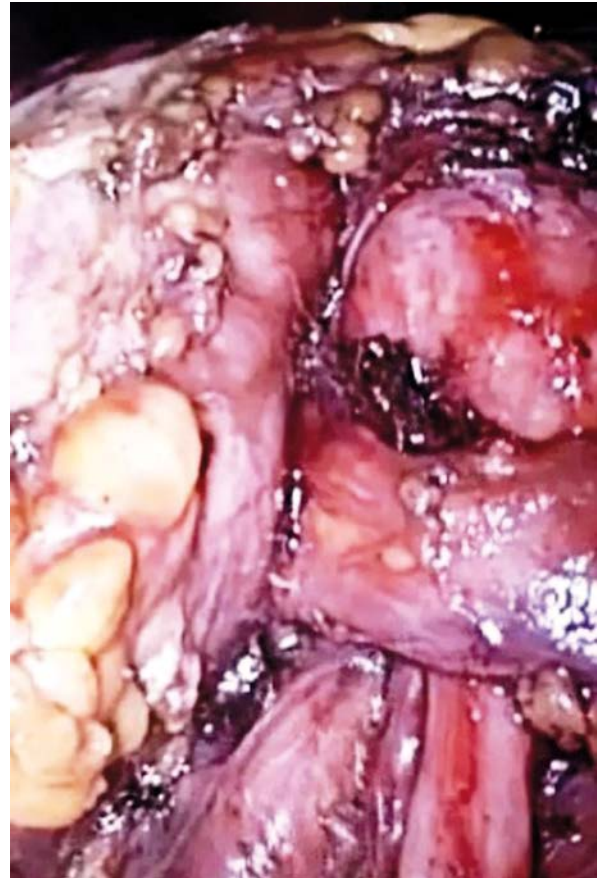

Photo 2. Lower pole of the right kidney with accessory vessel crossing the right ureter

has continued to be the standard treatment for PUJ obstruction [2]. Moreover, for the last decade further refinement of the laparoscopic techniques and equipment has allowed this type of surgery to be safely performed in selected cases as a 1-day procedure [7].

In our patient a dismembered laparoscopic pyeloplasty and appendectomy were simultaneously performed as the appendix with its extensive adhesions to the posterior abdominal wall was located in the close vicinity of the obstructed right PUJ, and could therefore be responsible for the patient's symptoms. Several studies have reported that appendicitis may impair renal urinary outflow which, as a consequence, can result in deteriorated renal function [8].

Tripp *et al.* described a case of bilateral urinary outflow obstruction due to a periappendiceal abscess [7]. It seems likely that in our patient, as a result of several courses of antibiotic treatments for reasons other than suspected appendicitis, the in-

flammatory process within the appendix could have been thereby limited. Therefore, recurrent appendicitis as a cause of the patient's intermittent abdominal pain could not have been excluded. Hence, simultaneous dismembered laparoscopic pyeloplasty and appendectomy seemed to have been the best treatment [9].

Evidence from American studies has shown that incidental appendectomy is a cost-effective procedure as it reduces the need for secondary intervention [10].

Conclusions

A dismembered laparoscopic pyeloplasty performed by an experienced urologist is a preferred treatment for PUJ obstruction. It allows for optimal visualization of co-existent intra-abdominal pathologies and simultaneous interventions. In patients with PUJ obstruction in whom the appendix could be a possible cause of symptoms, concurrent pyeloplasty and appendectomy is advised.

References

1. Szydelko T, Tuchendler T, Litarski A, et al. Laparoscopic Anderson-Hynes procedure as a treatment of ureteropelvic junction obstruction caused by fibroepithelial polyp. *Videosurgery Miniinv* 2013; 8: 361-3.
2. Wu Z, Feng C, Ding Q, et al. Ureteroscopic holmium:YAG laser endopyelotomy is effective in distinctive ureteropelvic junction obstructions. *Videosurgery Miniinv* 2011; 6: 144-9.
3. Stránský P, Eret V, Úrge T, et al. Laparoscopic adrenalectomy for metachronous ipsilateral metastasis following nephrectomy for renal cell carcinoma. *Videosurgery Miniinv* 2013; 8: 221-5.
4. Golab A, Slojewski S, Sikorski A. Simplified laparoscopic technique for the treatment of long distal ureteral stenosis. *Videosurgery Miniinv* 2013; 8: 346-51.
5. Kupajski M, Tkocz M, Ziaja D. Modern management of stone disease in patients with a solitary kidney. *Videosurgery Miniinv* 2012; 7: 1-7.
6. Schuessler WW, Grune MT, Tecuanhuey LV, Preminger GM. Laparoscopic dismembered pyeloplasty. *J Urol* 1993; 150: 1795-9.
7. Tripp BJ, Homsy YL, Kiruluta G. Bilateral ureteral obstruction secondary to a perforated appendiceal abscess. *J Urol* 1995; 154: 1158-9.
8. Varadhan KK, Humes DJ, Neal KR, et al. Antibiotic therapy versus appendectomy for acute appendicitis: a meta-analysis. *World J Surg* 2010; 34: 199-209.
9. Twang H, Sax HC. Incidental appendectomy in the era of managed care and laparoscopy. *J Am Coll Surg* 2001; 192: 182-8.
10. Costa F, Marchese LT, Fernandes MBL. Segmental ureteral necrosis due to acute appendicitis. *J Urol* 2000; 164: 483-4.

Received: 26.08.2013, **accepted:** 5.11.2013.