

# Diagnosis and management of early gastric band slip after laparoscopic adjustable gastric banding

Mehmet Sertkaya, Arif Emre, Fatih Mehmet Yazar, Ertan Bülbüloğlu

Department of General Surgery, Kahramanmaraş Sütçü İmam University, Kahramanmaraş, Turkey

Videosurgery Miniinv 2016; 11 (2): 121–125

DOI: 10.5114/wiitm.2016.60237

## Abstract

Laparoscopic adjustable gastric banding (LAGB) used to be a very popular bariatric procedure at a certain time for the treatment of obesity as it has many advantages and is associated with low morbidity and mortality rates. Complications are often late and are rarely seen by general surgeons due to the limited number of patients, and physicians should be aware of the symptoms. We present a case of a 40-year-old female patient who underwent LAGB and was admitted for a huge gastric pouch dilatation on postoperative day 5. She had a history of food consumption on the fourth day after surgery. She was diagnosed with early gastric band slippage (EGBS). The band was repositioned and gastrogastic sutures were placed to prevent re prolapse of the band. The EGBS is an immediate postoperative complication. Diagnosis of EGBS can be made with oral contrast X-ray studies, and surgical intervention is necessary.

**Key words:** obesity, complications, gastric banding, anterior band slip.

## Introduction

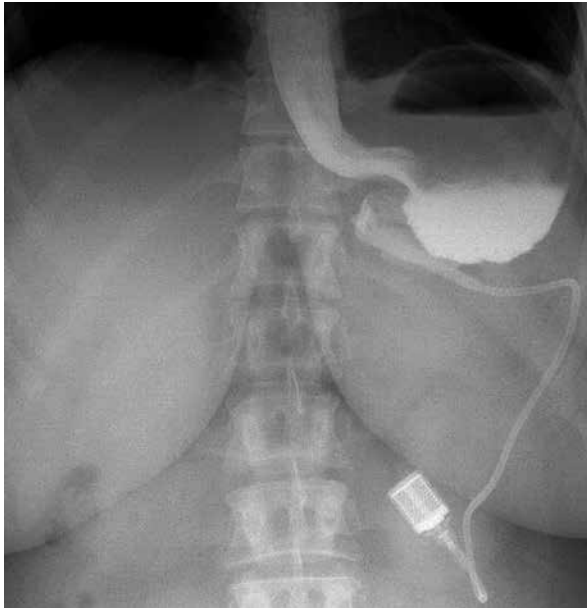
Bariatric surgery is worldwide an acceptable and the most preferred method for sustained weight loss in severely obese patients. Laparoscopic adjustable gastric banding (LAGB) sounds plausible to the patients and the surgeons as it has many advantages including simplicity of the tool, the relatively low morbidity of the surgery, the quick recovery, adjustability, reversibility, and positive overall results. Despite its many advantages, it has several early and late complications generally documented as band obstruction, gastric perforation, wound infection, bleeding, band slippage, pouch or esophageal dilatation, band erosion, and band migration. Rarely are these complications life-threatening, but early and accurate diagnosis and management is a matter of utmost importance to prevent ensuing results.

## Case report

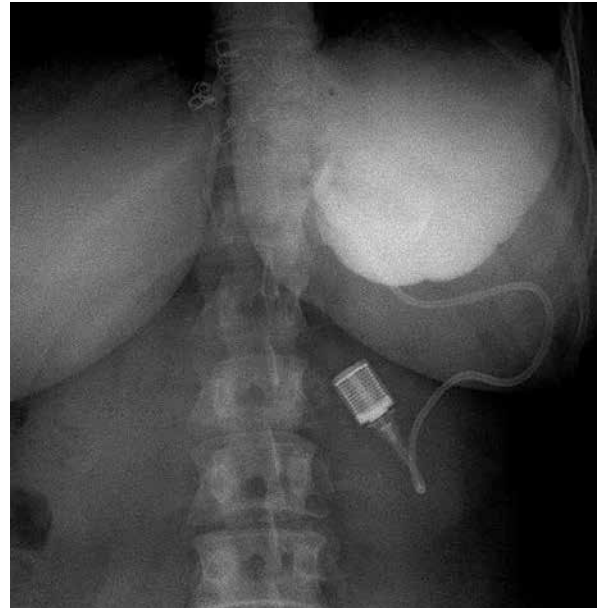
A 40-year-old woman with a body mass index (BMI) of 43.2 kg/m<sup>2</sup> was admitted and underwent an uneventful LAGB placement. The patient's recovery was uneventful and she was discharged home on the 2<sup>nd</sup> postoperative day. Five days after surgery she presented to the emergency department with complaints of abdominal pain and persistent vomiting. Oral contrast enhanced X-ray imaging was performed at the first (Photo 1), 20<sup>th</sup> (Photo 2), and 40<sup>th</sup> minute (Photo 3), and the first hour (Photo 4), which revealed no evidence of contrast passing into the intestine and showed a huge gastric pouch above the gastric band, with an air-fluid level (Photo 1) and delayed emptying of the stomach, which was very suggestive of anterior slippage. The patient was admitted for treatment and a nasogastric tube was inserted into the stomach. After preparing for reoperation she underwent a lap-

### Address for correspondence

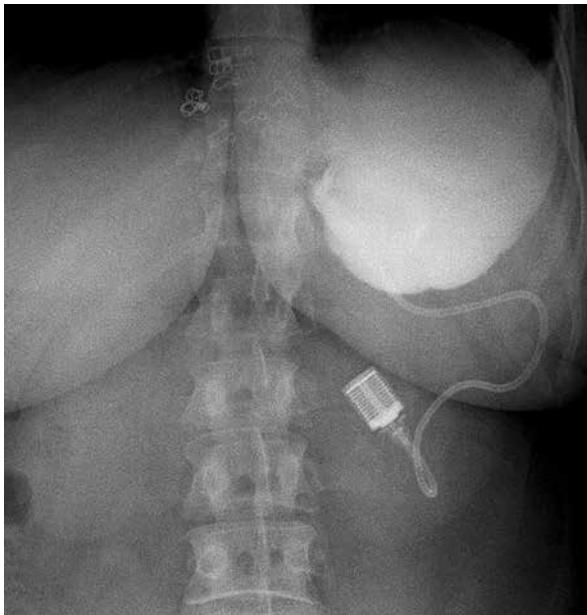
Mehmet Sertkaya, Department of General Surgery, Kahramanmaraş Sütçü İmam University, 46100 Kahramanmaraş, Turkey, phone: +90 5052214334, e-mail: drsertkaya@gmail.com



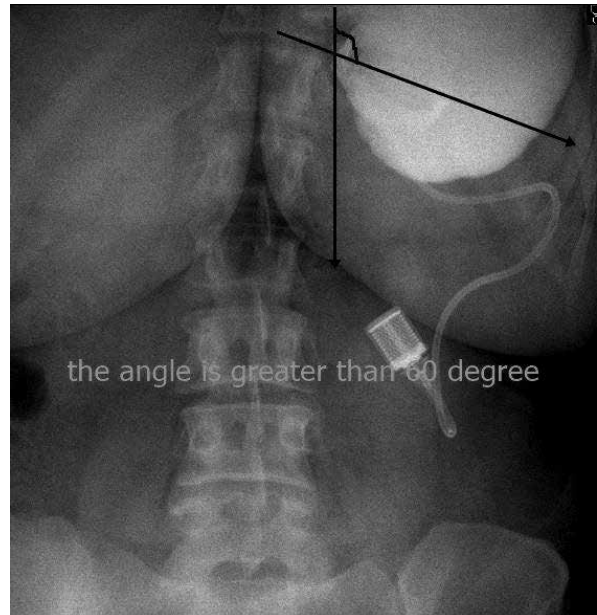
**Photo 1.** Plain abdominal X-ray in the first minute after swallowing Gastrografin showing air-fluid level in the stomach



**Photo 2.** Plain abdominal X-ray in the 20<sup>th</sup> minute after swallowing Gastrografin showing gastric dilatation



**Photo 3.** Plain abdominal X-ray in the 40<sup>th</sup> minute after swallowing Gastrografin showing no passage to the intestine



**Photo 4.** Plain abdominal X-ray in the first hour after swallowing Gastrografin showing no passage to the intestine. When measured the band had lost its angle, which should be 50–60°

aroscopy. In exploration we saw that the gastric band was prolapsed down to the pylorus. With the help of laparoscopic graspers the gastric band was pulled up, the stomach was pulled down through the band, the band was repositioned in its initial place, and three

gastrogastric imbrication sutures were successfully applied. The patient's recovery was uneventful and she was discharged home on the 2<sup>nd</sup> postoperative day. At the 20-month follow-up she had no problems and had a weight loss of 24%.

## Discussion

While lifestyle and eating habits have changed, obesity has become a challenging health problem worldwide as it is related to many comorbid diseases and attributable deaths [1–3].

Nonsurgical therapies including dietary changes and exercise can facilitate a 5–10% weight loss, which is not enough to reduce the risks of morbid obesity. The limited success of all these therapies made surgical treatment for the management of obesity inevitable [1–3]. Available procedure options for bariatric surgery include restrictive, malabsorptive or a combination of both functions, and the decision about technique is influenced by many factors such as BMI, general performance status, age, concurrent diseases, and also the surgeon's skills and experience [4].

Gastric bypass surgery has been at the forefront of surgical treatment for weight loss since the 1960s. After becoming unsatisfied with complications of the gastric bypass procedure for the treatment of morbid obesity, doctors began to think about a new procedure which can limit the caloric intake and ensure early satiety by diminishing the capacity of the stomach, while on the other hand maintaining the normal continuity of the gastrointestinal tract. Firstly, they tried nonadjustable gastric banding procedures using mesh types and encountered many complications and high reoperation rates. All this struggle with nonadjustable gastric banding led to the development of laparoscopic adjustable gastric banding [2]. It should also be noted that the evolution continues in obesity surgery and new procedures may surface in the near future.

There are two different techniques for adjustable gastric band placement. The first adjustable gastric band was offered to the world of surgery by Kuzmak, but the first LAGB operation was carried out by Belachew in 1993 with a perigastric technique. As time passed, because of the high complication rate attributed to the perigastric technique, most surgeons preferred the pars flaccida technique in adjustable gastric band placement [5].

In the perigastric technique, a small window at the lesser curvature of the stomach 3 cm below the gastro-esophageal junction is formed as an origin for a tunnel below the gastric wall and extended to the angle of His. After placing the band inside the abdomen through a trocar with a grasper, it is pulled through this tunnel with graspers and locked to create a gas-

tric pouch. Before locking the band, using a calibration bougie which is inserted orally into the stomach and inflated with 25 cc saline helps to adjust a 15–30 ml gastric pouch above the band. To reduce the risk of slippage, three to five anterior sutures between the greater curvature and gastric pouch are placed to create gastric plication. Finally, the connecting tube is pulled outside the abdomen through a trocar with the help of a grasper and linked to the port, which is fixed to the abdominal fascia with sutures [5].

In the pars flaccida technique, the dissection begins near the angle of His, and the thin area of the gastrohepatic ligament, that is the pars flaccida, over the caudate lobe, is divided. Continuing the dissection, the right crus is isolated and the peritoneum at the border of the crus is cut. Then, to make a tunnel for the band, a grasper is passed behind the gastro-esophageal junction to the angle of His. Thus the band is placed in the same way as in the perigastric technique. Through the oral route, a calibration bougie is inserted into the stomach and the balloon at the end of it is filled with 15 cc of saline to create a gastric pouch before closing the band. Also gastric plication is performed by applying three to five anterior sutures between the gastric wall and gastric pouch. The remaining process is completed in the same way as in the perigastric technique [5].

With time, it has been proven that the perigastric technique is associated with more frequent complications such as band slippage than the pars flaccida technique [5].

In the first operation for the present case we preferred the perigastric technique and placed three gastro-gastric sutures for plication to avoid band slippage. The possible reasons of gastric band slippage which occurred in this case can be listed as follows: the first sutures we applied may have become loosened, or may not have been enough to strengthen the line to avoid slippage, or the slippage which occurred in this case may be related directly to the perigastric technique. Also the patient's behavior on consuming solid food at an early stage may be the main reason for the sutures become loose and causing the slippage.

While laparoscopic adjustable gastric banding used to be a very popular bariatric procedure at a certain time, there is growing evidence of complications following gastric banding. Parallel to this situation, the use of the laparoscopic sleeve gastrectomy procedure is increasing [1]. Complications of LAGB can

be classified as minor complications such as pouch dilatation (12%), persistent gastroesophageal reflux disease (7%), port prominence (2.5% to 6%), port malfunction (< 1%), and major complications such as band slippage (< 5%), late port infection (< 1%), band erosion (< 1%), and stomal obstruction. Diagnosis is generally achieved by upper gastrointestinal series, upper endoscopy, ultrasonography and physical examination, and management consists of band deflation and repositioning, endoscopic dilation of obstruction, surgical removal of the band, behavioral diet modification, proton pump inhibitor treatment, abscess drainage, and systemic antibiotics. The management depends on the seriousness of the complication [6, 7].

Complications also could be classified as early complications, e.g. band obstruction, gastric perforation, wound infection, and bleeding, and late complications, e.g. band slippage, pouch or esophageal dilatation, band erosion, and port or tubing complications. Band slippage or prolapse of the band is when a part of the stomach herniates through the band. Recent studies show a 4% rate of occurrence of vomiting and abdominal pain [2]. Herein, we present a case of band slip with a huge pouch dilatation causing persistent vomiting starting on the 5<sup>th</sup> postoperative day. Eid *et al.* classified band slips into 5 types [3]:

- Anterior slip (type 1 prolapse) occurs with downward migration of the band, that is upward migration of the anterior wall of the stomach through the band, and is due to insufficient anterior fixation and disruption of the fixation sutures. Also it can be related to increased pressure in the pouch due to early solid food, vomiting, overeating or early band fill. In both anterior and posterior slips, the patient presents with dysphagia, vomiting, regurgitation and food intolerance, upper gastrointestinal series are useful for diagnosis and surgical treatment is indicated [3].
- Posterior slip (type 2 prolapse) occurs when the posterior wall of the stomach herniates through the band, and it is related to the surgical technique [3].
- Pouch enlargement (type 3 prolapse) is defined as dilatation of the proximal gastric or esophageal pouch with or without change in the angle of the band and without any signs of obstruction and is a pressure-related condition like surgical band overinflation or overeating which causes increased pressure in the pouch. Symptoms include lack of

satiety, heartburn, regurgitation and occasional chest pain, and the diagnosis can be made with an upper gastrointestinal series. Complete band deflation and re-education is useful in the treatment, but when it fails, band removal or replacement is indicated [3].

- Type 4 prolapse is described as an immediate postoperative prolapse and is generally due to placing the band too low on the stomach. Solid food intake or unconsciously eating more food is also suspected in the etiopathogenesis [3].
- Type 5 prolapse is defined as posterior or anterior slip with gastric perforation due to necrosis of the slipped stomach. Band slip types 1, 2, 4, 5 are acute and always necessitate surgical treatment, and laparoscopic removal or repositioning of the band is the most preferred method, but pouch enlargement is a chronic complication that can be managed nonsurgically in the first instance [3].

Kang *et al.* reported in their 6-year experience with 1347 patients who underwent an LAGB procedure that they encountered 47 patients who developed band prolapse and 7 were treated with endoscopy. According to this published article, band prolapse is a significant and common late complication following LAGB, the incidence of which within 5 years is approximately 5%, and it requires operative procedures. Use of gastrogastic sutures to prevent band prolapse is advocated [8]. The present case is concurrent with type 4 prolapse and is thought to be caused by early consumption of food. Although the patient was warned and recommended to be cautious about food consumption before discharge, she did not realize the severity of the condition until she found herself in the emergency room. The required surgical intervention was made after gastric decompression by nasogastric tubing. As can be seen in Photo 4, the band had lost its angle, which should be 50–60°. Since the band regulates the width of the lumen and the time of food passage from the upper stomach segment, the angle between the band and the vertical plane should be 50–60° [7]. During the operation we realized that the anterior wall of the stomach was fully herniated upward through the band. It was not hard to replace the band to its initial place using graspers. To prevent re prolapse we preferred to fasten the band after repositioning with gastrogastic imbrication sutures.

Chiapaikao *et al.* reported a 13.8% reoperation rate in LAGB, which is a lower range compared to the

16–60% reoperation rate that is seen in the current literature. They also remarked that the gastric prolapse was the most common complication leading to band removal (4.6%). According to the evidence, being a weight-loss procedure with low morbidity, LAGB has the highest reoperation rates when compared with other procedures such as gastric bypass and sleeve gastrectomy [9].

Lee *et al.*, in their three-year pouch dilatation and slippage management study, remarked that pouch dilatation and band slippage were the most common long-term complications after LAGB. They recorded that 11.1% (14 patients among 126 patients) of patients were diagnosed with these complications. Among them there were 7 patients who had pouch dilatation with anterior slippage, consisting of 3 with early anterior slippage which was managed conservatively, 2 with acute anterior slippage one of whom underwent a revision, and 2 cases with chronic anterior slippage one of whom underwent a revision [10].

For the LAGB procedure, although the operation is uneventful and the surgeon is well served by his experience, one should bear in mind that patient-related or band-related problems could arise in the ensuing days after surgery. Hence, the first radiological assessment should be performed after 1–2 days following the gastric banding procedure to ensure that the band and other components of the whole system are in the exact location and to exclude a possible perforation of the gastrointestinal tract [7]. As the delayed diagnosis of a band prolapse has an important potential for life-threatening complications such as pouch necrosis and gastric perforation [8], the pertinent doctors should be alert for band prolapse when a patient presents to the emergency department or when faced with symptoms such as vomiting, abdominal pain or dysphagia after an LAGB procedure. Band prolapse can be diagnosed easily by oral contrast X-ray or by endoscopy [8].

In summary, we can say that LAGB is a clinical-surgical treatment for obesity and it begins with the placement of the band, but success can be achieved with postoperative clinical decisions about how and when to adjust the band, dietary guidance, recognition and treatment of eating disorders, comorbidities, and early diagnosis and treatment of complications. These are all important aspects that are crucial to achieve the best results [11].

## Conclusions

The LAGB is one of the most common procedures used for the treatment of morbid obesity. The complications are generally not mortal but an accurate diagnosis is essential for the best results for the patients and surgeons. Early band slip is an acute emergency complication of LAGB. It can be diagnosed by oral contrast X-ray imaging, and surgical intervention is necessary. In addition, the surgeon and patient should consider the role of change in eating habits in the prevention and treatment of obesity and its complications.

## Conflict of interest

The authors declare no conflict of interest.

## References

1. Brown W, Korin A, Burton P. Laparoscopic adjustable gastric banding. *Australian Fam Phys* 2009; 38: 972-6.
2. Snyder B, Wilson T, Mehta S, et al. Past, present, and future: critical analysis of use of gastric bands in obese patients. *Diabetes Metab Syndr Obes* 2010; 3: 55-65.
3. Eid I. Complications associated with adjustable gastric banding for morbid obesity: a surgeon's guide. *Can J Surg* 2011; 54: 61-6.
4. Razak Hady H, Dadan J, Soldatow M, et al. Complications after laparoscopic gastric banding in own material. *Videosurgery Miniinv* 2012; 3: 166-74.
5. Banli O, Altun H, Aslan E, et al. Laparoscopic adjustable gastric banding: technique and results. *Eur J Endosc Laparosc Surg* 2014; 1: 167-71.
6. Kodner C, Hartman DR. Complications of adjustable gastric banding surgery for obesity. *Am Acad Fam Phys* 2014; 89: 813-8.
7. Nowicki G, Maliborski A, Zukowski P, Bogusławska R. Radiology of upper gastrointestinal tract with ASGB (adjustable silicone gastric banding) for morbid obesity. *Pol J Radiol* 2010; 75: 11-7.
8. Kang S, Kim KC, Kim KH. Endoscopic treatment of gastric band prolapse. *Obes Surg* 2014; 24: 954-7.
9. Chiapaikeo D, Schultheis M, Protyniak B, et al. Analysis of reoperations after laparoscopic adjustable gastric banding. *JSL* 2014; 18: e2014.002104.
10. Lee WK, Kim SM. Three-year experience of pouch dilatation and slippage management after laparoscopic adjustable gastric banding. *Yonsei Med J* 2014; 55: 149-56.
11. Pajeccki D, Mancini MC, Halpern A, et al. Multidisciplinary approach to morbidly obese patients undergoing surgical treatment by adjustable gastric banding. *Rev Col Bras Cir* 2010; 37: 328-32.

Received: 14.03.2016, accepted: 15.05.2016.