

# Minimally invasive surgery for resection of ossification of the ligamentum flavum in the thoracic spine

Wei Zhao, Chaoxiong Shen, Ranze Cai, Jianfeng Wu, Yuandong Zhuang, Zhaowen Cai, Rui Wang, Chunmei Chen

Department of Neurosurgery, Fujian Medical University Union Hospital, Fuzhou, China

Videosurgery Miniinv 2017; 12 (1): 96–105  
DOI: <https://doi.org/10.5114/wiitm.2017.66473>

## Abstract

**Introduction:** Thoracic ossification of the ligamentum flavum (TOLF) is a common cause of progressive thoracic myelopathy. Surgical decompression is commonly used to treat TOLF.

**Aim:** To evaluate the clinical outcomes of microsurgical decompression of TOLF via a paraspinal approach, using a percutaneous tubular retractor system.

**Material and methods:** First, three-dimensional (3D) image reconstruction and printed models were made from thin computed tomography scans for each patient. Then, 3D computer-assisted virtual surgery was performed using the 3D reconstruction to calculate the precise location and sizes of the bone window and the angle of insertion of the percutaneous tubular retractor system. In total, 13 patients underwent the surgery through the percutaneous micro channel unilateral vertebral approach under electrophysiological monitoring. Five days after the surgery, increased creatine phosphokinase levels returned to preoperative levels. The Japanese Orthopedic Association (JOA) score was improved and computed tomography reconstruction and magnetic resonance imaging of the thoracic spine showed that decompression was achieved without injuries to the spinal cord or nerve root. The stability of the spine was not affected, nor were any deformities of the spine detected. Finally, nerve functional recovery was achieved with minimal injury to the paraspinal muscle, articular process and spinous process and ligament.

**Results:** The mean operative time was  $98.23 \pm 19.10$  min, and mean blood loss was  $19.77 \pm 5.97$  ml. At a mean follow-up of 13.3 months (median: 12 months), the mean JOA score was  $7.54 \pm 1.13$  at the final follow-up, yielding a mean RR of  $49.10 \pm 15.71\%$ . Using The recovery rate, 7 (53.85%) patients had good outcomes, 5 (38.46%) patients had a fair outcome, and 1 (7.69%) patient had poor outcomes, indicating significant improvement by the final follow-up examination ( $p < 0.05$ ).

**Conclusions:** The 3D printed patient model-based microsurgical resection of TOLF via the paraspinal approach can achieve decompression of the spinal canal with minimal complications, faster recovery and improved stability of the vertebral body.

**Key words:** thoracic, ossification of ligamentum flavum, minimally invasive surgery, tubular retractors, 3D printing.

## Introduction

Ossification of the ligamentum flavum (OLF) is one of the major causes of thoracic spinal canal stenosis, with severe cases leading to paralysis of the lower limbs. Thoracic OLF (TOLF) usually leads to

blunt compression of the spinal cord, and conservative treatment is generally ineffective. Decompression is the only effective method for treating TOLF [1]. Therefore, once symptoms appear, early diagnosis and surgical treatment of TOLF are particularly important [2, 3]. Related studies show that ossifica-

### Address for correspondence

Chunmei Chen MD, Department of Neurosurgery, Fujian Medical University Union Hospital, 29 Xinquan Road, 350000 Fuzhou, China, phone: +86 13509339040, e-mail: [chenchunmei@hotmail.com](mailto:chenchunmei@hotmail.com)

tion of the yellow ligament is a form of endochondral ossification, which is caused by mechanical stress stimulation [4].

Several types of surgical methods have been proven to be effective for TOLF, including laminoplasty, laminectomy and lamina fenestration [5–7]. A caveat of these methods is that they can influence the stability of the spine or paraspinal muscle and cause soft tissue damage or spinal cord injury. As such, there has been a trend towards minimally invasive spinal surgery (MISS) [8–11]. The most prominent advantage of MISS is that it reduces the iatrogenic soft-tissue injury, a difference that is often reflected in perioperative outcome measures [12, 13]. Recently, reports of successful bilateral decompression conducted via the unilateral approach have appeared [14]. Our group has also preliminarily utilized the skin micro channel unilateral paravertebral approach for treatment of intraspinal tumors and intervertebral disc herniation [15, 16].

Thoracic vertebral clearance is narrow and vertebral alignment is dense. Therefore, the size and location of the bony opening should be accurate. In order to protect the stability of the spine, the size of the lamina resection site should be smaller than the lesion area, subsequently expanding according to the operation needs. Due to the presence of a deviation in the surgical location and the need for expansion of the bony opening, this strategy is likely to harm the facet joints, resulting in spinal instability. In order to improve the accuracy of the operation, the help of 3D printing auxiliary preoperative planning is necessary.

Three dimensional printing in science has been increasingly used over the last 20 years [17]. The improvement of 3D imaging and 3D printing has led to a variety of surgical specialties embracing these innovative technologies, particularly in the field of reconstructive surgery [18, 19]. Using 3D-computed tomography (CT) reconstruction and magnetic resonance imaging (MRI), 3D printers can produce visible anatomical and pathological structures. High concordance with patient anatomy, a decrease in production costs, expediency of the fabrication process and its utility for pre-surgical planning and teaching have made 3D printing increasingly popular. Preoperative planning using Materialise Mimics-3D professional image processing software allows the processing of thoracic CT patient data, printing of thoracic patient

models, and the calculation of preoperative parameters using simulation channels.

## Aim

On this basis, we set out to test the efficacy of this method in the treatment of TOLF.

## Material and methods

### Patient demographics

Between August 2014 and January 2016, 13 patients underwent surgery in our Spine Surgery Department associated with TOLF (Table I). The inclusion criteria for patients were systematic physical examination and complete preoperative investigation (CT three-dimensional reconstruction of the thoracic spine was performed preoperatively and 1 week postoperatively, and MRI plain scan of the thoracic spine was also conducted preoperatively and 1 week and 6 months postoperatively) for the confirmation of both TOLF and the efficacy of the surgery (Photo 1). Approval of the TOLF study was obtained from the Institutional Review Board and written informed consent was obtained from all study participants.

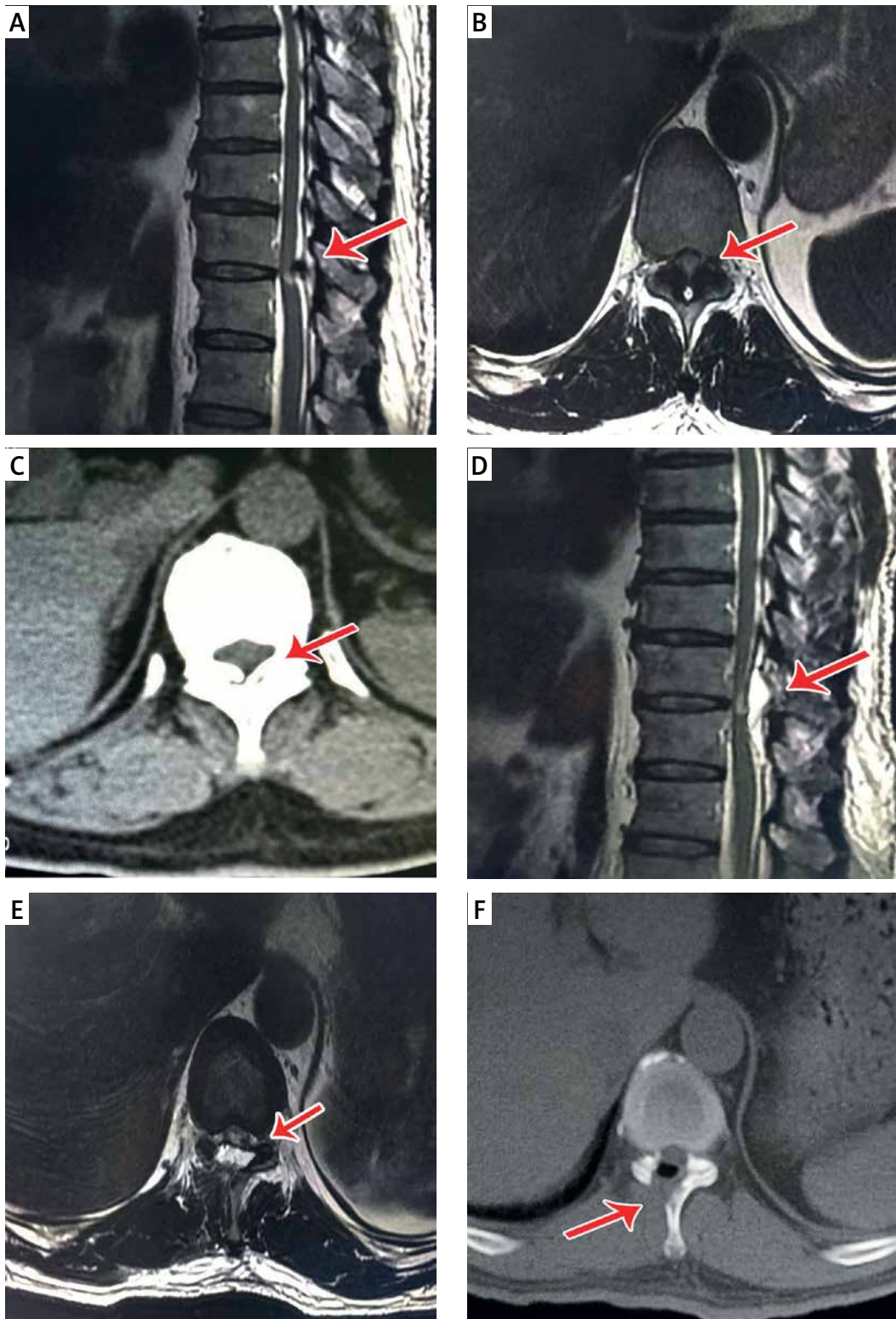
### Preoperative planning

Doctor-patient communication is very important before surgery and 3D printed patient models are a good tool for communication with patients. In this study, each patient was examined for 3D reconstruction of thoracic CT. Additionally, Materialise Mimics processing of the thoracic CT data was performed and 3D printing was used to generate a specific patient model of the vertebral body (Photo 2). Next, according to the needs of each patient's surgery and lesions, a precise surgical plan, including location and size of the bony opening, was determined by the computer to minimize damage of the facet. Additionally, patient models were used to explain the specific pathological changes to the patients, along with an explanation of the necessary surgical procedures. Simultaneously, surgeons measured vertebral fenestration in the model and determined the specific location and size of bone window needed during surgery, in order to understand the obstacles that may be encountered during the operative approach (osteophyma, developmental variation, etc.). This allowed for the planning of the best operative approach before the operation.

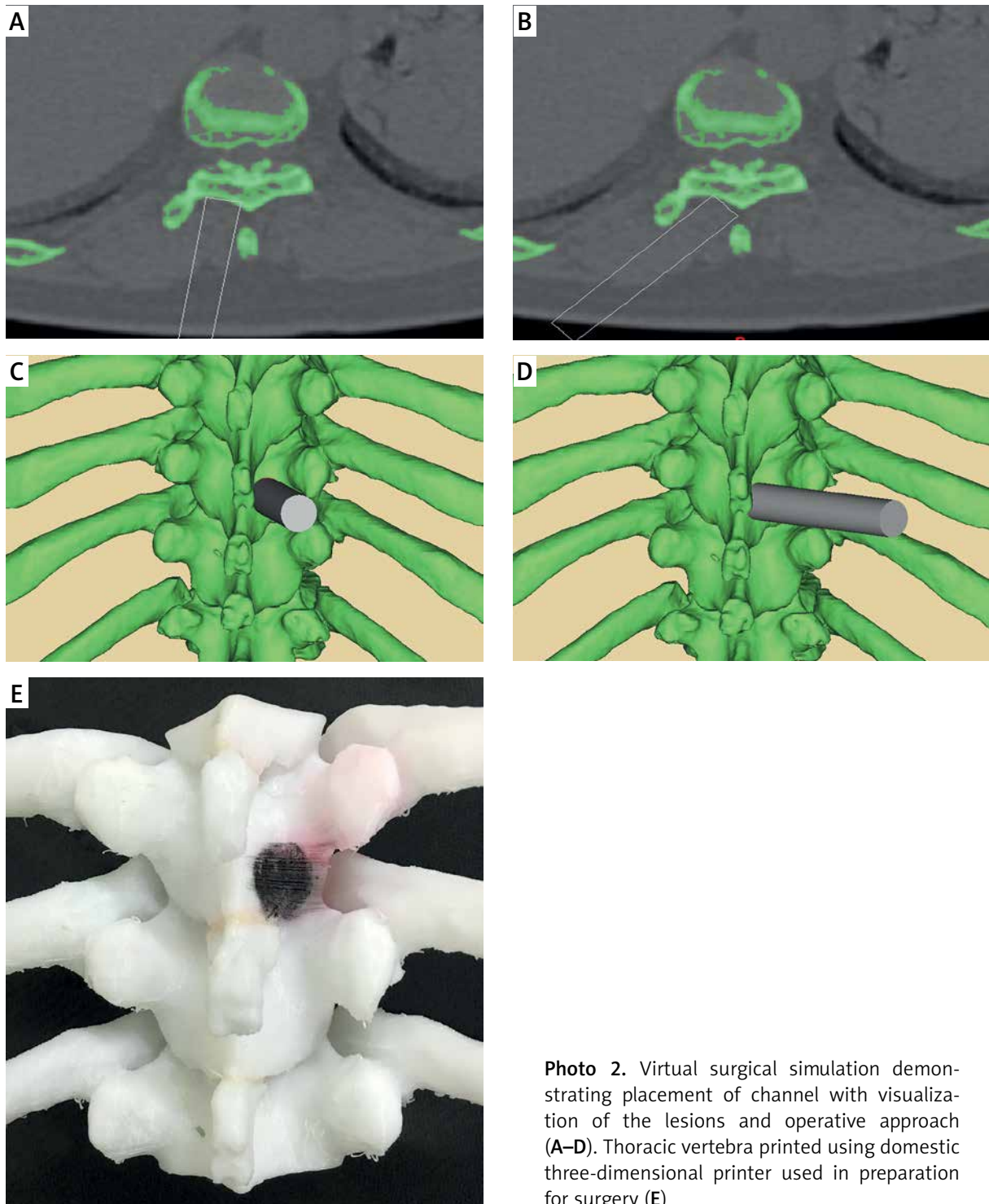
**Table 1.** Summary of clinical features obtained in the 13 patients with thoracic ossification of the ligamentum flavum

Patient no.	Age, sex	Signs and symptoms	Duration of symptoms [months]	Spinal levels of OLF	Operated levels	JOA score		Recovery rate (%)	Follow-up [months]
						Preop.	Postop.		
1	47, M	Lower limb weakness, numbness and hypesthesia below T9	4	T9-11	T9	4	4	42.86	20
2	53, M	Lower limb weakness, numbness and urinary incontinence	13	T10-11	T11	3	6	37.50	6
3	62, F	Lower limb weakness, numbness, gait disorder and urinary incontinence	6	T9-10	T9	3	7	50.00	23
4	51, M	Progressive paraparesis and gait disorder, low back pain and urinary incontinence	3	T7-10	T7-9	4	8	57.14	12
5	54, F	Post-trauma urinary incontinence, numbness and neurological claudication	4	T6-7	T6	5	9	66.67	20
6	35, F	Gait disorder, numbness and hypesthesia below T9	2	T8-10	T8-9	6	8	40.00	12
7	55, M	Lower limb weakness, numbness and urinary incontinence	2	T10-11	T10	3	6	37.50	10
8	71, M	Lower limb weakness, gait disorder, numbness and hypesthesia below T12	8	T10-12	T10-12	4	9	71.43	10
9	42, M	Gait disorder, numbness and hypesthesia below T12	4	T9-11	T10-11	6	8	40.00	12
10	59, F	Lower limb weakness, low back pain, urinary incontinence	4	T10-11	T10	4	9	71.43	16
11	62, F	Gait disorder, urinary incontinence, numbness and hypesthesia below T9	3	T8-10	T8-9	3	7	50.00	6
12	48, M	Lower limb weakness, numbness and hypesthesia below T10	5	T9-10	T9	4	8	57.14	12
13	52, F	Urinary incontinence, numbness and neurological claudication	15	T10-11	T10	5	6	16.67	14

F – female, M – male, preop. – preoperatively, postop. – postoperatively.



**Photo 1.** A 59-year-old woman (patient 10). Preoperative T2-weighted sagittal (A), axial (B) magnetic resonance imaging (MRI) and axial computed tomography (CT) scan (C) showed typical radiologic findings of (TOLF) and compression of the thoracic spinal cord by the nodular type lesion. Postoperative T2-weighted sagittal (D), axial (E) MRI, axial CT scan (F) showed the sufficiency of decompression



**Photo 2.** Virtual surgical simulation demonstrating placement of channel with visualization of the lesions and operative approach (A–D). Thoracic vertebra printed using domestic three-dimensional printer used in preparation for surgery (E)

### Surgical procedure

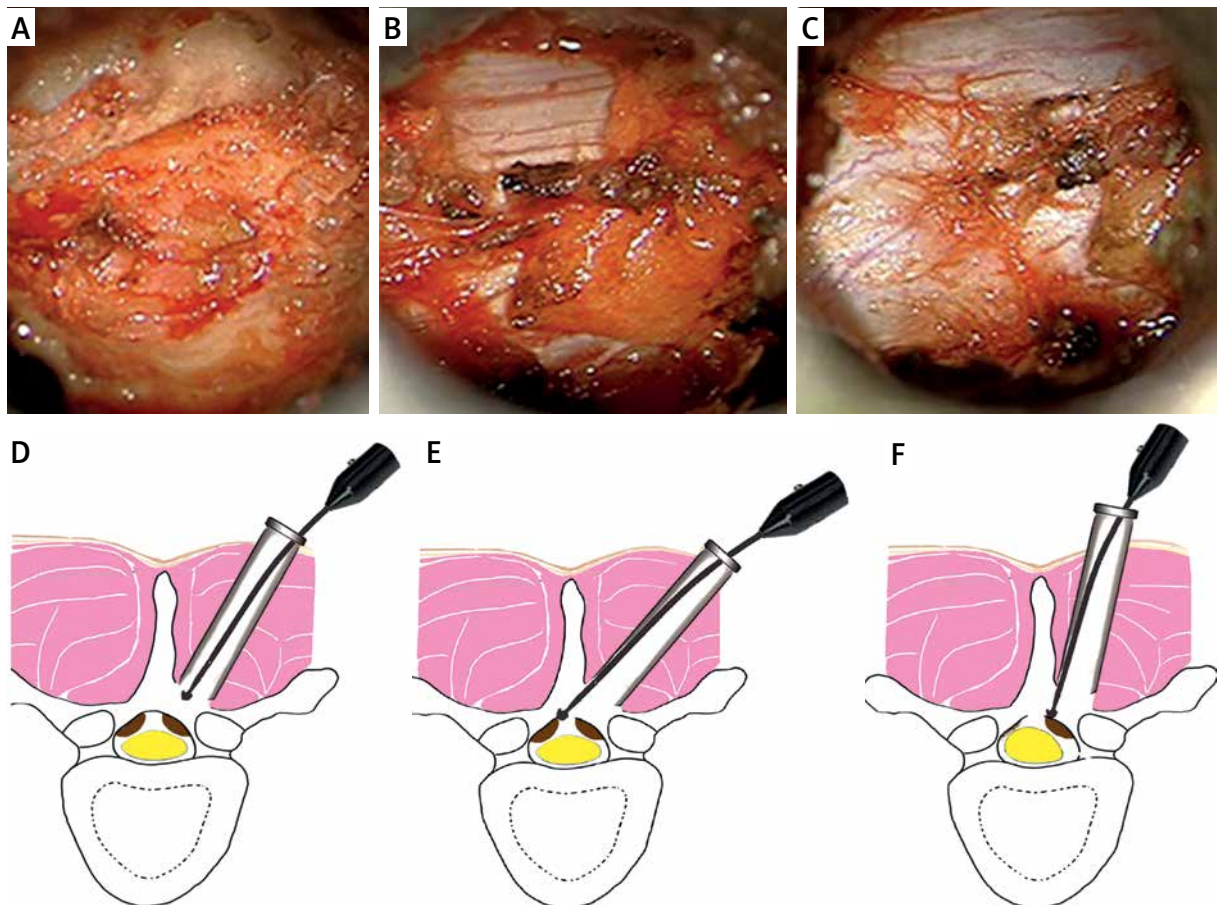
The 13 patients were treated by percutaneous decompression and nerve root decompression. Patients were monitored under general anesthesia for

prone positioning, neurophysiological features, motor evoked potentials (MEP), somatosensory evoked potentials (SEP), and electromyogram (EMG) monitoring. The operation levels were confirmed under the monitor of a “C” arm X-ray machine and were

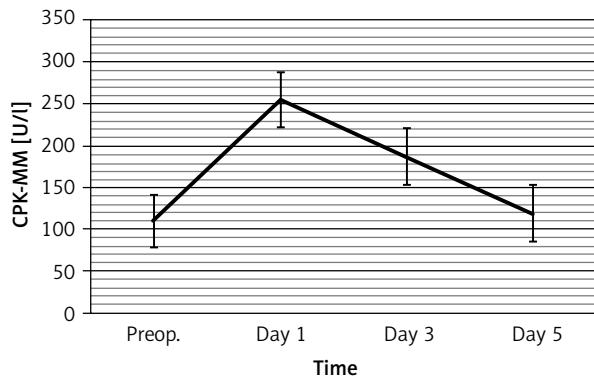
marked on the skin with ink. An 18-mm paramedian skin incision was usually sufficient for decompression, blunt separation of vertebral muscles, and insertion of a location pin to mark the preoperative planning center. An X-ray machine was used for confirmation, followed by insertion of an expansion tube along the guiding pin to separate the muscles. Finally, insertion of a homemade dilator was performed outside the expansion tube (Patent number: ZL201220747528.1).

First, the surgeon placed the outer tube on the surface of the lamina, once again using the X-ray machine to confirm the tube position. Grinding and removal of the lower part of the vertebral lamina and the base of the spinous process was then carefully initiated. Grinding of the calcified yellow ligament opposite the spinal canal was also performed,

leaving a thin layer of ossification tissue. Care was taken to reduce direct extrusion on the endorachis during the process of grinding. To gently provoke the thin ossification tissue with a hook aneurysm needle or micro stripping ion, the dural sac requires a space to release pressure after the decompression of the contralateral ossification lesion. Next, adjustment of the channel direction was applied to the ipsilateral side of the ossification lesion using the same method to remove the yellow ligament. Fully exposing the rear side of the dural sac and bilateral lateral recess and exploring the bilateral nerve root canals, nerve root activity was inspected. Finally, the surrounding fat layer was used to cover the exposed endorachis. To stop bleeding, the channel was carefully withdrawn and the incision was sewed up layer by layer (Figure 1).



**Figure 1.** Intraoperative views (A–C) and illustrations of the technique (D–F) (patient 10). Laminotomy was performed and the ossified bilateral yellow ligament was viewed through the channel (A, D). Removal of the contralateral (left side) ligamentum flavum (B, E); the position of the channel was adjusted and the ipsilateral (right side) side of the ossified ligamentum flavum was removed (C, F)



**Figure 2.** Temporal changes in serum creatine phosphokinase MM isoenzyme (CPK-MM) pre-operatively and at day 1, day 3, and day 5 post-operatively

**Postoperative evaluation**

All 13 patients were followed closely postoperatively. The patients’ neurological status was assessed using the modified Japanese Orthopedic Association (JOA) scale of myelopathy both preoperatively and at the end point of follow-up (Table I). The maximum score of 11 indicated normal function, and the recovery rate (RR) was calculated as follows: (postoperative JOA score – preoperative JOA score)/(11 – preoperative JOA score) × 100 [20]. The outcomes were ranked based on the RR as good (> 50%), fair (10–49%), unchanged (0–9%), or worse (< 0%).

The operation time, bleeding volume and post-operative hospital stay lengths were recorded. Additionally, creatine phosphokinase MM isoenzyme (CPK-MM) levels 1 day before the operation and 1, 3 and 5 days after the operation were examined. Computed tomography three dimensional reconstruction was additionally performed 1 week after

the operation and a thoracic MRI scan was performed at 1 week and 6 months after the operation.

**Statistical analysis**

Data are expressed as mean ± standard error of the mean. A paired *t*-test was performed using the Statistical Package for the Social Sciences version 13.0 (SPSS, Chicago, IL, USA). *P*-values < 0.05 were considered statistically significant.

**Results**

The mean duration of symptoms was defined as the duration between the initial onset of symptoms and surgery, the average being 4.31 ± 1.97 months. Microsurgical decompression of TOLF was performed in all patients. Mean operation time was 98.23 ± 19.10 min (range: 80–134 min) and mean bleeding volume was 19.77 ± 5.97 ml (range: 12–34 ml). There were no complications reported after surgery for any patient.

Serum CPK-MM levels were measured in the pre-operative period and at different postoperative periods. The mean CPK-MM was 111.38 ± 47.21 IU/l pre-operatively and 253.38 ± 91.65 IU/l, 186.69 ± 72.39 IU/l, and 118.08 ± 43.115 IU/l (Figure 2) at 1, 3, and 5 days postoperative, respectively. There was a significant increase 1 and 3 days postoperatively compared to preoperative levels (*p* < 0.05). However, there was no significant difference between the preoperative CPK-MM level by the 5<sup>th</sup> postoperative day (*p* > 0.05).

In the present study, the patients were followed post-operatively between 6 and 23 months, with a mean follow-up of 13.3 months and a median of 12 months. The mean preoperative JOA score was 4.15 ± 1.67, which was improved to 6.15 ± 0.69, 6.38 ± 0.96, and 6.85 ± 0.90 at 1, 3, and 6 months post-operatively, respectively. The post-operative JOA score in-

**Table II.** JOA score for 13 patients with TOLF

Stage	JOA score (mean ± SEM)	Outcome, number of patients					Combined good, excellent and fair (%)
		Excellent (75–100%)	Good (50–74%)	Fair (25–49%)	Poor (0–24%)	Worse (< 0%)	
Preop.	4.15 ± 1.67	/	/	/	/	/	/
1 month postop.	6.15 ± 0.69	0	0	9	4	0	69.23
3 months postop.	6.38 ± 0.96	0	2	8	3	0	76.92
6 months postop.	6.85 ± 0.90	0	3	9	1	0	92.31

JOA – Japanese Orthopedic Association, *preop.* – preoperatively, *postop.* – postoperatively, SEM – standard error of the mean.

licated significant improvement after the operation compared to preoperative levels ( $p < 0.05$ , Table II). The mean JOA score was  $7.54 \pm 1.13$  at the final follow-up, yielding a mean RR of  $49.10 \pm 15.71\%$ . The score was good in 7 patients, fair in 5 patients, and poor in 1 patient, indicating significant improvement by the final follow-up examination ( $p < 0.05$ ). All of the patients showed improved symptoms of varying degrees. Histopathologic studies of operative specimens revealed that all patients experienced TOLF and additionally that the ligament flavum had been replaced by mature lamellar bone (Photo 3).

## Discussion

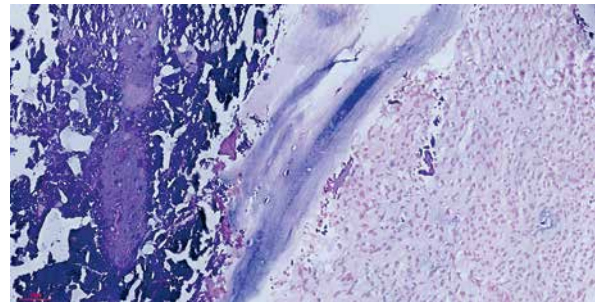
### Preoperative planning necessity

A 3D printing model was used as an assistive tool for preoperative patient communication and surgical planning in this study [21]. This tool allowed us to get a positive response from the patients and their families, customize models to help patients better understand their disease, and understand the purpose and necessity of the surgery. The use of the model made it possible for patients to know more about what was likely to happen during the course of the operation, allowing patients to feel more assured and minimizing fears.

Simultaneously, these tools allowed for the accurate planning of the operative approach by computer. They played an important role in guiding the actual operation. Previous studies have reported that the 3D printing model is helpful to the surgeon's operational training [22]. Whether these positive findings affect the operation time, and whether they are helpful for the recovery after surgery would require a larger, formal assessment of validated outcome measures.

### Surgical advantages

The traditional surgical methods of TOLF include laminoplasty, laminectomy, fenestration, etc. While laminoplasty retains most of the spine structure, it is often associated with ossification, spinal kyphosis, muscle atrophy and other complications [23]. The above methods have demonstrated an influence on the stability of the spine and often needs after decompression. Some procedures, such as muscle-preserving interlaminar decompression (MILD) [24] have



**Photo 3.** Photomicrography demonstrated the typical histopathology of OLF. Histological sections showed mature lamellar bone and bone islands developed in the ligament flavum (HE 200)

been developed to preserve the paraspinal muscles and the facet joint. However, the integrity of the facet joint can be preserved only when spinous process injury occurs while decompressing the spinal canal from the midline. Some studies have reported that the facet joints and the spinous processes play important roles in stabilizing the spine in some cases [25]. Thus, here we used an existing unilateral-approach decompression technique to preserve the facet joint and the spinous process.

Muscle injury during spine surgery is directly related to the retraction pressure, time, and extent of exposure [26, 27]. CPK-MM, a muscle-originating enzyme, exhibits high serum concentrations during muscle injury in spinal surgery and is usually used for muscle injury evaluation at the early postoperative stage [28]. In this study, a statistically significant difference was found in the level of CPK-MM between the first postoperative day and preoperative levels. Though CPK-MM levels temporarily increased on the first day after surgery, they declined rapidly three days after surgery and returned to normal levels 7 days after surgery. This demonstrated that the technique using a tubular retractor is a minimally invasive technique and that injury to paraspinal muscle is minor. In the present case, the paraspinal muscles exhibited no evidence of injury according to MRI images taken 6 months after surgery. The above results show that this technique can significantly contribute to the reduction of muscle injury during the early postoperative period, though there is still a need for a long-term follow-up in order to detect chronic changes in paraspinal muscle.

All patients received minimally invasive surgery for resection of ossification of the ligamentum flavum via expandable tubular retractor system with nerve elec-



trophysiological monitoring and slender high speed diamond grinding head technology. Previously, the use of intraoperative sequential nerve electrophysiological monitoring has been reported to aid in the avoidance of serious spinal injury [29–31]. Anatomically, the spinal canal in the thoracic region is smaller than in the lumbar areas, which allows less room for operating [32]. Consequently, surgery is harder to perform in the thoracic spinal canal than in the lumbar region [33]. The use of a slender high-speed diamond grinding head is thus recommended in the surgical procedure, which decreases the risk of spinal cord and blood supply injury from a Kerrison rongeur. So far, several case series have been reported regarding laminectomy outcomes of TOLF [34–38]. Most of the studies revealed the procedural outcome as having a mean RR in the range of 46–63%. Like other studies, an improved JOA score was observed in all of these patients, with the mean RR of 49.10% at the final follow-up, which was similar to those observed in prior reports. Therefore, minimally invasive surgery with the expandable tubular retractor system provided satisfactory neurological improvement in patients with TOLF. Additionally, no obvious instability or kyphotic deformity was seen at the end of follow-up. These results may be related to the operative planning strategies combined with the safe decompression technique.

## Conclusions

Unilateral approach bilateral decompression using the percutaneous tubular retractor system in the treatment of TOLF is an extremely effective technique. The integrity of the facet joints and spinous processes is preserved after spinal decompression using this method. Additionally, the technique was beneficial to the segmental stability at the operated level in the long term. Injury from the operation was further minimized, likely due to preoperative planning strategies, ultimately reducing blood loss and reducing medical costs for patients.

## Acknowledgments

The authors would like to thank Clarity Manuscript Consultant LLC. (Indianapolis) for their language editing.

## Conflict of interest

The authors declare no conflict of interest.

## References

1. Isaacs RE, Podichetty VK, Santiago P, et al. Minimally invasive microendoscopy-assisted transforaminal lumbar interbody fusion with instrumentation. *J Neurosurg Spine* 2005; 3: 98-105.
2. Lawton CD, Smith ZA, Barnawi A, et al. The surgical technique of minimally invasive transforaminal lumbar interbody fusion. *J Neurosurg Sci* 2011; 55: 259-64.
3. Ogden AT, Bresnahan L, Smith JS, et al. Biomechanical comparison of traditional and minimally invasive intradural tumor exposures using finite element analysis. *Clin Biomech* 2009; 24: 143-7.
4. Palmer S, Turner R, Palmer R. Bilateral decompression of lumbar spinal stenosis involving a unilateral approach with the microscope and tubular retractor system. *J Neurosurg* 2002; 97: 213-7.
5. Li KK, Chung OM, Chang YP, et al. Myelopathy caused by ossification of ligamentum flavum. *Spine* 2002; 27: E308-12.
6. Okada K, Oka S, Tohge K, et al. Thoracic myelopathy caused by ossification of the ligamentum flavum. Clinicopathologic study and surgical treatment. *Spine* 1991; 16: 280-7.
7. Ikuta K, Tarukado K, Senba H, et al. Decompression procedure using a microendoscopic technique for thoracic myelopathy caused by ossification of the ligamentum flavum. *Minim Invasive Neurosurg* 2011; 54: 271-3.
8. Fessler RG. Minimally invasive spine surgery. *Neurosurgery* 2002; 51: 3-4.
9. Khoo LT, Fessler RG. Microendoscopic decompressive laminotomy for the treatment of lumbar stenosis. *Neurosurgery* 2002; 51 (5 Suppl): S146-54.
10. Khoo LT, Smith ZA, Asgarzadie F, et al. Minimally invasive extracavitary approach for thoracic discectomy and interbody fusion: 1-year clinical and radiographic outcomes compared with a cohort of traditional anterior transthoracic approaches. *J Neurosurg Spine* 2011; 14: 250-60.
11. Lawton C, Smith ZA, Barnawi A, et al. The surgical technique of minimally invasive transforaminal lumbar interbody fusion. *J Neurosurg Sci* 2011; 55: 259-64.
12. Palmer S, Davison L. Minimally invasive surgical treatment of lumbar spinal stenosis: two-year follow-up in 54 patients. *Surg Neurol Int* 2012; 3: 41.
13. Ikuta K, Arima J, Tanaka T, et al. Short-term results of microendoscopic posterior decompression for lumbar spinal stenosis. Technical note. *J Neurosurg Spine* 2005; 2: 624-33.
14. Palmer S, Turner R, Palmer R. Bilateral decompression of lumbar spinal stenosis involving a unilateral approach with microscope and tubular retractor system. *J Neurosurg* 2002; 97: 213-7.
15. Chen CM, Cai GF, Wang R, et al. Microsurgical resection of lumbar intraspinal tumors through paraspinous approach using percutaneous tubular retractor system. *Zhonghua Yi Xue Za Zhi* 2015; 95: 969-72.
16. Chen CM, Cai GF, Zhang WQ, et al. Comparison of microinvasive effect between paraspinous tubular retractor system and posterior median approach for treatment of lumbar intervertebral disc herniation. *Chin J Neurosurg* 2012; 30: 677-81.
17. Jones N. Science in three dimensions: the print revolution. *Nature* 2012; 487: 22-3.

18. Cohen A, Laviv A, Berman P, et al. Mandibular reconstruction using stereolithographic 3-dimensional printing modeling technology. *Oral Surg Oral Med Oral Pathol Oral Radiol Endod* 2009; 108: 661-6.
19. Duncan JM, Daurka J, Akhtar K. Use of 3D printing in orthopaedic surgery. *BMJ* 2014; 348: g2963.
20. Hirabayashi K, Miyakawa J, Satomi K, et al. Operative results and postoperative progression of ossification among patients with ossification of cervical posterior longitudinal ligament. *Spine* 1981; 6: 354-64.
21. Liew Y, Beveridge E, Demetriades AK, et al. 3D printing of patient-specific anatomy: a tool to improve patient consent and enhance imaging interpretation by trainees. *Br J Neurosurg* 2015; 29: 712-4.
22. Gottschalk MB, Yoon ST, Park DK, et al. Surgical training using three-dimensional simulation in placement of cervical lateral mass screws: a blinded randomized control trial. *Spine J* 2015; 15: 168-75.
23. Perez-Cruet MJ, Foley KT, Isaacs RE, et al. Microendoscopic lumbar discectomy: technical note. *Neurosurgery* 2002; 51: 129-36.
24. Hatta Y, Shiraishi T, Sakamoto A, et al. Muscle-preserving interlaminar decompression for the lumbar spine: a minimally invasive new procedure for lumbar spinal canal stenosis. *Spine (Phila Pa 1976)* 2009; 34: 276-80.
25. Murata H, Hachiya Y, Muramatsu K, Onitake H. Unilateral microscopic decompression for spinal canal stenosis in upper lumbar lesions. *Surgical Technique for Spine and Spinal Nerves* 2008; 10: 133-7.
26. Kawaguchi Y, Matsui H, Tsuji H. Back muscle injury after posterior lumbar spine surgery. A histologic and enzymatic analysis. *Spine (Phila Pa 1976)* 1996; 21: 941-4.
27. Kawaguchi Y, Matsui H, Tsuji H. Changes in serum creatine phosphokinase MM isoenzyme after lumbar spine surgery. *Spine (Phila Pa 1976)* 1997; 22: 1018-23.
28. Kim KT, Lee SH, Suk KS, et al. The quantitative analysis of tissue injury markers after mini-open lumbar fusion. *Spine (Phila Pa 1976)* 2006; 31: 712-6.
29. Pastorelli F, Di Silvestre M, Plasmati R, et al. The prevention of neural complications in the surgical treatment of scoliosis: the role of the neurophysiological intraoperative monitoring. *Eur Spine J* 2011; 20: 105-14.
30. Yang J, Huang Z, Shu H, et al. Improving successful rate of transcranial electrical motor-evoked potentials monitoring during spinal surgery in young children. *Eur Spine J* 2012; 21: 980-4.
31. Verla T, Fridley JS, Khan AB, et al. Neuromonitoring for intramedullary spinal cord tumor surgery. *World Neurosurg* 2016; 95: 108-16.
32. Zhong ZM, Wu Q, Meng TT, et al. Clinical outcomes after decompressive laminectomy for symptomatic ossification of ligamentum flavum at the thoracic spine. *J Clin Neurosci* 2016; 28: 77-81.
33. Baba S, Oshima Y, Iwahori T, et al. Microendoscopic posterior decompression for the treatment of thoracic myelopathy caused by ossification of the ligamentum flavum: a technical report. *Eur Spine J* 2016; 25: 1912-9.
34. Gao R, Yuan W, Yang L, et al. Clinical features and surgical outcomes of patients with thoracic myelopathy caused by multilevel ossification of the ligamentum flavum. *Spine J* 2013; 13: 1032-8.
35. Yu S, Wu D, Li F, et al. Surgical results and prognostic factors for thoracic myelopathy caused by ossification of ligamentum flavum: posterior surgery by laminectomy. *Acta Neurochir (Wien)* 2013; 155: 1169-77.
36. Li Z, Ren D, Zhao Y, et al. Clinical characteristics and surgical outcome of thoracic myelopathy caused by ossification of the ligamentum flavum: a retrospective analysis of 85 cases. *Spinal Cord* 2016; 54: 188-96.
37. Chen XQ, Yang HL, Wang GL, et al. Surgery for thoracic myelopathy caused by ossification of the ligamentum flavum. *J Clin Neurosci* 2009; 16: 1316-20.
38. Hirabayashi H, Ebara S, Takahashi J, et al. Surgery for thoracic myelopathy caused by ossification of the ligamentum flavum. *Surg Neurol* 2008; 69: 114-6.

**Received:** 13.09.2016, **accepted:** 8.02.2017.