

Safety and efficacy of oesophageal stenting with simultaneous percutaneous endoscopic gastrostomy as a supplementary feeding route in unresectable proximal oesophageal cancer

Janusz R. Włodarczyk, Jarosław Kuźdżał

Department of Thoracic and Surgical Oncology, Jagiellonian University Medical College, John Paul II Hospital, Krakow, Poland

Videosurgery Miniinv 2018; 13 (2): 176–183
DOI: <https://doi.org/10.5114/wiitm.2018.73361>

Abstract

Introduction: Proximally located oesophageal cancer poses an especially difficult problem in terms of restoration of patency and the stenting procedure. Supplementary percutaneous endoscopic gastrostomy (PEG) may be useful in these patients.

Aim: To assess the safety of the stenting procedure in the proximal oesophagus in patients with unresectable upper oesophageal cancer, performed simultaneously with PEG insertion.

Material and methods: Patients with obstructing upper oesophageal tumours were scheduled for an oesophageal stenting procedure and simultaneous PEG insertion. Degree of dysphagia, body weight loss, daily energy requirement, body mass index and performance status before and after the stenting procedure as well as complications were assessed.

Results: Forty-five patients aged 19–88 years were included in the study. Six of them had a fistula to the trachea and underwent stenting of the oesophagus or both the oesophagus and the airway. The technical success rate was 100%. Following the procedure all patients were able to swallow fluids and semi-liquids, and PEG was used as the primary feeding route. Body mass index increased from 20.4 to 21.1 ($p = 0.0001$), body weight gain improved from -10.1 to $+2.0$ kg and metabolic requirements improved ($p = 0.0001$). Also, the Karnofsky score improved significantly (56.7 vs. 65.1 , $p = 0.0001$). Mean survival time was 133 days (range: 36–378).

Conclusions: Stenting of the proximal oesophagus with simultaneous PEG is a safe procedure, allowing the patients to resume oral intake of liquids whilst improving nutritional status and general performance, with an acceptable rate of complications.

Key words: oesophageal cancer, stenting, percutaneous endoscopic gastrostomy, fistula.

Introduction

Proximal oesophageal cancer occurs relatively rarely, constituting approximately 10% of oesophageal cancers. In the case of cancer located in the cervical oesophagus, the recommended treatment is radical chemo-radiation therapy, whereas surgical treatment, i.e., free intestinal flap, free myocutaneous flap or gastric conduit, is rarely indicated [1–3].

In the case of relapse, or in patients who are not candidates for curative-intent therapy, palliative treatment is usually indicated. The aims of the palliative therapy are: restoration of patency of the oesophagus to enable, at least partial, oral feeding, and improvement of nutritional status.

The most often used methods of palliative treatment include oesophageal stenting, gastrostomy or

Address for correspondence

Janusz Włodarczyk MD, PhD, Department of Thoracic Surgery, John Paul II Hospital, 80 Pradnicka St, 31-202 Krakow, Poland, phone: +48 691 893 853, fax: +48 12 614 34 31, e-mail: jrwloдарczyk@gmail.com

feeding jejunostomy, chemo- and/or radiation therapy, and laser or photodynamic intraluminal therapy. The use of covered self-expandable metallic stents (SEMS) in the upper oesophagus is controversial, due to the relatively frequent intolerable discomfort in the neck, globus sensation, impairment of the swallowing act, chest pain, and complications such as perforation or migration. New, low-profile stents are reportedly better tolerated [4, 5].

Due to the development of endoscopic surgery, technological progress in the available oesophageal and airway stents as well as percutaneous endoscopic gastrostomy (PEG) technique, together with the growing experience of medical centres performing such procedures, it is possible to expand the range of palliative treatment in this group of patients.

Aim

In the present study, we assessed the safety and effectiveness of the stenting procedure in the proximal oesophagus in patients with unresectable upper oesophageal cancer, performed simultaneously with PEG insertion. The aims of the palliative therapy are restoration of patency of the oesophagus to enable, at least partial, oral feeding, and improvement of nutritional status and quality of life.

Material and methods

The study included data for a consecutive group of patients treated for unresectable upper oesophageal cancer with or without oesophago-airway fistula (OAF) between 2003 and 2016. Institutional review board approval was waived due to the retrospective character of the study. For the same reason, patients' informed consent was not obtained.

The pre-procedure work-up in all patients included:

- endoscopic examination – oesophagoscopy with the assessment of oesophageal patency and the length of the involved segment, and bronchoscopy;
- assessment of the degree of dysphagia;
- assessment of body mass index (BMI), body weight loss, and basal metabolic rate (BMR) requirement calculated using the Harris-Benedict equation: for men $BMR = 88.362 + (13.397 \times \text{weight [kg]} + (4.799 \times \text{height [cm]} - (5.677 \times \text{age [years]}))$, and for women $BMR = 447.593 + (9.247 \times \text{weight [kg]} + (3.098 \times \text{height [cm]} - (4.330 \times \text{age [years]}))$ [6],
- in patients with OAF the degree of dyspnoea was additionally assessed (Table I).

Mean degree of dysphagia before and after the stenting procedure was assessed according to a four-grade scale [7]: 0 – no dysphagia; 1 – able to swallow semi-liquid food; 2 – able to swallow liquids; 3 – unable to swallow liquids and saliva.

Degree of stenosis of bronchial lumen and the degree of dyspnoea were assessed according to the original, four-grade scale [8]: 0 – stenosis of the bronchial lumen < 30%, no dyspnoea; 1 – stenosis of the bronchial lumen 30–50%, dyspnoea on exercise; 2 – stenosis of the bronchial lumen 50–70%, dyspnoea on short-distance walk; 3 – stenosis of the bronchial lumen > 70%, dyspnoea on rest.

Patients with oesophageal fistula were classified according to the original classification depending on the fistula location [8]: type I – oesophageal-mediastinal fistula, without penetration to the bronchial tree; type II – oesophageal fistula penetrating to the trachea; type III – oesophageal fistula penetrating to the carina and/or main bronchus/bronchi.

Patients' performance status before and after stenting was assessed based on the Karnofsky score [9]. Patients whose performance was assessed below 40 on the Karnofsky scale were excluded from the study group.

Qualification criteria for oesophageal stenting and airway stenting were as follows:

1. For oesophageal stenting:
 - upper oesophageal tumour;
 - endoscopically confirmed OAF.
2. For double stenting:
 - airway stenosis of 2nd–3rd degree or fistula not covered by the oesophageal SEMS.

Intervention

Oesophageal stenting was conducted under general anaesthesia. The location of stenosis and the distance from the upper oesophageal sphincter were endoscopically identified and then the dilatation was performed with Savary-Gilliard dilators, up to the size of 10–14 Fr. After the dilatation, the length of the involved segment was assessed using a small-diameter endoscope. Partially covered SEMS 7–12 cm long and with diameter of 18 mm (Ultraflex Boston Scientific, Natick, USA) were used. A guide-wire was inserted and the oesophageal stent was introduced over it. Generally, if the tumour was located below the upper oesophageal sphincter, the SEMS was positioned with its proximal end at least

Table I. Clinical and demographic data of the patients

Measurement	All patients	Patients without fistula	Patients with fistula
Number of patients	45	39	6
Age, mean (range)	60.3 (19–88)	63.8 (21–88)	58.7 (19–82)
Males/females	38/7	34/5	4/2
Type of cancer:			
SCC	44	39	5
SCEC	1		1
Mean length (range) of the involved oesophageal segment [cm]	5.8 (3–7)	5.57 (4–7)	5.9 (3–7)
Location of tracheal stricture in the airway > 30%	4	1	3
Location of tracheal stricture in the airway < 30%	21	20	1
Type of fistula:			
I	2		2
II	4		4
Cause of death:	45	39	6
Cachexia	36	36	
Dyspnoea	6	3	3
Other	3	6	3
Mean survival time (range) [days]		133 (range: 36–378)	73.4 (range: 43–154)
Adjuvant therapy:	32	28	4
Cht	14	16	1
Cht + Rth	18	12	3

Cht – chemotherapy, Cht + Rth – chemo-radiotherapy, SCC – squamous cell carcinoma, SCEC – small-cell oesophageal cancer.

2 cm below the sphincter. However, in patients in whom the tumour involved the sphincter, the stent was deployed with its proximal end slightly below the proximal margin of the tumour. In patients with OAF, the SEMS was positioned to cover 2–4 cm of the oesophageal wall above and below the fistula. Next, the stent location was checked endoscopically. If necessary, stent reposition was performed or an additional stent was inserted.

A percutaneous endoscopic gastrostomy tube was inserted using the standard ‘pull technique’ [10].

Airway stenting, if indicated, was performed during the same general anaesthesia. Routinely, airway stenting was performed first to avoid its potentially fatal compression by the expanding oesophageal stent. Prior to implantation of the stent, airway patency was restored mechanically using rigid bronchoscopes (Karl Storz GmbH, Tuttlingen, Germany)

no. 6.5, 7.5 and 8.5, or using argon plasma coagulation (APC Covidien, Minneapolis, USA) and laser (MY 40 1.3, KLS Martin GmbH & Co. KG, Freiburg, Germany) [11]. Partially covered SEMS (Ultraflex, Boston Scientific, Natick, MA, USA) were implanted under endoscopic control [12].

Follow-up

Patients received follow-up examinations 1 day after surgery, and every 30 days thereafter. When necessary, the follow-up examinations were conducted by telephone. Patients underwent the following assessments: chest X-ray, esophagoscopy, bronchoscopy, and computed tomography (CT). The follow-up examinations determined the patient’s general condition, quality of life, dyspnoea (assessed on a breath scale), and difficulties in swallowing.

Statistical analysis

All statistical analyses were performed with the Statistica 10 PL software package (StatSoft, USA). The following tests were used: Gehan-Wilcoxon, and Kruskal-Wallis χ^2 test. The dependent variable regression test was used to analyse data collected before and after surgery. The analyses included survival, dysphagia, assessment of BMI, body weight loss, and basal metabolic rate requirement, quality of life (according to the Karnofsky scale), the influence of adjuvant therapy (chemotherapy and/or radiotherapy). *P*-values < 0.05 were considered statistically significant.

Results

Patient characteristics

There were 45 patients, 38 (84.4%) males, mean age 60.3 years (range: 19–88), who underwent a simultaneous stenting procedure and PEG. Forty-four (97.8%) (84.4%) patients had squamous-cell oesophageal cancer, and 1 (2.2%) had small-cell oesophageal cancer.

In 35 (77.7%) patients the proximal margin of the tumour was located 18–21 cm from the incisors and in 10 (22.3%) patients it was located 22–24 cm from the incisors. In 6 (13.3%) patients OAF was present: in 2 (4.4%) patients type I, in 4 (8.8%) patients type II. In 1 (2.2%) patient double stenting was performed due to the tumour compressing the trachea. In 2 (4.4%) patients complete sealing of the OAF by the oesophageal SEMS was achieved, and in 3 (6.6%) patients with OAF, double stenting of the oesophagus and trachea using SEMS was conducted.

Two (4.4%) patients had a history of surgical procedures (cholecystectomy) within the upper abdomen. In 33 (73.3.8%) patients the PEG catheter was inserted through the stent, and in 12 (26.7%) patients before stent implantation (*p* = 0.021).

Quality of life

The restoration of oesophageal patency was achieved in all the patients after the stenting procedure. The degree of dysphagia improved significantly (2.9 vs. 1.0, *p* = 0.0001) (Figure 1). The mean body weight loss within the last 6 months before the procedure was –10.1 kg and after the stenting it improved to +2.0 kg (*p* = 0.0001) (Figure 2). This corresponded with a significant increase of mean BMI (20.4 vs. 21.1, *p* = 0.0001) (Figure 3). Mean loss in daily basal metabolic rate requirement before the stenting procedure was 8.9%. After the stenting procedure all patients were able to fully cover their daily basal metabolic requirement. Three of them (6.6%) reported body weight loss (2, 3, 7 kg), in 14 (31.1%) patients body weight remained stable, and in 28 (62.2%) patients body weight gain was observed from 2 to 9 kg, which was statistically significant (*p* = 0.0001) (Figure 4).

Statistically significant improvement in the performance status was also observed. The mean Karnofsky score improved from 56.7 to 65.1 (*p* = 0.0001) (Figure 5).

After the stenting 33 (73.3%) patients were able to swallow semi-liquid and liquid food and 11 (24.4%) liquid food.

Thirty-two (71.1%) patients received adjuvant chemo- and/or radiation therapy (Table I). These

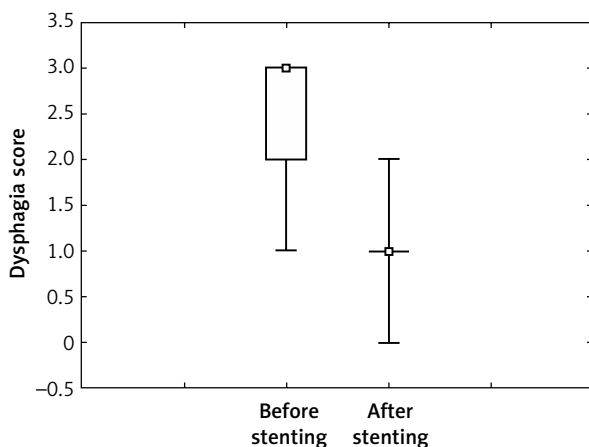


Figure 1. Dysphagia before and after stenting

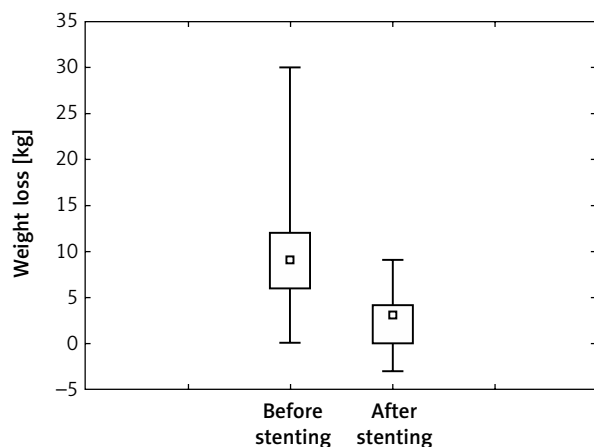


Figure 2. Weight loss before and after stenting

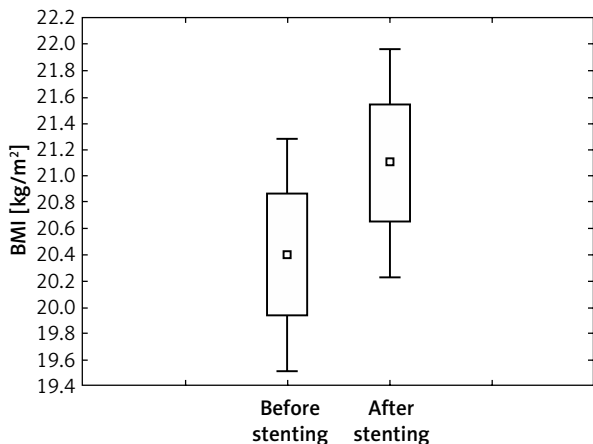


Figure 3. Gain of BMI in patients before and after stenting

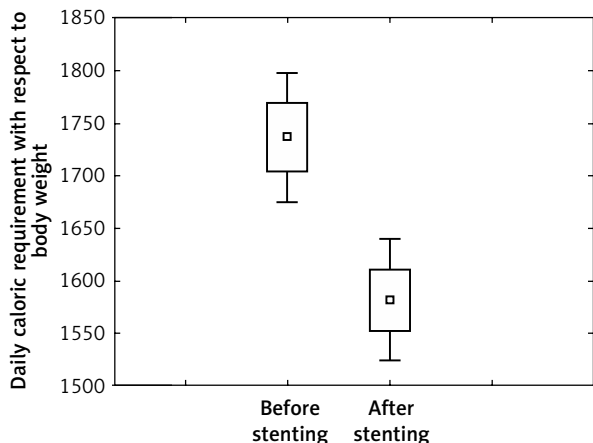


Figure 4. Energy requirement before and after stenting

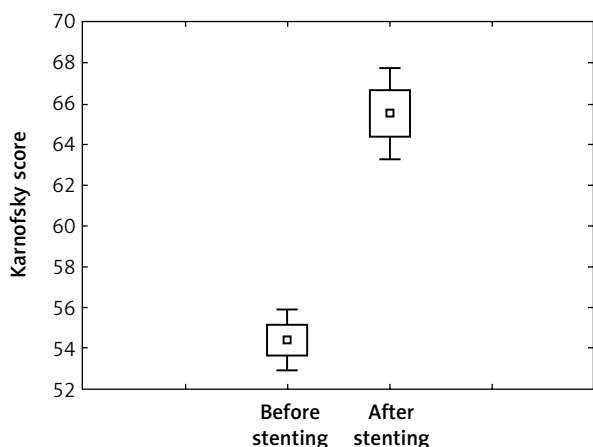


Figure 5. Karnofsky score before and after stenting

treatments had no effects on re-interventions or patient survival ($p = 0.36$).

Mean survival time was 133 days (range: 36–378) and for patients with OAF 73.4 days (range: 43–154).

Complications

Most complications of oesophageal stenting and PEG insertion were mild. Twenty-five (55.5%) patients had discomfort in the neck, 17 (37.7%) had the feeling of a foreign body in the oesophagus, in 2 (4.4%) patients repeat restoration of patency was necessary due to the overgrowth of granulation tissue, in 1 (2.2%) patient a re-stenting procedure was performed by placing another stent into the first one, and in 1 (2.2%) case the stent was removed and the stenting procedure was repeated.

Buried bumper syndrome occurred in 2 (2.4%) patients following PEG insertion; in 1 (2.2%) of them endoscopic reposition was performed and the patients were able to resume feeding via PEG within 10 days, whereas in 1 (2.2%) patient the PEG was removed and re-inserted 21 days later. In 3 (6.6%) patients soft tissue infection occurred due to a leak around the PEG tube, in 1 (2.2%) patient the PEG was removed, and in 2 (4.4%) patients infection subsided following temporary discontinuation of feeding via PEG and antibiotic therapy.

Severe postoperative complications occurred in 1 (2.2%) patient due to colonic perforation during PEG insertion. The patient had undergone left-sided hemicolectomy in the past. Laparotomy was performed, the perforation was sutured and the gastrostomy tube was inserted. The patient resumed oral nutrition and was discharged home.

Discussion

Patients with malignant obstruction of the upper oesophagus are characterized by higher incidence of vocal cords paralysis, risk of OAF formation, rapid body weight loss, and choking with saliva and food that lead to recurrent refractory pneumonia. These factors are associated with poor quality of life and progressive disability.

Traditional palliative treatment has been limited to gastrostomy or jejunostomy and adjuvant radio-chemotherapy in fit patients. These measures, however, do not solve the problems of dysphagia and aspiration of food and saliva to the airway. Also,

psychological aspects should be noted, i.e. increasing anxiety and depression.

Restoration of the patency and stenting in the upper one-third of the oesophagus is technically more challenging than in its thoracic part, due to the anatomical relationships. These difficulties are associated with limited ability of insufflation, high resting pressure within the lower pharynx and upper oesophageal sphincter as well as close vicinity of the lower larynx and trachea. The rate of improper stent implantation in the upper oesophagus is reported to be 7–23% [13].

An additional problem is the short margin (or no margin at all) between the upper oesophageal sphincter and the tumour. Implantation of SEMS at the level of this sphincter usually leads to considerable discomfort and impairment of the swallowing act. Therefore, the result of restoration of patency and the stenting procedure is uncertain and does not guarantee full comfort of oral nutrition and a sufficient supply of nutrients [14].

Management of unresectable oesophageal cancer usually requires oesophageal stenting, but can also require simultaneous stenting of the airway if tracheal stenosis or OAF is present. Verschuur *et al.* used covered SEMS and reported 1 case of tracheal compression that required tracheal stenting, among 104 treated patients. In our study, tracheal compression that required stenting occurred in 1 of 45 patients [3, 15, 16].

Formation of an OAF is a bad prognostic factor for survival. It is estimated that oesophageal fistulas occur in 0.9–18% of patients with oesophageal cancer as a result of direct neoplastic infiltration and necrosis between the oesophagus and bronchial tree or mediastinum. According to most authors, covered SEMS are recommended for oesophageal stenting and covered SEMS or silicone Y-stents are recommended for stenting of the bronchial tree [17–20].

Despite the restrictions described above, effectiveness of stenting procedures in malignant proximal oesophageal stenoses is in the range 87–100% in experienced centres. In our group, satisfactory oesophageal patency was obtained in all the patients and dysphagia subsided, enabling oral nutrition; in the literature this rate ranges between 73% and 100% [21, 22].

Despite restoration of oesophageal patency, full coverage of nutritional requirements is not always

possible. During the early post-stenting period patients report discomfort in the neck, particularly on swallowing, and the feeling of a foreign body in the oesophagus. These symptoms, impairing patients' quality of life, can be temporary, but remain in up to 30% of patients [23–26]. This problem can be, at least partially, overcome by creation of a supplementary route of enteral feeding.

Reportedly, the most frequent complication is late obstruction of the stent, caused by the overgrowth of granulation tissue, which can occur in up to 28% of patients in the case of partially covered stents and in 13% in the case of plastic stents [27, 28]. In our study the rate of late obstructions was 8.8%. In these patients stent removal or an additional telescopic stent-in-stent implantation is usually required, a procedure that is technically challenging. Another complication, which can occur early or late, is migration of the stent, which happens in 6–12% of patients. The stent can migrate towards the hypopharynx, leading to life-threatening dyspnoea, or distally [29]. In our group, similar as reported by Eleftheriadis *et al.* and Fujita *et al.*, migration was not observed [20, 23].

Generally, oesophageal stenting is a relatively safe procedure; however, according to some reports, the rate of complications can reach 34% with mortality of 0–5%. [27].

According to the available literature, for stenting of the upper oesophagus most authors use covered stents or self-expandable plastic stents (SEPS). In our institution, partially covered SEMS are used because their non-covered ends provide some protection from migration, even during pulling the bumper of the PEG catheter through the stent. Indeed, there was no stent migration in our group. An additional advantage is the technically simple, precise implantation under endoscopic control. If necessary, partially covered SEMS can be removed.

According to Mariette *et al.*, patients who receive < 75% of energy requirement are at risk of malnutrition, whereas patients whose supply is < 50% of their energy requirement should receive enteral nutrition [30]. Reportedly, 60–80% of patients with oesophageal cancer are malnourished [31–33]. Although restoration of oesophageal patency enables oral nutrition, it is often not sufficient in severely malnourished patients. The PEG insertion as an alternative method of nutrition is an effective way to provide adequate protein and

caloric supply. In our group, improvement of patients' metabolic condition was observed after PEG implantation (significant increase in BMI and body weight) with an acceptable rate of perioperative complications. Other authors also observed an improvement of patients' metabolic condition after routine nutrition via gastrostomy, often indicated in surgically treated patients with head and neck cancers [34]. In a prospective study Löser *et al.* observed that before the introduction of nutritional treatment via PEG, mean body weight loss was 11.35 kg, and after that it was reduced to 3.75 kg. This kind of nutrition also leads to an increase in caloric intake of approximately 30% compared to those receiving only oral nutrition, but can have no influence on the increase in fat free mass, skeletal mass or BMI [35–37].

In our study the PEG was inserted using the 'pull' technique described by Gauderer *et al.* [10]. Meticulous technique of PEG insertion is crucial for avoiding complications. Previous surgery in the upper abdomen is considered a relative contraindication, which is supported by our results. Among our patients, 4 patients had previous upper abdominal surgery, and one of the injuries to the colon occurred in this group. Some authors consider that the inadequate experience of the endoscopist performing the procedure is one of the risk factors [31, 38].

It is possible to insert the PEG after or before oesophageal stenting. It should be noted that the PEG catheter can be pulled through the stent only if the stent is fully expanded, which is not always possible to achieve. Also, if a low-profile SEMS (12 mm in diameter) is used, insertion of the PEG will not be possible thereafter. In the case of patients with stenosis located below the upper sphincter, pulling through the catheter is easier, because stent expansion is usually complete. Stent migration after pulling the PEG catheter was not observed in our group. Insertion of the PEG catheter through the stent is also suggested by some reports concerning the implantation of cancer cells along the PEG channel in the gastric wall and the abdominal wall. The risk of such implants is estimated to be approximately 1% [39, 40]. Moreover, the clinical relevance of such implants is uncertain because of the short life expectancy in this group of patients. The presence of cancer implants around the PEG was not observed in our group.

Conclusions

Stenting of the proximal oesophagus with simultaneous PEG is a relatively safe procedure. It allows the patients to resume oral intake of liquids. Supplementary feeding via the PEG tube allows for adequate coverage of nutritional requirements, improving nutritional status and general performance, with an acceptable rate of complications.

Conflict of interest

The authors declare no conflict of interest.

References

1. Bosetti C, Levi F, Ferlay J, et al. Trends in oesophageal cancer incidence and mortality in Europe. *Int J Cancer* 2008; 122: 1118-29.
2. Siegel R, Ma J, Zou Z, et al. Cancer statistics, 2014. *CA Cancer J Clin* 2014; 64: 9-29.
3. National Comprehensive Cancer Network. NCCN Guidelines Version 3.2015: Esophageal and Esophagogastric Junction Cancers. Available online: <http://www.nccn.org>
4. Verschuur EM, Kuipers EJ, Siersema PD. Esophageal stents for malignant strictures close to the upper esophageal sphincter. *Gastrointest Endosc* 2007; 66: 1082-90.
5. Hindy P, Hong J, Lam-Tsai Y, et al. A comprehensive review of esophageal stents. *Gastroenterol Hepatol* 2012; 8: 526-34.
6. Roza AM, Shizgal HM. The Harris Benedict equation reevaluated: resting energy requirements and the body cell mass. *Am J Clin Nutr* 1984; 40: 168-82.
7. Blazeby JM, Williams MH, Brookes ST, et al. Quality of life measurement in patients with oesophageal cancer. *Gut* 1995; 37: 505-8.
8. Włodarczyk J, Kuźdźał J. Double stenting for malignant oesophago-respiratory fistula. *Videosurgery Miniinv* 2016; 11: 214-21.
9. Karnofsky DA, Burchenal JH. The clinical evaluation of chemotherapeutic agents in cancer. In: *Evaluation of Chemioterapeutic Agents*. McLeod CM (ed.). Columbia Press; 1949; 196.
10. Gauderer M, Ponsky J, Izant R. Gastrostomy without laparotomy: a percutaneous endoscopic technique. *J Pediatr Surg* 1980; 15: 872-5.
11. Stephens KE, Wood DE. Bronchoscopic management of central airway obstruction. *J Thorac Cardiovasc Surg* 2000; 119: 289-95.
12. Lazaraki G, Katsinelos P, Nakos A, et al. Malignant esophageal dysphagia palliation using insertion of a covered Ultraflex stent without fluoroscopy: a prospective observational study. *Surg Endosc* 2011; 25: 628-35.
13. Spinelli P, Cerrai FG, Meroni E. Pharyngo-esophageal prostheses in malignancies of the cervical esophagus. *Endoscopy* 1991; 23: 213-4.
14. Verschuur EM, Homs MY, Steyerberg EW, et al. A new esophageal stent design (Niti-S stent) for the prevention of migration: a prospective study in 42 patients. *Gastrointest Endosc* 2006; 63: 134-40.

15. Verschuur EM, Steyerberg EW, Kuipers EJ. A new fully covered stent with antimigration properties for the palliation of malignant dysphagia: a prospective cohort study. *Gastrointest Endosc* 2010; 71: 600-5.
16. Paganin F, Schouler L, Cuissard L, et al. Airway and esophageal stenting in patients with advanced esophageal cancer and pulmonary involvement. *PLoS One* 2008; 29: 3:e3101.
17. Leclaire S, Antonietti M, Di Fiore F, et al. Double stenting of oesophagus and airways in palliative treatment of patients with oesophageal cancer is efficient but associated with a high morbidity. *Aliment Pharmacol Ther* 2007; 25: 955-63.
18. Spaander MC, Baron TH, Siersema PD, et al. Esophageal stenting for benign and malignant disease: European Society of Gastrointestinal Endoscopy (ESGE) Clinical Guideline. *Endoscopy* 2016; 48: 939-48.
19. Macdonald S, Edwards RD, Moss JG. Patient tolerance of cervical esophageal metallic stents. *J Vasc Interv Radiol* 2000; 11: 891-8.
20. Eleftheriadis E, Kotzampassi K. Endoprosthesis implantation at the pharyngo-esophageal level: problems, limitations and challenges. *World J Gastroenterol* 2006; 12: 2103-8.
21. Xianopoulos D, Bassioulas SP, Dimitroulopoulos D, et al. Self-expanding plastic stents for inoperable malignant strictures of the cervical esophagus. *Dis Esophagus* 2009; 22: 354-60.
22. Bethge N, Vakil N. A prospective trial of a new self-expanding plastic stent for malignant esophageal obstruction. *Am J Gastroenterol* 2001; 96: 1350-4.
23. Fujita T, Tanabe M, Shimizu K, et al. Radiological image-guided placement of covered Niti-S stent for palliation of dysphagia in patients with cervical esophageal cancer. *Dysphagia* 2013; 28: 253-9.
24. Poincloux L, Sautel C, Rouquette O, et al. The clinical outcome in patients treated with a newly designed SEMS in cervical esophageal strictures and fistulas. *J Clin Gastroenterol* 2016; 50: 379-87.
25. Choi EK, Song HY, Kim JW. Covered metallic stent placement in the management of cervical esophageal strictures. *J Vasc Interv Radiol* 2007; 18: 888-95.
26. Radecke K, Gerken G, Treichel U. Impact of a self-expanding, plastic esophageal stent on various esophageal stenoses, fistulas, and leakages: a single-center experience in 39 patients. *Gastrointest Endosc* 2005; 61: 812-18.
27. Szegeedi L, Gal I, Kósa I, et al. Palliative of esophageal carcinoma with self-expanding plastic stents: a report on 69 cases. *Eur J Gastroenterol Hepatol* 2006; 18: 1197-201.
28. Kinsman KJ, DeGregorio BT, Katon RM, et al. Prior radiation and chemotherapy increase the risk of life-threatening complications after insertion of metallic stents for esophagogastric malignancy. *Gastrointest Endosc* 1996; 43: 196-203.
29. Sloan MA, Hauter WE, Sloan PA, et al. Esophageal stent migration as a cause of severe upper airway obstruction. *Emergency Med* 2014; 4: 197.
30. Mariette C, De Botton ML, Piessen G. Surgery in esophageal and gastric cancer patients: what is the role for nutrition support in your daily practice? *Ann Surg Oncol* 2012; 19: 2128-34.
31. Riccardi D, Allen K. Nutritional management of patients with esophageal and esophagogastric junction cancer. *Cancer Control* 1999; 6: 64-72.
32. Daly JM, Weintraub FN, Shou J, et al. Enteral nutrition during multimodality therapy in upper gastrointestinal cancer patients. *Ann Surg* 1995; 221: 327-38.
33. Miller KR, Bozeman MC. Nutrition therapy issues in esophageal cancer. *Curr Gastroenterol Rep* 2012; 14: 356-66.
34. Pulkkinen J, Rekola J, Asanti M, et al. Prophylactic percutaneous endoscopic gastrostomy in head and neck cancer patients: results of tertiary institute. *Eur Arch Otorhinolaryngol* 2014; 271: 1755-8.
35. Löser C, Wolters S, Fölsch UR. Enteral long-term nutrition via percutaneous endoscopic gastrostomy (PEG) in 210 patients: a four-year prospective study. *Dig Dis Sci* 1998; 43: 2549-57.
36. Kimyagarov S, Turgeman D, Fleissig Y, et al. Percutaneous endoscopic gastrostomy (PEG) tube feeding of nursing home residents is not associated with improved body composition parameters. *J Nutr Health Aging* 2013; 17: 162-5.
37. Bower M, Jones W, Vessels B, et al. Nutritional support with endoluminal stenting during neoadjuvant therapy for esophageal malignancy. *Ann Surg Oncol* 2009; 16: 3161-8.
38. Lee C, Im JP, Kim JW, et al. Risk factors for complications and mortality of percutaneous endoscopic gastrostomy: a multi-center, retrospective study. *Small Intestine Research Group of the Korean Association for the Study of Intestinal Disease (KASID). Surg Endosc* 2013; 27: 3806-15.
39. Ellrichmann M, Sergeev P, Bethge J, et al. A prospective evaluation of malignant cell seeding after percutaneous endoscopic gastrostomy in patients with oropharyngeal/esophageal cancers. *Endoscopy* 2013; 45: 526-31.
40. Volkmer K, Meyer T, Sailer M, et al. Metastasis of an esophageal carcinoma at a PEG site: case report and review of the literature. *Zentralbl Chir* 2009; 134: 481-5.

Received: 29.10.2017, accepted: 20.12.2017.