

# Carbon nanoparticle-assisted natural orifice specimen extraction surgery with left colic artery preservation: a retrospective study

Mengao Qian, Shangyu Yin, Kepeng Hu, Quanpeng Wang, Weilan Cao, Changbao Liu, Zhonglin Wang, Chongjie Huang

Department of Colorectal Surgery, The Second Affiliated Hospital and Yuying Children's Hospital of Wenzhou Medical University, Wenzhou, China

Videosurgery Miniinv 2022; 17 (3): 498–505  
DOI: <https://doi.org/10.5114/wiitm.2022.116284>

## Abstract

**Introduction:** Natural orifice specimen extraction surgery (NOSES) has been widely regarded as a new technology in minimally invasive surgery. Meanwhile, carbon nanoparticles have been increasingly used for lymph node tracing in colorectal cancer surgery.

**Aim:** To evaluate the effectiveness and feasibility of carbon nanoparticle-assisted natural orifice specimen extraction surgery with left colic artery preservation for total laparoscopic colorectal resection.

**Material and methods:** We retrospectively reviewed the medical records of 83 patients diagnosed with sigmoid colon cancer or mid- and upper-rectal cancer from October 2017 to June 2020. These patients were divided into the NOSES group who underwent left colic artery preservation NOSES, being injected with a carbon nanoparticle suspension under colonoscopy the day before surgery, and the LA group, who underwent left colic artery preservation laparoscopic surgery. Surgical outcomes were retrospectively analyzed.

**Results:** The mean number of harvested lymph nodes ( $p < 0.001$ ) in the NOSES group was higher than in the LA group. Conversely, as regards pain score ( $p < 0.001$ ) and postoperative hospital stay ( $p = 0.035$ ), the LA group has higher mean values. The incidence of perioperative complications ( $p = 0.385$ ) was 5.3% for the NOSES group compared to 13.3% for the LA group.

**Conclusions:** Preoperative colonoscopic injection of a carbon nanoparticle suspension is a feasible and practical solution to dissect lymph nodes surrounding the inferior mesenteric artery without affecting the left colic artery in patients with colorectal cancer and about to receive NOSES. Moreover, NOSES combined with this approach leads to less postoperative pain and shorter hospital stays.

**Key words:** colorectal surgery, laparoscope, carbon nanoparticle suspension, natural orifice specimen extraction surgery, left colic artery preservation.

## Introduction

In recent years, natural orifice specimen extraction surgery (NOSES) has become an increasingly popular noninvasive surgical technique and attracted extensive attention from researchers worldwide

[1, 2]. There is ample evidence showing that it is reasonable and feasible to collect specimens from the sigmoid colon or the rectum via the anus during NOSES [3, 4]. This procedure perfects the traditional laparoscopic colorectal resection as it effectively reduces the incidence of such postoperative complica-

### Address for correspondence

Zhong-Lin Wang, Department of Colorectal Surgery, The Second Affiliated Hospital and Yuying Children's Hospital of Wenzhou Medical University, Wenzhou 325027, Zhejiang Province, China, phone: +86-577-88002234, fax: +86-577-88002234, e-mail: [ph115507@163.com](mailto:ph115507@163.com);  
Chong-Jie Huang, Department of Colorectal Surgery, The Second Affiliated Hospital and Yuying Children's Hospital of Wenzhou Medical University, Wenzhou 325027, Zhejiang Province, China, phone: +86-577-88002234, fax: +86-577-88002234, e-mail: [209187@wzhealth.com](mailto:209187@wzhealth.com)

tions as pain, wound infection, and anastomotic hernia. However, since NOSES is still at its early stage of development, there is a limited number of cases for reference, and many conceptual and technical problems require further discussion and solutions.

Colorectal leak rates have been found to vary according to the anatomic location of the anastomosis, with distal colorectal, coloanal, and ileoanal leak rates ranging from 1% to 20%, colocolonic leak rates from 0% to 2%, and ileocolonic leak rates from 0.02% to 4% [5]. Studies have demonstrated the presence of anastomotic leakage in NOSES even with ligation of the root of the inferior mesenteric artery (IMA), which adversely affects the prognosis [6]. Alternatively, dissecting D3 lymph nodes surrounding the IMA with left colic artery (LCA) preservation is a safe procedure that guarantees sufficient blood supply to the distal colon, especially for those who have coexisting diseases and face a high risk of failure in anastomosis [7]. Yet, it takes a relatively long time to finish the procedure.

Nowadays, carbon nanoparticles, composed of nanoscale carbon particles with an average diameter of 150 nm, have been widely used for lymph node tracking in radical gastrectomy, breast tumor resection, thyroidectomy, and colorectal cancer surgery [8–11]. After the carbon nanoparticles have been injected, they drain through the lymphatic system to reach the various levels of draining lymph nodes in the injected area, which then form black stains [9, 12]. Various studies have shown that carbon nanoparticle suspensions for injection are safe [13–15].

## Aim

We conducted this retrospective study to evaluate the effectiveness and feasibility of carbon nanoparticle-assisted NOSES with LCA preservation.

## Material and methods

### Patients

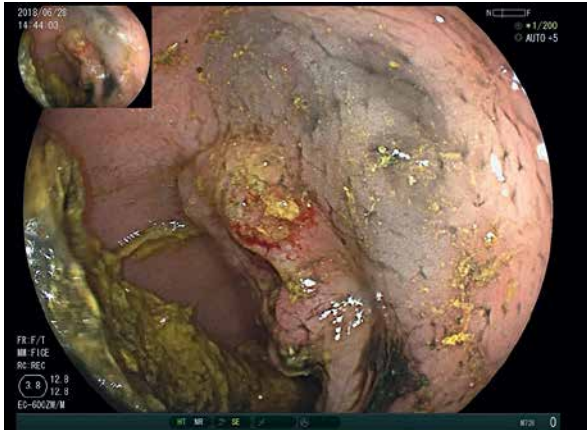We performed a retrospective observational study that included 83 patients who were diagnosed with sigmoid colon cancer or mid- and upper-rectal cancer between October 2017 and June 2020. Definitive diagnosis was established on the basis of colonoscopy and biopsy before surgery. The conventional preoperative staging was composed of physical

examination, contrast-enhanced computed tomography (CT), or magnetic resonance imaging (MRI). Patients undergoing neoadjuvant chemotherapy or chemoradiotherapy, having stage IV cancer, having emergency surgery or protective ostomy were excluded from the study. All procedures were performed by an experienced surgeon who was skilled at laparoscopic operations. The Ethics Committee of The Second Affiliated Hospital of Wenzhou Medical University approved this study, and this study was conducted in accordance with the Declaration of Helsinki.

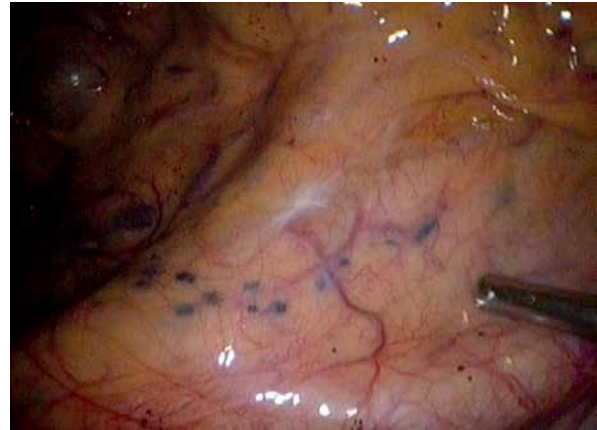Pre-NOSES surgical methods were subject to each patient's preoperative staging workup. For the NOSES group, before laparoscopic colorectal resection, the carbon nanoparticle suspension was injected into the upper and lower edges of the lesion under colonoscopy to track the lymph nodes. Lymph nodes surrounding the IMA were dissected while the LCA remained intact. An intergroup comparison was made in terms of general information (age, body mass index (BMI), sex) and short-term efficacy based on operative time, blood loss, harvested lymph nodes, time to first flatus, postoperative complication, anastomotic leakage, postoperative hospital stay and VAS (visual analog scale) pain score 24 h after surgery.

### Preoperative labeling under colonoscopy

The carbon nanoparticle suspension injection for labeling was produced by Chongqing Lummy Pharmaceutical Co., Ltd. (batch number: H20073246; 0.5 ml). All tumors were labeled by a designated gastroenterologist. To minimize the effect of post-colonoscopy on intestinal tympanites or diffusion of the suspension on operations, the labeling was completed the day before surgery. The injection catheter enters the body via the endoscope's working channel. The carbon nanoparticle suspension was injected at three to four locations in the colorectal submucosa at a distance of about 0.5 cm from the upper and lower edge of the target lesion. To make sure the needle is injected into the submucosa instead of the peritoneum, a mucosal protrusion was created with a small amount of saline. Following that, 0.5 ml of the carbon nanoparticle suspension was diluted to 5 ml, and each submucosal location was injected with about 0.5 ml of carbon nanoparticle suspension injection (CNSI) (Photo 1).



**Photo 1.** Carbon nanoparticle suspension was injected at a distance of about 0.5 cm from the lower edge of the tumor for labeling and tracing the day before surgery



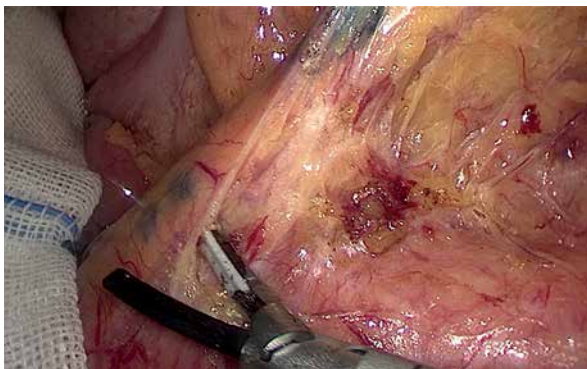
**Photo 2.** Intraoperative image of black-stained lymph nodes showing clear boundaries and well-defined distribution patterns along the IMA

### Operations

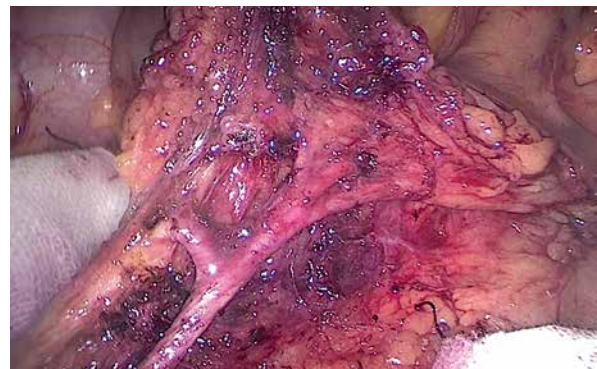General anesthesia was performed on each patient in the modified lithotomy position. Lymph node dissection was made via a medial-to-lateral approach along the IMA. For the LA group, radical peri-IMA lymph node dissection was completed under laparoscopy, the LCA was identified and preserved while low ligation of the IMA (the superior hemorrhoidal artery) was performed. Then, an auxiliary incision was made at the lower abdomen to remove the lesion, after which, anastomosis of the colon was performed. For the NOSES group, at first, the root of the IMA was exposed to observe the distribution of black-stained lymph nodes along the IMA (Photo 2); an incision was made to open the peritoneum at the root of the IMA in connection to the abdominal aorta; based on the tissue with black-

stained lymph nodes (Photo 3), the target lesion was removed from the bottom up along the IMA until the separate lesion reached the origin of the LCA; following that, adipose tissue and the black-stained lymphatic tissue were removed radically through an incision from the LCA to the root of the IMA (Photo 4).

After lymph node dissection, the superior rectal artery (SRA) was cut under the IMA-LCA junction (Photo 5). Determination of resection lines was subject to the labeled lymph nodes. In the case of colon cancer, the margins of resection on both sides should be 10 cm or above; in contrast, a distal margin of resection of at least 2 cm should be obtained below the edge of the rectal cancer; splenic flexure mobilization is not recommended in either case. All specimens were then removed through the anus. Tumor location is the most important factor in the selection of different surgical procedures. High rec-



**Photo 3.** Lymph node dissection guided by black-stained lymph nodes surrounding the IMA



**Photo 4.** Freed IMA and LCA during lymph node dissection

tum and sigmoid colon cancers were resected in the abdominal cavity by laparoscopy and then the specimens were pulled out through the anus; for middle rectal cancer (Photos 6 A, B), after abdominal lymph node dissection by laparoscope the preresected intestine was pulled out through the anus, and then the specimens were resected *in vitro* (Photo 7).

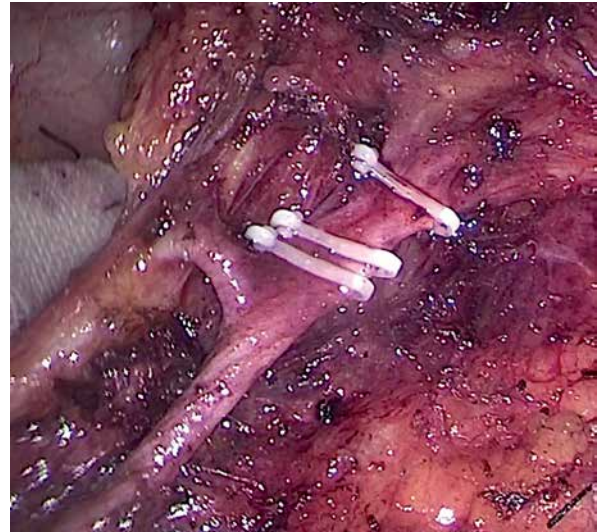
### Statistical analysis

The software SPSS 19.0 was used for statistical analysis. The  $\chi^2$  test was employed in the comparison of classification variables; Student's *t*-test was applied for the analysis of continuous variables, with  $p < 0.05$  indicating a difference of statistical significance.

### Results

This study analyzed 83 eligible patients having received colorectal resection (38 cases of NOSES and 45 cases of laparoscopic-assisted surgery). Comparison of age, male-to-female ratio, BMI, American Society of Anesthesiologists (ASA) score, tumor size, tumor site, and depth of tumor infiltration between the two groups is shown in Table I.

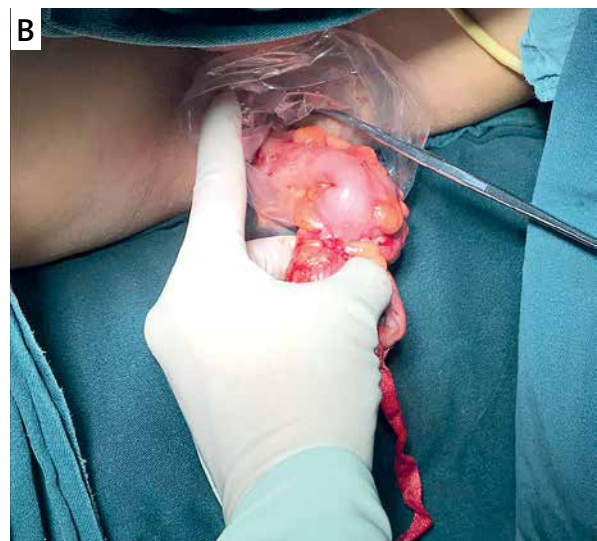
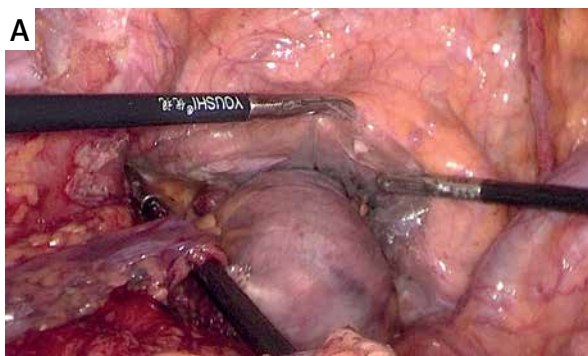
The mean number of harvested lymph nodes was  $22.8 \pm 5.6$  in the NOSES group and  $17.0 \pm 2.8$  in the LA group ( $p < 0.001$ ); mean operative time was  $129.5 \pm 18.7$  min in the NOSES group and  $120.4 \pm 17.1$  min in the LA group ( $p = 0.073$ ). Although the NOSES group had longer operative time compared to the LA group, more lymph nodes were harvested in it than in the LA group. Moreover, in each group a sufficient



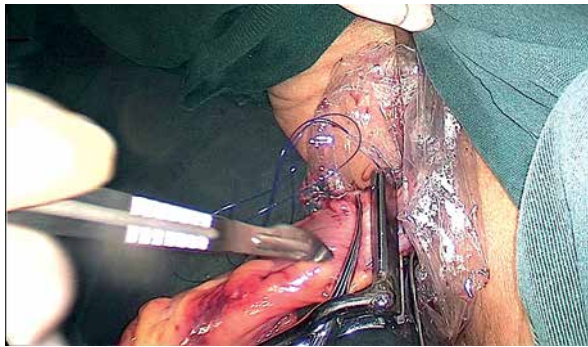**Photo 5.** Superior rectal artery ligation at the origin of the LCA from the IMA while leaving the LCA intact

number of lymph nodes was harvested for postoperative staging. The pain scores at 24 h after surgery of the NOSES group and the LA group were  $3.6 \pm 1.2$  and  $4.8 \pm 0.9$ , respectively ( $p < 0.001$ ). There was a significant difference between the two groups in postoperative recovery time and hospital stay ( $7.1 \pm 1.2$  days vs.  $8.2 \pm 1.9$  days,  $p = 0.035$ ) (Table II).

In the NOSES group, there were 2 cases of postoperative complications, namely, intestinal obstruction and lymphatic leakage. The intestinal obstruction was cured by means of abrosia and gastrointestinal decompression while the lymphatic leakage was treated by adjusting the patient's diet



**Photo 6 A, B** – Pulling the collected specimen out of the body from the distal rectum before anastomosis



**Photo 7.** After abdominal lymph node dissection by laparoscope, and then the specimens were resected *in vitro*

and maintaining unobstructed drainage until improvement and extubation. No NOSES-associated complications, such as damage to the distal colon, bladder or anus, tumor overflow, anastomotic leakage, and intra-abdominal infection, were reported. The LA group had 6 cases of postoperative complications, including anastomotic leakage, wound infection, intestinal obstruction, and lymphatic leakage. Two patients with anastomotic leaks were given transverse colostomy and conservative treatment, respectively. The wound infection, intestinal

obstruction, and lymphatic leak were cured with relevant conservative treatment.

### Discussion

Since the world’s first laparoscopic surgery for rectal cancer was carried out in 1991, minimally invasive surgery represented by laparoscopic technology has become the main means of colorectal cancer treatment in a short period of 20 years. As a new star of minimally invasive technology, NOSES is gradually being recognized and accepted by many clinicians because of the potential benefits including reduction in postoperative pain and wound complications, less use of postoperative analgesia, faster recovery of intestinal function, shorter hospital stay, and better cosmetic and psychological effects described in colorectal surgery [16]. Some researchers have proposed that, compared with the conventional laparoscopic procedure, NOSES is in conformity with the principle of asepsis and tumor-free technique and can be worthy of clinical application [17]. A systematic review and meta-analysis of NOSES showed that NOSES is a safe and viable alternative to traditional laparoscopy in colorectal oncology in terms of short-term results [18].

**Table I.** Intergroup comparison of general information

Parameter	NOSES group (n = 38)	LA group (n = 45)	P-value
Sex:			0.522
Male	27 (71%)	29 (64%)	
Female	11 (29%)	16 (36%)	
Age [years]	61.2 ±9.7	65.0 ±8.1	0.097
BMI [kg/m <sup>2</sup> ]	23.9 ±1.3	23.3 ±1.7	0.164
ASA score:			0.912
I	18 (47%)	20 (45%)	
II	19 (50%)	24 (53%)	
III	1 (3%)	1 (2%)	
Tumor site:			0.677
Sigmoid colon	16 (42%)	21 (47%)	
Upper and middle rectum	22 (58%)	24 (53%)	
T-staging:			0.052
T1	7 (19%)	3 (7%)	
T2	11 (29%)	8 (18%)	
T3	18 (47%)	24 (53%)	
T4	2 (5%)	10 (22%)	

BMI – body mass index, ASA – American Society of Anesthesiologists.

**Table II.** Intergroup comparison of surgical outcomes

Outcomes	NOSES group (n = 38)	LA group (n = 45)	P-value
Operative time [min]	129.5 ±18.7	120.4 ±17.1	0.073
Blood loss [ml]	50.6 ±21.0	40.9 ±20.2	0.352
Number of harvested lymph node	22.8 ±5.6	17.0 ±2.8	< 0.001
Time to first flatus [day]	2.2 ±0.4	2.4 ±0.6	0.081
Complication	2 (5%)	6 (13%)	0.385
Anastomotic leakage	0 (0)	2 (4%)	0.498
Postoperative hospital stay [day]	7.1 ±1.2	8.2 ±1.9	0.035
VAS pain score	3.6 ±1.2	4.8 ±0.9	< 0.001

VAS – visual analog scale.

In this study, patients in the NOSES group had shorter postoperative hospital stays and lower pain compared to traditional laparoscopic surgery. Possible reasons include the following: In conventional laparoscopic surgery, the extraction of the specimen requires an additional incision, which damages the abdominal wall and is more likely to cause vascular and nerve damage, so the patient's postoperative pain is more significant. In addition, due to abdominal pain, patients need more time to return to normal exercise after surgery, which will be more detrimental to postoperative recovery and prolong hospital stay.

As with conventional laparoscopic colorectal cancer surgery, NOSES carries the risk of anastomotic leakage. The studies by Park *et al.* [19] and Xingmao *et al.* [6] both showed there was no significant difference between the NOSES group and conventional laparoscopy in terms of anastomotic leakage and postoperative complications, which is the same as the results of this study. Based on previous experience, preserving the LCA in laparoscopic resection of carcinomas in the sigmoid colon and the sigmoid colon-rectum junction could effectively prevent anastomotic leakage [20–22]. In the present study, for patients in the NOSES group, the optimal depth of tumor invasion was within T3, and the circumferential diameter of the specimen after transrectal NOSES was less than 3 cm, which had clear planes of surgical resection thanks to the preoperative carbon nanoparticle suspension injection for tracing. On this basis, it was safe and feasible to dissect lymph nodes surrounding the root of the IMA while leaving the LCA intact. In addition, previous studies [23, 24] have shown that the collateral pathways between the superior mesenteric artery (SMA) and IMA play an important role in anastomotic perfusion in left

colorectal cancer surgery, which requires significant attention.

With the preoperative injection of the tumor marker, precise incisions were placed over the colorectum, minimizing resection of the normal segment of the colorectum without affecting the surgical outcomes of the radical resection, especially for those who had sigmoid colon-rectum junction cancer or upper-rectal cancer and needed precise incisions to avoid unnecessary resection of the normal colorectum and reduce the tension on the anastomosis. Moreover, the operative time was markedly reduced when skipping the invalid step of freeing the colon, which effectively demonstrated the high precision and non-invasive property of NOSES in total endoscopic resection for the involved colorectum.

Previous studies showed that there was no significant difference in number of harvested lymph nodes between the NOSES group and laparoscopy group [6, 25, 26]. However, in this study, significantly more lymph nodes were harvested in the NOSES group compared with LA group due to the application of the nanoparticle suspension. Preoperative colonoscopy injection of carbon nanoparticle suspension as a tracer was used as the first step for lymph node dissection between vaginal blood vessels and adventitia. The black stained lymph nodes and fatty tissue can be completely removed along the IMA from the bottom to the beginning of the LCA. This is an effective method of lymph node dissection, thereby reducing the operation time required for lymph node resection.

## Conclusions

This study demonstrates that in NOSES for sigmoid colon cancer or rectal cancer, it is safe and feasi-

ble to guide peri-IMA lymph node dissection with LCA preservation using carbon nanoparticles as a specific tracer. As a non-invasive surgical technique, NOSES is characterized by its benefits of fast recovery and a sufficient harvest of involved lymph nodes. However, a multicenter study with a larger sample size is needed to assess the long-term results and potential benefits of carbon nanoparticle-assisted NOSES.

## Acknowledgments

Mengao Qian and Shangyu Yin have contributed equally to this work.

We would like to thank the surgeons from the participating institutes, for helping us with this study.

This study was funded by the Wenzhou Municipal Science and Technology Bureau (Y20190155, Y20210250), the Medical and Health Research Project of Zhejiang Province (2016KYA168).

## Conflict of interest

The authors declare no conflict of interest.

## References

1. Sanchez JE, Marcet JE. Colorectal natural orifice transluminal endoscopic surgery (NOTES) and transvaginal/transrectal specimen extraction. *Tech Coloproctol* 2013; 17 Suppl 1: S69-73.
2. Nishimura A, Kawahara M, Honda K, et al. Totally laparoscopic anterior resection with transvaginal assistance and transvaginal specimen extraction: a technique for natural orifice surgery combined with reduced-port surgery. *Surg Endosc* 2013; 27: 4734-40.
3. Wolthuis AM, Van Geluwe B, Fieuws S, et al. Laparoscopic sigmoid resection with transrectal specimen extraction: a systematic review. *Colorectal Dis* 2012; 14: 1183-8.
4. Franklin ME Jr, Liang S, Russek K. Natural orifice specimen extraction in laparoscopic colorectal surgery: transanal and transvaginal approaches. *Tech Coloproctol* 2013; 17 Suppl 1: S63-7.
5. Sciuto A, Merola G, De Palma GD, et al. Predictive factors for anastomotic leakage after laparoscopic colorectal surgery. *World J Gastroenterol* 2018; 24: 2247-60.
6. Xingmao Z, Haitao Z, Jianwei L, et al. Totally laparoscopic resection with natural orifice specimen extraction (NOSE) has more advantages comparing with laparoscopic-assisted resection for selected patients with sigmoid colon or rectal cancer. *Int J Colorectal Dis* 2014; 29: 1119-24.
7. Liang JT, Lai HS. Surgical technique of robotic D3 lymph node dissection around the inferior mesenteric artery with preservation of the left colic artery and autonomic nerves for the treatment of distal rectal cancer. *Surg Endosc* 2014; 28: 1727-33.
8. Hong Q, Wang Y, Wang JJ, et al. Application of lymph node labeling with carbon nanoparticles by preoperative endoscopic subserosal injection in laparoscopic radical gastrectomy. *Zhonghua Yi Xue Za Zhi* 2017; 97: 123-6.
9. Wang Q, Chen E, Cai Y, et al. Preoperative endoscopic localization of colorectal cancer and tracing lymph nodes by using carbon nanoparticles in laparoscopy. *World J Surg Oncol* 2016; 14: 231.
10. Wang B, Qiu NC, Zhang W, et al. The role of carbon nanoparticles in identifying lymph nodes and preserving parathyroid in total endoscopic surgery of thyroid carcinoma. *Surg Endosc* 2015; 29: 2914-20.
11. Gill A, Brunson A, Lara P Jr, et al. Implications of lymph node retrieval in locoregional rectal cancer treated with chemoradiotherapy: a California Cancer Registry Study. *Eur J Surg Oncol* 2015; 41: 647-52.
12. Zhang XM, Liang JW, Wang Z, et al. Effect of preoperative injection of carbon nanoparticle suspension on the outcomes of selected patients with mid-low rectal cancer. *Chin J Cancer* 2016; 35: 33.
13. Figarol A, Pourchez J, Boudard D, et al. In vitro toxicity of carbon nanotubes, nano-graphite and carbon black, similar impacts of acid functionalization. *Toxicol In Vitro* 2015; 30: 476-85.
14. Valagussa P, Bonadonna G, Veronesi U. Patterns of relapse and survival following radical mastectomy. Analysis of 716 consecutive patients. *Cancer* 1978; 41: 1170-8.
15. Mannerström M, Zou J, Toimela T, et al. The applicability of conventional cytotoxicity assays to predict safety/toxicity of mesoporous silica nanoparticles, silver and gold nanoparticles and multi-walled carbon nanotubes. *Toxicol In Vitro* 2016; 37: 113-20.
16. Guan X, Liu Z, Longo A, et al. International consensus on natural orifice specimen extraction surgery (NOSES) for colorectal cancer. *Gastroenterol Rep (Oxf)* 2019; 7: 24-31.
17. Ouyang Q, Peng J, Xu S, et al. Comparison of NOSES and conventional laparoscopic surgery in colorectal cancer: bacteriological and oncological concerns. *Front Oncol* 2020; 10: 946.
18. Chin YH, Decruz GM, Ng CH, et al. Colorectal resection via natural orifice specimen extraction versus conventional laparoscopic extraction: a meta-analysis with meta-regression. *Tech Coloproctol* 2021; 25: 35-48.
19. Park JS, Kang H, Park SY, et al. Long-term outcomes after Natural Orifice Specimen Extraction versus conventional laparoscopy-assisted surgery for rectal cancer: a matched case-control study. *Ann Surg Treat Res* 2018; 94: 26-35.
20. Kato H, Munakata S, Sakamoto K, et al. Impact of left colonic artery preservation on anastomotic leakage in laparoscopic sigmoid resection and anterior resection for sigmoid and rectosigmoid colon cancer. *J Gastrointest Cancer* 2018. doi: 10.1007/s12029-018-0126-z.
21. Hinoi T, Okajima M, Shimomura M, et al. Effect of left colonic artery preservation on anastomotic leakage in laparoscopic anterior resection for middle and low rectal cancer. *World J Surg* 2013; 37: 2935-43.
22. You X, Wang Y, Chen Z, et al. Clinical study of preserving left colic artery during laparoscopic total mesorectal excision for the treatment of rectal cancer. *Zhonghua Wei Chang Wai Ke Za Zhi* 2017; 20: 1162-7.
23. Karatay E, Javadov M. The importance of the Moskowitz artery as a lesser-known collateral pathway in the medial laparoscopic

- ic approach to splenic flexure mobilisation and its evaluation with preoperative computed tomography. *Videosurgery Mini-invasive* 2021; 16: 305-11.
24. Zhang C, Li A, Luo T, et al. Evaluation of characteristics of left-sided colorectal perfusion in elderly patients by angiography. *World J Gastroenterol* 2020; 26: 3484-94.
  25. Liu RJ, Zhang CD, Fan YC, et al. Safety and oncological outcomes of laparoscopic nose surgery compared with conventional laparoscopic surgery for colorectal diseases: a meta-analysis. *Front Oncol* 2019; 9: 597.
  26. Hisada M, Katsumata K, Ishizaki T, et al. Complete laparoscopic resection of the rectum using natural orifice specimen extraction. *World J Gastroenterol* 2014; 20: 16707-13.

**Received:** 20.03.2022, **accepted:** 25.04.2022.