

Y-configured metallic stent combined with ^{125}I seed strands cavity brachytherapy for a patient with type IV Klatskin tumor

Jiao Dechao, MD, PhD, Prof. Xinwei Han, MD, Prof. Wang Yanli, MD, Prof. Li Zhen, MD

Department of Interventional Radiology, The First Affiliated Hospital of Zhengzhou University, Zhengzhou, People's Republic of China

Abstract

We report a case in an inoperable patient with type IV Klatskin tumor treated by the use of a novel, two piece, Y-configured self-expandable metallic stent (SEMS) combined with two ^{125}I seed strands via bilateral approach. The placement of the Y-shaped SEMS was successful and resulted in adequate biliary drainage. After 2 months of intraluminal brachytherapy (ILBT), both ^{125}I seed strands and temporary drainage catheter were removed after patency of the expanded stents was confirmed by the cholangiogram. This technique was feasible and could be considered for the treatment of patients with Bismuth type IV Klatskin tumors.

J Contemp Brachytherapy 2016; 8, 4: 356–360

DOI: 10.5114/jcb.2016.61704

Key words: biliary stent, bile duct cancer, brachytherapy, cholangiocarcinoma, Klatskin tumor.

Purpose

The treatment of Bismuth type IV Klatskin tumor remains a challenging clinical problem [1]. Two techniques have been developed for the percutaneous placement of bilateral self-expandable metallic stent (SEMS) for palliative drainage: stent-in-stent and side-by-side deployment techniques, in which two tubular stents were used for bilateral SEMS deployment, including Y and T-configured stent placement [2,3]. We developed a novel, two-piece, Y-shaped SEMS, with angled main stent and a smaller limb stent (Micro-tech, Nanjing, China). This configuration conforms to the hilar biliary tract anatomy and provides strong support forces to the duct (Figure 1).

High-dose-rate (HDR)- ^{192}Ir was the most common radioactive source for intraluminal brachytherapy (ILBT). However, an HDR- ^{192}Ir afterloading unit is not available at most hospitals in China, which should be protected by an isolated and well-shielded room. Moreover, because the bile duct tissue is very thin, HDR- ^{192}Ir ILBT cannot be completed in some cases due to the computerized remote after loading source where protection is needed [4]. ^{125}I seeds are characterized by a long half-life (59.6 days), which is convenient for their storage. The low-energy photons emitted by ^{125}I seeds also requires less shielding. Brachytherapy with ^{125}I seeds strands has been reported for the treatment of hepatocellular carcinoma with intrahepatic portal vein tumor thrombus [5]. Herein, we used a newly designed Y-shaped SEMS combined with two ^{125}I seed strands to treat type IV Bismuth tumor.

Case report

A 62-year-old female was admitted to the hospital complaining of right upper quadrant pain. Initial magnetic resonance (MR) showed hepatic hilar obstruction due to cholangiocarcinoma, extending from hilum of extrahepatic bile duct to distal common bile duct (Figure 2A). Elevated total bilirubin level (204.3 $\mu\text{mol/l}$) and direct bilirubin level (177.3 $\mu\text{mol/l}$) were found at admission. Percutaneous transhepatic biliary drainage (PTBD) through the left intrahepatic bile duct (Figure 3A) was done. Two temporary 8.5-F drainage catheters (Cook, Bloomington, IL, United States) were inserted across the hilar tumor to duodenum for percutaneous PTBD via bilateral approaches. The patient had severe hemobilia two days after PTBD and it was due to a pseudoaneurysm of the right intrahepatic artery, and was treated successfully with selective transarterial coil embolization. We developed a newly designed Y-configured bilateral SEMS, which has two components: angled main stent and a smaller limb stent (Figure 1). The cylindrical titanium capsules of the ^{125}I seeds (Xingke Company, Shanghai, China) were 0.8 mm in diameter and 4.5 mm in length, and seed activity was 1.0 mCi [5]. We placed 15 and 10 seeds in two 4-F sterile catheter to construct ^{125}I seed strands, respectively. The ends of the 4-F catheter were closed using 5-0 sutures.

The procedure was conducted on the tenth day after the initial drainage procedure. Super-stiff guide wire (Boston Scientific, Natick, MA, USA) were passed through the stenosis simultaneously into the duodenum via bilat-

Address for correspondence: Prof. Xinwei Han, MD, Department of Interventional Radiology, The First Affiliated Hospital of Zhengzhou University, Zhengzhou, 450052 Henan, People's Republic of China, phone: +0086-13803842129, e-mail: 13592583911@163.com

Received: 11.06.2016

Accepted: 21.07.2016

Published: 24.08.2016

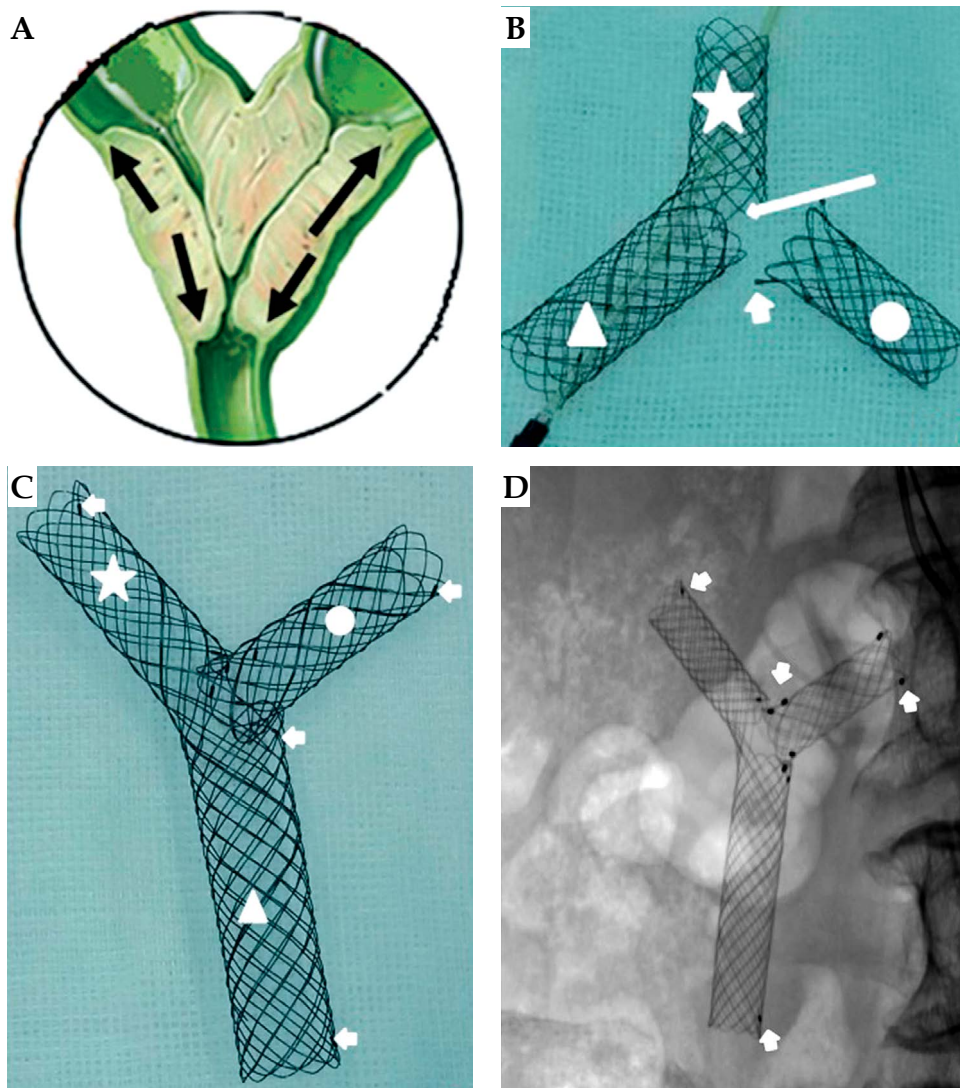


Fig. 1. The hilar trifurcated biliary anatomy (A). The novel Y-configured bilateral self-expandable metallic stent (SEMS) consists of two components: the main stent (angled shape) and a limb stent. The intrahepatic branch portion (star) of the main stent is 8 mm in diameter and 2.5 cm in length; the common bile duct portion (triangle) is 10 mm in diameter and 3.0 cm in length. At the angle of the main stent there is a 1.0-cm opening (long arrow). The limb stent (circle) is 8 mm in diameter and 2.5 cm in length (B, C). Fluoroscopic images show 4-6 radiopaque markers made of gold attached to the outer surface of the stent (D) (short arrow)

eral approach. The stenosis was dilated using a 6 mm balloon catheter. The main stent was first introduced over the guide wire into the common bile duct (CBD) through the right PTBD tract. The main stent was initially introduced over the guidewire into the CBD through the right PTBD tract. The proximal end of the main stent was located in the ipsilateral intrahepatic duct (IHD) beyond the boundary of the hilar tumor. The radiopaque markers on the outer surface of the proximal, middle, and distal portions of the stent positioned correctly under fluoroscopy, so that the opening in the side of the stent faced the contralateral bile duct. Firstly, the CBD part of the main stent and the part with the opening in the side were deployed, ensuring that the middle two radiopaque markers were positioned at the opening of the contralateral bile duct. Secondly, a catheter and guidewire were passed via the

contralateral bile duct, through the opening in the side of the stent, into the CBD and duodenum. The catheter was then withdrawn, and the limb stent was introduced over the guidewire and advanced until the distal portion of limb stent (micro-bell shape, 2-3 mm in length) going into the main piece of stent. After confirming that its proximal end was located in the IHD beyond the boundary of the hilar tumor and its distal end located within the lumen of the main stent, the limb stent was deployed. Thirdly, both 9-F sheath (Cordis, USA), was advanced along the stiff guide wire, and two ¹²⁵I seed strands were inserted through the 9-F sheath to the trifurcation stenosis, respectively (Figure 3D). Finally, fixed seed strands and super stiff guide wire withdraw the 9-F sheath, and two 8.5-F drainage catheters were inserted along super stiff guide wire across the hilar tumor to duodenum.

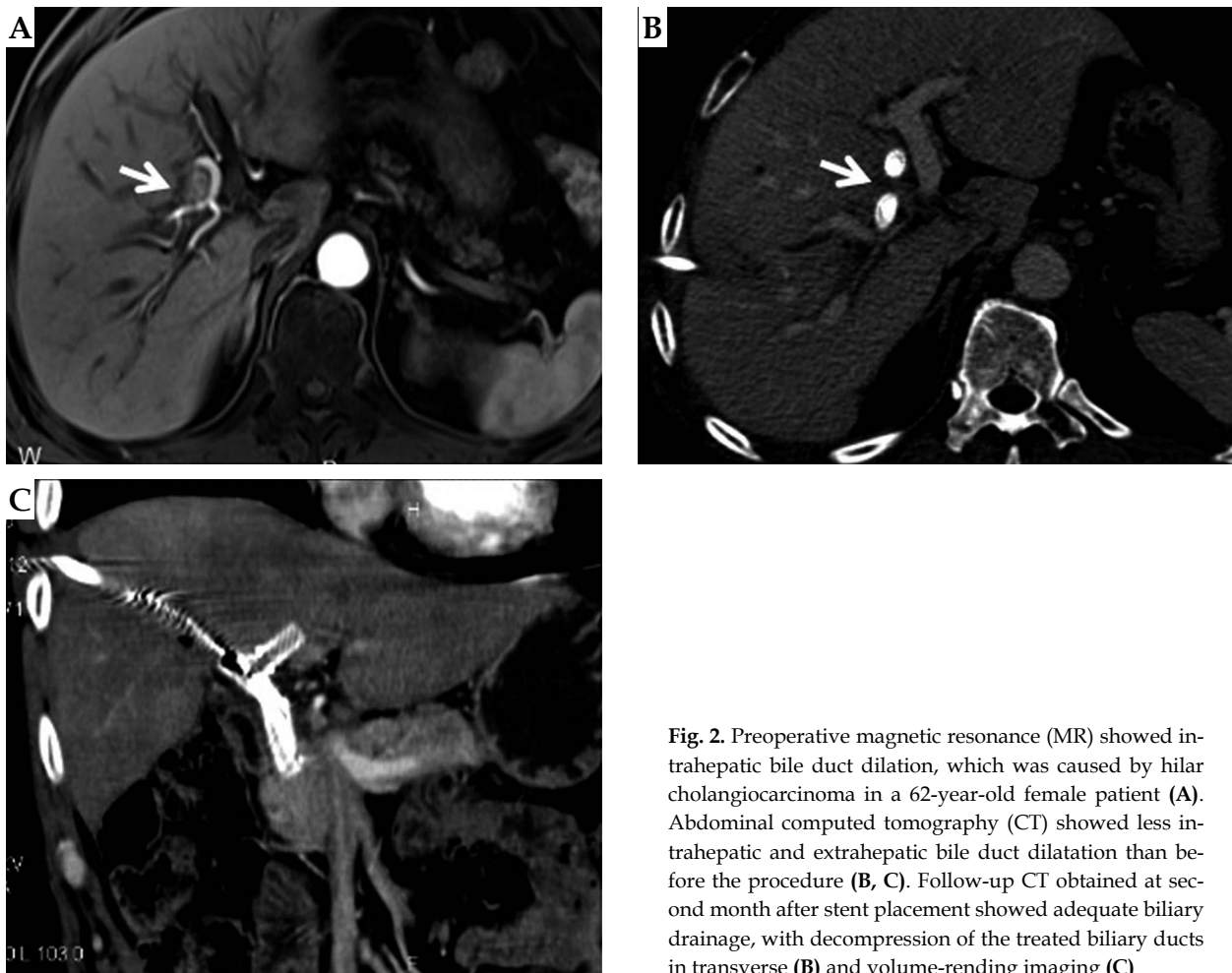


Fig. 2. Preoperative magnetic resonance (MR) showed intrahepatic bile duct dilation, which was caused by hilar cholangiocarcinoma in a 62-year-old female patient (A). Abdominal computed tomography (CT) showed less intrahepatic and extrahepatic bile duct dilatation than before the procedure (B, C). Follow-up CT obtained at second month after stent placement showed adequate biliary drainage, with decompression of the treated biliary ducts in transverse (B) and volume-rendering imaging (C)

After 2 months ILBT, two ^{125}I seed strands and temporary drainage catheter were removed after patency of the expanded stents was confirmed by the cholangiogram (Figure 3E and F). Cumulative absorbed dose at the dose reference points, 5 mm, 10 mm, 15 mm from the source axis, were 97.2, 28.8, 14.4 Gy according to the computerized treatment planning system (University of Beijing Aeronautics and Astronautics, Beijing, China) (Figure 4), respectively.

Abdominal computed tomography (CT) showed less intrahepatic and extrahepatic bile duct dilatation than before the procedure (Figure 2B and C). Meanwhile, total bilirubin and direct bilirubin levels decreased to 29.8 $\mu\text{mol/l}$ and 11.7 $\mu\text{mol/l}$, respectively, and remained low throughout the follow-up until patient's death due to myocardial infarction 381 days after the stenting.

Discussion

Palliation with percutaneous SEMS placement has been the best option available for the treatment of patients with unresectable malignant hilar biliary obstruction. Stent-in-stent deployment was the most common method, in which a second stent is placed through the mesh of the first stent. In these cases, the mesh in the middle portion of the stent is necessarily looser and therefore

more likely to allow tumor ingrowth and occlusion [6]. Bile duct stents manufactured in China are constructed using metal wires of thicker gauge (0.16 mm) than that used in South Korean stents (0.12 mm), which results in reduced stent compliance [7]. The newly designed Y-configured bilateral SEMS was in accordance with hilar biliary trifurcation anatomical structure improving compliance. Moreover, the proximal end with a micro single bell shape (2-3 mm in length) were inserted into the lumen of the main piece of stent without excessive overlapping, which was different from traditional stent-in-stent deployment, and another SEMS could be placed coaxially into the original SEMS through the PTBD tract without difficulty when second occlusion occurred. Considering that the median stent patency using a T or Y configuration was 104-250 days in the literatures [8], total bilirubin levels remained low throughout the follow-up 381 days, which was satisfactory.

Another innovation is the treatment of type IV Klatskin tumor with placement ^{125}I seed strands to prolong the patency period. There are several advantages. Firstly, the seeds can deliver a high radiation dose to the target tissues that drops rapidly with the distance from the seeds, thereby resulting in low radiation doses to the surrounding tissues. As a result, the use of ^{125}I seeds enables the delivery of a high radiation dose to tumor tis-

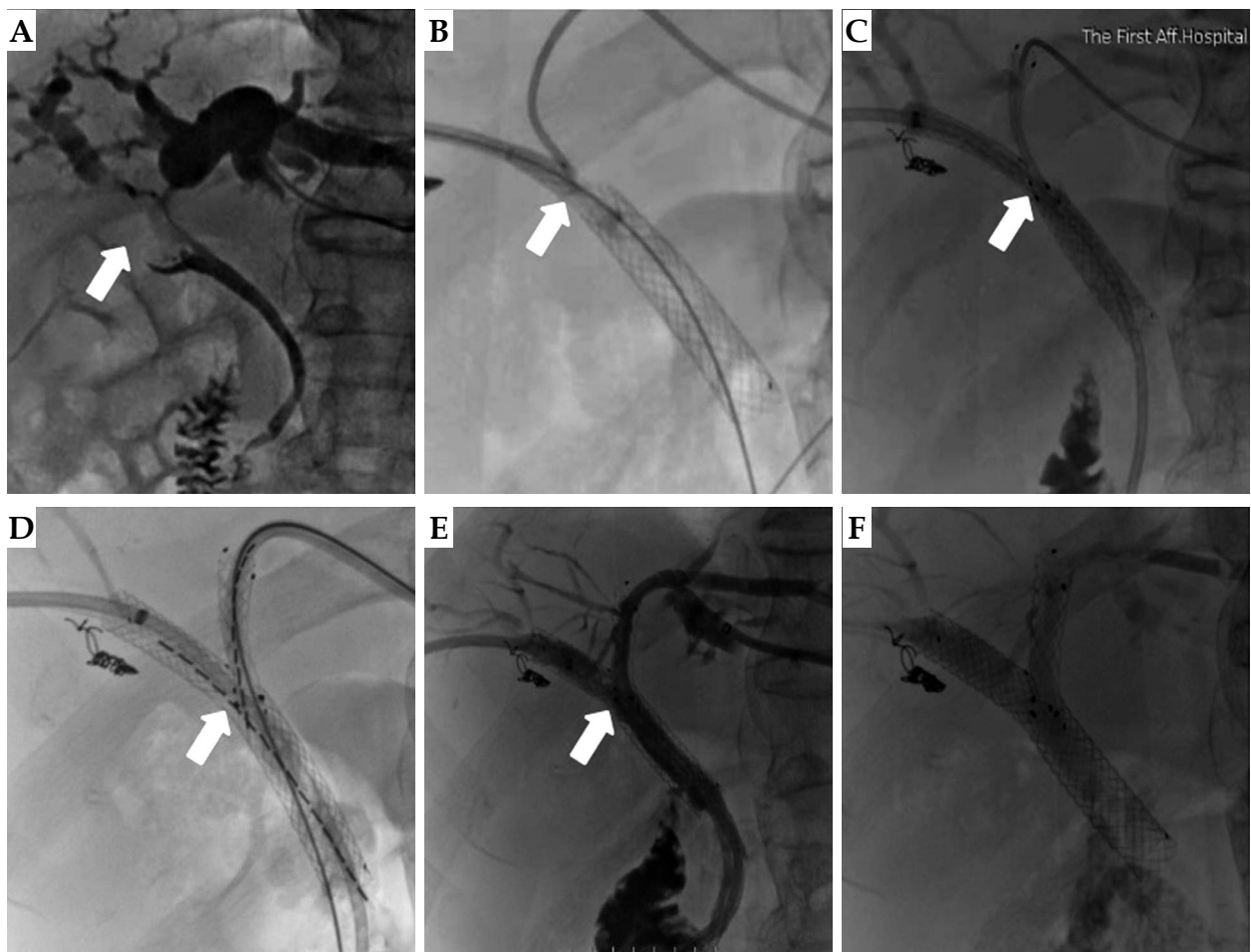


Fig. 3. Bismuth type IV cholangiocarcinoma was confirmed by PTCB (A). The CBD and opening hole portion of stent were deployed and ensure two middle radiopaque markers towards the opening of contralateral bile duct (B). The contralateral limb stent. Intrahepatic branch portion of the main stent were deployed (C). Both ¹²⁵I seed strands were inserted to the trifurcation stenosis (D). Cholangiography was performed through two 8.5-F drainage catheter two month later (E); after patency of the expanded stents was confirmed, and the drainage catheter and seed strands were removed (F)

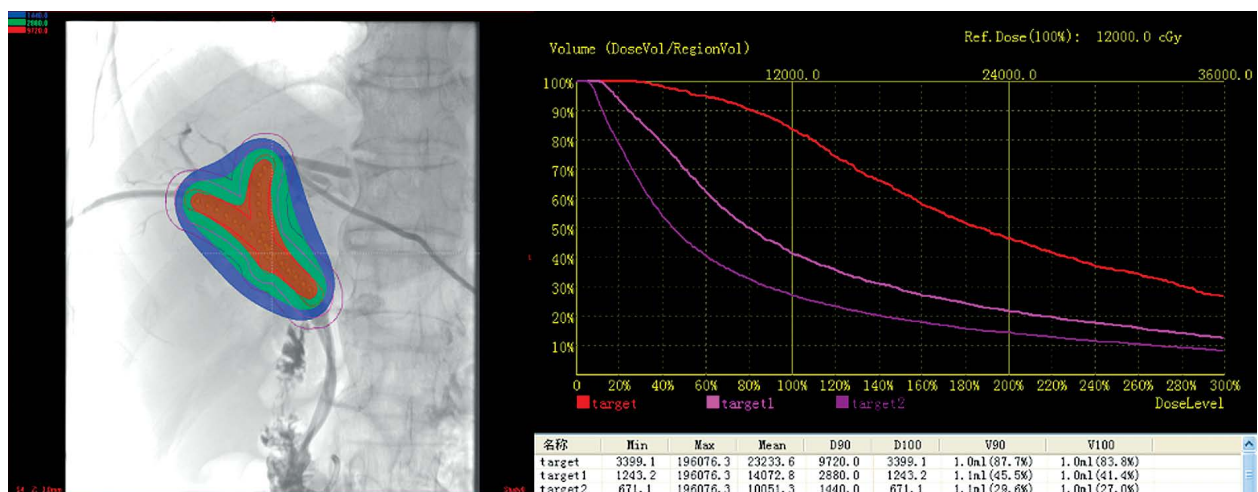


Fig. 4. Cumulative absorbed dose was analyzed according to the computerized treatment planning systems (TPS)

sues while minimizing injury to normal tissues, which requires less shield [9]. For example, cumulative absorbed dose at the 5 mm from the source axis was 97.2 Gy and it dropped rapidly to 28.8 Gy at the 10 mm from the source axis in this patient. Secondly, ^{125}I seeds are characterized by a long half-life (59.6 days), and this long half-life resulted in sustained injury to the tumor compared with the use of external irradiation. Thirdly, the ILBT can be stopped immediately when brachytherapy related complications occurred. In conclusion, a newly designed Y-shaped SEMS combined with two ^{125}I seed strands via bilateral approach represents a feasible treatment for patients with type IV Klatskin tumors, providing both brachytherapy and biliary drainage. Thus, this technique may provide a novel method for prolonging survival in these patients.

Acknowledgment

This work was supported by the National High-Tech Research and Development Program of China (863 Program) (grant number: 2015AA020301).

Disclosure

Authors report no conflict of interest.

References

1. Hong W, Sun X, Zhu Q. Endoscopic stenting for malignant hilar biliary obstruction: should it be metal or plastic and unilateral or bilateral? *Eur J Gastroenterol Hepatol* 2013; 25: 1105-1112.
2. Li J, Li T, Sun P et al. Covered versus Uncovered Self-Expandable Metal Stents for Managing Malignant Distal Biliary Obstruction: A Meta-Analysis. *PLoS One* 2016; 11: e0149066.
3. Kim DU, Kang DH, Kim GH et al. Bilateral biliary drainage for malignant hilar obstruction using the 'stent-in-stent' method with a Y-stent: efficacy and complications. *Eur J Gastroenterol Hepatol* 2013; 25: 99-106.
4. Mattiucci GC, Autorino R, Tringali A et al. A Phase I study of high-dose-rate intraluminal brachytherapy as palliative treatment in extrahepatic biliary tract cancer. *Brachytherapy* 2015; 14: 401-404.
5. Luo JJ, Zhang ZH, Liu QX et al. Endovascular brachytherapy combined with stent placement and TACE for treatment of HCC with main portal vein tumor thrombus. *Hepatol Int* 2016; 10: 185-195.
6. Yun JH, Jung GS, Park JG et al. Malignant hilar biliary obstruction: Treatment by means of placement of a newly Designed Y-shaped branched covered stent. *Cardiovasc Intervent Radiol* 2016; 39: 582-590.
7. Sun C, Yan G, Li Z et al. A meta-analysis of the effect of preoperative biliary stenting on patients with obstructive jaundice. *Medicine (Baltimore)* 2014; 93: e189.
8. Lee JM, Lee SH, Chung KH et al. Small cell- versus large cell-sized metal stent in endoscopic bilateral stent-in-stent placement for malignant hilarbiliary obstruction. *Dig Endosc* 2015; 27: 692-699.
9. Guinot JL, Ricós JV, Tortajada MI et al. Comparison of permanent (^{125}I) I seeds implants with two different techniques in 500 cases of prostate cancer. *J Contemp Brachytherapy* 2015; 7: 258-264.