

EXPRESSION OF SELECTED ADHESION MOLECULES IN DERMATITIS HERPETIFORMIS AND BULLOUS PEMPHIGOID

AGNIESZKA ŻEBROWSKA¹, ELŻBIETA WASZCZYKOWSKA², MAŁGORZATA WĄGROWSKA-DANILEWICZ³,
MARIAN DANILEWICZ³, ANNA ERKIERT-POLGUJ², RAFAŁ PAWLICZAK⁴, ANNA SYSA-JĘDRZEJOWSKA¹

¹Department of Dermatology and Venereology, Medical University of Lodz

²Laboratory of Immunodermatology, Department of Dermatology and Venereology,
Medical University of Lodz

³Laboratory of Nephropathology, Medical University of Lodz

⁴Department of Immunopathology, Faculty of Biomedical Sciences and Postgraduate Training,
Medical University of Lodz

Dermatitis herpetiformis (DH) and bullous pemphigoid (BP) are autoimmune diseases characterized by destruction of the basement membrane zone (BMZ) and anchoring fibres by autoantibodies and infiltration. Adhesion molecules can take part in these phenomena.

Skin biopsies were taken from 13 patients with DH, 21 with BP, and from 10 healthy subjects. The localization and expression of E and L selectins and $\beta 1$, $\beta 3$, $\beta 4$ integrins were studied by immunohistochemistry.

Expression of selectins was detected mainly in the skin leukocytes in all samples. Expression of $\beta 1$, $\beta 3$ integrins was detected mainly in basal keratinocytes. Expression of $\beta 4$ integrin was irregular and detected mainly in the blister.

Our results suggest that integrins and selectins may play an important role in the destruction of BMZ in DH and BP. The elucidation of the role of adhesion molecules in the pathogenesis of bullous diseases may be helpful in the development of new targeted therapies.

Introduction

Dermatitis herpetiformis (DH) is one of the subepidermal autoimmune bullous diseases characterized by skin and intestinal lesions. Skin lesions include polymorphic eruptions (papules, vesicles) accompanied by severe pruritus. Intestinal lesions are characterized by atrophy of intestinal villi resulting from immunological processes. In most cases intestinal disturbances are subclinical, but in a few patients they manifest with diarrhoea, malabsorption and loss of body weight. Diagnosis of dermatitis herpetiformis is established from the results of the direct immunofluorescence test (DIF) revealing granular deposits of IgA in the papillae and the presence of circulating IgA antibodies directed against endomysium and/or tissue and epidermal transglutaminase (tTG, eTG). Skin lesions in

dermatitis herpetiformis are histologically characterized by neutrophilic infiltrate leading to destruction of basement membrane zone (BMZ) proteins. Impairment of type IV collagen, laminin and entactin results in degradation of anchoring fibres and blister formation [1].

Recent literature data have shown that the main autoantigen in dermatitis herpetiformis is transglutaminase. This enzyme has probably two isoforms: tissue transglutaminase and epidermal transglutaminase [2, 3]. Binding of circulating complex of anti-tissue transglutaminase IgA antibodies with the antigen causes formation of deposits in skin papillae and activation of complement followed by influx of neutrophils, release of proinflammatory cytokines [4, 5] and overproduction of metalloproteinases [6].

Bullous pemphigoid (BP) is a blistering disease, characterized by inflammatory infiltrate in

the dermis, presence of IgG and C3 deposits along the basement membrane zone and circulating IgG autoantibodies. Autoantibodies binding to autoantigens localized in the basement membrane of the epidermis activate a series of immunological and enzymatic phenomena leading to destruction of basement membrane components and anchoring fibres and blister formation [7].

The main autoantigen in bullous pemphigoid is BPAG2 [8]. It is a key protein constituting the anchoring fibres responsible for adhesion of epidermis to the basement membrane. Structural studies have revealed that an extracellular fragment of (BPAG2) collagen XVII with COOH⁻ terminal collagenous domain connects the basement membrane with epidermal hemidesmosomes. The NC16A fragment of BPAG2, located within its extracellular fragment, is thought to be the most immunogenic part of the antigen [9].

Inflammatory infiltrates in the dermis, formed by neutrophils and eosinophils, and bound in vivo deposits along the basement membrane (BP) or neutrophils in the top of papillae (DH) are observed. Ultrastructural studies have also confirmed the presence of intensive inflammatory infiltrate at the dermo-epidermal junction, as well as destruction of hemidesmosomes and components of the extracellular matrix [7]. Formation of the infiltrates is preceded by early accumulation of leukocytes, depending on activity of adhesion molecules, especially selectins and integrins. The binding of autoantibodies leads to activation of keratinocytes, releasing interleukin 6 and interleukin 8, as well as activation of C5 component of the complement [9, 10]. Activated neutrophils migrate through blood vessels walls utilizing E and L selectins and secrete specific proteases digesting basement membrane proteins, especially collagen XVII and VII. Matrix metalloproteinases, released by inflammatory cells and keratinocytes, are finally responsible for blister formation [9, 10]. These enzymes are produced by eosinophils and neutrophils attracted to the basement membrane by selectins and integrins [8, 11].

Migration of cells from blood vessels into foci of inflammation consists of several phases. In each stage of this process different families of integrins are involved, β 1 and β 3 for example, responsible for rolling, adhesion, activation, binding and diapedesis of leukocytes. Subfamily β 1 integrins are involved mainly in the interactions between cells and connective tissue macromolecules (e.g. fibronectin, laminin, collagen); β 2 integrins are associated with cell-to-cell interactions, while β 3 integrins play a role in connections with ligands, such as fibrinogen, vitronectin, throm-

bospondin and von Willebrand factor [12, 13]. The β 4 integrin additionally is involved in connecting the filaments of the cell to the basement membrane and forming hemidesmosomes. Destruction of these hemidesmosomes is an essential process in the development of skin lesions in bullous pemphigoid [7].

Scarce literature data have revealed the role of certain adhesive molecules in the pathogenesis of dermatitis herpetiformis and bullous pemphigoid. The goal of the study was to investigate expression of selected integrins and selectins, and because of different inflammatory infiltrations in these diseases, to compare their expression in dermatitis herpetiformis and bullous pemphigoid.

Material and methods

Patients

The study included 13 untreated patients with dermatitis herpetiformis (5 women, 8 men, mean age 44.8 years; range: 18-58) in an active stage of the disease. Seven out of 13 patients had skin lesions characterized by vesicles and itching papules; the others had erythematous papules.

In all cases the histological pictures showed perivascular neutrophilic infiltrates, the presence of Pierrard's abscesses, and in all cases small subepidermal blisters. In 7/13 samples large unilocular blisters displaying multiple neutrophilic papillary microabscesses were found. The histopathological findings according to Ackerman in all cases were fully developed [14]. Direct immunofluorescence tests revealed the presence of granular deposits of IgA in skin papillae and indirect immunofluorescence tests were positive for IgAEmA (Oesophagus monkey IgAEmA, Medizinische Labordiagnostica) in all the patients (titre range 1 : 10 – 1 : 320, median 1 : 40). Anti-tissue transglutaminase antibodies measured using an immunoassay (Celikey, Pharmacia & Upjohn) were present in 4/13 cases (median 4.3 IU/ml). Diagnosis of dermatitis herpetiformis was established based on clinical presentation and results of histological and immunological examination [15].

Twenty-one untreated patients (15 women, 6 men, mean age 68.5 years, range: 58-84) with bullous pemphigoid entered the study. The patients were at an active stage of the disease, i.e. they presented with skin lesions (urticarial papules, vesicles, blisters).

Pemphigoid was diagnosed based on the clinical picture, and histological and immunological findings

[16]. Eleven out of 21 patients presented with skin blisters, vesicles and itching papules, whereas others had only small vesicles and urticarial papules. The histopathological findings according to Ackerman in all cases were fully developed. In all the patients direct immunofluorescence test revealed IgG/C3 linear deposits along BMZ. In the salt-split test deposits were observed in the epidermal part of the blister. Using the indirect immunofluorescence test circulating IgG antibodies were found in 17/21 patients. The anti-Nc16A autoantibodies were present in the serum of 19 out of 21 patients. Typical histological features of bullous pemphigoid including neutrophilic infiltrates, eosinophils, lymphocytes, and in 11 cases subepidermal blisters, supported the clinical diagnosis.

The control group consisted of 10 healthy individuals (5 women and 5 men, age between 19 and 49 years, mean age 42 years).

All study subjects signed informed consent before entering the study and the study protocol was approved by the Local Ethical Committee of the Medical University of Lodz.

Tissue specimens. The biopsies were taken from the buttock or trunk skin before administration of any (topical or systemic) treatment. The skin lesions had been developing for a period ranging from 2 weeks to 3 months. Additional biopsy specimens were taken from buttock skin from healthy volunteers, age and sex matched with the patient group.

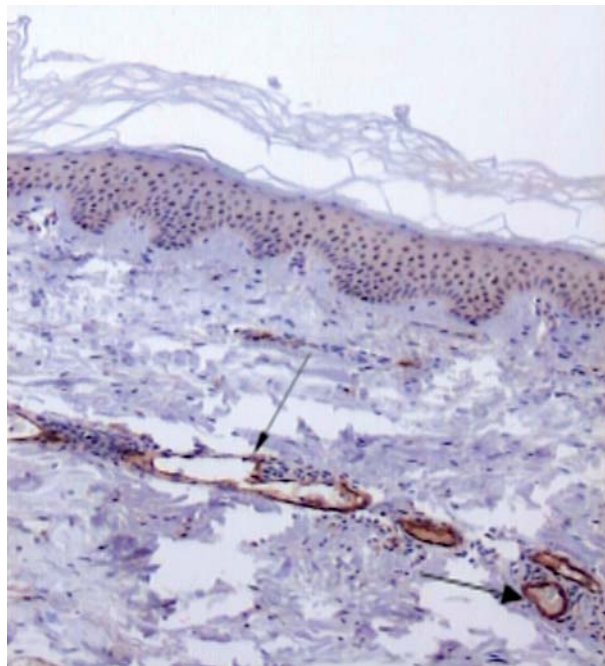


Fig. 1. Skin lesions. Bullous pemphigoid. Immunohistochemistry. Strong expression of E selectin (arrow – expression in endothelial cells). Original magnification 100 ×

Immunohistochemistry

Formalin-fixed, paraffin-embedded sections (3–4 µm) were used for routine H+E staining and for immunohistochemistry in the DAKO EnVision detection system using the immunoperoxidase method. The following primary monoclonal antibodies were used: anti-E selectins (16G4 clone), anti-L selectins (9H6 clone), anti-β1 (CD29, 2F10 clone), anti-β3 (CD61, 2f2 clone) and anti-β4 integrin (CD104, 4G2 clone) all obtained from Novocastra, United Kingdom.

For immunohistochemistry the paraffin-embedded section was placed on adhesive plates and dried at 56°C for 24 hours, and later deparaffinized in a series of xylenes and alcohols with decreasing concentrations (96%, 80%, 70%, 60%). Activity of endogenous peroxidase was inhibited with 3% hydrogen peroxide solution in methanol for 5 min.

In order to retrieve the antigenicity of tissues and allow them to react with antibodies, specific procedures were used for each of the tested antibodies, according to the manufacturer's instructions. After incubation with diluted antibodies for 60 min at room temperature, they were washed with TRIS buffer twice. The DAKO EnVision double-step visualization system was then applied in order to visualize the antigen-antibody reaction. In cases of positive immunohistochemical reaction cellular nuclei were stained with Meyer haematoxylin for 2 min. After dehydration and processing through a series of acetones and xylenes the sections were fixed in Canadian balm.

Expression of selectins and integrins was assessed by two independent pathologists using an Olympus BX 40 microscope (Japan). Magnification used was 100 × and 400 × respectively.

The semi-quantitative visual scale was employed to assess the intensity of E-selectin (CD62E), L-selectin (CD62L), integrin β1 (CD29), integrin β3 (CD61) and integrin β4 (CD104) expression. The scale range consists of 4 grades defined as follows: 0: no detection, 0.5: very weak intensity – immunohistochemical reaction was limited to very few epithelial cells, 1: weak intensity in more cells, 2: moderate intensity (immunohistochemical reaction was observed in part of epithelial cells and/or was present in some areas of the stroma) and 3: strong intensity – immunohistochemical reaction was observed in numerous epithelial cells and/or was present in large areas of the stroma.

All data are shown as mean ±SD. Student's t test was applied where appropriate after evaluation of distribution. The Mann-Whitney U test was used where appropriate. The diffe-

rence was considered statistically significant when $p < 0.05$.

Results

E-selectin (CD62E)

Expression of E-selectin was mostly detected in endothelial cells and neutrophils (Fig. 1). E-selectin expression was weaker in specimens taken from bullous pemphigoid patients as compared to in dermatitis herpetiformis subjects. Mean intensity of expression of E-selectin in pemphigoid patients was 1.05 ± 0.72 as compared to 1.73 ± 0.79 in subjects with dermatitis herpetiformis. The difference was statistically significant ($p < 0.03$) (Fig. 2). In skin biopsies taken from healthy subjects only single basal keratinocytes showed very weak expression of E-selectin.

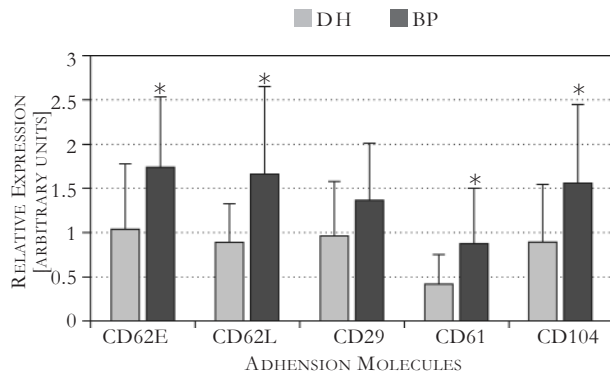


Fig. 2. Adhesion molecule expression in patients with bullous pemphigoid (open bars) and DH (closed bars). Semi-quantitative scale was applied to assess the expression (see Materials and methods section for details). Data (bars) are presented as mean \pm SD; * $p < 0.05$

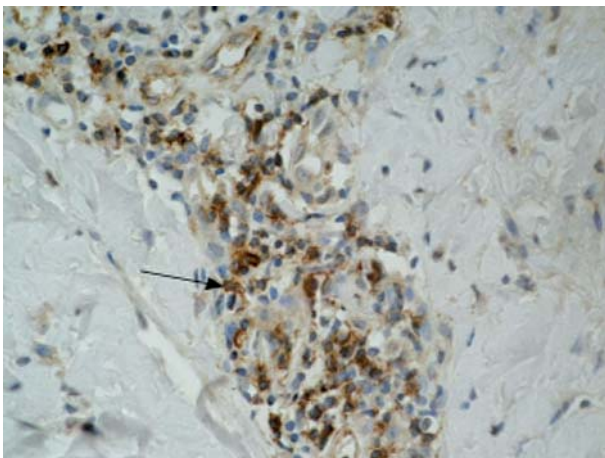


Fig. 3. Skin lesions. Dermatitis herpetiformis. Immunohistochemistry. Moderate expression of L selectin (arrow – expression in inflammation). Original magnification $400 \times$

L-selectin (CD62L)

L-selectin expression was detected on lymphocytes, macrophages and neutrophils (Fig. 3). L-selectin expression was weaker in specimens taken from patients with bullous pemphigoid as compared to biopsies done in dermatitis herpetiformis patients. Mean intensity of L-selectin

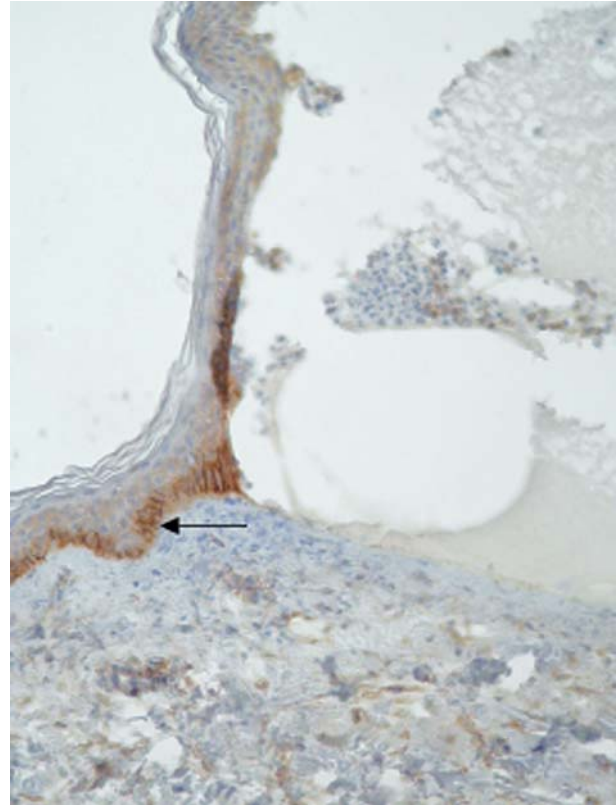


Fig. 4. Skin lesions. Bullous pemphigoid. Immunohistochemistry. Moderate expression of $\beta 1$ integrin in basal keratinocytes (arrow) and weak in the whole epidermis and blister fluid. Original magnification $100 \times$

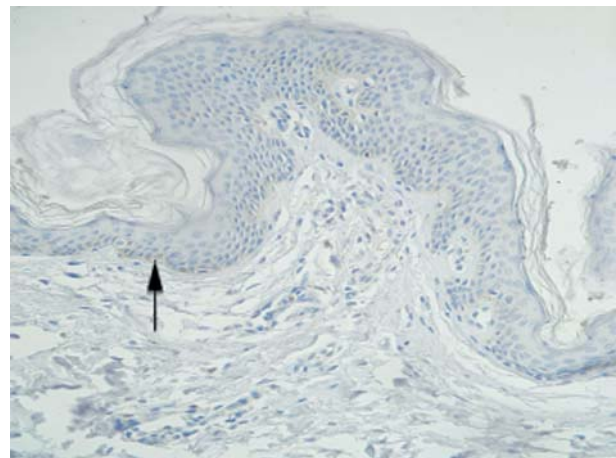


Fig. 5. Healthy skin. Immunohistochemistry. Signal for $\beta 1$ integrin in single keratinocytes (arrow). Original magnification $100 \times$

expression was 0.88 ± 0.44 in pemphigoid as compared to 1.64 ± 1.0 in dermatitis herpetiformis ($p < 0.006$). In tissue specimens from healthy controls only single basal keratinocytes showed very weak expression of L-selectin.

Integrin $\beta 1$ (CD29)

Integrin $\beta 1$ expression was detected in basal keratinocytes in all the dermatitis herpetiformis and bullous pemphigoid specimens (Fig. 4). In skin samples obtained from healthy volunteers expression was detected only in very few basal keratinocytes (Fig. 5). In skin samples from both bullous pemphigoid and dermatitis herpetiformis patients, Integrin $\beta 1$ positive staining was present and its insensitivity was assessed as: 0.95 ± 0.63 and 1.36 ± 0.64 ($p > 0.05$), respectively. Moreover, there was no difference in integrin $\beta 1$ expression in bullous pemphigoid as compared to dermatitis herpetiformis patients.

Integrin $\beta 3$ (CD61)

Integrin $\beta 3$ expression was not present in skin biopsy specimens obtained from healthy individuals. Basal keratinocytes stained positive for integrin $\beta 3$ in samples obtained from both bullous pemphigoid and dermatitis herpetiformis patients (Fig. 6). The mean intensity of integrin $\beta 3$ expression was lower in bullous pemphigoid patients (0.41 ± 0.34) than in subjects with dermatitis herpetiformis (0.86 ± 0.64 ; $p < 0.05$).

Integrin $\beta 4$ (CD104)

Integrin $\beta 4$ expression was detected in hemidesmosomes in skin biopsy specimens obtained

from control subjects as well as from both bullous pemphigoid and dermatitis herpetiformis patients. Mean intensity of integrin $\beta 4$ expression was statistically lower in patients with pemphigoid (0.88 ± 0.65) as compared to patients with dermatitis herpetiformis (1.54 ± 0.9 ; $p < 0.03$). Integrin $\beta 4$ expression was weak and regular in samples from healthy individuals, whereas its expression in samples from dermatitis herpetiformis and bullous pemphigoid patients was much stronger and irregular, mostly localized in the dermal part of the blister (Fig. 7).

Discussion

Blister formation in bullous diseases is initiated by accumulation of leucocytes, attracted by $\text{INF-}\alpha$, $\text{TNF-}\gamma$ and IL-2 secreted mainly by CD4+ T cells infiltrating the dermo-epidermal junction [17]. There are scarce data on the localization and intensity of expression of various adhesion molecules in skin lesions obtained from patients with dermatitis herpetiformis and bullous pemphigoid [18, 19].

E selectin is present on stimulated epithelial cells and its production is induced by lipopolysaccharide (LPS), thrombin, and cytokines such as IL-1 and $\text{TNF-}\alpha$ [12, 13]. E selectin expression seems to be a marker of endothelium activation and can be detected only in inflammatory processes in tissue specimens [12]. In some authors' opinion, basic fibroblast growth factor (bFGF) influences recruitment of leukocytes to extravascular milieu by enhancing E and P selectin expression [20].

In this study strong expression of E selectin in vascular walls and its moderate expression in

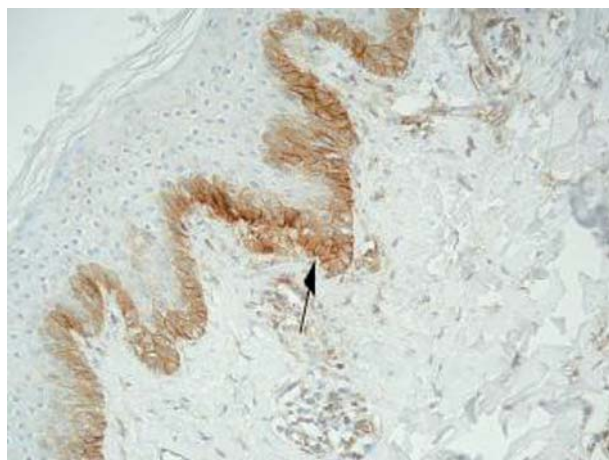


Fig. 6. Skin lesions. Dermatitis herpetiformis. Immunohistochemistry. Moderate expression of $\beta 3$ integrin in basal keratinocytes (arrow). Original magnification $100 \times$

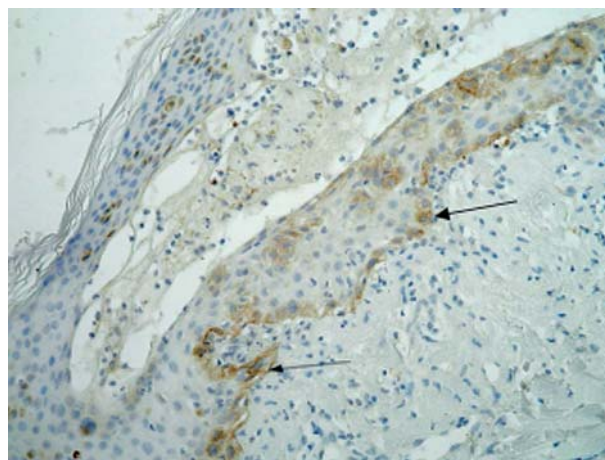


Fig. 7. Skin lesions. Bullous pemphigoid. Immunohistochemistry. Moderate expression of $\beta 4$ integrin in the dermal part of blister (arrow) and in blister fluid. Original magnification $100 \times$

leukocytes was found in dermatitis herpetiformis as well as in bullous pemphigoid skin biopsies. Its expression was significantly higher in DH, and this might be related to the intensity of neutrophilic infiltration in dermal papillae. In dermatitis herpetiformis patients microabscesses are often a hallmark of the disease. These results confirmed the role of E selectin in recruitment of immunocompetent cells to the sites of inflammation in bullous diseases.

Auria *et al.* found an increased sE selectin level in blood patients with autoimmune bullous diseases in contrast to healthy subjects [21]. There was a strong correlation between sE selectin levels and number of skin lesions in untreated patients. After initiation therapy the number of skin lesions and sE selectin levels decreased. This observation may suggest that sE selectin blood level can be a good marker of the effectiveness of the therapy. Interestingly, similar correlations were not present for any other adhesion molecules or their soluble forms [21]. Hall *et al.* confirmed an increased serum level of E selectin as well as increased level of E selectin mRNA in skin biopsies as evidence of endothelial cell activation in development of skin lesions in DH [22]. A correlation was found between E selectin expression on pericytes and disease activity in lesional skin and after methotrexate therapy the E selectin expression was significantly diminished [18].

L selectins are generally expressed on almost all leucocytes but disappear from their surface after stimulation. Leukocytes recruitment from the circulation into a site of inflammation is a multistep process regulated by L selectins. Leukocytes first tether and roll on vascular endothelial cells, before they are activated to adhere firmly and subsequently emigrate into the extravascular space. L selectin soluble forms may take part in adhesion regulation and forming a buffer system [12, 13].

According to these data, L selectin expression should not be present on activated leucocytes in dermatitis herpetiformis and bullous pemphigoid samples. Interestingly, we revealed L selectin expression in microabscesses in DH specimens and in eosinophilic and neutrophilic infiltration in BP biopsies. L selectins were expressed on lymphocytes, macrophages and neutrophils. The level of expression was significantly higher in tissues specimens taken from dermatitis herpetiformis patients. Its expression on inflammatory cells might be related to various stages of cell activation. In examined skin samples weak expression of L selectin was detected in the epidermis. It could be attributed to an inflam-

matory response of keratinocytes induced by the pathological process.

Smith *et al.* investigated L selectin expression on neutrophils in dermatitis herpetiformis patients with active, ongoing disease and quiescent disease activity using a fluorescence-activated cell sorter [19]. In contrast to our data L selectin expression in both groups of dermatitis herpetiformis patients was significantly lower than in controls. This may be related to the laboratory method used.

Further studies are needed to correlate tissue L selectin expression and sL selectin concentrations in peripheral blood in patients with bullous diseases.

Interactions between keratinocytes and structures of the basement membrane are crucial for the pathogenesis of autoimmune bullous diseases – pemphigoid and dermatitis herpetiformis.

Integrins are cell surface transmembrane glycoproteins that play a role as adhesion receptors transmitting biochemical and mechanical signals in a bidirectional manner across the cell membrane. Integrin expression in normal, undamaged epidermis is confined to the basal keratinocytes and the outer root sheath of the hair follicle. Keratinocytes exhibit a number of integrins, which are essential for their anchorage and migration. Some of them are constitutively expressed, while others are upregulated upon stimulation by wounding, pathological changes or culture [23-26].

Individual integrins can bind more than one ligand, and similarly, individual ligands are often recognized by more than one integrin [13, 25, 27]. The second important function of integrins is their role in signal transduction. Stimulation of different signalling pathways depends on the type of integrin, type of ECM attached and other external and internal factors such as: cytokines, growth factors, chemokines and other adhesive molecules [25, 28].

Although pathogenesis of dermatitis herpetiformis is still not fully elucidated, there is increasing evidence for a primary role of tissue transglutaminase (tTG). Recent studies suggest that formation of anti-tTG deposits antibody, activates the complement and leads to accumulation of neutrophils with subsequent inflammation and degradation of extracellular components [17, 29]. It is postulated that formation of blisters is stimulated by overexpression of local enzymes mediated by cytokines and adhesion molecules [30]. On the other hand, experimental studies have revealed that transglutaminase cross-linking to anchoring fibres in the epidermis also significantly

contributes to impairment of the dermo-epidermal junction (DEJ) [31].

According to our results, integrin expression is not restricted only to basal keratinocytes but the strongest expression was detected in this layer of the epidermis. Increased levels of integrins have also been demonstrated in blister fluid. Some authors have suggested that integrins attract neutrophils and they are involved in development of dermatitis herpetiformis skin lesions [19]. It is possible that integrin activities are the first factors of immunological processes leading to formation of abscesses in dermatitis herpetiformis lesions [8, 18, 32].

Integrins were first known for being involved in cell anchorage to the extracellular matrix (ECM), linking it to the cytoskeleton (fibronectin, vitronectin, collagen) by a short protein domain [12, 13].

Molecules of integrin $\beta 1$ often appear 2 to 7 weeks after lymphocytes stimulation. Most of them have a predilection to bind to laminin, fibronectin, collagen and another protein of ECM so that they may play an important role in the anchorage process [33]. Our results showed upregulated expression of $\beta 1$ integrin in dermatitis herpetiformis and bullous pemphigoid biopsies. In healthy skin this integrin expression is small and appears focally. During organization of an infiltrate and formation of vesicles in DH and BP expression of $\beta 1$ integrin was stronger and was detected in all basal keratinocytes. These data suggest that integrins may play a role in migration and cellular activation in inflamed tissue in patients with dermatitis herpetiformis and bullous pemphigoid.

Integrins in normal human keratinocytes are found focally in the basal layers and hair follicles but $\alpha 6\beta 4$ expression is restricted to the basal surface of resting epidermal cells confined to hemidesmosomes [34]. Other components of the hemidesmosomes include plectin, bullous antigen type 1 (BPAG1, 230 kD), bullous pemphigoid antigen 2 (BPAG2, 180 kD) and CD151 tetraspanin [35]. Laminin 5 and laminin 1 are the preferred extracellular ligands for $\alpha 6\beta 4$ integrin [36].

Antibodies binding to autoantigens localized in the skin basement membrane may activate a series of immunological and enzymatic phenomena that lead to destruction of hemidesmosomes. Integrin $\alpha 6\beta 4$ is a heterodimer taking part in linking filaments to the basement membrane and this integrin has a crucial role in formation of hemidesmosomes [37]. Antibodies against $\alpha 6\beta 4$ integrin abolish formation of hemidesmosomes and destroy existing hemidesmosome structures

[38]. The cytoplasmic domain of the $\beta 4$ subunit is essential for the formation and function of hemidesmosomes [38-40].

Kurpakus *et al.* monitored incorporation of $\alpha 6\beta 4$ integrin into hemidesmosomes in an in vitro wound-healing explants model [41]. Antibodies directed against the $\beta 4$ subunit do not interfere with the migration of epithelial cells but they induced disrupted established hemidesmosomes. Antibodies directed against the $\alpha 6$ subunit completely detach epithelial cells in the unwounded area of the explants [41].

Our results revealed linear and regular expression of $\beta 4$ integrin in healthy skin biopsies. This confirms constitutive expression of this adhesion molecule in anchoring fibres. However, this expression is enhanced in destroyed basement membrane in dermatitis herpetiformis and bullous pemphigoid. Cascade of cytokine and enzyme reaction mediated by autoantibodies may lead to basement membrane damage causing irregular and focal $\beta 4$ integrin expression in specimens from patients with dermatitis herpetiformis and bullous pemphigoid.

Integrin $\beta 3$ is a membrane glycoprotein predominantly expressed in platelets and megakaryocytes. Integrin $\beta 3$ is also associated with CD51 forming the vitronectin receptor, which is expressed in many tissues. Moreno *et al.* used a monoclonal antibody against integrin $\beta 3$ to study the distribution of this molecule in normal animal tissues [42]. Similarly, in humans, integrin $\beta 3$ was broadly expressed in all tissues. It has been suggested that expression of $\beta 3$ integrins may be enhanced in keratinocytes in some inflammatory disorders [43].

Our data confirm this hypothesis, showing positive staining for integrin $\beta 3$ in basal keratinocytes in healthy controls, while integrin $\beta 3$ was expressed in other layers of the epidermis in specimens taken from patients with bullous pemphigoid and dermatitis herpetiformis. Integrin $\beta 3$ expression was significantly lower in bullous pemphigoid samples where infiltration is usually smaller.

Adhesion molecule levels are increased in many inflammatory diseases [21, 44, 45]. Although integrins and selectins are probably involved in the development of skin lesions in dermatitis herpetiformis and bullous pemphigoid, their precise role in this process is not fully understood.

The elucidation of the role of inflammatory cells, their soluble mediators, adhesion molecules and signal transduction pathways in the pathogenesis of the diseases, may be helpful in the development of new targeted therapies. Extensive research has focused on modulating

activity of adhesive molecules. Among the new therapeutic modalities humanized monoclonal antibodies against adhesion molecules are in the early phase of clinical trials [46].

Impaired expression of selectins and integrins, stimulated by immune complexes present in structures of the basement membrane zone, may be responsible for destruction of anchoring fibres and blister formation. Although there are slight differences in expression of selectins and integrins in dermatitis herpetiformis and bullous pemphigoid, it is difficult to say that this is the cause of differences in inflammatory infiltration in these diseases. More studies focused on the precise role of adhesive molecules in pathogenesis of dermatitis herpetiformis and pemphigoid are needed to further elucidate the factors activating expression of selectins and integrins in bullous diseases.

Acknowledgments

We would like to thank Ms Grażyna Jastrzębska and Stanisława Madalińska for technical support. The authors state no conflict of interest.

This study was funded by the Medical University of Łódź, Poland, research projects 503-1019-1 and 503-8019-1, and Polish Government Grant 503-280-11.

References

1. Reunala T. Dermatitis herpetiformis. *Clin Dermatol* 2001; 19: 728-736.
2. Dietrich W, Ehnis T, Bauer M, et al. Identification of tissue transglutaminase as the autoantigen of celiac disease. *Nature Med* 1997; 3: 797-801.
3. Sardy M, Karpati S, Merkl B, et al. Epidermal transglutaminase (Tgase 3) is the autoantigen of dermatitis herpetiformis. *J Exp Med* 2002; 195: 747-757.
4. Zone JJ, Meyer L, Petersen M. Deposition of granular IgA relative to clinical lesions in dermatitis herpetiformis. *Br J Dermatol* 1994; 131: 822-826.
5. Caproni M, Feliciani C, Fuligni A, et al. Th2 – like cytokine activity in dermatitis herpetiformis. *Br J Dermatol* 1998; 138: 242-247.
6. Oikarinen AI, Reunala T, Zone JJ, et al. Proteolytic enzymes in blister fluids from patients with dermatitis herpetiformis. *Br J Dermatol* 1986; 114: 295-302.
7. Jordan RE. Basement zone antibodies in bullous pemphigoid. *JAMA* 1967, 200: 751-756.
8. Stanley JR. Cell adhesion molecules as targets of autoantibodies in pemphigus and pemphigoid, bullous diseases due to defective epidermal cell adhesion. *Adv Immunol* 1992; 53: 291-325.
9. Schmidt E, Obe K, Bocker EB, Zillikens D. Serum levels of autoantibodies to BP 180 correlate with disease activity in patients with bullous pemphigoid. *Arch Dermatol* 2000; 136: 253-254.
10. Stähle-Bäckdahl M, Inoue M, Guidice GJ, Parks WC. 92-kD gelatinase is produced by eosinophils at site of blister formation in bullous pemphigoid and cleaves the extracellular domain of recombinant 180-kD bullous pemphigoid antigen. *J Clin Invest* 1994; 93: 2022-2030.
11. Verraes S, Hornebeck W, Polette M, et al. Respective contribution of neutrophil elastase and matrix metalloproteinase 9 in the degradation of BP180 (type XVII collagen) in human bullous pemphigoid. *J Invest Dermatol* 2001; 117: 1091-1096.
12. Springer TA. Adhesion receptors of the immune system. *Nature* 1990; 346: 425-434.
13. Freemont AJ. Demystified adhesion molecules. *Mol Pathol* 1998; 51: 175-184.
14. Ackerman AB, Chongchitnant N, Sanchez J, et al. *Histologic Diagnosis of Inflammatory Skin Disease: A Algorithmic Method Based on Pattern Analysis*. Second Edition ed. Williams & Wilkins Baltimore 1997.
15. Chorzelski T, Beutner EH, Jablonska S, et al. Immunofluorescence studies in the diagnosis of dermatitis herpetiformis and its differentiation from bullous pemphigoid. *J Invest Dermatol* 1971; 56: 373-380.
16. Gammon WR, Kowalewski C, Chorzelski TP, et al. Direct immunofluorescence studies of sodium chloride-separated skin in the differential diagnosis of bullous pemphigoid and epidermolysis bullosa acquisita. *J Am Acad Dermatol* 1990; 22: 664-670.
17. Graeber M, Baker BS, Garioch JJ, et al. The role of cytokines in the generation of skin lesions in dermatitis herpetiformis. *Br J Dermatol* 1993; 129: 530-532.
18. Dahlman-Ghozlan K, Heilborn JD, Stephansson E. Circulating levels of soluble E-selectin, ICAM-1 and VCAM-1 in bullous pemphigoid during low-dose methotrexate therapy. A prospective study. *Exp Dermatol* 2000; 9: 336-340.
19. Smith AD, Streilein RD, Hall RP 3rd. Neutrophil CD11b, L-selectin and Fc IgA receptors in patients with dermatitis herpetiformis. *Br J Dermatol* 2002; 147: 1109-1117.
20. Zittermann SI, Issekutz AC. Basic fibroblast growth factor (bFGF, FGF-2) potentiates leukocyte recruitment to inflammation by enhancing endothelial adhesion molecule expression. *Am J Pathol* 2006; 168: 835-846.
21. D'Auria L, Cordiali Fei P, Pietravalle M, et al. The serum levels of sE-selectin are increased in patients with bullous pemphigoid or pemphigus vulgaris. Correlation with the number of skin lesions and recovery after corticosteroid therapy. *Br J Dermatol* 1997; 137: 59-64.
22. Hall RP3rd, Takeuchi F, Benbenisty KM, Streilein RD. Cutaneous endothelial cell activation in normal skin of patients with dermatitis herpetiformis associated with increased serum levels of IL-8, sE-selectin and TNF-alpha. *J Invest Dermatol* 2006; 126: 1331-1337.
23. Hynes RO. Integrins: Versatility, modulation and signaling in cell adhesion. *Cell* 1992; 69: 11-25.
24. Ginsberg MH, Du X, Plow EF. Inside-out integrin signaling. *Curr Opin Cell Biol* 1992; 4: 766-771.
25. Bouvard D, Brakebusch C, Gustafsson E, et al. Functional consequences of integrin gene mutations in mice. *Circ Res* 2001; 89: 211-223.
26. Watt FM. Role of integrins in regulating epidermal adhesion, growth and differentiation. *EMBO J* 2002; 21: 3919-3926.
27. Stepp MA, Spurr-Michaud S, Tisdale A, et al. a6b4 integrin heterodimer is a component of hemidesmosomes. *Proc Natl Acad Sci* 1990; 87: 8970-8974.
28. O'Toole TE, Katagiri Y, Faull RJ, et al. Integrin cytoplasmic domains mediate inside-out signal transduction. *J Cell Biol* 1994; 124: 1047-1059.
29. Dahl M, Falk J, Carpenter R, Michael AF. Membrane attack complex of complement in dermatitis herpetiformis. *Arch Dermatol* 1985; 121: 70-72.
30. Petersen MJ, Woodley DT, Stricklin GP, O'Keefe EJ. Production of procollagenase by cultured human keratinocytes. *J Biol Chem* 1987; 262: 835-840.
31. Aeschliman D, Paulsson M. Cross-linking of laminin-nidogen complexes by tissue transglutaminase. A novel mechanism for basement membrane stabilization. *J Biol Chem* 1991; 266: 15308-15317.

32. Airola K, Reunala T, Salo S, Saarialho-Kere UK. Urokinase plasminogen activator is expressed by basal keratinocytes before interstitial collagenase, stromelysin 1 and laminin 5 in experimentally induced dermatitis herpetiformis lesions. *J Invest Dermatol* 1997; 108: 7-11.
33. Hynes RO. Integrins: bidirectional, allosteric signaling machines. *Cell* 2002; 110: 673-687.
34. Stupack DG, Cheresh DA. Get a ligand, get a life: integrins, signaling and cell survival. *J Cell Sci* 2002; 115: 3729-3738.
35. Sterk LM, Geuijen CA, Oomen LC, et al. The tetraspan molecule CD151, a novel constituent of hemidesmosomes, associates with the integrin alpha6beta4 and may regulate the spatial organization of hemidesmosomes. *J Cell Biol* 2000; 149: 969-982.
36. Marchisio PC, Bondanza S, Cremona O, et al. Polarized expression of integrin receptors and their relationship with the cytoskeleton and basement membrane matrix in cultured human keratinocytes. *J Cell Biol* 1991; 112:761-773.
37. Eody RA. The hemidesmosome: a target in autoimmune bullous disease. *Dermatology* 1994; 189: 38-41.
38. Borradori L, Koch PJ, Niessen CM, et al. The localization of bullous pemphigoid antigen 180 (BP180) in hemidesmosomes is mediated by its cytoplasmic domain and seems to be regulated by the beta4 integrin subunit. *J Cell Biol* 1997; 136: 1333-1347.
39. Leverkus M, Bhol K, Hirako YI, et al. Cicatricial pemphigoid with circulating autoantibodies to beta4 integrin, bullous pemphigoid 180 and bullous pemphigoid 230. *Br J Dermatol* 2001; 145: 998-1004.
40. Schaapveld RQJ, Borradori L, Geerts D, et al. Hemidesmosome formation is initiated by the beta 4 integrin subunit, requires complex formation of beta 4 and HD1/Plectin and involves a direct interaction between beta 4 and the bullous pemphigoid Antigen 180. *J Cell Biol* 1998; 142: 271-284.
41. Kurpakus MA, Quaranta V, Jones JC. Surface relocation of alpha6beta4 integrins and assembly of hemidesmosomes in an in vitro model of wound healing. *J Cell Biol* 1991; 115: 1737-1750.
42. Merono A, Lucena C, López A, et al. Immunohistochemical analysis of beta 3 integrin (CD61): expression in pig tissues and human tumors. *Histol and Histopath* 2002; 17: 347-352.
43. Liu KY, Timmons S, Lin YZ, Hawiger J. Identification of a functionally important sequence in the cytoplasmic tail of integrin beta3 by using cell-permeable peptide analogs (signal transduction/cell adhesion/glycoprotein IIb-IIIa/peptide delivery). *Proc Natl Acad Sci U S A* 2000; 93: 11819-11824.
44. de Vries IJ, Langeveld-Wildschut EG, van Reijssen FC, Bihari IC. Nonspecific T-cell homing during inflammation in atopic dermatitis: expression of cutaneous lymphocyte-associated antigen and integrin alphaE beta7 on skin-infiltrating T cells. *J Allergy Clin Immunol* 1997; 100: 694-701.
45. Agarwal SK, Brenner MB. Role of adhesion molecules in synovial inflammation. *Curr Opin Rheumatol* 2006; 18: 268-276.
46. Liu Z, Zhao M, Li N, et al. Differential roles for beta 2 integrins in experimental autoimmune bullous pemphigoid. *Blood* 2006; 107: 1063-1039.

Address for correspondence

Agnieszka Żebrowska MD, PhD
Department of Dermatology and Venereology,
Medical University of Lodz
ul. Krzemieniecka 5
94-017 Łódź
phone/fax +48 42 6864565
e mail: zebrowskaaga@wp.pl