

COLLISION TUMOUR OF THE STOMACH – ADENOCARCINOMA AND NEUROENDOCRINE CARCINOMA: CASE REPORT AND REVIEW OF THE LITERATURE

ANDRZEJ MRÓZ^{1,2}, MIROSLAW KIEDROWSKI^{1,2}, MAŁGORZATA MALINOWSKA², RAFAŁ SOPYŁO³

¹Department of Gastroenterology and Hepatology, Medical Centre for Postgraduate Education, Warsaw

²Department of Pathology, Maria Skłodowska-Curie Memorial Cancer Center and Institute of Oncology, Warsaw

³Department of Brachytherapy, Maria Skłodowska-Curie Memorial Cancer Center and Institute of Oncology, Warsaw

We report a rare case of gastric collision tumour composed of poorly differentiated adenocarcinoma and neuroendocrine carcinoma in a 56-year-old Caucasian male. The tumour was located in the gastric body and, to our knowledge, it is the tenth case described in the literature and the first in Poland. The adenocarcinoma component constituted 20% of the lesion and was in a more advanced stage than the neuroendocrine component. Additionally, the adenocarcinoma was the only one to metastasize to regional lymph nodes and the liver. The controversies regarding nomenclature of such lesions are discussed and a review of the literature is presented.

Key words: gastric adenocarcinoma, neuroendocrine carcinoma, collision tumour, composite tumour, stomach

Introduction

Adenocarcinoma is the most common malignant neoplasm of the stomach. It is not unusual to find neuroendocrine differentiation within typical glandular histology. In the cases when 2 types of tissue are intermingled within the same tumour, the term “composite” is used, while when 2 elements are adjacent to one another without intermixing, the term “collision” is generally accepted.

Most collision tumours of the stomach consist of epithelial and non-epithelial components – the latter being most commonly lymphoma followed by stromal tumours. The combination of adenocarcinoma and neuroendocrine elements seems to be an unusual finding among collision tumours of the stomach. Furthermore, it is of great importance to clearly emphasize that all tumours without a sharp, clear-cut interface between histological patterns should be excluded from this category and treated as mixed neoplasms, which is still not unequivocally accepted.

We report a case of a gastric collision tumour that consisted of adenocarcinoma and neuroendocrine carcinoma. To our knowledge it is the tenth such case described in the literature, the third in the Western World and the first in Poland.

Report of a case

A 56-year-old Caucasian male was admitted to the surgical clinic of the Maria Skłodowska-Curie Memorial Institute Cancer Centre in Warsaw with a history of gastric pain of 3 months duration. Within this period he lost 4 kg and no other complaints were reported. His family history was relevant and revealed that his mother died of gastric carcinoma and his father of lung cancer. On admission moderate anaemia was noted with Hb 10 g/l, haematocrit of 33-35% and slight elevation of aspartate transaminase to 40 IU/l. Other blood and urine biochemical analyses were within normal ranges.

The patient underwent endoscopic examination of the upper and lower gastrointestinal tract, which

displayed a blastomatic, slightly elevated lesion located on the greater curvature and posterior wall of the stomach. The tumour was solid with marked contact bleeding, and a noticeable amount of blood was observed in the lumen. Several tissue samples were collected according to the standard procedure and the pathological diagnosis of poorly differentiated adenocarcinoma was established.

Colonoscopy was unremarkable. On computed tomography of the abdominal cavity there was a hypodense lesion of 22 mm diameter in the liver, suspicious of metastasis. In addition small cortical cysts of the kidneys were found. No signs of lymphadenopathy were noted.

The patient underwent total gastrectomy with Roux-en-Y anastomosis. Postoperative recovery was uneventful and after a 2-month interval, according to the histopathological diagnosis, he was included in an adjuvant chemotherapy scheme.

Pathological findings

On macroscopic inspection a Bormann type 3 tumour partly exophytic with ulcerated area, 8.5 cm in diameter, located in the gastric body and partly the cardiac region, focally penetrating to the subserosa, was found. On the cut surface the tumour showed mainly white with yellowish areas. Grossly no features of necrosis or haemorrhages could be observed. Forty four lymph nodes were submitted along with the specimen to the pathology laboratory. In addition, a fragment of hepatic tissue with a white, round, subcapsular nodule 3.5 cm in diameter was delivered.

Microscopic examination of routine haematoxylin-eosin stained slides revealed two distinct types of neoplastic proliferation, one of them presenting poorly differentiated adenocarcinoma of mixed Lauren

type. The second component consisted of smaller, round and slightly elongated cells (Fig. 1, 2) with inconspicuous nucleoli and dispersed chromatin, arranged in nests, sheets and glandular-like structures. These cells were positive for chromogranin and synaptophysin immunostains (Dako cytometry). Mitotic activity index (Ki 67) reached 70% of nuclei. According to the Polish Network of Neuroendocrine Tumours, poorly differentiated neuroendocrine carcinoma G3 (WHO group 3, pT2) was diagnosed. No intermingling areas of neoplastic patterns were observed at the interface of growth and no foci of opponent type differentiation within the tumours. Mitotic activity was high in both parts. The adenocarcinoma, which constituted about 20% of the tumour, deeply invaded the gastric wall and disruption of the serosa was noted as well as angioinvasion and infiltration of perineural spaces. Neuroendocrine carcinoma penetrated no deeper than the muscularis propria. In 22 of 41 lymph nodes adenocarcinoma metastases were found (CK positive, synaptophysin and chromogranin negative) (Fig. 3). Similarly, solely adenocarcinoma of the stomach metastasized to the liver with the same immunoprofile. Based on the above findings collision tumour of the stomach consisting of poorly differentiated adenocarcinoma and poorly differentiated neuroendocrine carcinoma was diagnosed.

Gastric mucosa from non-neoplastic areas displayed focally intestinal metaplasia with no pronounced atrophic pattern.

Discussion

As described in the literature collision tumours of the gastrointestinal tract are rare. Most of them consist of epithelial and non-epithelial components, while it can be stated that cases of collision tumours

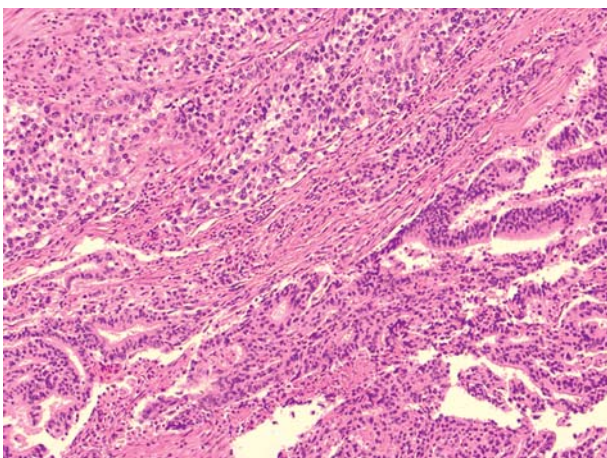


Fig. 1. Hematoxylin-eosin stain. Neuroendocrine carcinoma (top) and adenocarcinoma (bottom). Interface. Magnification 100 ×

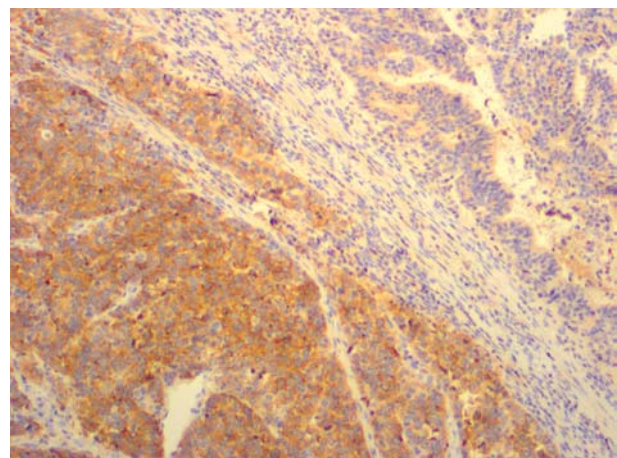


Fig. 2. Collision tumour – synaptophysin stain. Magnification 100 ×

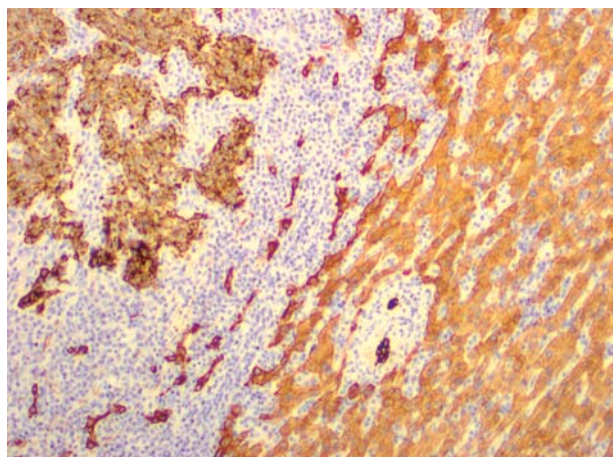


Fig. 3. Metastasis of adenocarcinoma in the liver – cytokeratin 7 stain. Magnification 100 ×

composed of adenocarcinoma and neuroendocrine tumour are exceptional. Our case is only the tenth described thus far and the third in Western countries. It may potentially reflect the general lower frequency of stomach cancers in comparison with the Far and Middle East. Apart from the stomach also single cases have been described in other segments of the gastrointestinal tract, e.g. the oesophagus, Vater ampulla, ileum and colon. Gonzalez *et al.* depicted an oesophageal collision tumour of adenocarcinoma and oat cell carcinoma patterns, presenting in the background of Barrett's oesophagus [1]. A similar combination existed also in the ileum, as described by Van Kerckhove [2]. A better differentiated component of neuroendocrine tumour coexisted with adenocarcinoma in the Vater ampulla as well as in the colon [3, 4]. Still, these are only anecdotal reports. In contrast, in a summary prepared by Mardi *et al.* gastric collision tumours were usually composed of epithelial and non-epithelial malignant components, most of 34 cases being adenocarcinoma and lymphoma [5].

There are some controversies regarding the pathomechanism of adenocarcinoma/neuroendocrine carcinoma collision tumour development. According to the first hypothesis the neuroendocrine component differentiates from the adenocarcinoma during tumorigenesis, whereas the second theory states that the adenocarcinoma and neuroendocrine carcinoma arise from a multipotential epithelial stem cell and a primitive neuroendocrine cell, respectively, and they exist next to each other coincidentally [6].

As Lewin and Appelman proposed, mixed neuroendocrine and conventional carcinomas of the stomach should be classified into one of five distinct groups. These include: carcinomas with interspersed neuroendocrine cells, composite glandular-endocrine carcinomas, collision tumours, amphicrine tumours,

and combinations of the above [7]. More recently Fujiyoshi *et al.* reclassified the mixed endocrine and non-endocrine epithelial tumours into six categories. These included: neuroendocrine cells interspersed within carcinomas, carcinoids (neuroendocrine tumours/NET) with interspersed non-endocrine cells, composite glandular-neuroendocrine cell carcinomas containing both areas of carcinoid and conventional carcinoma, collision tumours in which neuroendocrine tumours and conventional carcinomas are closely juxtaposed but not admixed, amphicrine tumours predominantly composed of cells exhibiting concurrent neuroendocrine and non-endocrine differentiation, and combinations of the previous types [8].

We believe that these classifications are too complicated and do not point out clearly enough the dualistic nature of collision tumours. Moreover they could be confusing for clinicians and do not reflect their needs in terms of leading to the correct therapeutic options. That is why we suggest simplifying the issue by reverting to the previously advocated binomial classification. Every case with any degree of intermixing adenocarcinoma and neuroendocrine carcinoma pattern should be designated a "mixed" or "composite" tumour as synonyms, while two separate, sharply delineated compounds should be regarded as a "collision" tumour – as previously proposed by Yamashina, Corsi and others [9, 10]. Additionally, attention must be paid to the proper nomenclature of the neuroendocrine component. According to the current WHO classification and Polish consensus on stomach and duodenum endocrine tumours, the designation of carcinoid tumour should be replaced with neuroendocrine tumour – neuroendocrine carcinoma sequence terms [11, 12].

In our opinion a matter of serious debate is the possible diagnostic confusion in preoperative endoscopic biopsies. Such a collision tumour might be erroneously diagnosed as a neuroendocrine carcinoma only, depending on the biopsied site, which could possibly change the clinical approach. On the other hand, the adenocarcinoma component seems to have a major impact on disease stage and patient outcome. Indeed, similarly as in previous cases [5, 13] only the adenocarcinoma component metastasized, which was immunohistochemically confirmed. The adenocarcinoma component constituted only 20% of the tumour; nevertheless its extension was significantly deeper than the neuroendocrine carcinoma.

Adenocarcinoma most probably has a major impact on prognosis and postoperative follow-up, which possibly is not different than for adenocarcinoma alone. In contrast, if the metastatic disease is caused by the neuroendocrine component,

Table I. Summary of case reports on gastric collision tumours (adenocarcinoma and the neuroendocrine component)

CASE NO.	AGE/SEX	LOCATION	EPITHELIAL COMPONENT	NON-EPITHELIAL COMPONENT	LITERATURE
1.	50/M	Middle body	Adenocarcinoma	Carcinoid	Yamashina and Flinner, 1985
2.	69/F	Body	W/D adenocarcinoma	Carcinoid	Chodankar <i>et al.</i> , 1989
3.	49/M	Upper body	M/D adenocarcinoma	Carcinoid	Morishita <i>et al.</i> , 1991
4.	72/M	Unknown	M/D adenocarcinoma	Carcinoid	Corsi and Bosman, 1995
5.	66/M	Cardia	Adenocarcinoma	Carcinoid	Mohinelo <i>et al.</i> , 1997
6.	84/F	Cardia	M/D adenocarcinoma	Carcinoid	Morishita <i>et al.</i> , 2004
7.	48/M	Pylorus	M/D adenocarcinoma	Carcinoid	Jayaraman <i>et al.</i> , 2005
8.	47/F	Pylorus	M/D adenocarcinoma	Carcinoid	Mardi <i>et al.</i> , 2008
9.	57/?	Antrum	M/D adenocarcinoma	Carcinoid	Jeong <i>et al.</i> , 2008
10.	56/M	Body	P/D adenocarcinoma	Neuroendocrine carcinoma	present case, 2009

the prognosis seems to be a bit more favourable [19]. Currently our patient is being given adjuvant chemotherapy, which is well tolerated. However, the period of observation is too short to make any final statements about his outcome.

References

- González LM, Sanz-Esponera J, Saez C, et al. Case report: esophageal collision tumor (oat cell carcinoma and adenocarcinoma) in Barrett's esophagus: immunohistochemical, electron microscopy and LOH analysis. *Histol Histopathol* 2003; 18: 1-5.
- Van Kerkhove F, Coenegrachts K, Steyaert L, et al. Collision tumor in the ileum: a rare combination of an adenocarcinoma and small cell neuroendocrine tumor. *JBR-BTR* 2006; 89: 258-260.
- Ferrando Marco J, Pallas Regueira A, Moro Valdezate D, Fernández Martínez C. Collision tumor of the ampulla of Vater: carcinoid and adenocarcinoma. 2007; 99: 235-238
- Olinici CD, Domæa I, Crişan D. Collision adenocarcinoma – carcinoid tumor of the colon. Case report and review of the literature. *Rom J Morphol Embryol* 2007; 48: 75-78.
- Mardi K, Sharma J, Gupta S. Gastric collision tumor: a rare case of an adenocarcinoma and carcinoid tumor. *The Internet Journal of Gastroenterology* 2009; 7: 2.
- Lyda MH, Fenoglio-Preiser CM. Adenoma-carcinoid tumors of the colon. *Arch Pathol Lab Med* 1998; 122: 262-265.
- Fujiyoshi Y, Kuhara H, Eimoto T. Composite glandular-endocrine cell carcinoma of the stomach. Report of two cases with goblet cell carcinoid component. *Path Res Pract* 2005; 823-829.
- Lewin KJ, Appelman HD. Endocrine cell proliferation of the stomach. In: *Tumor of the Esophagus and Stomach*. Rosai J (ed.). Armed Forces Institute of Pathology Washington, DC 1996; 331-356.
- Yamashina M, Flinner RA: Concurrent occurrence of adenocarcinoma and carcinoid tumor in the stomach: a composite tumor or collision tumors? *Am J Clin Pathol* 1985; 83: 233-236.
- Corsi A, Bosman C. Adenocarcinoma and atypical carcinoid: morphological study of a gastric collision-type tumour in the carcinoma-carcinoid spectrum. *Ital J Gastroenterol* 1995; 27: 303-308.
- World Health Organization Classification of Tumors. Pathology and Genetics of Tumours of Endocrine Organs. DeLellis RA, Lloyd RV, Heitz PU, Eng C (Eds.). IARC Press, Lyon 2004.
- Endocrine tumors of the stomach and duodenum (including gastrinoma) – management guidelines (recommended by the Polish Network of Neuroendocrine Tumors). *Endokrynol Pol* 2008; 59: 57-67.
- Morishita Y, Sugitani M, Sheikh A, et al. Collision tumor of the stomach – a rare case of an adenocarcinoma and carcinoid tumor. *Arch Pathol Lab Med* 2005; 129: 407-409.
- Chodankar CM, Pandit SP, Motiwale SS, Deodhar KP. Collision tumor of stomach. *Indian J Gastroenterol* 1989; 8: 297-298.
- Morishita Y, Tanaka T, Kato K, et al. Gastric collision tumor (carcinoid and adenocarcinoma with gastritis cystica profunda). *Arch Pathol Lab Med* 1991; 115: 1006-1010.
- Mohinelo C, Requena M, Zaragoza M, et al. Tumor de colision gastrico con metaplasia osea. *Rev Esp Enf Digest* 1997; 89: 317-319.
- Jayaraman A, Ramesh S, Jeyasingh R, Bagyalakshmi KR. Gastric collision tumor – a case report. *Indian J Pathol Microbiol* 2005; 48: 264-265.
- Jeong SW, Kim YS, Cho JY, et al. A Case study of a gastric collision tumor with an adenocarcinoma and a carcinoid tumor. *Korean J Gastrointest Endosc* 2008; 36: 159-164.
- Nugent SL, Cunningham SC, Alexiev BA, et al. Composite signet-ring cell/neuroendocrine carcinoma of the stomach with a metastatic neuroendocrine carcinoma component: a better prognosis entity. *Diagn Pathol* 2007; 2: 43.

Address for correspondence

Andrzej Mróz MD, PhD
 Department of Gastroenterology and Hepatology
 Medical Centre for Postgraduate Education
 ul. Roentgena 5
 02-781 Warszawa
 phone +48 22 546 23 28
 fax +48 22 546 29 84
 e-mail: amroz@fedor.pl