

QUIZ

WHAT IS YOUR DIAGNOSIS?

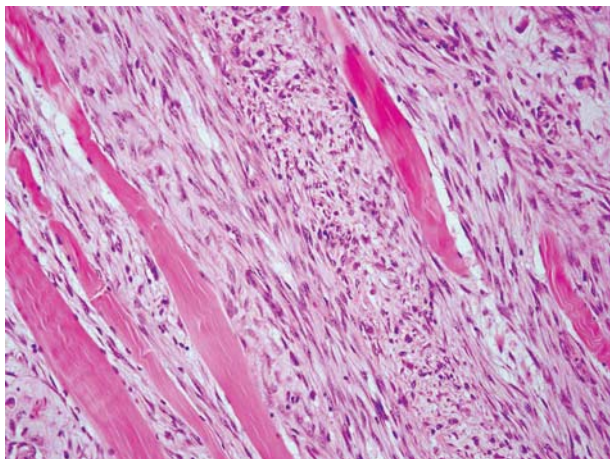


Fig. 1

A 53-year-old woman was admitted to the hospital because of a calf tumour noticed 2 months earlier. There was no obvious history of a previous injury. Macroscopically, within the gastrocnemius muscle, an ill-defined tumour, 3 × 2.5 cm in size, was found (Fig. 1-5).

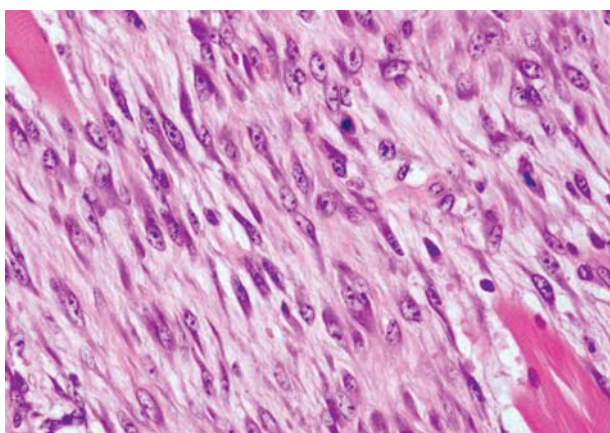


Fig. 2

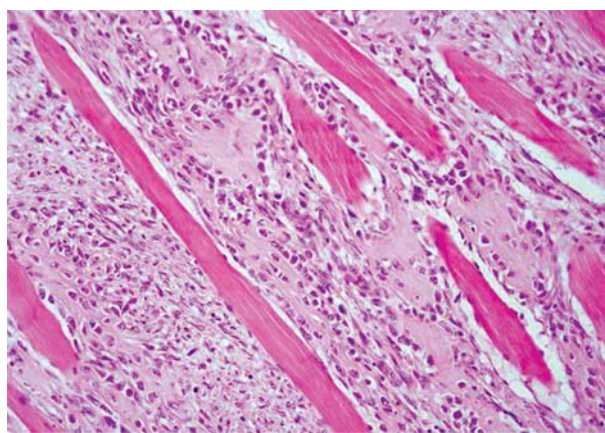


Fig. 4

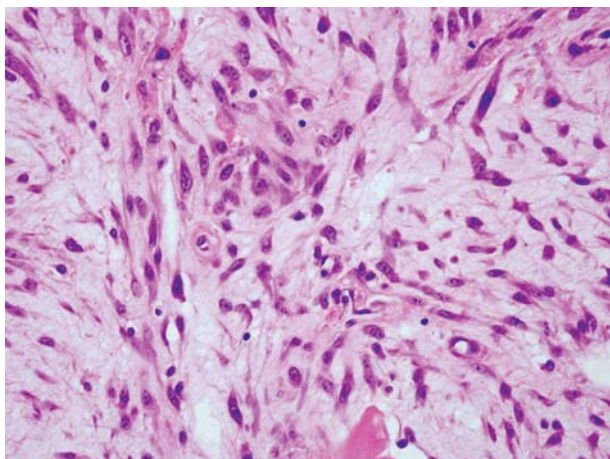


Fig. 3

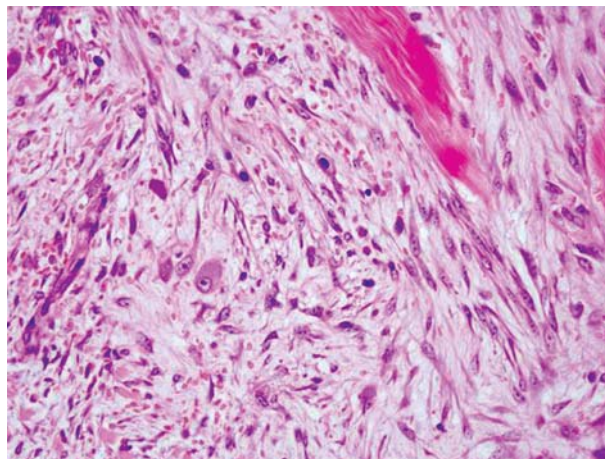


Fig. 5

Janusz Ryś¹, Andrzej Gruchała¹, Elżbieta Korobowicz²

¹Department of Tumour Pathology, Centre of Oncology Maria Skłodowska-Curie Memorial Institute, Cracow Branch, ul. Garncarska 11, 31-115 Kraków, phone +48 12 421 20 98, e-mail: z5rys@cyf-kr.edu.pl

²Department of Clinical Pathomorphology, Medical University of Lublin

Answers should be sent to the Editorial Office by 30.09.2009. The correct answer will be announced in the next issue of the *Polish Journal of Pathology*. All participants with the highest number of correct answers to the quizzes published in vol. 60 (4 issues) will be entered into the prize draw for a book.