

## SEGMENTAL CONGENITAL DEFECT OF THE INTESTINAL MUSCULATURE

MONIKA DZIENIECKA<sup>1</sup>, ADRIANA GRZELAK-KRZYMIAŃSKA<sup>2</sup>, ANDRZEJ KULIG<sup>1</sup>

<sup>1</sup>Department of Clinical Pathomorphology, Research Institute Polish Mother's Memorial Hospital, Łódź

<sup>2</sup>Medical University of Łódź, Foreign Language Teaching Centre, Łódź

---

Congenital defect of the small intestine muscular layer is rare cause of spontaneous bowel perforation or obstruction in premature infants. Etiology is still unknown. The authors report one case of segmental absence of small bowel muscular layer in preterm born infant. Some ideas concerning the pathogenesis of this entity and review of the literature is presented.

**Key words:** intestinal perforation, congenital defect, muscular layer.

---

### Segmental congenital defect of the intestinal musculature

Congenital focal absence of the muscular layer of the small intestine is considered a rare cause of intestinal obstruction or perforation in the newborn. Its aetiology and pathogenesis are unknown. The first case of spontaneous perforation secondary to congenital absence of the gastric musculature was described in 1943 by Herbut [1]. Subsequently descriptions of spontaneous perforation in the small intestine and the colon appeared. In 1943, Emanuel described for the first time segmental absence of the intestinal musculature as a new cause of intestinal obstruction [2].

Here we present a case report of perforation due to congenital defects of the intestinal musculature. A premature 3-month-old male infant developed two abdominal events (the first one at the age of 2 months). The clinical diagnosis in both cases was necrotizing enterocolitis. We describe the recent one. The surgical specimen contained 2 segments of ileum 5 and 3 cm in length. The minimum diameter was 0.8 cm and the maximum 1 cm. On gross examination in the midportion of the second fragment of the intestine, a focus of perforation with thin and congested mucosa around was observed. The remaining intestine appeared intact. Histological examination revealed multifocal partial or complete absence of the muscularis propria (Fig. 1-4). The mucosa of the bowel was well preserved with high villi covered by

normal, cylindrical epithelium. Muscularis mucosa appeared within normal limits. The submucosa and serosa were oedematous and slightly infiltrated by lymphocytes and plasma cells. The mucosa and submucosa surrounding the perforation were congested, oedematous with mild leucocytic reaction in the serosa. No thrombotic phenomena were observed. It was concluded that necrotizing enterocolitis was not observed. Histological sections of different areas of the specimen showed several foci of muscular hyperplasia of the muscularis propria. The plexuses of Auerbach and Meissner were absent in regions of muscle loss (Fig. 4), but present in others and appeared well formed and situated.

Neonatal focal spontaneous perforations of the gastrointestinal tract with no evidence of necrotizing enterocolitis or mechanical obstruction is a known phenomenon [1, 3, 4]. In spite of numerous theories proposed in the past, the majority of these lesions continue to be reported as spontaneous perforation of unknown aetiology [4]. The histological picture is distinctive and quite different from that of necrotizing enterocolitis, which is characterized at the early stage by necrosis of the mucosa, intestinal haemorrhage, and occasionally thrombosed capillary loops in the villous cores. Transmural necrosis and varying degrees of intramural haemorrhage are seen in a more advanced process [1, 4]. In all cases described in the literature, the histology showed intact mucosa, absence of muscularis propria and minimal or absent

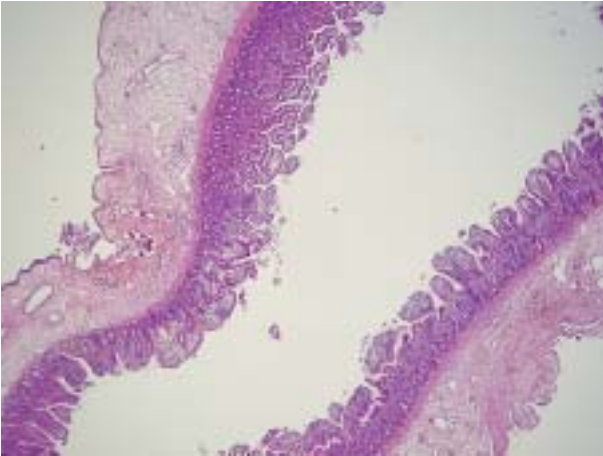


Fig. 1. The wall of the small intestine formed by intact mucosa, oedematous submucosa and serosa. The muscular coat is absent. Haematoxylin and eosin, original magnification 50×

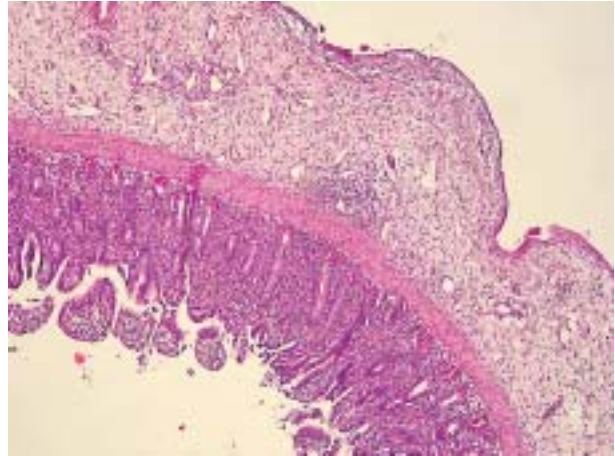


Fig. 2. The wall of the small intestine formed by intact mucosa, oedematous submucosa and serosa. The muscular coat is absent. Haematoxylin and eosin, original magnification 200×

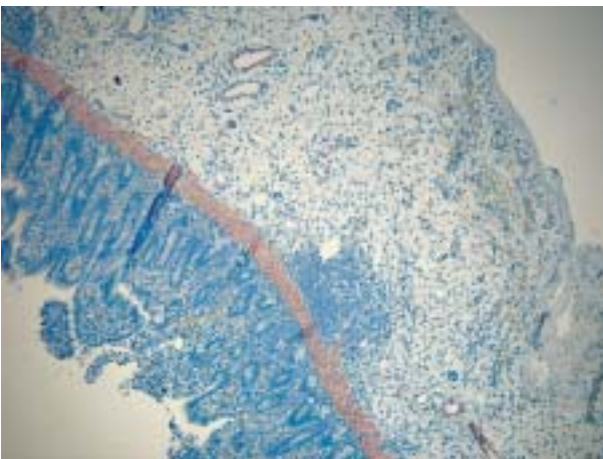


Fig. 3. The wall of the small intestine with absent muscular coat. SMA, original magnification 200×

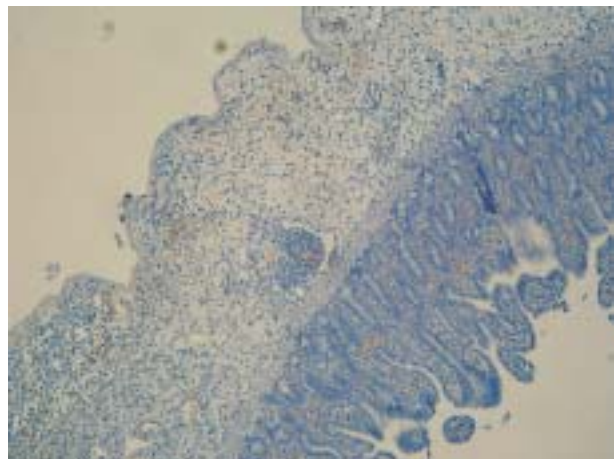


Fig. 4. The wall of the small intestine, absence of myenteric plexus. S-100, original magnification 200×

inflammation [1-5]. However, there are some similarities in aetiology between two entities. Most cases with congenital intestinal muscular defect occurred in premature infants with low birth weight [3]. Alawadhi *et al.* [6], basing on embryogenesis, proposed two theories that suggested either failure of resorption of the small intestine diverticula or over-resorption of muscle during regression of the omphalomesenteric duct [3, 6]. In reference to the theory of primary defect, the presence of occasionally remaining myenteric plexus in regions of muscle loss is of importance because plexus formation in the ileum occurs at about the sixth week of gestation and follows the formation of the muscle layers [3, 6, 7]. Not all authors agree that this is a congenital anomaly, and some believe ischemia to be the only etiological factor in cases of perforation [4, 5]. Although the role of ischemia in causing perforations is accept-

ed by most authors, it is difficult to explain such extensive muscular damage while the mucosa, which should be much more sensitive to ischemia, remains intact [4]. Some authors postulate that ischemic injury occurring postnatally or perhaps during late foetal life causes injury to both the mucosa and the muscularis propria. Taking into account the different degree of regenerative capacity of mucosa and muscles, the mucosa might regenerate and the muscularis propria might not, resulting in total or partial absence of the musculature [3]. Why does muscularis mucosa remain intact then?

In summary, congenital defect of the intestinal musculature is rare and its aetiology is controversial. In our reported case we did not find any signs of unresorbed necrotic muscles or fibrotic tissue. Moreover, we observed absence of the myenteric plexus in the region of muscle loss with no signs of inflammation.

In our opinion, this is an important argument against the theory of pre- or postnatal ischemic aetiology in our case.

## References

1. Izraeli S, Freud E, Mor C, et al. Neonatal intestinal perforation due to congenital defect in the intestinal muscularis. *Eur J Pediatr* 1992; 151: 300-303.
2. Emanuel B, Gault B, Sanson J. Neonatal intestinal obstruction due to absence of intestinal musculature: A new entity. *J Pediatr Surg* 1967; 2: 332-335.
3. Huang S, Vacanti J, Kozakewich H. Segmental defect of the intestinal musculature of a newborn: evidence of acquired pathogenesis. *J Pediatr Surg* 1996; 31: 721-725.
4. Litwin A, Avidor I, Schujman E, et al. Neonatal intestinal perforation caused by congenital defects of the intestinal musculature. *Am J Clin Pathol* 1984; 81: 77-80.
5. Carroll RL. Absence of musculature of the distal ileum a cause of neonatal intestinal obstruction. *J Pediatr Surg* 1973; 8: 29-31.
6. Alawadhi A, Chou S, Carpenter B. Segmental agenesis of intestinal muscularis: A case report. *J Pediatr Surg* 1986; 24: 1089-1090.
7. Okamoto E, Ueda T. Embryogenesis of intramural ganglia of the gut and its relation to Hirschsprung's disease. *J Pediatr Surg* 1967; 2: 437-443.

## Address for correspondence

**Monika Dzieńiecka MD**  
Department of Clinical Pathomorphology  
Research Institute Polish Mother's Memorial Hospital  
ul. Rzgowska 281/289  
93-338 Łódź  
phone +48 42 271 12 80  
e-mail: chicamonika@yahoo.es