

QUIZ

WHAT IS YOUR DIAGNOSIS?

In June 2007, an otherwise healthy, 16-year-old male was referred by an orthodontist to the Department of Oral Surgery, Medical College, Jagiellonian University for extraction of retained tooth 43.

Orthopantomography revealed the 2 × 3 cm cystic radiolucency around retained tooth 43 with its apex reaching the inferior border of the mandibular body (Fig. 1) and displacement of the neighbouring teeth roots. Under local anaesthesia, both the retained tooth and the cyst were removed.

Macroscopically, the pathological specimen consisted of the cystic-like follicle (diam. 28 mm) with

a tiny tumour in the wall (diam. 7 mm) and the tooth.

Microscopically, the tumour was assembled of whorled nodules interconnected by a lattice of thin epithelial strands. The columnar cells lined duct-like spaces with a lumen containing eosinophilic material. In the stroma, there were aggregates of eosinophilic hyaline material in-between the strands of epithelial cells (Fig. 2, 3 and 4; lens magnification 10×, 20×, 60×, respectively).

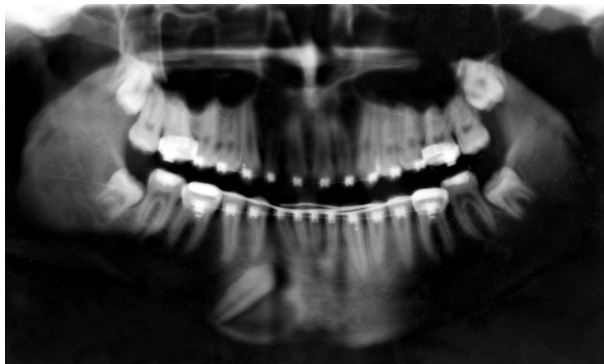


Fig. 1.

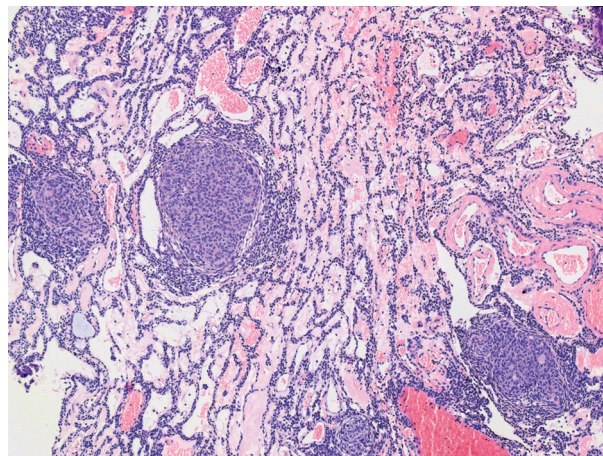


Fig. 2.

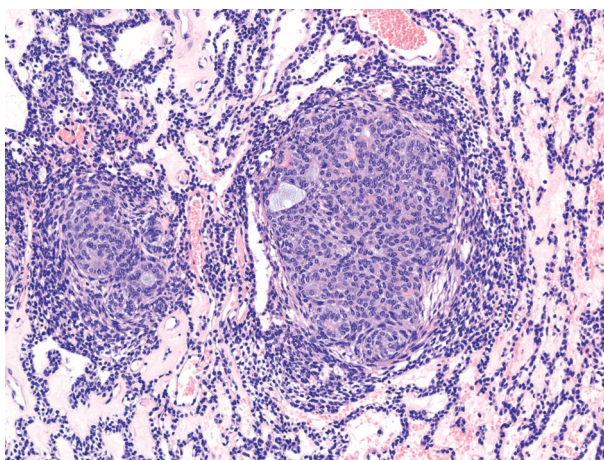


Fig. 3.

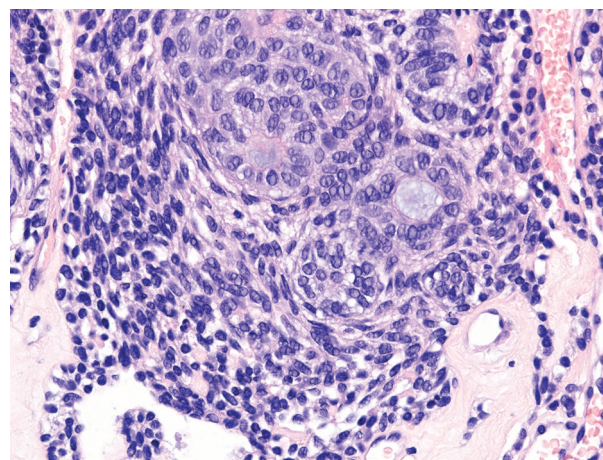


Fig. 4.

Jacek Czopek¹, Tomasz Kaczmarzyk²

¹Department of Pathomorphology

²Department of Oral Surgery, Jagiellonian University *Medical College*, Kraków, Poland

Answers should be sent to the Editorial Office by 12.05.2011. The correct answer will be announced in the next issue of the *Polish Journal of Pathology*. All participants with the highest number of correct answers to the quizzes published in vol. 62 (4 issues) will be entered into the prize draw for a book.