

QUIZ

CORRECT ANSWER TO THE QUIZ. CHECK YOUR DIAGNOSIS

ADENOMATOID ODONTOGENIC TUMOUR

JACEK CZOPEK¹, TOMASZ KACZMARZYK²

¹Department of Pathomorphology, Jagiellonian University Medical College, Krakow, Poland

²Department of Oral Surgery, Jagiellonian University Medical College, Krakow, Poland

A case of adenomatoid odontogenic tumour (AOT) is presented with a short review of clinical, radiological and histological features.

Key words: adenomatoid odontogenic tumour, AOT.

Introduction

Adenomatoid odontogenic tumour (AOT) is a rare, slowly growing, encapsulated, epithelial odontogenic tumour composed of whorled nodules of spindle cells, double cell strands and formation of microcystic or duct-like spaces. It has a limited growth potential, and is considered to be a hamartoma rather than a neoplasm [1, 2].

Case report

In June 2007 an otherwise healthy, 16-year-old male was referred by an orthodontist to the Department of Oral Surgery at the Medical College of the Jagiellonian University for extraction of the retained tooth 43. Two years earlier, he was supplied with orthodontic appliances but no X-ray examination had been performed beforehand.

Extraoral examination was non-contributory. Intraorally, tooth 43 was not present and teeth 42 and 44 were displaced and leaned concurrently. A slight, painless distension of the internal surface of the mandibular body in the vicinity of teeth 42, 43 and 44 was noted.

Orthopantomography revealed a 2 × 3 cm radiolucency around retained tooth 43 with its apex reaching the inferior border of the mandibular body (Fig. 1). Roots of the neighbouring teeth (particularly 42) were displaced concurrently. A tentative diagnosis of dentigerous cyst was made.

Under local anaesthesia, both the retained tooth and the cyst follicle were removed. The postoperative period was uneventful.

Macroscopically, the pathological specimen consisted of a cystic-like follicle (diam. 28 mm) with a tiny tumour in the wall (diam. 7 mm) and the tooth.

Microscopically, the tumour was assembled of spindle-shaped and columnar epithelial cells. The spindle-shaped cells formed whorled nodules interconnected by a lattice of thin epithelial strands. The columnar cells lined duct-like spaces with a lumen containing eosinophilic material. In the stroma, there were aggregates of eosinophilic hyaline material in between the strands of epithelial cells (Figs. 2-4; lens magnifications: 10×, 20×, 60×, respectively).

The diagnosis was: adenomatoid odontogenic tumour (No. 1614940).

Discussion

The pathogenesis of AOT is unknown. The tumour is suspected to develop from residues of the dental lamina and proliferations of odontogenic epithelium adjacent to the reduced enamel epithelium of unerupted teeth.

The relative frequency AOT varies from 1.7% to 7.5% of all odontogenic tumours. Female to male ratio is 1 : 1.9 [1-3].

The age range varies between 3 and 82 years [2], but almost 70% of the tumours are diagnosed in patients in their second decade of life and more than 50% in patients between the age of 13 and 19 [3]. Few patients are older than 30 years [4].

More than 95% of all cases occur within the bone, with a preference ratio of about 2 : 1 for the maxilla over the mandible [1-5]. AOT has a predilection for

the canine area; it occurs only rarely in the posterior regions [1-3].

AOT is usually asymptomatic; most of them are discovered accidentally during a routine radiographic examination. Larger lesions may cause painless expansion of the bone. The growth rate of AOT is very slow and the size of the lesion is between 1.5

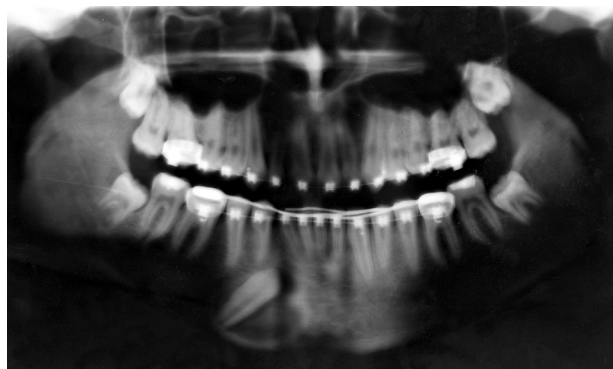

Fig. 1.

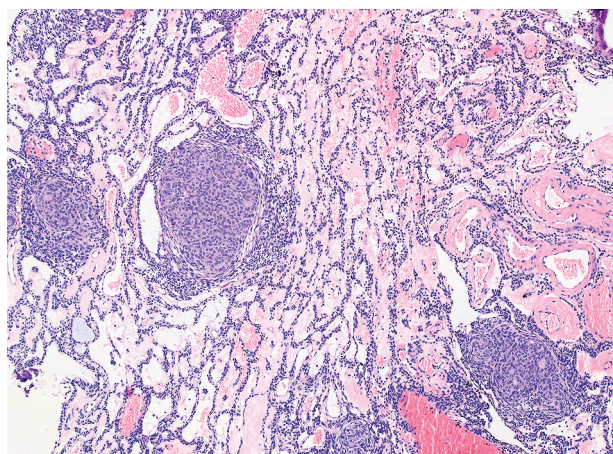


Fig. 2.

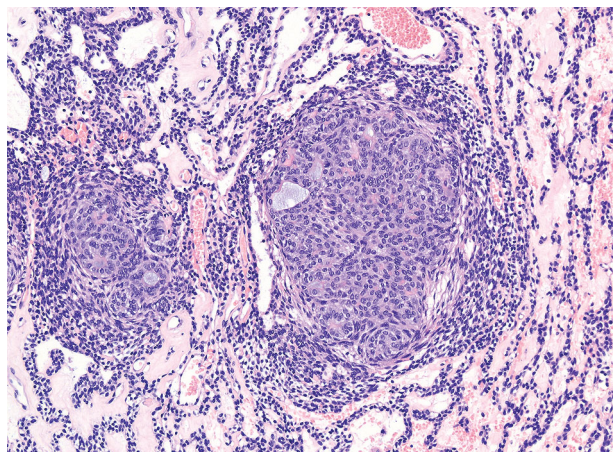


Fig. 3.

and 3 cm [1, 2], but there are reports of lesions that reached a size of 6 to 7 cm [8].

A rare peripheral (extraosseous) AOT occurs usually in the anterior part of the maxilla and very rarely in the mandible [2, 4]. It presents as a pink gingival swelling; the mean age of patients is about 13 years [4].

In imaging studies, AOT usually wraps around the crown or the entire tooth (so-called "follicular" AOT – 70% of all cases), which simulates a dentigerous cyst and may be impossible to distinguish from a dentigerous cyst on a radiogram [2-4]. The tumour is well defined and unilocular; in 50-75% of cases also scattered fine radiopacities may be seen within the radiolucent area [2, 4].

Rarely the AOT involves the second permanent incisor or the first permanent premolar; involvement of other permanent teeth is rare.

An intraosseous AOT unrelated to an unerupted tooth ("extrafollicular" type) presents as a well-delimited radiolucent lesion. It can resemble a residual, a radicular, or a lateral periodontal cyst. It may also be located deep in the bone without visible relation to teeth [3]. Sometimes erosion of the alveolar bone crest, root resorption, perforation of the cortical bone, and invasion of the maxillary sinus is observed [1, 2, 6].

Macroscopically the tumour is well circumscribed and usually encapsulated. Some present as a solid mass. Those situated around the crown of a tooth are (partly) cystic.

Histologically AOTs are unrelated to their location in the jaws; all types show the same pattern. Solid lesions consist of a proliferating epithelium surrounded by a well-defined fibrous capsule. Various patterns are seen in the epithelium. Spindle and polyhedral cells often form nodules. Several nodules of various sizes are placed close together with narrow strands of more orderly arranged epithelial cells in between [1, 2].

Some epithelial cells form small nests ("rosettes") often with droplets of an eosinophilic, PAS-positive

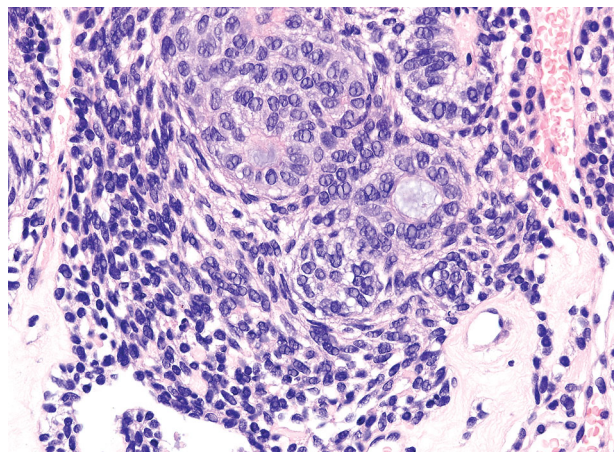


Fig. 4.

and diastase resistant, extracellular substance. Cystic (or “duct-like”) spaces of different sizes are seen between the nodules but they may not be present in all tumours [1, 2]. The lumen is lined with a layer of radially arranged columnar or cuboidal, epithelial cells. The cytoplasm is lightly stained, and oval nuclei are polarized away from the lumen. In the lumen a thin PAS-positive, diastase-resistant, eosinophilic material is often seen. Some of the cystic structures may show invaginations of part of the wall [1, 2].

Another distinctive pattern consists of long, narrow epithelial strands of two layers or a single layer of cubic cells. They form large loops, which are connected to each other in a “plexiform” pattern. The stroma inside the loop is often very loose and sometimes missing. This pattern is found in particular toward the periphery of the lesion. In the stroma a perivascular hyalinization with concentric disposition of hyaline layers in the surrounding connective tissue and degeneration of the endothelial layer may be found [2, 6].

Calcifications are present in various amounts: they may be seen in the degenerated epithelium and in the extracellular, eosinophilic, PAS-positive material [2]. Also an eosinophilic, hyalinized and partly mineralized, dentinoid-like material and even melanin may be seen [1, 2, 7].

A quite common feature in AOTs is the presence of minor areas of tumour tissue showing similarities to the calcifying epithelial odontogenic tumour. However, it does not change the course of the AOT. The capsule remains intact and recurrence is unlikely [2, 8].

Mitotic figures may be found occasionally in AOT, but dysplasia has never been described [2].

The cystic, follicular variant of AOT has a thick fibrous capsule with a smooth surface. On a section, a large cystic cavity is seen, which is partially filled with solid tissue showing the same histomorphology as the solid variant, sometimes with calcifications. Part of the luminal surface of the cystic lesion may be covered with a layer of squamous epithelium similar to dentigerous cysts.

Due to rather distinctive microscopic features the diagnosis is usually not difficult. Sometimes AOT may be mistaken for ameloblastoma, but only the former is encapsulated and shows duct-like structures within the tumour.

If the lesion is small and found in the wall of a dentigerous cyst, it may be overlooked. The pres-

ence of a large amount of calcified material also may confuse the pathologist. In common diagnostic practice, immunohistochemistry is not a valuable aid to diagnosis [1, 2, 6]. It may be interesting, however, that only rarely was p53 protein detected in AOTs, in contrast to keratocystic odontogenic tumour, ameloblastoma and clear cell odontogenic carcinoma, which were reported as positive [2, 9].

The treatment of choice is enucleation of the tumour from the bone followed by curettage [1, 2, 10]. The risk of recurrence is extremely low; only four cases have been reported [1, 2]. Malignant transformation has never been described [2].

The authors declare no conflict of interest.

References

1. Philipsen HP, Nikai H. Adenomatoid odontogenic tumour. In: Barnes L, Eveson JW, Reichart P, et al. (eds.). World Health Organization Classification of Tumours. Pathology and Genetics of Head and Neck Tumours. IARC Press, Lyon 2005: 304-305.
2. Prætorius F. Odontogenic tumours. In: Surgical Pathology of the Head and Neck. Barnes L (ed.). 3rd ed. Informa Healthcare USA Inc., New York 2008; 1201-1338.
3. Philipsen HP, Reichart PA. Adenomatoid odontogenic tumour: facts and figures. Oral Oncol 1998; 35: 125-131.
4. Philipsen HP, Reichart PA, Siar CH, et al. An updated clinical and epidemiological profile of the adenomatoid odontogenic tumour: a collaborative retrospective study. J Oral Pathol Med 2007; 36: 383-393.
5. Swadison S, Dhanuthai K, Jaikittivong A, et al. Adenomatoid odontogenic tumors: an analysis of 67 cases in a Thai population. Oral Surg Oral Med Oral Pathol Oral Radiol Endod 2008; 105: 210-215.
6. Leon JE, Mata GM, Fregnani ER, et al. Clinicopathological and immunohistochemical study of 39 cases of Adenomatoid Odontogenic Tumour: a multicentric study. Oral Oncol 2005; 41: 835-842.
7. Aldred MJ, Gray AR. A pigmented adenomatoid odontogenic tumor. Oral Surg Oral Med Oral Pathol 1990; 70: 86-89.
8. Ledesma-Montes C, Mosqueda Taylor A, Romero de Leon E, et al. Adenomatoid odontogenic tumour with features of calcifying epithelial odontogenic tumour. (The so-called combined epithelial odontogenic tumour.) Clinicopathological report of 12 cases. Eur J Cancer B Oral Oncol 1993; 29B: 221-224.
9. Carvalhais J, Aguiar M, Araujo V, et al. p53 and MDM2 expression in odontogenic cysts and tumours. Oral Dis 1999; 5: 218-222.
10. Zaleska-Szczurek M, Stypułkowska J, Stachura J, Kapera P. Adenomatoid odontogenic tumor – a rare odontogenic neoplasm of the jaws in own clinical material. Poradnik Stomatologiczny 2004; 8: 34-40.

THE AUTHORS OF CORRECT DIAGNOSIS ARE:

Maciej Znaniecki MD, Janusz Korczak Memorial Provincial Specialistic Hospital in Słupsk, Department of Pathomorphology, ul. Hubalczyków 1, 76-200 Słupsk

Jacek Kowalski MD, Saint Adalbert Memorial Specialistic Hospital, Department of Pathomorphology, Al. Jana Pawła II 50, 80-046 Gdańsk

Elżbieta Trojnar, Provincial Hospital No2 in Rzeszów, Department of Pathomorphology, ul. Lwowska 60, 35-301 Rzeszów