

QUIZ

CORRECT ANSWER TO THE QUIZ. CHECK YOUR DIAGNOSIS

BENIGN FIBROUS HISTIOCYTOMA OF THE SKIN METASTASIZING TO THE INGUINAL LYMPH NODE

ANNA SZUMERA-CIEĆKIEWICZ, KONRAD PTASZYŃSKI

Department of Pathology, Maria Skłodowska-Curie Memorial Cancer Centre and Institute of Oncology, Warsaw, Poland

Benign fibrous histiocytoma (FH, dermatofibroma) is a common skin lesion but its metastasizing variant is extremely rare and only a few cases have been reported to date. The usual sites of metastases include locoregional lymph nodes and lung. In the majority of cases, the clinical course is indolent. At present, there are no reliable clinical or histological features of the primary tumour that could predict the risk of locoregional or distant metastases. Authors describe a case of metastasizing FH and briefly review available data.

Key words: benign fibrous histiocytoma, dermatofibroma, metastases.

Introduction

Benign fibrous histiocytoma (FH, dermatofibroma) is a common skin lesion and several histologic variants were identified including three major subtypes: cellular, aneurysmal and atypical. The primary lesion most frequently occurs in young adults, is located on the extremities and microscopically presents as a cellular FH. Its metastasizing variant is extremely rare and only 18 cases have been reported to date. Locoregional lymph nodes and (or) lung are typical sites of metastases.

Case report

A 31-year-old female underwent resection of the inguinal lymph node, 3 cm in diameter, with a suspicion of metastasis. Two years before the resection, a cutaneous and subcutaneous lesion measuring 1.5 cm in diameter of the right thigh was excised (Fig. 1 A, B). There was no evidence of relevant family history of oncologic diseases. The microscopic findings of the lesion revealed a nodular, cellular proliferation involving dermis and extending into subcutis forming short, intersecting fascicles of fibroblastic spindle and ovoid cells with no nuclear atypia and low mitotic activity. The stroma was composed of a delicate collagen network (Fig. 1 C, D). The morphological features of metastasis to the lymph node were the same as the primary skin

FH presented above (Fig. 1 A, B). The immunohistochemical stainings with anti CD34, S100 and desmin antibodies were negative. After three years of follow-up, the patient is alive with no symptoms of metastatic disease.

Discussion

Benign fibrous histiocytoma of the skin is one of the most common entities diagnosed in the routine surgical pathology service. It represents a benign but diverse group of neoplasms which exhibits both fibroblastic and histiocytic features; however, its nature of differentiation is still uncertain. Several histologic variants were identified including three major subtypes: cellular, aneurysmal and atypical. A number of rare variants, i.e. lipidized (ankle-type), palisading, with myxoid, clear-cell or granular cell change. A minor group of FH has borderline histologic image demonstrating focal atypia and some mitotic activity; it was classified as atypical benign fibrohistiocytoma, which may recur locally and is thought not to metastasize. The differential diagnosis includes other benign lesions, i.e. nodular fasciitis, neurofibroma and leiomyoma as well as dermatofibrosarcoma protuberans (DFSP). The most typical immunostaining for FH is positive reaction for factor XIIIa and negative or peripherally scant with CD34 antibody. Dermatofibrosarcoma protu-

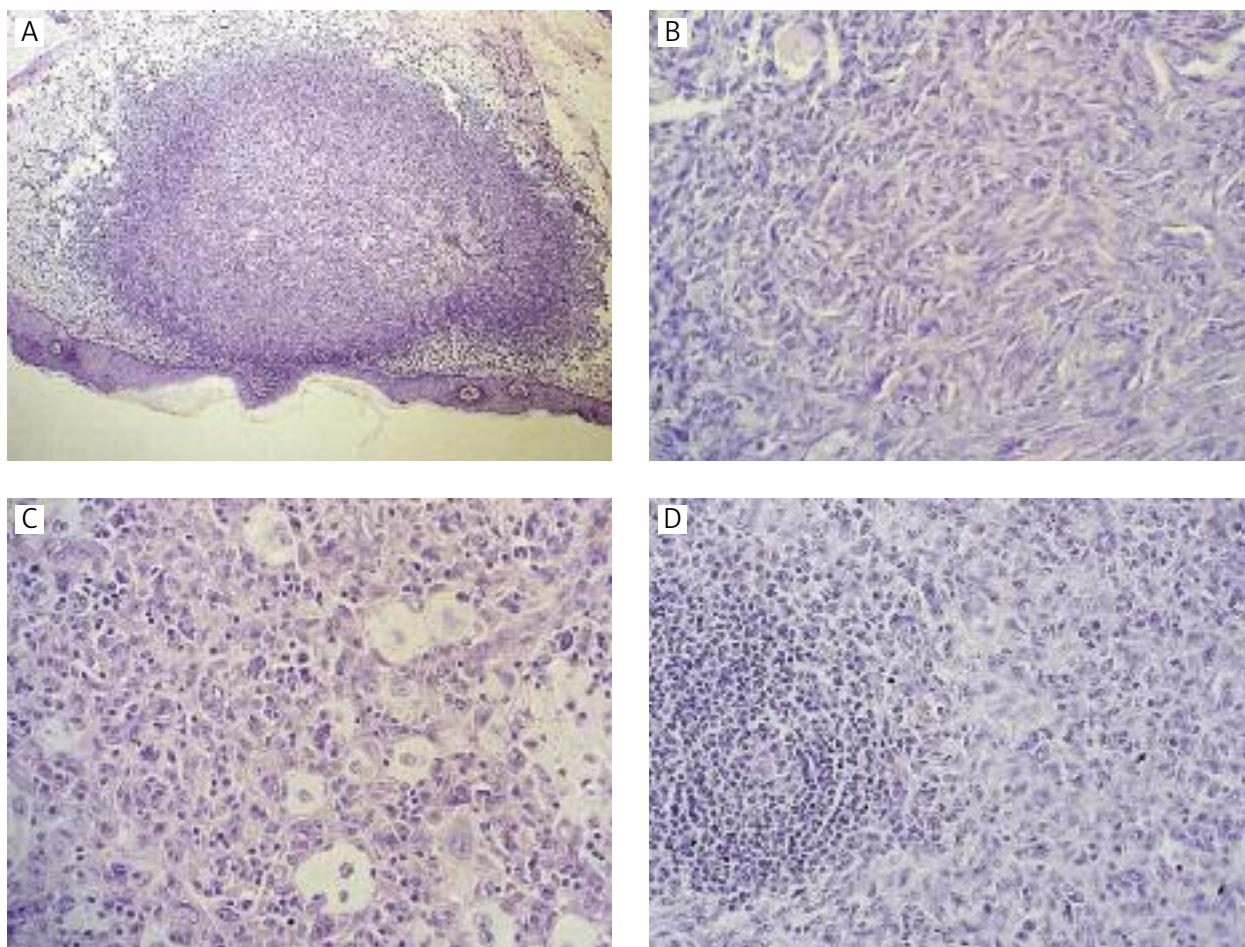


Fig. 1. Benign fibrous histiocytoma (A, B) metastasizing to locoregional lymph node (C, D)

berans expresses CD34 in a significant portion of neoplastic cells. Thus, a combination of these two immunohistochemical reactions is needed for differential diagnosis. In some cases, desmin or smooth muscle actin may be positive but the morphological features of FH are characteristic enough to avoid the diagnosis of a smooth muscle neoplasm. In vast majority of cases, no recurrence is observed once the lesion is completely removed but occasionally one or more recurrences are noted. In 1996, Colome-Grimmer reported two cases of FH designated as cellular [1]. One of the cases recurred several times and metastasized to the locoregional lymph node and lung. The other case metastasized to the lymph node and lung with no recurrence observed. In addition, the authors described histological features of FH that are associated with a tendency for recurrence and metastasis. The set of features includes: relatively large size, aneurysmal change, high cellularity, pleomorphism, high mitotic index and necrosis. Subsequently, more cases of the metastasizing FH have been reported [2-10]. In

2010, Luzar and Calonje reviewed cutaneous fibrohistiocytic tumours including all 12 cases of metastasizing FH available in the literature [11]. Deep FH is usually larger in diameter than the cutaneous or subcutaneous variant. It shows histological features similar to FH but rare haemangiopericytoma (HPC) pattern, fibrosis and necrosis are seen. Occasionally, deep FH may behave as an aggressive neoplasm. Among 69 cases of deep FH published by Gleason, two cases showed metastases and the patients ultimately died of the disease [2]. The primary skin lesion of the current case showed histological features of FH with bland spindle and ovoid cells, focal aggregates of foam cells, low mitotic index and no necrosis. An inguinal lymph node showed similar histological features intermingled with lymphoid tissue. Three years after initial diagnosis of the skin lesion, the patient shows no recurrence and no other metastatic lymph nodes. There is no evidence of distant metastasis. Table I shows a summary of the literature review which includes all 19 cases reported to date.

Table I. A summary of the literature review of metastasizing benign fibrous histiocytoma

NO*	GEN- DER	AGE	PRIMARY LESION	MAXIMAL DIAMETER	LOCALI- SATION	TIME TO LOCAL RECUR- RENCE	TIME TO META- STASIS	SITE OF META- STASIS	FOLLOW- UP	YEAR OF PUBLI- CATION	REFE- RENCES
1	M	35	Deep FH	6 cm	Posterior mediastinal	43 mo	115 mo	Lungs Liver Scalp Paraver- tebral soft tissue	Died, 2 y later	2008	[2]
2	F	51	Deep FH	9 cm	Lumbar	No	9/18 mo	Retrope- ritoneal region	Died, 79 mo later	2008	[2]
3	M	46	Aneurysmal/ Atypical FH	1.3 cm	Thigh	No	19 y	Inguinal lymph nodes	Alive	2000	[3]
4	M	22	Cellular FH	3 cm	Thigh	No	4 mo	Inguinal lymph node	Alive, 14 y	2000	[3]
5	M	28	Cellular FH	2 cm	Neck	16 mo	20 mo	Cervical lymph nodes	Alive, 15 mo	2000	[3]
6	F	36	Cellular FH	ND	Shoulder	No	7 y	Multiple meta to both lungs	ND	2007	[4]
7	M	54	Cellular FH	ND	Chest wall	2/9 y	23 y	Multiple meta to both lungs	Alive, 4 y	2002	[5]
8	M	29	Cellular FH	ND	Back	No	10 y	Multiple meta to both lungs	ND	2002	[5]
9	M	33	Cellular FH	5 cm	Back	No	2 y	Multiple meta to both lungs	ND	2002	[6]
10	M	18	Cellular FH	ND	Thigh	17/26 mo	26 mo/ 4 y	Lymph nodes / Multiple meta to both lungs	Alive, 4 y	1996	[1]
11	M	33	Cellular FH	ND	Posterior neck	3 mo	7/8 y	Lymph nodes / Multiple meta to both lungs	Alive, 8 y	1996	[1]
12	ND	ND	AFH	ND	ND	No	12 mo	Multiple meta to both lungs	Alive, 16 mo	2002	[7]
13	ND	ND	AFH	ND	ND	12 mo	12 mo	Skin Lymph nodes Abdominal Organs lungs	Died, 96 mo	2002	[7]
14	F	30	FH	ND	Shoulder	No	17 y	Multiple meta to both lungs	ND	1997	[8]
15	F	31	FH	1.5 cm	Thigh	No	2 y	Lymph node	Alive, 1 y	2011	current case

*4 additional cases were reported: 2 by Joseph in 1990 [9] and 2 by Bisceglia in 2006 [10]. Data unavailable

FH – benign fibrous histiocytoma

AFH – atypical fibrous histiocytoma

ND – no data available

mo – month

y – year

References

1. Colome-Grimmer MI, Evans HL. Metastasizing cellular dermatofibroma. A report of two cases. *Am J Surg Pathol* 1996; 20: 1361-1367.
2. Gleason BC, Fletcher CD. Deep "benign" fibrous histiocytoma: clinicopathologic analysis of 69 cases of a rare tumor indicating occasional metastatic potential. *Am J Surg Pathol* 2008; 32: 354-362.
3. Guillou L, Gebhard S, Salmeron M, Coindre JM. Metastasizing fibrous histiocytoma of the skin: a clinicopathologic and immunohistochemical analysis of three cases. *Mod Pathol* 2000; 13: 654-660.
4. Gu M, Sohn K, Kim D, Kim B. Metastasizing dermatofibroma in lung. *Ann Diagn Pathol* 2007; 11: 64-67.
5. Osborn M, Mandys V, Beddow E, et al. Cystic fibrohistiocytic tumours presenting in the lung: primary or metastatic disease? *Histopathology* 2003; 43: 556-562.
6. De Hertogh G, Bergmans G, Molderez C, Sciot R. Cutaneous cellular fibrous histiocytoma metastasizing to the lungs. *Histopathology* 2002; 41: 85-86.
7. Kaddu S, McMenamin ME, Fletcher CD. Atypical fibrous histiocytoma of the skin: clinicopathologic analysis of 59 cases with evidence of infrequent metastasis. *Am J Surg Pathol* 2002; 26: 35-46.
8. Colby TV. Metastasizing dermatofibroma. *Am J Surg Pathol* 1997; 21: 976.
9. Joseph MG, Colby TV, Swensen SJ, et al. Multiple cystic fibrohistiocytic tumors of the lung: report of two cases. *Mayo Clin Proc* 1990; 65: 192-197.
10. Bisceglia M, Attino V, Bacchi CE. Metastasizing "benign" fibrous histiocytoma of the skin: a report of two additional cases and review of the literature. *Adv Anat Pathol* 2006; 13: 89-96.
11. Luzar B, Calonje E. Cutaneous fibrohistiocytic tumours – an update. *Histopathology* 2010; 56: 148-165.

Address for correspondence

Anna Szumera-Ciećkiewicz MD
Department of Pathology
Maria Skłodowska-Curie Memorial
Cancer Center and Institute of Oncology
ul. Roentgena 5
02-781 Warszawa
Poland
phone: +48 22 546 27 26
e-mail: annacieckiewicz@coi.waw.pl

THE AUTHOR OF CORRECT DIAGNOSIS IS:

Maciej Znaniński MD, Janusz Korczak Memorial Provincial Specialistic Hospital in Słupsk,
Department of Pathomorphology, ul. Hubalczyków 1, 76-200 Słupsk