

QUIZ

WHAT IS YOUR DIAGNOSIS?

Case description

A 55-year-old woman with a history of cardiac disorders, presented with melaena, anorexia and weight loss. By gastric biopsy, infiltrate of poorly dif-

ferentiated carcinoma was diagnosed and total gastrectomy was performed. Grossly, the tumour infiltrated most of the stomach wall, entering the perigastric fat tissue. The pictures show histological appearance of this infiltrate.

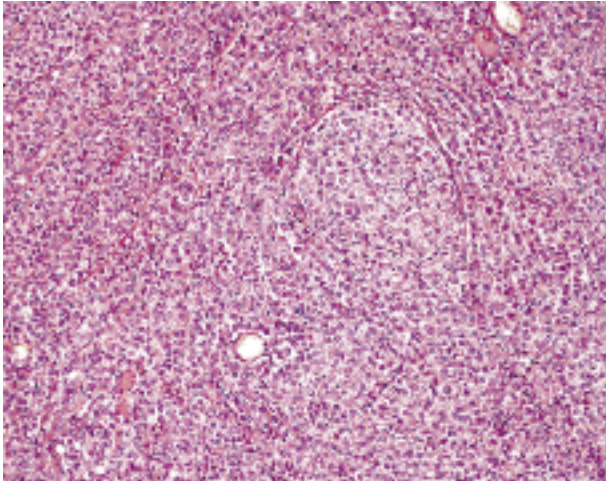


Fig. 1

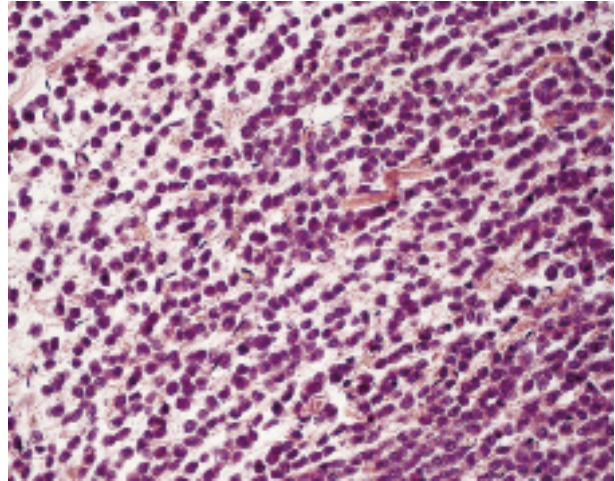


Fig. 2

Katarzyna Wysocka¹, Krzysztof Okoń¹, Andrzej Matyja²

¹Department of Pathology and ²Department of Gastrointestinal Surgery, Jagiellonian University Medical College, ul. Grzegórzecka 16, 31-531 Krakow, Poland

Answers should be sent to the Editorial Office by 30.11.2011. The correct answer will be announced in the next issue of the *Polish Journal of Pathology*. All participants with the highest number of correct answers to the quizzes published in vol. 62 (4 issues) will be entered into the prize draw for a book.