

WHEN “DIABETIC NEPHROPATHY” IS NOT ALWAYS OF DIABETIC ORIGIN: A CASE REPORT

KRZYSZTOF WRÓBLEWSKI¹, MAŁGORZATA SODOLSKA¹, MAŁGORZATA WĄGROWSKA-DANILEWICZ²,
MARIAN DANILEWICZ², DARIUSZ MOCZULSKI¹

¹Department of Internal Medicine and Nephrodiabetology, Medical University of Lodz, Łódź, Poland

²Department of Nephropathology, Medical University of Lodz, Łódź, Poland

The etiology and pathogenesis of fibrillary glomerulonephritis (FGN) remains unknown. The presented case shows an extremely rare FGN in association with commonly diagnosed diabetes. A 74-year-old, non-smoking, obese and diabetic woman was hospitalized due to a progressive and accelerated decrease in the renal function. The primary cause of chronic kidney disease was believed to be of diabetic origin. In the renal biopsy, light microscopy showed glomerular changes resembling diabetic nephropathy, however electron microscopy evaluation revealed linear, randomly arranged fibrils present in the glomerular mesangium and in peripheral capillary loops. The biopsy confirmed fibrillary glomerulopathy.

Key words: diabetes, fibrillary glomerulopathy, chronic kidney disease, haematuria, proteinuria.

Introduction

The incidence of fibrillary glomerulonephritis (FGN) is very low. In this type of glomerulopathy, Congo red-negative organized immunoglobulin-derived deposits can be widely spread within every glomerular structure. Non-branching, linear, randomly arranged fibrils resembling amyloid with a diameter of 10 to 30 nm have no lumen and in the vast majority are found only in kidneys [1]. The light microscopy can present different types of glomerulonephritis with different patterns of proliferation or even sclerosis. Thus, without electron microscopy FGN tends to be misdiagnosed. The patients are frequently asymptomatic. The disease manifests by progressive deterioration of the kidney function. The urinalysis usually shows subnephrotic proteinuria and microscopic haematuria [2].

In diabetic patients, chronic kidney disease is usually referred to as diabetic nephropathy; hence the renal biopsy is not commonly performed [3]. Due to the fact that the lack of diabetic retinopathy seems to be a good predictor of non-diabetes related kidney failure, in these cases a progressive decrease in the

glomerular filtration rate should be histopathologically verified.

Case report

A 74-year-old, non-smoking woman with BMI of 37.3 kg/m², treated for 10 years for diabetes type 2 and hypertension, was admitted to our clinic due to a progressive and accelerated decrease in the renal function and malaise. The woman had been suffering from fatigue and weakness for half a year, but had not been diagnosed by then. Six months later routine blood tests revealed an impaired renal function with a creatinine level of 186 µmol/l and hemoglobin level below 10 g/dl. With the diagnosis of chronic diabetic kidney disease and renal related anemia, the patient was treated with erythropoiesis-stimulating agent (ESA) for six months. Despite good glycemic and blood pressure control, a follow-up visit showed an increase in the serum creatinine level up to 192 µmol/l with a decrease in glomerular filtration estimated by GFR-MDRD equation (Glomerular Filtration Rate – Modification of Diet in Renal Disease) to 22 ml/min/1.73 m². A repeated uri-

analysis indicated the presence of proteinuria at the maximal level of 0.92 g/l, haematuria, 10 to 12 fresh and dysmorphic RBC/field with single granular and hyaline casts. Despite the erythropoietin-stimulating agent (ESA) treatment, hemoglobin remained at a level of 10.2 g/dl. Ceasing ESA treatment resulted in a sudden fall in the hemoglobin level to 8.9 g/dl. Before admission to hospital, the cause of chronic kidney disease was believed to be of diabetic origin. Yet, the presence of diabetic retinopathy had not been proven. In repeated blood sample collections, a marked elevated erythrocyte sedimentation rate (ESR) was observed (ranging from 94 to 105 mm/h), but no signs of inflammation were disclosed (CRP 2.9 mg/l). Laboratory findings have not revealed any autoimmune background of the disease. Anti-neutrophil cytoplasmic antibodies (ANCA) and anti-nuclear antibodies (ANA) were negative and there was no alteration in the complement (C3 and C4) level. Protein electrophoresis excluded the presence of paraproteins. Endoscopic examination of the upper and lower gastrointestinal tract as well as two-phase spiral computed tomography of the abdomen did not reveal any abnormalities. The screenings for multiple myeloma as well as for amyloidosis proved to be negative.

Histopathological findings

Owing to the absence of diabetic retinopathy and an unclear reason for renal failure, the renal biopsy was performed. The renal biopsy contained 6 globally sclerosed glomeruli and 6 glomeruli with mesangial matrix expansion, diffuse capillary walls thickening and mild segmental hypercellularity (Fig. 1). The expanded mesangium was PAS positive (Fig. 2) and purple blue on trichrome stain. In Jones methenamine silver stain, the expanded mesangial matrix and thickened capillary walls had a distinctive "moth-eaten" appearance (Fig. 3). Congo red stain was negative. Fibrous crescents in Bowman's space in 2 glomeruli were present. In tubulo-Interstitial compartment, focal fibrosis, tubular atrophy and lymphocytic infiltrates were seen. Immunofluorescence revealed weak IgG, C3, κ and λ light chains staining in mesangial areas and focally along the capillary loops (Fig. 4).

Electron microscopy evaluation (Fig. 5) revealed non-branching, linear randomly arranged fibrils resembling those of amyloid, but approximately twice as thick. The diameter of the fibrils measured on electron microscopic pictures averages at 20 nm, with the range of approximately 10 to 30 nm. Abundant fibrils were present in the glomerular mesangium and extended into peripheral capillary loops. Fibrillary deposits were found in the subepithelial space, subendothelial space, and within the glomerular basement membrane. Glomerular visceral epithelial cell foot processes were diffusely effaced. Fibrillar deposits were not seen in tubuli or vessels.

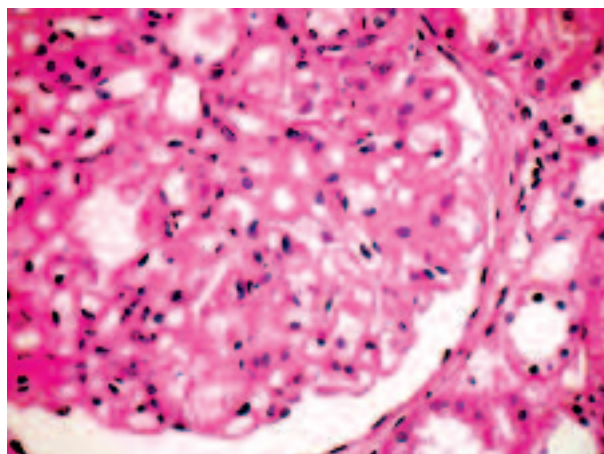


Fig. 1. Glomerulus with diffuse capillary walls thickening, mesangial matrix expansion and mild segmental mesangial proliferation. Light microscopy, HE staining

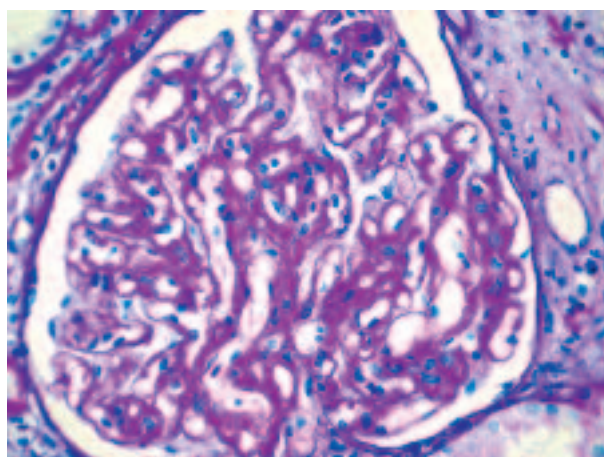


Fig. 2. PAS positive material in mesangium and along capillary walls. Mild segmental hypercellularity. Light microscopy, PAS staining

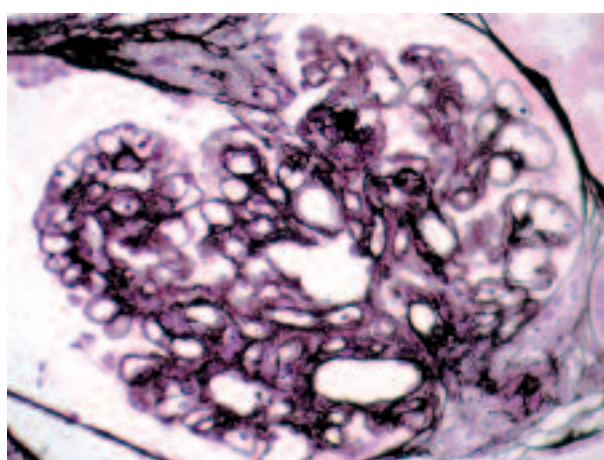


Fig. 3. Decreased affinity for silver in the mesangial areas and in most of the capillary basement membranes. Jones staining

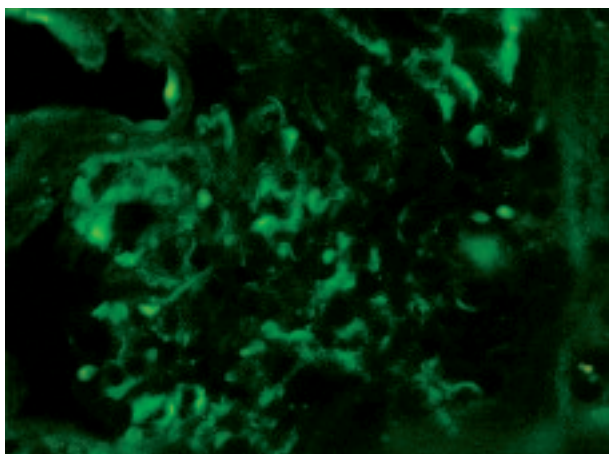


Fig. 4. Weak IgG staining in mesangial areas and focally along the capillary loops. Immunofluorescence on the paraffin section with FITC-conjugated anti-IgG antibody

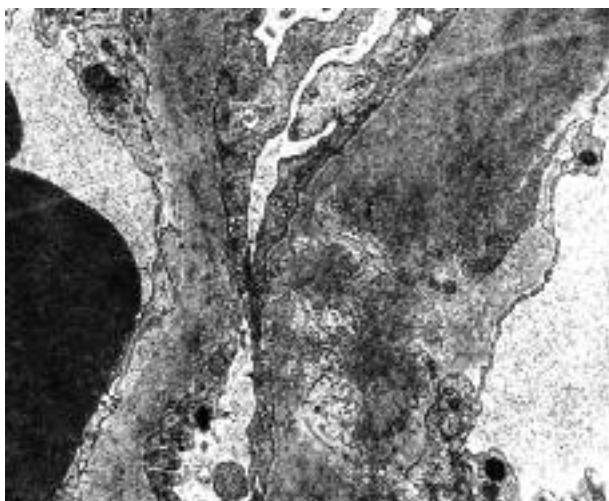


Fig. 5. Fibrillary deposits disrupting the glomerular basement membrane and expanding the subepithelial and subendothelial space. Effacement of visceral epithelial cell foot processes. Electron microscopy

Discussion

Chronic kidney disease in patients with diabetes is usually referred to as diabetic nephropathy. However, the onset of nephropathy that occurs in type 2 diabetics is rarely confirmed by renal biopsy [3]. Recent data show that the prevalence of non-diabetic renal disease (NDRD) in type 2 diabetics exceeds 40% [4]. According to different reports, IgA nephropathy and membranous nephropathy seem to be the most frequent glomerular lesions among NDRD patients. The confirmed fibrillary glomerulopathy occurs most frequently as an idiopathic disease [5] and its association with diabetes is extremely rare. So far FGN in diabetic patients has been reported only in few cases [6, 7]. A patient that was presented by the Dutch group [6] has much in common with our report. Both patients had

no evidence for diabetic retinopathy and their blood pressure and diabetes were well controlled over the past years. The etiology of FGN remains unknown suggesting that the pathogenesis depends on unspecified immune complexes. In the clinical presentation, FGN is diagnosed in the fifth life decade and the patients usually present proteinuria and mild haematuria. In renal biopsy, FGN is characterized by the deposition of non-branch, randomly arranged and Congo-negative fibrils usually localized in mesangium and capillary loops. The size of fibrils ranges from 10 to 30 nm and the diameter is twice as big as that of amyloid fibrils [8]. Immunofluorescence staining commonly reveals a ribbon-like, smudgy pattern. The differential diagnosis of FGN includes diabetic fibrillosis, an entity which was first described by Sohar *et al.* [9]. In diabetic fibrillosis, the fibrils are restricted to nodular mesangial areas and are not found along peripheral capillary walls. Moreover, the immunofluorescence profile of diabetic fibrillosis is identical to that seen in other patients with nodular diabetic glomerulosclerosis, and differs from a typical fluorescence profile in FGN [10-12]. Additionally, FGN should be distinguished from amyloidosis, where the fibers are Congo red positive with usually apple-green birefringence under polarized light [13].

The presented case emphasizes the role of renal biopsy in those patients with diabetes type 2 who have atypical symptoms. Contrary to haematuria, the lack of diabetic retinopathy seems to be a good predictor of NDRD. This association between FGN and diabetes probably has no cause-effect and it is supposed to be merely coincidental, however in that case we assumed that the result of biopsy might contribute to a better therapeutic approach. It should be indicated that in problematic cases, electron microscopy evaluation plays a crucial role in establishing the right diagnosis, which is best illuminated in the renal biopsy in question. The patient was advised to continue angiotensin receptor blocker therapy and to reduce weight. In a follow-up visit after 6 months, the patient successfully reduced weight from 92 to 86.4 kg, but the progression of deterioration of the kidney function was noticed (creatinine level 218 $\mu\text{mol/l}$). The prognosis for restoring the renal function in FGN is poor and it progresses to end-stage kidney disease. Additionally, there is a high risk of recurrence in renal transplant recipients. Despite the fact that FGN poorly responds to immunosuppressive therapy, cytotoxic agents, and there is no treatment of proven efficacy [14], the immunosuppressive protocol has been implemented. The patient started treatment with methylprednisolone (3 bolus injections of 1 g) and cyclophosphamide 1g monthly. Daily prednisone was withheld due to diabetes and obesity.

The presented case is unique for a number of reasons. First of all, it shows a possible coexistence of NDRD with one of the most common metabolic dis-

eases. Secondly, in diabetic patients without diabetic retinopathy, the impaired renal function should not be automatically attributed to diabetic nephropathy. Finally, more emphasis should be put on renal biopsies in those diabetic patients in whom the origin of renal failure remains uncertain.

All the authors declared no competing interests.

References

1. Iskandar SS, Falk RJ, Jenette JC. Clinical and pathologic features of fibrillary glomerulonephritis. *Kidney Int* 1992; 42: 1401-1407.
2. Ivanyi B, Degrell P. Fibrillary glomerulonephritis and immunotactoid glomerulopathy. *Nephrol Dial Transplant* 2004; 19: 2166-2170.
3. Pham TT, Sim JJ, Kujubu DA, et al. Prevalence of nondiabetic renal disease in diabetic patients. *Am J Nephrol* 2007; 27: 322-328.
4. Soni SS, Gowrishankar S, Kishan AG, Raman A. Non diabetic renal disease in type 2 diabetes mellitus. *Nephrology (Carlton)* 2006; 11: 533-537.
5. Rosenstock JL, Markowitz GS, Valeri AM, et al. Fibrillary and immunotactoid glomerulonephritis: distinct entities with different clinical and pathologic features. *Kidney Int* 2003; 63: 1450-1461.
6. Gonul II, Gough J, Jim K, et al. Glomerular mesangial fibrillary deposits in a patient with diabetes mellitus. *Int Urol Nephrol* 2006; 38: 767-772.
7. Gielen GA, Wetzels JF, Steenbergen EJ, et al. Fibrillary glomerulonephritis in a patient with type 2 diabetes mellitus. *Neth J Med* 2006; 64: 119-123.
8. Wągrowska-Danilewicz M. Kłębuszkowe choroby nerek w dysproteinemiach i ze zorganizowanymi złożami. *Pol J Pathol* 2011; 2 Suppl. 1: S90-S100.
9. Sohar E, Ravid M, Ben-Shaul Y, et al. Diabetic fibrillosis. *Am J Med* 1970; 49: 64-69.
10. Iskandar SS, Herrera GA. Glomerulopathies with organized deposits. *Sem Diag Pathol* 2002; 19: 116-132.
11. Howell D, Gu X, Herrera GA. Organized deposits and look-alikes. *Ultrastruct Pathol* 2003; 27: 295-312.
12. Kronz JD, Meu AM, Nadasdy T. When nonconglomerular fibrils do not represent fibrillary glomerulonephritis: nonspecific mesangial fibrils in sclerosing glomeruli. *Clin Nephrol* 1998; 50: 218-223.
13. Herrera GA, Turbat-Herrera EA. Renal diseases with organized deposits: an algorithmic approach to classification and clinicopathologic diagnosis. *Arch Pathol Lab Med* 2010; 134: 512-531.
14. Nasr SH, Valeri AM, Cornell LD, et al. Fibrillary glomerulonephritis: a report of 66 cases from a single institution. *Clin J Am Soc Nephrol* 2011; 6: 775-784.

Address for correspondence

Krzysztof Wróblewski MD, PhD
 Department of Internal Medicine and Nephrodiabetology
 Medical University of Lodz
 ul. Żeromskiego 113
 90-549 Łódź
 e-mail: krzysztof.wroblewski@umed.lodz.pl