

LETTER TO THE EDITOR

Re: Co-existence of intramuscular spindle cell lipoma with an intramuscular ordinary lipoma: Report of a case Ivan Chernev, Shane Mctighe, Dirk P. Stanley

AGGELOS LALIOU¹, EELCO DE BREE², STAVRIANTHI VASILAKI³, MICHAEL PAPADAKIS⁴, JOHN MELISSAS²

¹Department of Surgery, St Thomas' Hospital, Guy's and St Thomas' NHS Foundation Trust, London, UK

²Department of Surgical Oncology, University Hospital, Heraklion, Greece

³Radiology Department, Asklipios Diagnostic Center, Heraklion, Greece

⁴Department of Pathology, University Hospital, Heraklion, Greece

Dear Editor,

We read the Letter to the Editor submitted by Chernev *et al.*, in which the authors challenge the description of our case which concerned the co-existence of an intramuscular spindle cell lipoma with an intramuscular ordinary lipoma with great interest [1]. It is quite unusual to question so intensely data which have been presented by colleagues. Certainly, our description of this rare case only includes data of complete verity.

Chernev *et al.* contend that since no MRI of the ordinary lipoma was provided, its anatomical relationship with the spindle cell lipoma had not been demonstrated. Since the number of figures in a case report is usually limited, simply mentioning its image findings in the manuscript should be considered sufficient. Thus, we had not included radiographic images of the ordinary lipoma in our manuscript. As described, the synchronous existence of both lesions was initially detected at a CT scan made for staging, as sarcoma was suspected after core needle biopsy. Unfortunately, we cannot provide an appropriate 3D reconstruction of the area of interest, since we have only films and no digital CT scan file. However, the ordinary CT films provide clear evidence that this case concerns two different chest wall tumors (Fig. 1A-H of this response letter).

Further, Chernev *et al.* questioned whether the spindle cell lipoma was intramuscular, as noted in our manuscript, and suggest that its localization might be intermuscular instead. As demonstrated in Fig. 1 (MRI) and 2 (surgical specimen) of our case report, the lesion was evidently intramuscular. This observation can be further supported by Fig. 1A and 1B of this response letter.

The authors of the Letter to the Editor expressed their interest in the type of the ordinary lipoma. We had not specified whether the lipoma was well-circumscribed or infiltrative, since we considered this fact of minor importance. However, for their information, it concerned a well-circumscribed type (Fig. 2 of this response letter) which had been simply enu-

cleated out of its pseudocapsule during the surgical procedure.

Subsequently, we cordially thank Chernev *et al.* for their comment that the other four cases with concurrent spindle cell and ordinary lipoma, which have been previously published and are referred to in the discussion of our manuscript, concern cases with subcutaneous or unspecified localization of the spindle cell lipoma or with existence of a spindle cell lipoma in an intramuscular ordinary lipoma in a single lesion. Their observation makes our presented case all the more rare and unique due to the co-existence of intramuscular spindle cell lipoma and intramuscular ordinary lipoma as two separated masses in one patient.

The authors of the Letter to the Editor suggested that cytogenetic analysis of the spindle cell lipoma should have been performed. Although indeed in some cases of lipomatous tumors cytogenetic analysis might be helpful in their differential diagnosis, it is definitely not a standard procedure in cases in which the histological diagnosis is not in doubt [2, 3]. Moreover, cytogenetic analysis is of limited value in the case of spindle cell lipoma. Although cytogenetic analysis of spindle cell lipomas has revealed 13q and 16q deletions, unfortunately these cytogenetic alterations are not seen in all spindle cell lipomas and are in addition observed in other lipomatous tumors [3, 4]. The authors also suggest that cytogenetic alterations may be of prognostic value for local recurrence of spindle cell lipomas. Unfortunately, they do not provide any literature data to support their assumption and, as far as we know, such data have not been reported.

Chernev *et al.* stressed that the follow-up period of our patients is short. Because the rarity of the co-existence of those benign lipomatous tumors was the focal point and reason for this case report, we had not mentioned detailed follow-up data. Therefore, only the fact that the ordinary lipoma had significantly increased in size six months after the excision of the spindle cell lipoma had been noted. Complementarily, we can inform you that, to date, five years after the

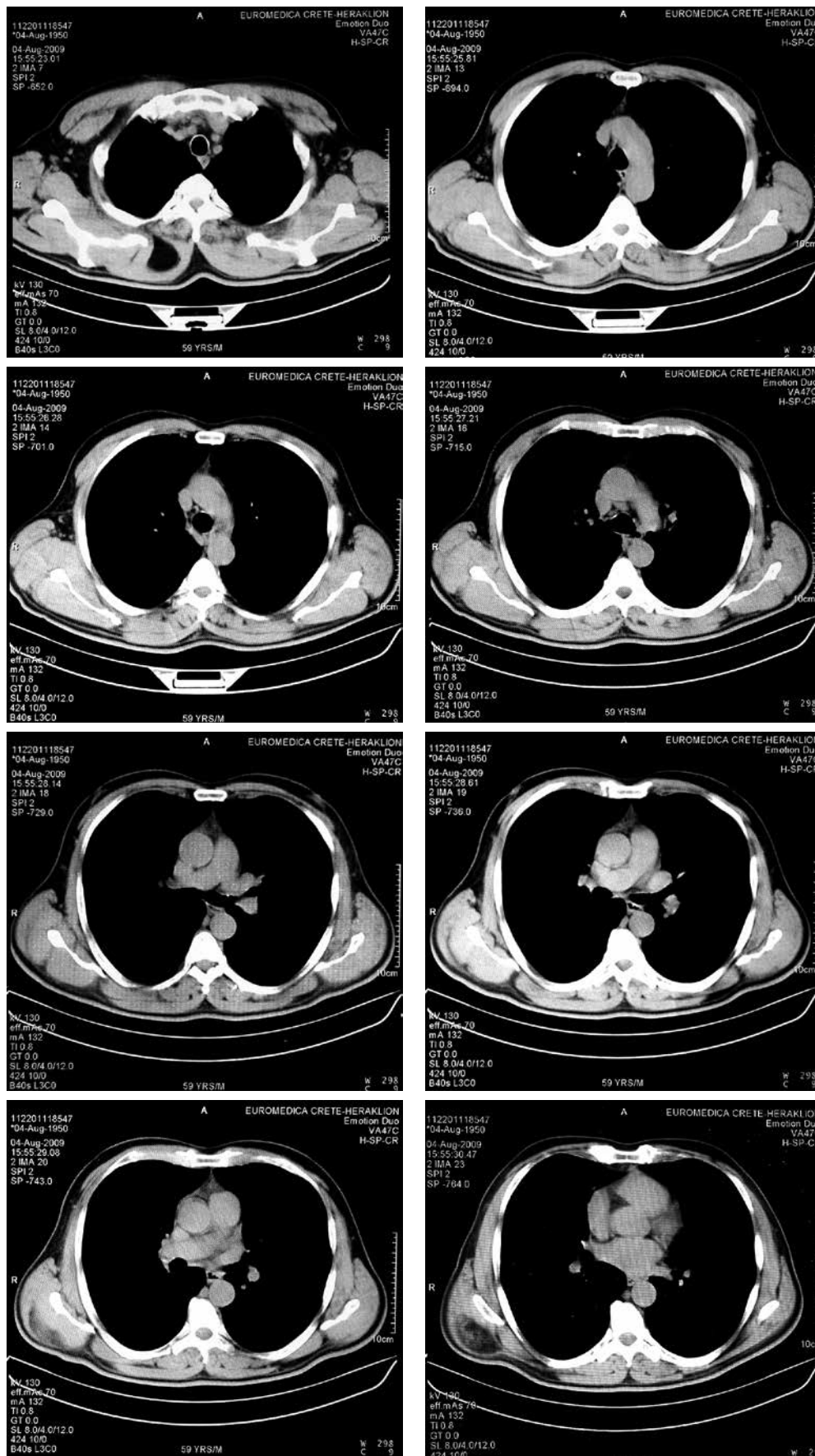


Fig. 1. CT scan of the chest (7-mm slices) demonstrates the ordinary lipoma in the right major rhomboid muscle (A), the lowest level at which this lipoma can be seen (B), an area without any lesion (C-F), the highest level at which the spindle cell lipoma in the right latissimus dorsi muscle can be seen (G) and the central part of the latter lipoma

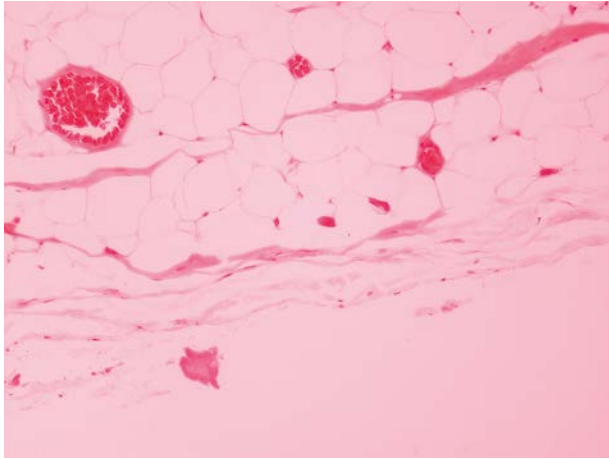


Fig. 2. Histological examination of the secondarily removed tumor (HE staining, magnification 200 \times) revealed a well described ordinary lipoma with mature fatty tissue surrounded by a layer of its fibrous pseudocapsule

excision of the spindle cell lipoma, local recurrence of either tumor has not been observed during follow-up examinations.

In conclusion, it is regrettable that colleagues express such disbelief in the data provided in a case description. The statement of Chernev *et al.* that "... it is very possible that the two masses presented in this case in fact represent *a single mass* with heterogeneous histological findings which grew *intermuscular* with eventual secondary muscular invasion." is definitely false, as demonstrated above. This unique case concerns *two separate lesions*, a spindle and an ordinary lipoma, which were both located *intramuscularly* and detected concurrently in one patient. Regarding their assumption that cytogenetic analysis should have been performed, we note that this is definitely not a standard procedure and, moreover, is of limited value in spindle cell lipomas, as discussed above.

References

1. Laliotis A, de Bree E, Vasilaki S, et al. Co-existence of intramuscular spindle cell lipoma with an intramuscular ordinary lipoma: report of a case. *Pol J Pathol* 2013; 64: 224-227.
2. de Bree E, Karatzanis A, Hunt JL, et al. Lipomatous tumours of the head and neck: a spectrum of biological behavior. *Eur Arch Otorhinolaryngol* 2014 May 7 [Epub ahead of print].
3. Nishio J. Contributions of cytogenetics and molecular cytogenetics to the diagnosis of adipocytic tumors. *J Biomed Biotech* 2011; 2011: 524067.
4. Miettinen MM, Mandahl N. Spindle cell lipoma / pleomorphic lipoma. In: WHO classification of tumors. Pathology and genetics of tumours of soft tissue and bone. Fletcher CDM, Unni K, Mertens F (eds.). IARC Press, Lyon 2002; 31-32.

Address for correspondence

Aggelos Laliotis, MD
 Department of Surgery
 St Thomas' Hospital, Guy's and St Thomas' NHS Foundation Trust
 Westminster Bridge Road
 London, UK
 SE1 7EH
 tel. +447596428020
 e-mail: laliotisac@gmail.com