

Quiz

CORRECT ANSWER TO THE QUIZ. CHECK YOUR DIAGNOSIS

SEBACEOUS TRICHOFOLLICULOMA OF THE CHEEK IN A 65-YEAR-OLD MAN

ASMAA GABER ABDOU, NANCY YOUSSEF ASAAD

Pathology Department, Faculty of Medicine, Menofiya University, Egypt

Sebaceous trichofolliculoma is considered as hamartomatous lesion with follicular differentiation. In this study, we demonstrated a classic histopathologic picture of sebaceous trichofolliculoma in a 65-year-old male presented with large sized right cheek swelling.

Key words: sebaceous trichofolliculoma, cheek, hamartoma, hair follicles.

Introduction

Sebaceous trichofolliculoma is a variant of trichofolliculoma (TF), which is considered as a hamartomatous lesion with follicular differentiation. In this report we describe a classic case of TF present as a cheek mass in a 65-year-old man.

Discussion

Trichofolliculoma usually arises in skin of the face, neck and scalp [1] but it can arise in other sites, such as the vulva [2] and penis [3]. Affection of cheek similar to that seen in our case was also reported [4]. The age of TF greatly varied from young age (7 years) [5] to very old one (86 years) [6].

The present case represents the classic histopathologic picture of TF that also showed dense inflammation. Inflammation may be absent in TF or present in variable degrees [7]. TF usually presents with a single nodule with or without pore formation, its size varies greatly from 0.3 cm up to 1.8 cm according to Wu, 2008 [7]. The case under discussion concern large nodule that reached 4 cm in maximal diameter. Folliculosebaceous cystic hamartoma is an intimately

related lesion to TF that may reach giant forms up to 15 cm [8]. The two entities shared each other in histopathological changes of hair follicles but mesenchymal changes are more apparent in folliculosebaceous cystic hamartoma [9]. Schulz and Hartschuh [9] proposed that folliculosebaceous cystic hamartoma is a late-stage of TF and represents an abnormal variant along the normal hair follicle cycle of regression.

The authors declare no conflict of interest.

References

1. Lim P, Kossard S. Trichofolliculoma with mucinosis. *Am J Dermatopathol* 2009; 31: 405-406.
2. Peterdy GA, Huettner PC, Rajaram V, Lind AC. Trichofolliculoma of the vulva associated with vulvar intraepithelial neoplasia: report of three cases and review of the literature. *Int J Gynecol Pathol* 2002; 21: 224-230.
3. Nomura M, Hata S. Sebaceous trichofolliculoma on scrotum and penis. *Dermatologica* 1990; 181: 68-70.
4. Seong SY, Kim BG, Lee HR, Hong HJ. A case of sebaceous trichofolliculoma on the right cheek. *Korean J Otorhinolaryngol-Head Neck Surg* 2011; 54: 650-653.
5. Park HC, Lee HB, Oh SJ. A case of sebaceous trichofolliculoma in lower eyelid margin. *J Korean Ophthalmol Soc* 1994; 35: 1291-1294.

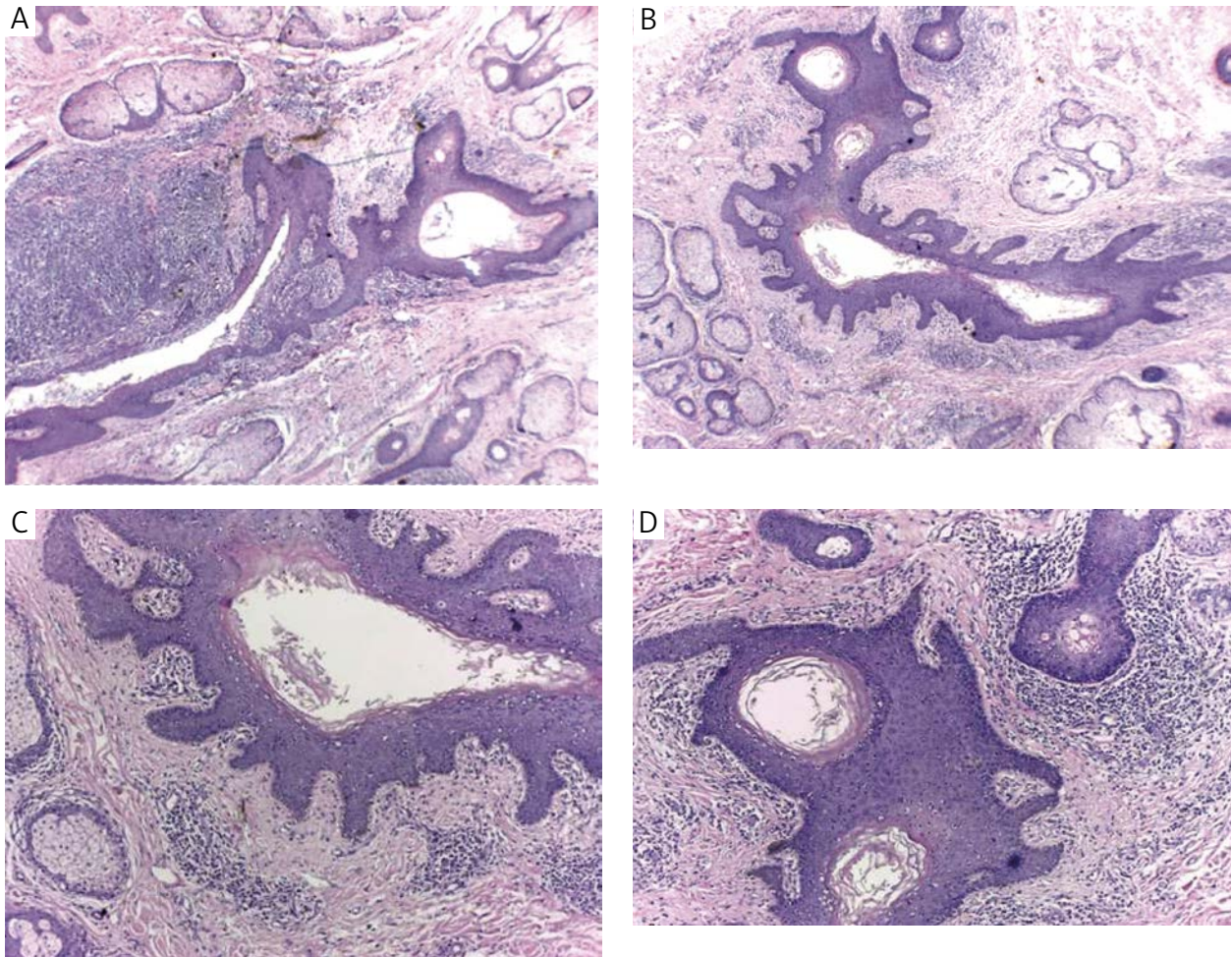


Fig. 1. Sebaceous trichofolliculoma with the characteristic dilated primary follicles filled with keratin and radiating secondary follicles associated with sebaceous lobules. Dense inflammation surrounding the dilated pilosebaceous units (HE staining $\times 100$ for **A**, and **B**, $\times 200$ for **C** and **D**)

6. Ryu HJ, Song HJ, Oh C. A case of sebaceous trichofolliculoma. *Korean J Dermatol* 2003; 41: 1662-1663.
7. Wu YH. Folliculosebaceous cystic hamartoma or trichofolliculoma? A spectrum of hamartomatous changes induced by perifollicular stroma in the follicular epithelium. *J Cutan Pathol* 2008; 35: 843-848.
8. Cole P, Kaufman Y, Dishop M, Hatfeh DA, Hollier L. Giant, congenital folliculosebaceous cystic hamartoma: a case against a pathogenetic relationship with trichofolliculoma. *Am J Dermatopathol* 2008; 30: 500-503.
9. Schulz T, Hartschuh W. The trichofolliculoma undergoes changes corresponding to the regressing normal hair follicle in its cycle. *J Cutan Pathol* 1998; 25: 341-353.

Address for correspondence

Asmaa Gaber Abdou
Faculty of Medicine
Pathology Department
Maxcem street
002 Shebein Elkom, Egypt
e-mail: asmaa_elsaidy@yahoo.com