

CASE REPORT

MERCURY-INDUCED NEPHROTIC SYNDROME: A CASE REPORT AND REVIEW OF THE LITERATUREMAŁGORZATA WĄGROWSKA-DANILEWICZ¹, MARIAN DANILEWICZ², ZBIGNIEW ZBROG³¹Department of Nephropathology, Medical University of Lodz, Lodz, Poland²Department of Pathomorphology, Medical University of Lodz, Lodz, Poland³Department of Nephrology, M. Kopernik District Hospital, Lodz, Poland

A 42-year-old man was admitted to the Nephrology Department because of nephrotic syndrome. Eight months prior to admission he attempted suicide by intravenous self-injection of 2.5 ml of elemental mercury. Renal biopsy was performed. Light microscopy findings showed normal glomeruli and injury of proximal tubular cells. Immunofluorescence was negative, and electron microscopy study revealed diffuse effacement of podocyte foot processes and vacuolization of podocyte cytoplasm. Minimal change disease was diagnosed. The patient was treated with 2,3-dimercaptopropane-1-sulfonate, for mercury detoxification, and steroids. In one-year follow-up the 24-h urine protein excretion decreased from 30 g to 0.186 g, and the renal function remain normal. The presented case indicates that mercury intoxication should be mentioned as a cause of secondary minimal change disease.

Key words: mercury intoxication, nephrotic syndrome, minimal change disease.

Introduction

Nephrotic syndrome is defined on the basis of presence of heavy proteinuria (≥ 3.5 g/24 h), accompanied by hypoalbuminemia, hyperlipidemia, lipiduria, and edema. It is a common clinical manifestation of glomerular diseases. The causes of the nephrotic syndrome include primary glomerular lesions of minimal change disease, membranous nephropathy, focal/segmental glomerulosclerosis, membranoproliferative glomerulonephritis, and other idiopathic glomerulopathies. Among the common secondary forms of nephrotic syndrome are diabetic nephropathy, multisystem diseases (systemic lupus erythematosus), amyloidosis, and neoplasia. Exposure to various drugs and toxins is less often a cause of secondary nephrotic syndrome.

It is well known that mercury can affect renal function [1-3]. The toxic effects of mercury depend on the compound to which the patient is exposed and the intensity and duration of exposure. Acute

exposure to large doses of mercury chloride leads to acute tubular necrosis. Prolonged exposure to mercury chloride may lead to chronic renal failure. Several mercury compounds, including ammoniated mercury skin lightening creams, and diuretics, have been reported to produce nephrotic syndrome [4-10].

Case report

A 42-year-old man was admitted to the Nephrology Department because of nephrotic syndrome. Eight months prior to the admission he attempted suicide by intravenous self-injection of 2.5 ml of elemental mercury, obtained after breaking a thermometer. On examination he presented peripheral edema, and a non-healing ulcer on his left antecubital fossa. X-ray showed subcutaneous radioopaque deposits in this region (Fig. 1). X-ray (Fig. 2) and chest CT revealed multiple opaque deposits throughout the lungs. Similar deposits were seen in the pelvis on X-ray pictures of the abdomen (Fig. 3), and on CT scans of the cen-

tral nervous system, liver, heart and kidneys. The concentration of mercury in his urine was elevated up to $830 \mu\text{g/l}$. Serum creatinine level was 1.34 mg/dl .

Renal biopsy was performed. The samples were embedded in paraffin and sectioned at $2 \mu\text{m}$, followed by HE, Masson, periodic acid-Schiff, periodic acid-silver methenamine, and Congo red staining. For immunofluorescence staining, the samples were sectioned in frozen conditions, followed by staining for IgG, IgA, IgM, C3, C1q, kappa and lambda light chain. The electron microscopy observations were done with JEM 1011 electron microscopy after routine staining.

Light microscopy showed 7 normal glomeruli (Fig. 4) and 3 completely sclerosed glomeruli. Tubular cells demonstrated flattening of epithelium, desquamation of epithelial cells, and exfoliation of the brush border membrane of proximal tubules (Fig. 5). In the interstitium focal inflammatory infiltrates composed of lymphocytes were seen. Immunofluorescence microscopy was completely negative. Electron microscopy revealed prominent visceral epithelial cell foot-process effacement, vacuolization, and microvillous transformation of podocytes (Fig. 6). Electron microscopy study did not show electron dense deposits in glomeruli. Based on the renal biopsy findings, minimal change disease and tubular injury were diagnosed.

The patient was treated with 2,3-dimercaptopropane-1-sulfonate, for mercury detoxification, and steroids. In one-year follow-up the 24-h urine protein excretion decreased from 30 g to 0.186 g, and the renal function remains normal.

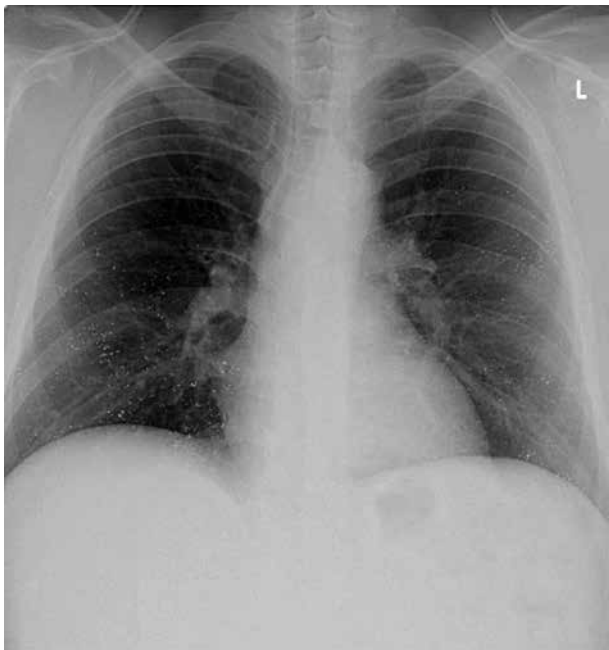

Fig. 2. X-ray of chest showing diffuse radio-opaque mercurial deposits throughout the lung fields

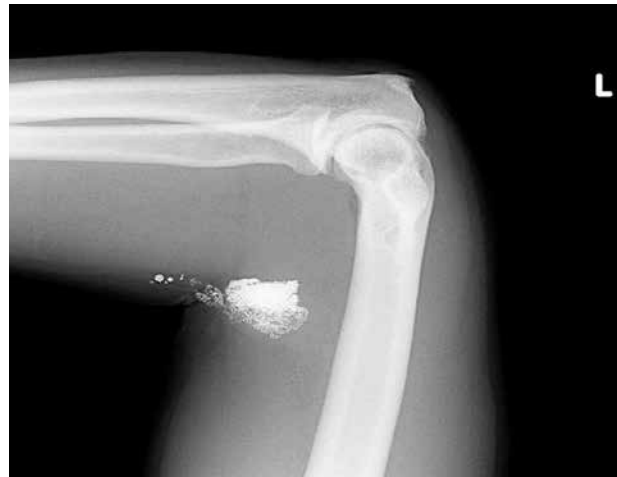

Fig. 1. X-ray of left arm showing subcutaneous radio-opaque deposits in antecubital fossa

Discussion

Mercury exists in three forms: elemental mercury, organic mercury, and inorganic mercury. Elemental mercury is a silvery liquid at room temperature. Organic mercury compounds are formed when mercury combines with carbon. Inorganic mercury compounds are formed when mercury combines with other elements, such as sulfur or oxygen, and can occur naturally in the environment. Microscopic organisms in water and soil can convert elemental and inorganic mercury into an organic mercury compound, which accumulates in the food [11]. Mercury is used in the manufacture of technical and medical instruments, as well as certain types of fluorescent lamps, and is

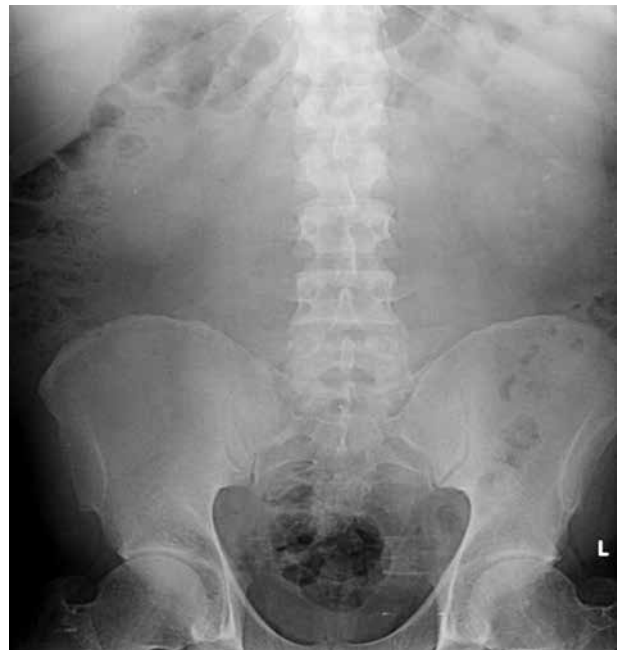

Fig. 3. X-ray of abdomen showing radio-opaque deposits in pelvis

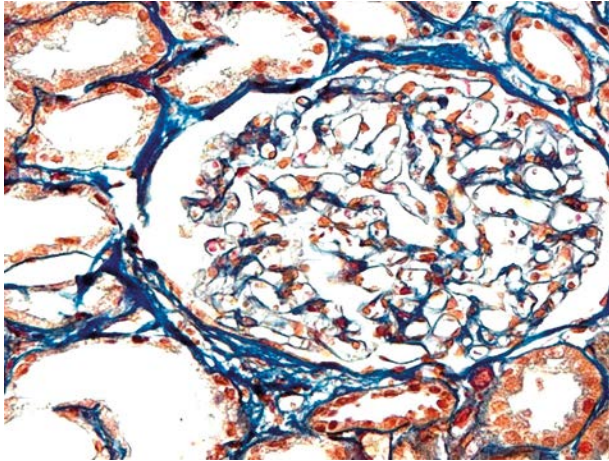


Fig. 4. Kidney biopsy showing normal appearing glomerulus. Masson staining, magnification 400×

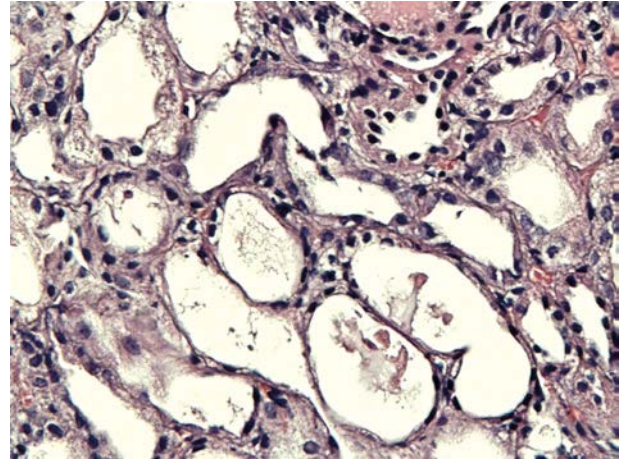


Fig. 5. Kidney biopsy showing flattening of epithelium and desquamation of epithelial cells. PAS staining, magnification 400×

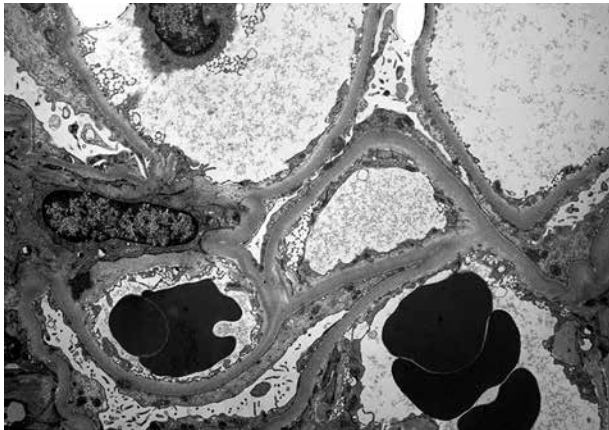


Fig. 6. Kidney biopsy. Electron microscopy showing prominent visceral epithelial cell foot process effacement and microvillous transformation of podocytes. Magnification 6000×

a component of dental silver amalgams. Mercury was used to treat syphilis and other infectious diseases, and is still used today in vaccinations and in some medicines as a preservative. Mercury can be absorbed into the body through inhalation, ingestion, absorption through skin, and injection. Intravenous mercury injection is usually seen in suicide attempts.

Mercury has strong affinity for the renal tissue. Nephrotoxicity is commonly manifested as nephrotic syndrome and tubular injury [1, 3]. Mercury-associated nephrotic syndrome is reversible after elimination of the source of intoxication. The literature data from 1950 to 2010 concerning toxic mercury exposure and nephrotic syndrome described: 4 cases of minimal change disease, 15 cases of membranous glomerulonephritis, and 1 case of chronic proliferative glomerulonephritis [12]. It is well known that secondary minimal change disease may occur as a complication of certain forms of drug therapy, several malignancies, food allergies and viral infection, but it is rather rarely diagnosed in mercury poisoning. In the

presented case the pathological diagnosis of minimal change disease was confirmed by light microscopy, immunofluorescence, and electron microscopy findings. Immunofluorescence was completely negative, and electron microscopy did not show deposits in the glomeruli. To our best knowledge, this is the first biopsy proven case of mercury-poisoning-associated minimal change disease in Poland. In 1972 Barr *et al.* [13] reported minimal change glomerular lesions in African women in Kenya who used mercury-containing skin lightening creams. In other reports, minimal change glomerular lesions were associated with the use of mercurial diuretics and occupational contact with mercury. In 2009 Campbell *et al.* [14] described a case of biopsy-confirmed minimal change disease following occupational exposure to mercury vapor in a man working at a fluorescent light factory. In 2013 Tang *et al.* [15] reported 4 cases of minimal change disease following exposure to mercury-containing skin-lightening cream for 2-6 months. In 2013 Saleem *et al.* [16] described a case of minimal change disease with nephrotic syndrome in mercury poisoning from home gold amalgam extraction.

Subcutaneous or intravenous self-injection of elemental mercury is rare and is often part of a suicide attempt. It is thought that subcutaneous injection has a low risk of systemic toxicity. Mercury is carried by the circulation and reaches internal organs over a period of time. Gopalakrishna and Pavan Kumar [17] described two cases of intravenous injection of elemental mercury intended to be an aphrodisiac. One of their patients succumbed, and the other remained asymptomatic two years after the surgical removal of all the injected mercury. Priva *et al.* [18] reported a case of attempted suicide by intravenous self-injection of elemental mercury. Their patient suffered from membranous nephropathy and aplastic anemia.

Mercury-induced membranous nephropathy is due to long-term use of mercury-containing skin lightening cosmetics or occupational contact with mercury [4-6, 11, 19]. Aymaz *et al.* [4] reported membranous nephropathy in two patients from exposure to mercury in the fluorescent tube recycling industry. Shi-Jun *et al.* [20] described 11 patients with a clear history of contact with mercury-containing preparations or staying in a mercury-containing environment who presented with proteinuria or nephrotic syndrome and normal renal function with biopsy-proven membranous nephropathy. In those cases light microscopic findings were identical with idiopathic membranous nephropathy, but the immunofluorescence findings showed granular deposits of IgG, predominantly IgG1, and C3 along the glomerular capillary wall, mostly accompanied by deposits of C4 and C1q. They concluded that deposits of IgG1 subclass in renal tissue indicated that the pathogenesis of mercury-induced membranous nephropathy differs from the idiopathic form of this glomerulopathy.

The mechanism of glomerular injury in mercury-related glomerulopathies is not clear. It has been suggested that nephrotic syndrome following mercury exposure is due to idiosyncratic reactions or an abnormal immune response to the heavy metal. Mercury components can have immunomodulating activity [21]. Mercuric chloride and methylmercury inhibit most animal and human lymphocyte functions including proliferation, expression of cell activation markers on the cell surface and cytokine production. Experimental data showed that Brown Norway rats injected with mercuric chloride develop autoantibodies which immunolocalize along the glomerular basement membrane at first in a linear pattern and then in a granular pattern [22]. In this model, the interaction of anti-laminin and type IV collagen antibodies with antigens secreted by glomerular visceral epithelial cells might, together with other mechanisms, contribute to the formation of granular immune deposits in the subepithelial part of the glomerular basement membrane. In an experimental study in Dorus-Zadel Black rats exposed to mercuric chloride Aten *et al.* [23] showed that IgG1 and IgG2 antibodies, eluted from glomeruli with subepithelial immune deposits, bind to the glomerular basement membrane and epithelial cell interface, causing focal ultrastructural transformations of the podocytes. No reactivity was found with type IV collagen, fibronectin, heparin sulfate proteoglycans, or tubular brush border antigens. The authors concluded that mercury-induced membranous glomerulopathy is caused by autoantibodies to basement membrane components which are located at the epithelial cell-basement membrane interface and may be involved in cell-matrix binding. The mechanism of renal injury in mercury-associated

minimal change disease is not evident. It is speculated that genetic factors and dysregulation of the immune system with lymphokine production may be responsible for renal lesions [24].

Mercury is a well-known cause of nephrotic syndrome, but the underlying renal pathology in most of the reported cases is membranous glomerulopathy. The present case shows that mercury intoxication should be taken into consideration as a cause of secondary minimal change disease.

The authors declare no conflict of interest.

This work was supported by grant of Medical University of Lodz 503/6-038-01.

References

- Gonick HC. Nephropathies in heavy metal intoxication. In: Massry SG, Glassock RJ. Massry & Glassock's Textbook of nephrology (eds.). 4th ed. Lippincott William & Wilkins, Philadelphia 2001; 933-934.
- George CR. Mercury and the kidney. *J Nephrol* 2011; 24 (Suppl. 17): 126-132.
- Hill G. Drug-associated glomerulopathies. *Toxicol Pathol* 1986; 14: 37-44.
- Aymaz S, Gros O, Krakamp B, et al. Membranous nephropathy from exposure to mercury in the fluorescent-tube-recycling industry. *Nephrol Dial Transplant* 2001; 16: 2253-2255.
- Cameron JS, Trounce JR. Membranous glomerulonephritis and the nephrotic syndrome appearing during mersalyl therapy. *Guys Hospi Rep* 1965; 114: 101-107.
- Chakera A, Lasseron D, Beck LH Jr, et al. Membranous nephropathy after use of UK-manufactured skin creams containing mercury. *Q J Med* 2011; 104: 893-896.
- Munck O, Nissen NI. Development of nephrotic syndrome during treatment with mercurial diuretics. *Acta Med Scand* 1956; 153: 307-313.
- Soo Yo, Chow KM, Lam CW, et al. A whitened face woman with nephrotic syndrome. *Am J Kidney Dis* 2003; 41: 250-253.
- Tang HL, Chu KH, Mak YF, et al. Minimal change disease following exposure to mercury-containing skin lightening cream. *Hong Kong Med J* 2001; 12: 316-318.
- Kazantzis G, Schiller KF, Asscher AM, et al. Albuminuria and the nephrotic syndrome following exposure to mercury and its compounds. *Q J Med* 1962; 31: 403-418.
- [http://www.who.int/mediacentre/factsheets/fs361/en/WHO Mercury and health. Fact sheet N°361.](http://www.who.int/mediacentre/factsheets/fs361/en/WHO_Mercury_and_health_Fact_sheet_N°361)
- Miller S, Shelley P, Gangji A, et al. Mercury-associated nephrotic syndrome: A case report and systematic review of the literature. *Am J Kidney Dis* 2013; 62: 135-138.
- Barr RD, Rees PH, Cordy PE, et al. Nephrotic syndrome in adult Africans in Nairobi. *Br Med J* 1972; 2: 131-134.
- Campbell G, Leith D, Lewington A, et al. Minimal-change nephrotic syndrome due to occupational mercury vapor inhalation. *Clin Nephrol* 2001; 72: 216-219.
- Tang HL, Mak YF, Chu KH, et al. Minimal change disease caused by exposure to mercury-containing skin lightening cream: a report of 4 cases. *Clin Nephrol* 2013; 79: 326-329.
- Saleem M, Alfred S, Bahnisch RA, et al. Mercury poisoning from home amalgam extraction. *Med J Aust* 2013; 199: 125-127.
- Gopalakrishna A, Pavan Kumar TV. Intravenous injection of elemental mercury: A report of two cases. *Indian J Plast Surg* 2008; 4: 214-218.

18. Priva N, Nagaprabhu VN, Kurian G, et al. Aplastic anemia and membranous nephropathy induced by intravenous mercury. *Indian J Nephrol* 2012; 22: 451-454.
19. Oliveira DBG, Foster G, Savill J, et al. Membranous nephropathy caused by mercury-containing skin lightening cream. *Postgrad Med J* 1987; 63: 303-304.
20. Shi-Jun Li, Su-Hua Z, Hui-Ping C, et al. Mercury-induced membranous nephropathy: Clinical and pathological features. *Clin J Am Soc Nephrol* 2010; 5: 439-444.
21. Moszczyński P. Mercury compounds and the immune system: a review. *Int J Occup Med Environ Health* 1997; 10: 247-258.
22. Fukatsu A, Brentjens JR, Killen PD, et al. Studies on the formation of glomerular immune deposits in brown Norway rats injected with mercuric chloride. *Clin Immunol Immunopathol* 1987; 45: 35-47.
23. Aten J, Veninga A, Bruijn JA, et al. Antigenic specificities of glomerular-bound autoantibodies in membranous glomerulopathy induced by mercuric chloride. *Clin Immunol Immunopathol* 1992; 63: 89-102.
24. Belghiti D, Patey O, Berry JP, et al. Lipoid nephrosis of toxic origin 2 cases. *Presse Med* 1986; 15: 1953-1955.

Address for correspondence

Małgorzata Wągrow ska-Danilewicz
Department of Nephropathology
Medical University of Lodz
Pomorska 251
92-216 Lodz, Poland
e-mail: malgorzata.wagrowska-danilewicz@umed.lodz.pl