

ORIGINAL PAPER

CYSTOISOSPORIASIS-RELATED HUMAN ACALCULOUS CHOLECYSTITIS: THE NEED FOR INCREASED AWARENESSMAHMOUD AGHOLI^{1,2}, ELHAM ALIABADI³, GHOLAM REZA HATAM⁴¹HIV/AIDS Research Center, Fasa University of Medical Sciences, Fasa, Iran²Department of Microbiology, Fasa University of Medical Sciences, Fasa, Iran³Department of Anatomy, School of Medicine, Shiraz University of Medical Sciences, Shiraz, Iran⁴Basic Sciences in Infectious Diseases Research Center, Shiraz University of Medical Sciences, Shiraz, Iran

Cholecystitis is one of the common surgical indications affecting human beings in many countries. A variety of infectious agents can be associated with acute or chronic acalculous cholecystitis, especially in HIV/AIDS patients. In this investigation, the authors aim to describe two cases of histologically and molecularly documented cystoisosporiasis (syn. isosporiasis) as the cause of chronic acalculous cholecystitis in two immunodeficient patients.

During microscopic examinations of more than 2500 diarrheic patients' samples, 11 cases of cystoisosporiasis-related recurrent persistent/chronic diarrhea were detected. A review of the medical records of *Cystoisospora belli* (syn. *Isoospora belli*)-positive patients showed that two of them, i.e. a patient with prolonged corticosteroid therapy and an AIDS patient, several months prior to fecal examinations had undergone cholecystectomy due to acalculous cholecystitis. The study was continued by a review of the histopathological investigation of the recuts prepared from the excised gallbladder tissue sections and stained with hematoxylin and eosin in order to detect a possible specific clinical correlation with cystoisosporiasis. Light microscopic examination revealed the presence of various developmental stages of a coccidial parasite, namely *Cystoisospora belli*, in both patients' gallbladder tissue sections.

To the best of our knowledge, *C. belli*-associated cholecystitis has not been previously reported in a patient with prolonged corticosteroid therapy.

Key words: cholecystitis, *Cystoisospora belli*, corticosteroid therapy, AIDS.

Introduction

Cholecystitis is a common disease in many countries, often requiring surgical treatment. A variety of infectious agents may be associated with acute or chronic acalculous cholecystitis, especially in HIV/AIDS patients. Unfortunately, in as many as half of cases, no microorganisms can be identified by pathological examination [1].

Since the first description of acalculous cholecystitis with an abnormal biliary tree in an AIDS patient in 1983, AIDS cholangiopathy, a group of biliary disorders characterized by cholangitis and acalculous cholecystitis, has been a clinically significant problem for which the etiology remains obscure [2]. AIDS cholangiopathy is now recognized to result from opportunistic infections within the biliary tree. In general, the opportunistic pathogens most commonly associated with acute or chronic acalculous cholecystitis

are *Cytomegalovirus* and *Cryptosporidium*. However, the potential cause of the disease is not identified in as many as 50% of cases [3]. Recently, *Sarcocystis* has also been reported to be pathogenic in one case of AIDS-related acalculous cholecystitis [4].

In this investigation, the authors aim to describe two cases of histological and molecular documented cystoisosporiasis (syn. isosporiasis) as the cause of chronic acalculous cholecystitis in two immunodeficient patients.

Material and methods

From May 2008 to September 2015, stool samples with unknown etiology from more than 2500 subjects (from diarrheic infants to elderly patients) were obtained and investigated using the direct cover glass mount, concentration technique and Kinyoun's acid-fast stain to determine parasitic etiology at the Parasitology Laboratories of Shiraz and Fasa Universities of Medical Sciences, Fars province, Iran. The doubtful cases were also ruled out by using *Cystoisospora belli*-specific PCR.

Prior to fecal examinations, two of these patients had undergone cholecystectomy due to acalculous cholecystitis with unknown etiology. The renewed investigation was made by a review of histopathologic examination and imaging studies as well as nested-PCR techniques on the residual paraffin-embedded biopsy tissues by using specific primers of the coccidian protozoan parasites [5].

Results

During microscopic examination and *Cystoisospora belli*-specific PCR, in addition to the presence of other intestinal parasites, oocysts of *C. belli* were detected in fecal smears prepared from 11 (i.e., 2 solid organ transplant recipients, 3 cancer patients receiving antineoplastic chemotherapy, 5 AIDS patients and 1 patient on prolonged corticosteroid therapy) patients (Fig. 1A–D). A review of the medical records all of the cystoisosporiasis-positive patients, in order to detect a possible specific clinical correlation with *C. belli*, showed that they were all immunocompromised persons.

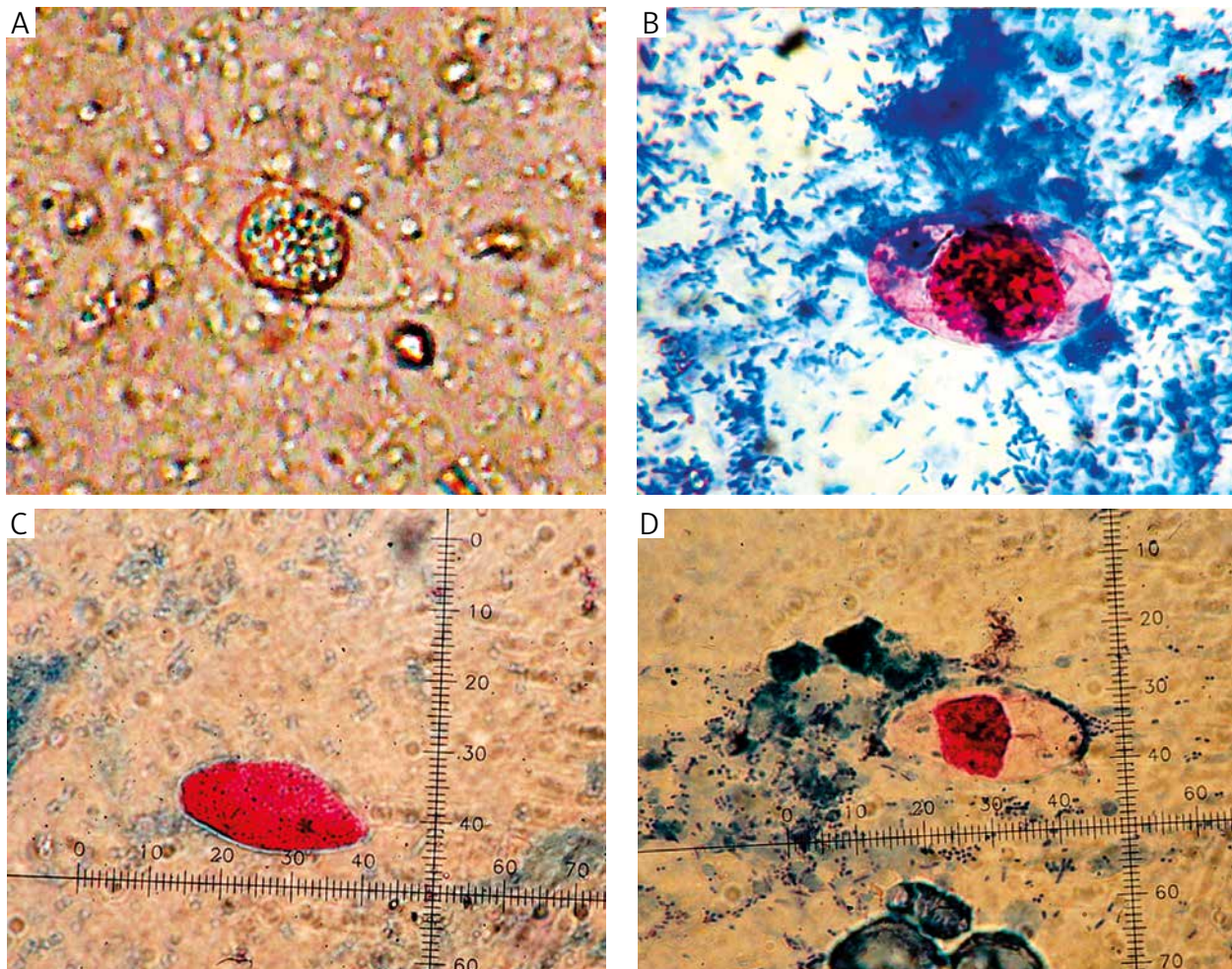


Fig. 1. A) Oocyst of *Cystoisospora belli* in direct fecal smear (original magnification 400 \times); B-D) Kinyoun's acid-fast stained fecal smears showing oocysts of *Cystoisospora belli* (original magnification 1000 \times)

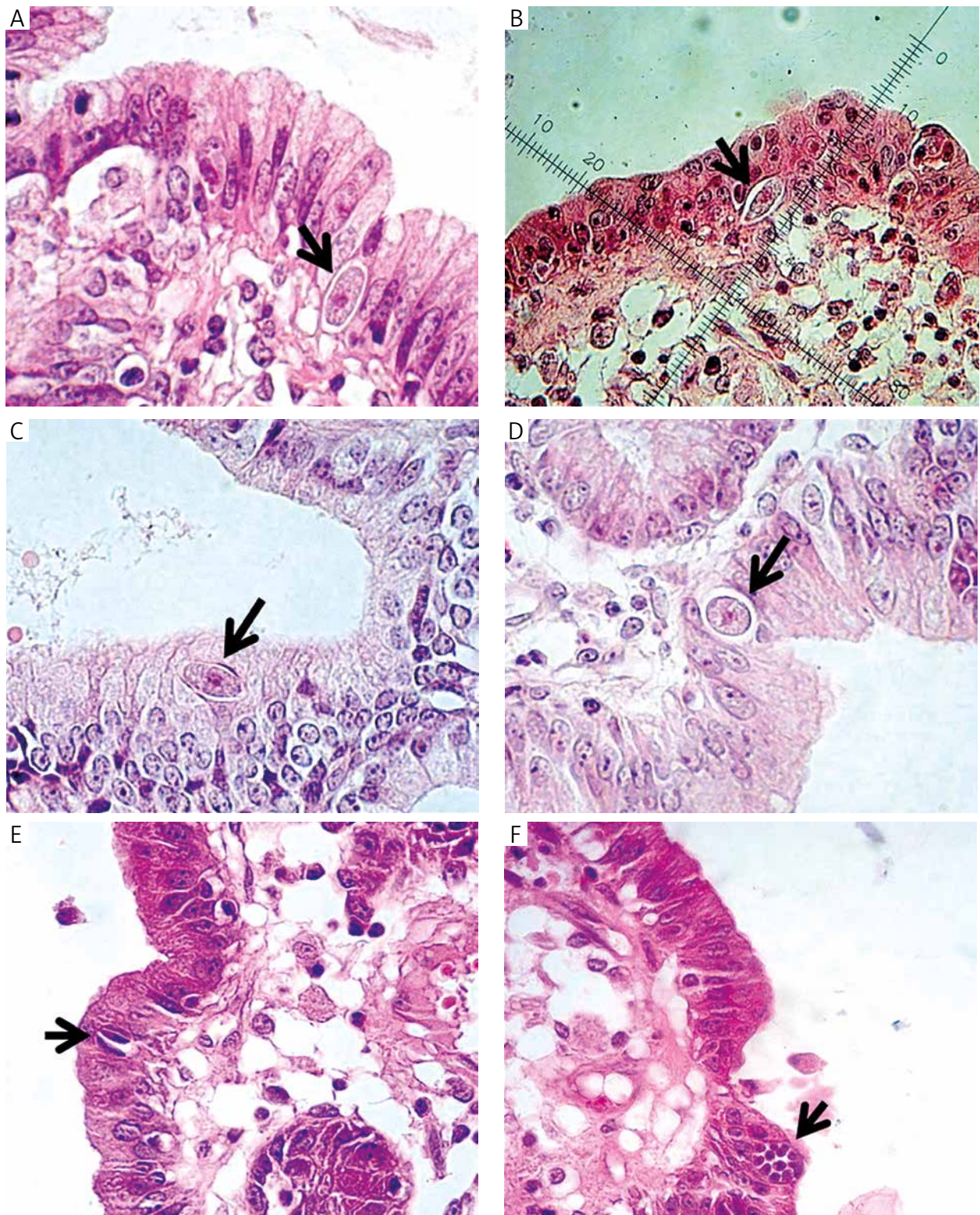


Fig. 2. *Cystoisospora belli* (syn. *Isospora belli*) in the gallbladder wall (arrows). A-C Immature oocysts are seen longitudinally and (D) cross sectionally. (E) The elongated banana-shaped zygotes were present within the cytoplasm of the epithelial cell. (F) A schizont containing developing zygotes is also present. Prominent halos surround the organisms and represent parasitophorous vacuoles (hematoxylin and eosin stain; original magnification 400 \times)

The slides examined for molecular investigation were recuts prepared from the original paraffin blocks, and no original slides were used. To do this, DNA was extracted from the rest of the residual paraffin-embedded gallbladder tissues and amplified with primers to the small subunit-ribosomal DNA (SSU-rDNA) genes of *C. belli*.

Investigations by histopathology, ultrasonography and computed tomography showed distended gallbladders with thickened walls and without calculi. Light microscopic examination of histopathological slides revealed the presence of various developmental stages (immature oocysts, zoites, schizont, etc.) of a coccidial parasite in two gallbladder tissue sections (Fig. 2A–F). In total, the microscopic and molecular characteristics of the observed microorganisms are consistent with *C. belli* (Fig. 3).

Below, we describe the two cases of chronic acalculous cholecystitis due to *C. belli* in a 25-year-old woman with prolonged corticosteroid therapy and a 35-year-old man with AIDS.

Case 1

The patient was a 25-year-old woman with a history of prolonged corticosteroid therapy from a rural area of Fars province. She was admitted to the Enteric Protozoology Laboratory, School of Medicine, Shiraz University of Medical Sciences, for stool examination.

She complained of abdominal discomfort and diarrhea. In a direct wet mount prepared from the patient's stool, oocysts of *C. belli* were seen, but no trophozoite or cyst and ova were detected. Biopsies prepared from the patient's small and large bowels showed nonspecific inflammation without parasitic infection on HE staining.

After concentration by the formol-ethyl acetate concentration technique, apart from *C. belli* (Fig. 1A), no pathogenic parasites were seen. The foul-smelling, pale yellow and liquid was suggestive of malabsorption. The patient was treated with Co-trimoxazole. The diarrhea ceased within 3 days of starting treatment. Unfortunately, the patient did not return for treatment follow-up.

Prior to fecal examination by the authors, due to symptoms and signs of cholecystitis, e.g., the tender right upper quadrant, low-grade fever, nausea, vague abdominal pain, diarrhea, belching, and elevated alkaline phosphatase, the patient had undergone cholecystectomy. Our patient had presented to a local hospital of Shiraz City, Iran, about 12 months earlier. An ultrasound of the right upper quadrant had showed thickening of the gallbladder wall with no stones, pericholecystic fluid, or dilation of the bile ducts. No pathogenic parasites had been detected in repeated microscopic examinations of the patient's fecal samples. Re-examination by light microscopy

of hematoxylin and eosin stained sections of the patient's gallbladder showed unsporulated oocysts of a coccidial infection, suggestive of *C. belli* (Fig. 2B).

Case 2

In June 2010, a 35-year-old man was admitted to a local hospital, with an episode of abdominal pain, vomiting, and diarrhea. Abdominal ultrasound showed a thick-walled gallbladder without stones and a dilated bile duct. Abdominal computed tomography also showed a dilated common bile duct without stones, mass, or chronic pancreatitis. In addition, serum liver enzymes were mildly elevated. Laparoscopic cholecystectomy for presumed cholecystitis showed a grossly thickened gallbladder wall. Moreover, routine histologic sections demonstrated

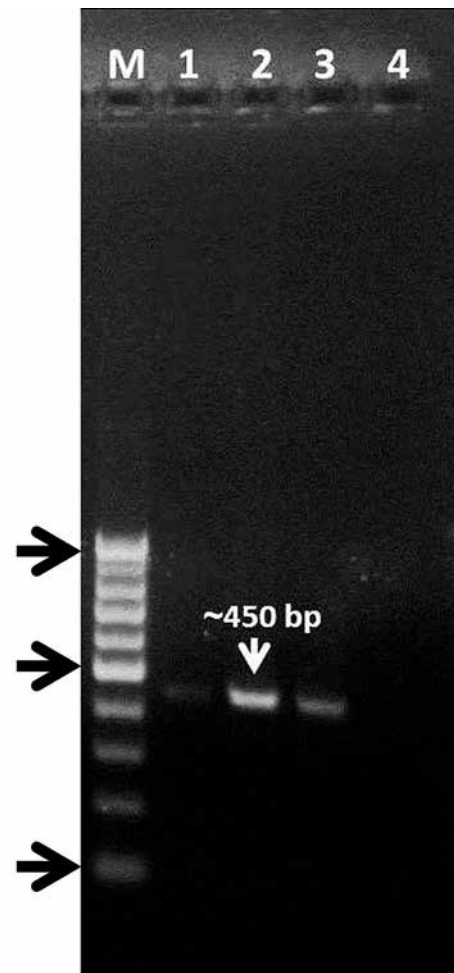


Fig. 3. A two-step nested PCR amplification of DNA from a gallbladder specimen using *Cystoisospora belli* ITS-1 rDNA locus primers. Lane M, molecular size markers; lane 1, study sample; lanes 2 and 3, positive controls (DNAs extracted from the patient's fecal samples); lane 4, negative control

chronic cholecystitis and nonspecific inflammation. Nevertheless, no pathogen was identified on hematoxylin and eosin stain. Unfortunately, due to lack of experienced personnel, the cause of the diarrhea was undetermined since repeated stool examinations revealed negative results. Of course, the clinical course after cholecystectomy was favorable.

About six months later, due to sudden onset of severe diarrhea, his stool sample was sent to the Parasitology Laboratory of Shiraz University of Medical Sciences to rule out any parasitological etiology. Also, during a histopathologic review of the gallbladder, infection with *Cystoisospora belli* was diagnosed on sections stained with hematoxylin and eosin and then confirmed by a *C. belli*-specific nested PCR of recuts from the paraffin block [4].

In all the developmental stages, a number of parasites with distinctive features of *C. belli* were seen within parasitophorous vacuoles in the cytoplasm of a number of epithelial cells. In addition, a number of nonsporulated (immature) oocysts of *C. belli*, as elongated intracellular parasites, were observed in longitudinal sections which appeared rounded on cross-sections (Fig. 2A, C, D). They show structures that are characteristic of a coccidian parasite. Intracellular elongated banana-shaped zoites of *C. belli* were present within the cytoplasm of the epithelial cells (Fig. 2E). In hematoxylin and eosin, they appeared as stained structures with a small central nucleus surrounded by clear paranuclear spaces (Fig. 2E). Furthermore, light microscopic investigation of the gallbladder mucosa revealed intracellular stages of the schizogony cycle of the parasite (Fig. 2F). However, parasites were not found in the lamina propria. Marked lymphocytic depletion was seen in the examined gallbladder wall. A DNA fragment of the expected size (~450 base pairs) was amplified from the patient's specimen, but not from the negative control (Fig. 3). Also, further investigations on the patient's medical file demonstrated that he was HIV positive. Unfortunately, he had been lost to follow-up by the time these results were obtained, and his CD4 lymphocyte count was unknown.

Discussion

Infections with *Cystoisospora belli* have been reported worldwide, usually as sporadic cases or as small clusters of cases in parasitological surveys [6]. It has been found that in tropical and subtropical countries, human *C. belli* is a prevalent cause of chronic gastroenteritis in individuals with acquired immunodeficiency syndrome [7]. Despite its worldwide distribution, cystoisosporiasis has not been well studied in Iran, and to date, human coccidiosis resulting from *C. belli* is a rare infection in Iran. In 1961, the first human enteric cystoisosporiasis in Iran was reported in

a 5-year-old girl from Tehran [8]. The second case of intestinal cystoisosporiasis was reported in a 9-year-old Iranian girl from Mashhad [9]. Another rare case of the disease was reported by other workers in a pediatric AIDS patient with severe persistent diarrhea in Iran [10]. Until now, there has been no report of *C. belli* extraintestinal infection from Iran. In this study, prior to fecal examination by the authors, the 11 patients had recurrent diarrhea of several months' duration for which no cause had been found in repeated stool examinations and small-bowel biopsies.

This member of Coccidia is now classified under the species *C. belli* because it can have extraintestinal tissue stages [11]. In general, the infection is acquired by the fecal-oral route through ingestion of infective oocysts in contaminated water or on contaminated fruits and vegetables. The common habitat of *C. belli* is the epithelial cells of the small intestine [12, 13, 14]. After ingestion of mature oocysts with food or water, the sporozoites are released in the intestinal lumen, enter the epithelial cell, and develop in the cytoplasm. The differences between *Cryptosporidium* and *C. belli* are that the latter develops in the cell cytoplasm and the oocyst is unsporulated (not infective) at the time of evacuation with feces and develops to form an infective stage containing two sporocysts in the environment [12, 13, 14]. However, person-to-person transmission is unlikely because *C. belli* oocysts are not infectious at the time of passing via stool and require a developmental period in the environment [12, 13, 14]. Cystoisosporiasis is a cause of diarrhea seen with increasing frequency in immunosuppressed or immunocompromised patients [15]. The infection is usually more severe and may be fatal in immunocompromised patients [15]. In patients with HIV/AIDS, *C. belli* often produces watery diarrhea and abdominal pain. *C. belli* has been observed in patients with concurrent Hodgkin's disease, non-Hodgkin's lymphoproliferative disease, human T-cell leukemia virus type 1-associated adult T-cell leukemia, and acute lymphoblastic leukemia. These patients respond to specific anti-*C. belli* treatment [15]. The diagnosis is most commonly made by identification of *C. belli* by microscopic examination of fecal samples or biopsy specimens. *C. belli* can cause diseases with relatively few stages of the parasite being present and can be missed on biopsy. Familiarity with the appearance of the stages is far more useful in locating them in histological samples; many parasites will be in vacuoles, making them readily identifiable [7, 11].

Unfortunately, the incidence of gallbladder cystoisosporiasis is not known. Human acalculous cholecystitis due to *C. belli* infection was first reported in 1994 from a 39-year-old homosexual man with HIV, and histopathological investigation of the gallbladder specimens stained with hematoxylin

and eosin stain revealed chronic inflammation along with stages of development with distinctive feature of *C. belli* in the thickened wall [16]. Diffuse biliary cystoisosporiasis has been also reported in a West African man who presented with acute illness and dilated bile ducts, and unknown HIV status [17]. The first case of *Sarcocystis*-related human non-calculous cholecystitis worldwide was reported in 2014 in an AIDS patient [4].

In the specimen of our cases, both the asexual and sexual stages of *C. belli* were identified, demonstrating that active, replicative infection in the gallbladder epithelium that can occur independent of overt intestinal disease. The microscopic patterns described previously by non-Iranian workers in the gallbladder and bile duct specimens of two cases are remarkably similar to the two observed in our patients [16, 17]. Also, the molecular characteristics of these microorganisms corresponded to *C. belli*. Cystoisosporiasis-related cholecystitis has been postulated to occur via dissemination from the gastrointestinal tract. We suggest that *C. belli* may reach the gallbladder as a result of contiguous spread from the gastrointestinal tract.

Cystoisosporiasis is easily overlooked on light microscopic examination of tissue biopsy specimens. Intestinal lesions induced by *C. belli* in immunocompromised patients are usually similar to those in immunocompetent patients [15]. *C. belli* microorganisms have been observed within parasitophorous vacuoles in the cytoplasm of epithelial cells of the gastrointestinal tract [7]. Therefore, familiarity with the appearance of the stages is far more useful in locating them in histological samples; many parasites will be in vacuoles, making them readily identifiable [7, 11].

To identify cystoisosporiasis, a pathologist must often be aware of the possibility of finding this microorganism [18]. Attention should be directed to the epithelial mucosal surface of the organ in question. With the incidence of HIV/AIDS anticipated to increase in the future, it is likely that the incidence of *C. belli* infection will also increase. When a patient with HIV/AIDS status or an immunosuppressed condition and recurrent diarrhea develops acalculous cholecystitis, we propose that infection with enteric opportunistic coccidian parasites be included in the differential diagnosis.

We suspect, furthermore, that this small group of patients may be the tip of the iceberg, with many more patients remaining undetected. Cystoisosporiasis can be suspected when compatible symptoms of gallbladder infection are present in conjunction with a history of recurrent and profuse loose stool or watery diarrhea in an endemic area.

To the best of our knowledge, this is the first report of cystoisosporiasis-related cholecystitis docu-

mented in a patient with prolonged corticosteroid therapy. Also, we believe there is a remarkable feature in the present cases, which make them unique. Firstly, histopathologic examination of excised gallbladders revealed various development stages of *C. belli*. Secondly, a notable difference in the light microscopic findings in these two patients is the presence of more than one zoite in the tissue cyst observed in tissue sections.

Conclusions

This study describes two cases of cystoisosporiasis as the cause of chronic acalculous cholecystitis in two immunodeficient patients. Also, these data raise the possibility that cystoisosporiasis of the gallbladder may be more prevalent than is generally appreciated. So, it is important that specialist physicians and pathologists become aware of this coccidian infection, since the number of patients with this infection is likely to increase in the near future.

The authors would like to thank Dr. Hamid Reza Heidarian, pathologist, for his kind comment.

The authors declare no conflict of interest.

References

1. Kumar Y, Abbas AK, Aster JC. Robbins and Cotran Pathologic Basis of Disease. 9th ed. ELSEVIER SUANDERS, Canada 2014; 877-879.
2. Pitlik SD, Fainstein V, Rios A, Guarda L, Mansell PW, Hersh EM. Cryptosporidial cholecystitis. N Engl J Med 1983; 308: 967.
3. French AL, Beaudet LM, Benator DA, Levy CS, Kass M, Orenstein JM. Cholecystectomy in patients with AIDS: clinicopathologic correlations in 107 cases. Clin Infect Dis 1995; 21: 852-858.
4. Agholi M, Heidarian HR, Moghadami M, Hatam GR. First detection of acalculous cholecystitis associated with *Sarcocystis* infection in a patient with AIDS. Acta Parasitol 2014; 59: 310-315.
5. Agholi M, Hatam GR, Motazedian MH. Microsporidia and coccidia as causes of persistence diarrhea among liver transplant children: incidence rate and species/genotypes. Pediatr Infect Dis J 2013; 32: 185-187.
6. Cimerman S, Cimerman B, Lewi DS. Enteric parasites and AIDS. Sao Paulo Med J 1999; 117: 266-273.
7. Lindsay DS, Dubey JP, Blagburn BL. Biology of *Isoospora* spp. from humans, nonhuman primates, and domestic animals. Clin Microbiol Rev 1997; 10: 19-34.
8. Hadjian A. Study on a case of children diarrhea and report of the first case of human coccidiosis in Iran. Revue de La Faculte de Medicine de Tehran 1961; 19:1-10.
9. Motakef M, Rezvani H, Elahi R. Coccidiosis and reports on its fourth case in Iran. Revue de La Faculte de Medicine de Mashhad 1874; 16: 530-549.
10. Nateghi Rostami M, Nikmanesh B, Haghi-Ashtiani MT, Monajemzadeh M, Douraghi M, Ghalavand Z, Kashi L. *Isoospora belli* associated recurrent diarrhea in a child with AIDS. J Parasit Dis 2014; 38: 444-446.

11. Restrepo C, Macher AM, Radany EH. Disseminated extraintestinal isosporiasis in a patient with acquired immune deficiency syndrome. *Am J Clin Pathol* 1987; 87: 536-542.
12. Pierce KK, Kirkpatrick BD. Update on human infections caused by intestinal protozoa. *Curr Opin Gastroenterol* 2009; 25: 12-17.
13. Curry A, Smith HV. Emerging pathogens: *Isoospora*, *Cycloospora* and microsporidia. *Parasitology* 1998; 117 Suppl: S143-159.
14. Stark D, Barratt JL, van Hal S, Marriott D, Harkness J, Ellis JT. Clinical significance of enteric protozoa in the immunosuppressed human population. *Clin Microbiol Rev* 2009; 22: 634-650.
15. DeHovitz JA, Pape JW, Boncy M, Johnson WD Jr. Clinical manifestations and therapy of *Isoospora belli* infection in patients with the acquired immunodeficiency syndrome. *N Engl J Med* 1986; 315: 87-90.
16. Benator DA, French AL, Beaudet LM, Levy CS, Orenstein JM. *Isoospora belli* infection associated with acalculous cholecystitis in a patient with AIDS. *Ann Intern Med* 1994; 121: 663-664.
17. Walther Z, Topazian MD. *Isoospora* cholangiopathy: case study with histologic characterization and molecular confirmation. *Hum Pathol* 2009; 40: 1342-1346.
18. Velásquez JN, Carnevale S, Mariano M, Kuo LH, Caballero A, Chertcoff A, Ibáñez C, Bozzini JP. Isosporosis and unizuite tissue cysts in patients with acquired immunodeficiency syndrome. *Hum Pathol* 2001; 32: 500-505.

Address for correspondence

Gholam Reza Hatam
Basic Sciences in Infectious Diseases Research Center
Shiraz University of Medical Sciences
Zand Street
7194753415 Shiraz, Iran
e-mail: Hatam908@yahoo.com and hatamghr@sums.ac.ir