

Quiz

WHAT IS YOUR DIAGNOSIS?

A 56-years-old unemployed male patient was a known case of squamous carcinoma of the larynx, diagnosed and treated with radiotherapy in 2015 outside our institute. Patient was referred to our institute for further management. On work up the patient was diagnosed with recurrence of the laryngeal disease. In addition, clinical examination revealed multiple verrucous ulcerative lesions over right calf, largest measuring 10 × 10 cm which was present since 10 years and was recently increasing in size since last one year. Punch biopsy sample was sent from this skin lesion

for histopathological confirmation of clinical diagnosis of verrucous carcinoma.

Histopathological examination showed irregular acanthosis, pseudotheliomatous hyperplasia, hyperkeratosis and parakeratosis of the overlying epidermis (Fig. 1). Upper dermis showed microabscesses, surrounded by granulomas (Figs. 2, 3), and pigmented septate bodies (copper pennies) (Fig 3); which were also highlighted on Grocott's methenamine silver (GMS) stain (Fig. 4).

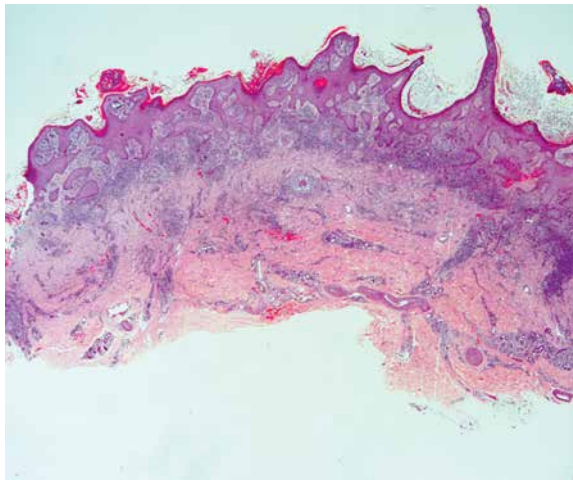


Fig. 1.

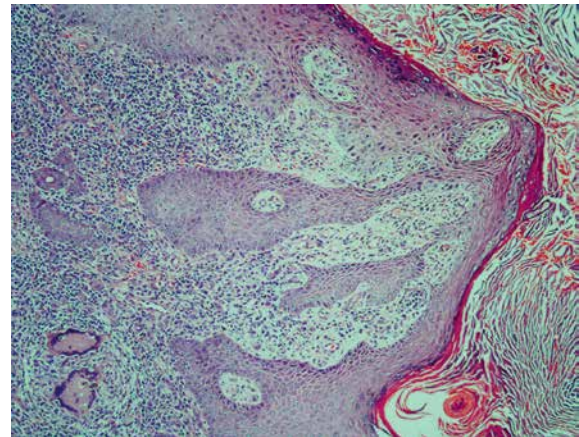


Fig. 2.

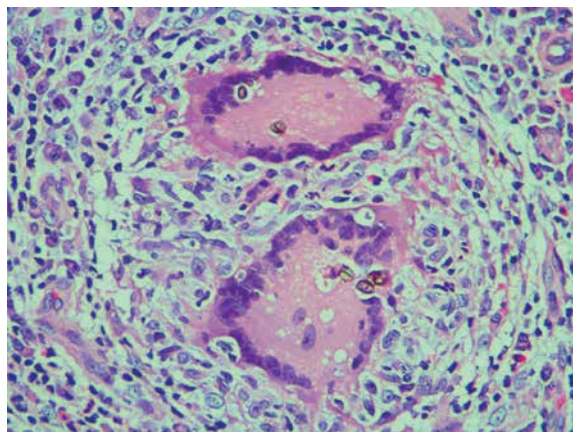


Fig. 3.

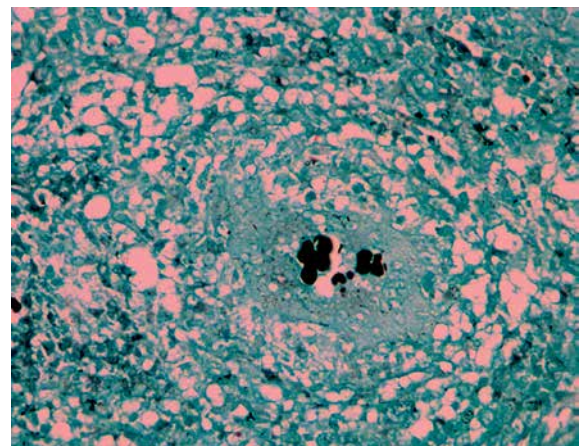


Fig. 4.

Akash Pramod Sali, Ayushi Jai
Department of Pathology, Tata Memorial Hospital, Mumbai, India

Answers should be sent to the Editorial Office by 31.05.2017. The correct answer will be announced in the next issue of the *Polish Journal of Pathology*. All participants with the highest number of correct answers to the quizzes published in vol. 68 (4 issues) will be entered into the prize draw for a book.