

ORIGINAL PAPER

CERAMIC-POLYLACTIDE COMPOSITE MATERIAL USED IN A MODEL OF HEALING OF OSSEOUS DEFECTS IN RABBITS

PAWEŁ MYCIŃSKI¹, JOANNA ZARZECKA¹, AGNIESZKA SKÓRSKA-STANIA², AGNIESZKA JELONEK², KRZYSZTOF OKOŃ³, MARIA WRÓBEL⁴

¹Chair of Conservative Dentistry with Endodontics, Jagiellonian University Collegium Medicum, Krakow, Poland

²Faculty of Chemistry, Jagiellonian University Collegium Medicum, Krakow, Poland

³Chair of Pathomorphology, Jagiellonian University Collegium Medicum, Krakow, Poland

⁴Chair of Medical Biochemistry, Jagiellonian University Collegium Medicum, Krakow, Poland

The growing demand for various kinds of bone regeneration material has in turn increased the desire to find materials with optimal physical, chemical, and biological properties. The objective of the present study was to identify the proportions of ceramic and polylactide components in a bone substitute material prepared in collaboration with the Crystal Chemistry of Drugs Team of the Faculty of Chemistry at the Jagiellonian University, which would be optimal for bone regeneration processes. Another goal was to provide a histological analysis of the influence of a ceramic-polylactide composite on the healing of osseous defects in rabbits. The study was performed on laboratory animals (18 New Zealand White rabbits).

The following study groups were formed:

- group A (study group, 9 animals) – in this group we performed a histological analysis of healing with a ceramic-polylactide composite based on an 80/20 mix of hydroxyapatite and polylactide;
- group B (study group, 9 animals) – in this group we performed a histological analysis of healing with a ceramic-polylactide composite with a reduced amount of hydroxyapatite compared to the previous group, i.e. in a ratio of 61/39;
- group K (control, 18 animals) – the control group comprised self-healing, standardised osseous defects prepared in the calvarial bone of the rabbits on the contralateral side. In the assessment of histological samples, we were also able to eliminate individual influences that might have led to differentiation in wound healing.

The material used in the histological analysis took the form of rabbit bone tissue samples, containing both defects, with margins of around 0.5 cm, taken 1, 3, and 6 months after the experiment.

The osseous defects from groups A and B filled with ceramic-polylactide material healed with less inflammatory infiltration than was the case with control group K. They were also characterised by faster regression, and no resorption or osteonecrosis, which allowed for better regeneration of the bone tissue. A statistical analysis of the study results revealed the increased resorptive activity of the composite in group B, which may have been due to its higher polylactide content. Simultaneously, we observed that healing of osseous defects filled with ceramic-polylactide composites in 80/20 and 61/39 ratios was comparable.

Key words: ceramic-polylactide composite, bone substitutes, bone regeneration, osteogenesis.

Introduction

Surgical reconstruction helps restore the impaired tissue integrity of the oral cavity as well as the functioning of such tissue. Aesthetic indications include, in particular, achieving symmetry by recreating the anatomical shape of the alveolar processes of the maxilla and alveolar aspects of the mandibular base. Functional rehabilitation provides a basis for restoring the correct occlusal, masticatory, phonetic, and respiratory conditions.

Bone grafts and bone substitutes are used in different areas of dentistry and various clinical procedures [1, 2]. They include:

A. Reconstructing the alveolar process:

- prosthetics:
 - increasing the height of the alveolar ridge of maxillary bones in cases of edentulism,
 - increasing the prosthetic area by reconstructing the margin of the alveolar ridge;
- implantology:
 - grafting of bone substitutes,
 - maxillary sinus lift procedures,
 - filling-in osseous defects following inflammation of peri-implant tissue (*periimplantitis*);
- dental and maxillofacial surgery:
 - filling-in extensive, post-extraction osseous defects in planned implant or prosthetic sites,
 - filling-in osseous defects after the following procedures: extraction of impacted teeth, cystectomy (when the radius of the cyst is greater than 1 cm), removal of odontogenic tumours and benign tumours in the maxilla and mandible,
 - filling-in maxillary osseous defects following oncological procedures (only bone grafts);
- endodontics (endodontic surgery):
 - filling-in larger osseous defects following the resection of root apices and the removal of periapical lesions.

B. Assisting periodontal regeneration processes:

- filling-in deep pockets;
- filling-in grade II open root furcations for the purposes of reconstructing lost bone in mandibular molars.

The most commonly used bone reconstructive materials are the following: bone materials of natural origin, i.e. bone from the same individual – autogenous grafts, bone materials from an individual of the same species – allogenic grafts, and bone materials from another species – xenogeneic grafts. A second group comprises materials of synthetic origin as bone substitutes – alloplastic grafts [1, 3, 4].

Bone materials of natural origin – bone grafts

Autogenous bone material is taken from the patient undergoing the surgery and is grafted in

a recipient site in the same patient. The material is comprised in 30% of an organic phase (collagen type I, non-collagen proteins) as well as in 70% of a non-organic phase (calcium phosphate) in the form of crystalline hydroxyapatite. It contains cells with osteogenic potential and factors that stimulate bone growth. It is characterised by osteoinductive and osteoconductive properties.

Allogenic materials are obtained from the human shafts of long bones. The donor and recipient are different genetically, but nevertheless still belong to the same species. Material of this type can be divided into 2 groups: material containing living cells and material devoid of living cells. The first category includes bone marrow cells and freeze-dried cancellous bone. The second category comprises demineralised freeze-dried bone allografts (DFDBA), freeze-dried bone allografts (FDBA), fresh frozen bone (FFB), and autolysed antigen-extracted allogenic bone (AAA).

Xenogeneic (heterogeneic) materials are the most commonly used type of bone grafts. They fall into 2 groups: materials taken from vertebrates and materials originating from invertebrates. Bone substitutes obtained from bovine and porcine bones are in practice non-resorbable and biocompatible. They are produced in block and granule form and taken from both cancellous bone and compact bone, sometimes with an admixture of collagen. The preparation process of the material is based on total deproteination under heat and ionising radiation. This reduces the immunogenicity of the product and the potential risk of transmission of zoonotic diseases.

Bone materials of synthetic origin – alloplastic grafts

Bone substitutes have the following optimal properties [1, 5]:

- biocompatibility (no allergic, cytotoxic, and carcinogenic reactions).
- biologically safe (can be fully sterilised, asepsis),
- resorptive and substitutive properties similar to those of bone,
- degree of tissue resorption or degradation synchronised with bone remodelling,
- low production costs,
- easy to store,
- suitable mechanical properties for specific applications.

Alloplastic materials are applied as synthetic, resorbable, or non-resorbable grafts. They are biocompatible, do not create any risk of cross infections, and possess osteoconductive potential. This group includes hydroxyapatite bioceramics, β -tricalcium phosphate (β -TCP), bioactive glass, artificial bone polymer, and ceramic-poly lactide composites [1, 6, 7, 8].

Composite materials in medicine

A combination of hydroxyapatite with alpha-hydroxy acid polymers is known as a ceramic-poly lactide composite. Composites possess a bone-like structure. They combine the osteoconductive properties of hydroxyapatite with the osteoinductive properties of poly lactide. This combination enhances the mechanical properties of hydroxyapatite and has a positive modifying effect on the inflammatory phase of the healing process. The use of crystals with dimensions not exceeding 200 nm in ceramic-poly lactide composites can result in grafts with favourable mechanical properties. Moreover, they help avoid delamination at the margin of phases between the organic polymer matrix and the reinforcing mineral phase [9, 10, 11, 12].

At the present time, polymer-based composite materials are a very popular and rapidly developing area of research. Modifiers improve the weak mechanical properties of polymers, in particular their strength and fracture toughness, while at the same time also preserving the Young module at the level of bone elasticity. In addition, they change their biological properties by bestowing upon them the characteristics of bioactivity. The first bioactive ceramic-poly lactide composite was polyethylene reinforced with hydroxyapatite, known under the brand name HAPEXTM HAPEXTM. In 1995 this composite was used to make a middle-ear implant with bone-like properties. It also proved to be a good base for osteogenic cell differentiation. Positive assessments from clinicians led to the development of other composites with polymer matrixes, i.e. polyetherketone (PEEK), polyhydroxybutyrate (PHB), and poly lactide (PLLA). Studies conducted by Yang *et al.* demonstrated that intensive osteogenesis was achieved with a ceramic-poly lactide composite featuring xenogeneic bone marrow stromal cells embedded *in vitro* and grafted onto athymic mice [13, 14, 15, 16].



Fig. 1. Scanning Electron Microscope (SEM) image of composite granule with diameter of approximately 600 μm (magnification 110 \times)

As with all medical products, implantation of a ceramic-polymer composite is preceded by sterilisation, the aim of which is to destroy vegetative and spore forms of microorganisms. The choice of sterilisation method depends on the substances from which the medical product is produced [17, 18, 19, 20].

Ceramic-poly lactide composites undergo deformation, thermal and oxidative degradation, as well as hydrolysis after being exposed to overheated water vapour, hot water, and high temperatures. As a result, they are sterilised with irradiation, and ethylene oxide gas [21, 22, 23].

Objective of study

The objectives of the study were as follows:

1. Identify the proportions of ceramic and poly lactide elements in experimental bone substitute material that would be optimal for bone regeneration.
2. Provide a histological assessment of the influence of a ceramic-poly lactide composite on the healing of osseous defects in rabbits.

Material and methods

The grafted ceramic-poly lactide material was created in collaboration with the Crystal Chemistry of Drugs Team of the Faculty of Chemistry at the Jagiellonian University. On account of a patent application being filed for the ceramic-poly lactide composite, a description of how it is obtained is presented here only in a general way, so as to ensure exclusive rights are maintained. Synthetic hydroxyapatite was obtained using the precipitation method described by Komlev (Fig. 1, 2) [24]. Granules with dimensions of 250–1000 μm were covered with a poly-(D,L lactide) layer with an average molecular weight of 80 kDa, which made up 20% (group A) and 39% (group B) of the graft mass. For the coating of granules, a meth-




Fig. 2. Scanning Electron Microscope (SEM) image of composite granule with diameter of approximately 600 μm (magnification 800 \times)

od of polymer dissolution in a solvent (acetone) was used. The solution was then mixed and granules added to it, which were then dried on a polystyrene substrate. Prior to the commencement of the study the material was sterilised with ethylene oxide.

The study was performed on a group of eighteen closely-related New Zealand white rabbits, aged 9-12 months, and weighing 3.0 to 4.0 kg. They came from 4 litters and from the same parents. For prophylactic purposes the rabbits were dewormed 6 and 1.5 months prior to the procedure and vaccinated against myxomatosis and pests as a protective measure 4 weeks prior to the procedure. The rabbits were given no food for 12-18 hours prior to the experiment, but had free access to water. All the procedures were performed in the Animal Reproduction Biotechnology Department of the Institute of Zootechnics – the State Research Institute in Balice.

The following study groups were formed:

- group A (study group, nine animals) – in this group we performed a histological analysis of healing with a ceramic-poly lactide composite based on an 80/20 mix of hydroxyapatite and poly lactide;
- group B (study group, nine animals) – in this group we performed a histological analysis of healing involving a ceramic-poly lactide composite with a reduced amount of hydroxyapatite compared to the previous group, i.e. in a ratio of 61/39;
- group K (control, 18 animals) – the control group comprised self-healing, standardised osseous defects, prepared in the calvarial bone of the rabbit

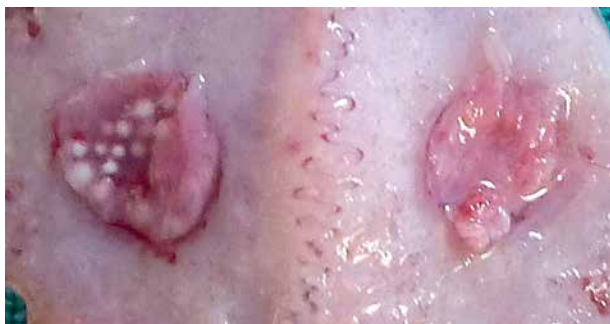

Fig. 3. Sample of frontal bone of rabbit one month after procedure (M1)

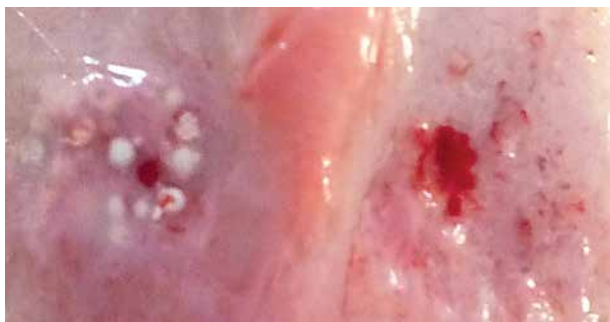

Fig. 4. Sample of frontal bone of rabbit three months after procedure (M3)

on the contralateral side. Individual influences that might have caused differences in healing were in this way additionally eliminated when assessing the histological samples.

All surgical procedures were conducted in accordance with the experimental model for the New Zealand White rabbit devised by the Krakow team from the Chair and Clinic of Cranio-Maxillo-Facial, Oncological, and Reconstructive Surgery at the Jagiellonian University Medical College [25, 26].

Consent for the study was obtained from the Local Krakow Ethics Committee at the Institute of Pharmacy of the Polish Academy of Sciences (Consent no. 746/2010)

A histological analysis was performed on rabbit bone tissue samples containing both defects, taken 1 month (M1) (Fig. 3), 3 months (M3) (Fig. 4), and 6 months (M6) (Fig. 5) after the experiment. Prior to taking the study material, the rabbits received pre-medication (2% Rometar, Spofa, Czech Republic). After being sedated they were euthanised (Morbital, Biowet, Poland) according to the formula devised by the Animal Reproduction Biotechnology Department of the Zootechnics Institute in Balice. After being transferred to the operating theatre the experimental sites with a margin (0.5 cm) of healthy tissue [27] were excised.

The samples were assessed under an optical microscope by an experienced pathomorphologist. A detailed description of individual lesions was recorded and photographic documentation prepared.

The next step in histological evaluation was to measure the amount of bone healing, which was defined between the bottom of the cavity and the highest point of filling the cavity. For the measurement expressed in absolute terms (microns) histological preparations were used made from scraps of bone from the centre of each bone defect. Image processing for measurements were performed using an Axioscope microscope (Zeiss GmbH, Germany) with a Plan Neo Fluar 2.5× lens (Carl Zeiss Micro-Imaging GmbH, Germany) and an MC1000 camera (Motic Corp., China), connected to a standard PC using AnalySIS image Pro 3.2 (Soft Imaging Systems

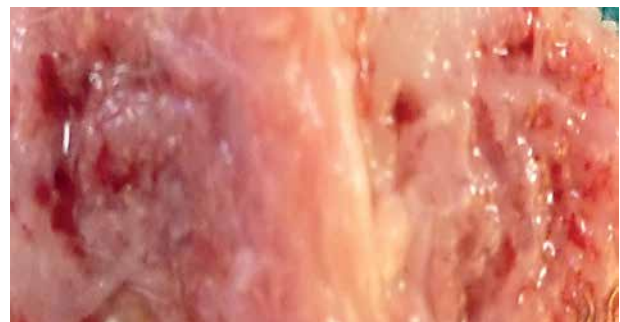

Fig. 5. Sample of frontal bone of rabbit 6 months after procedure (M6)

GmbH, Germany) for analysis. The measurements were made using the language Imaging C, performing user interaction. The results were saved in a text file and then imported to Excel 2010 (Microsoft Corp., USA).

Morphometric studies were used to assess the severity of the healing process of the bone and due to the type of filling material wound. Used to describe the arithmetic mean (average), standard deviation, median, the smallest value (minimum), and maximum value (maximum). To evaluate the distribution of the studied traits in the groups analysed in the months to follow-up, the Shapiro-Wilk test was used. Verification of the differences between the 2 groups was performed using Student's t test or the Mann-Whitney test. The calculations were carried out using the statistical package STATISTICA. Verification of statistical hypotheses were carried out at the level of significance $\alpha = 0.05$.

Results

A month after the experiment the dominant feature observed in the histological images for groups AM1 and BM1 was a build-up of fibrous connective tissue, which formed round spaces in the area surrounding the material. The following were visible: osteoclasts, individual macrophages, polymorphonuclear giant cells, necrotic trabeculae, and resorption type granulation (Fig. 6).

In the KM1 group necrotic trabeculae were observed at the base of the defects. In the remaining area we observed resorption as well as remodelling of the trabeculae with osteoclast participation together

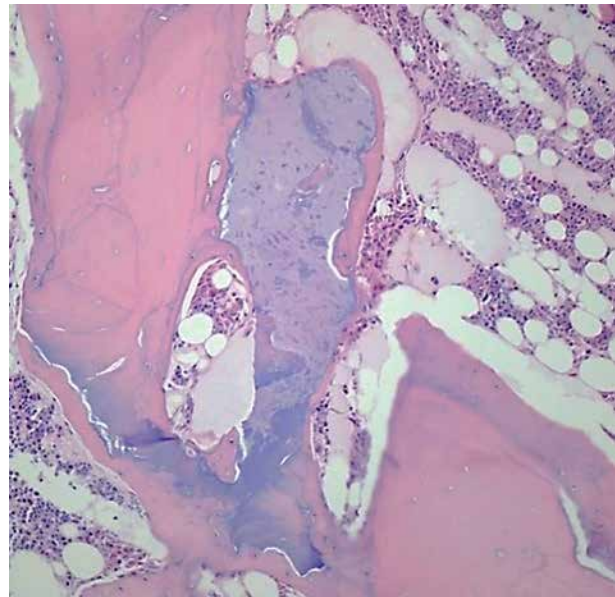


Fig. 6. Defect with graft filled with fibrous tissue and necrotic trabeculae 1 month after healing (HE stain, magnification 200×)

with a build-up of fibrous tissue. In one case, considerable giant cell granulation was visible (Fig. 7).

After 3 months a build-up of fibrous connective tissue was evident in groups AM3 and BM3, which formed round spaces in the area surrounding the material. In 5 cases, giant-cell reaction was visible. In 1 case, necrotic trabeculae were present. In 2 cases new trabeculae formed in connective tissue septa between the spaces containing remnants of the bone substitute material (Fig. 8).

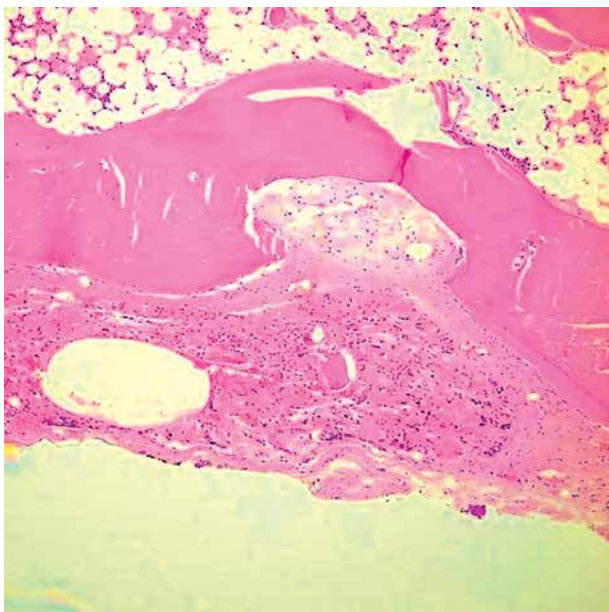


Fig. 7. Fibrous tissue and giant cell granulation in defect without graft after one month of healing (HE stain, magnification 100×)

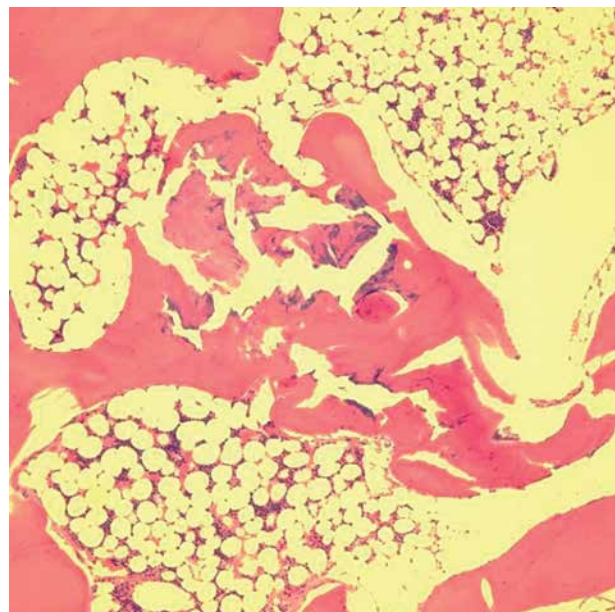


Fig. 8. Bands of fibrous tissue separates spaces with bone substitute material after three months of healing (HE stain, magnification 100×)

In 5 cases in the KM3 group fibrous connective tissue containing spaces lined with endothelium had built up in the defect area. There were some places of cellular abundance. In several cases small numbers of necrotic trabeculae were visible. Forming trabeculae were observed in other samples (Fig. 9).

A build-up of fibrous connective tissue was visible after 6 months in groups AM6 and BM6 with spaces containing remnants of biomaterial. Bone tissue with cementum lines had built up in these areas. Also present were spaces lined with endothelium and osteoblasts forming linear systems (Fig. 10).

In the KM6 group osseous defects contained necrotic trabeculae with characteristics of resorption.

A considerable volume of fibrous cell tissue featuring submerged slit-like vascular spaces was present in the surrounding area. Fibrotic processes affected the entire thickness of the laminar bone. In 2 cases we observed intense bone tissue formation with osteoblast proliferation (Fig. 11, 12).

Group A and group B showed significantly higher amounts of healing than the control group at one month follow-up ($p = 0.007$; $p = 0.003$) and at 6 months follow-up ($p = 0.010$; $p = 0.003$). There were no statistically significant differences between the groups at three months follow-up. There were no significant differences between groups A and B. The results are shown in Table I.

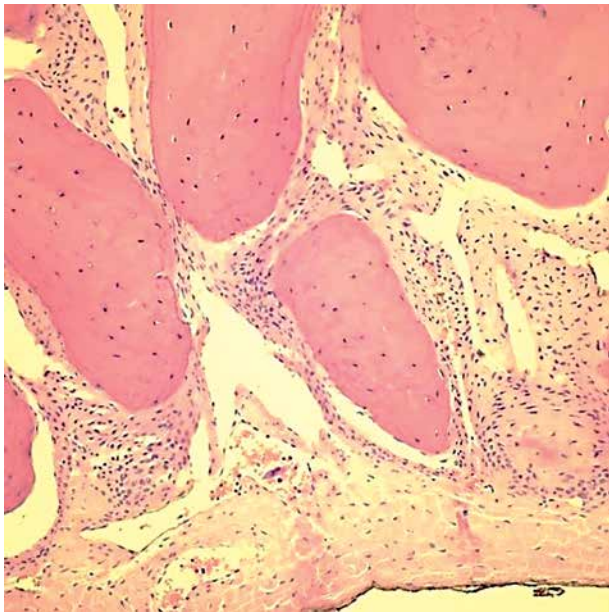


Fig. 9. Fibrous tissue between trabeculae after three months of healing (HE stain, magnification 200×)

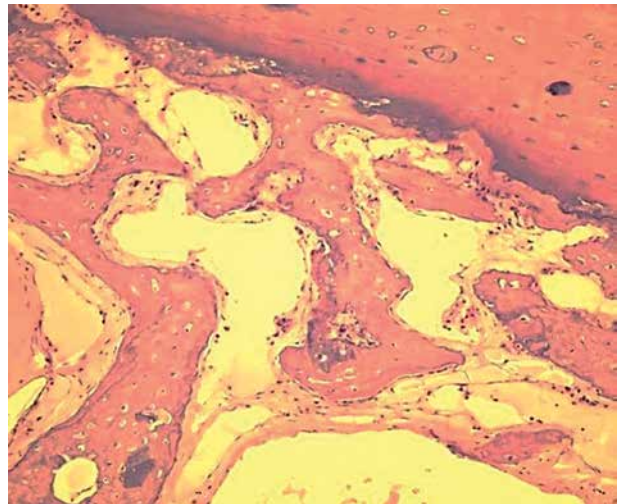


Fig. 10. Fibrous tissue with forming trabeculae bone after 6 months of healing. (HE stain, magnification 100×)

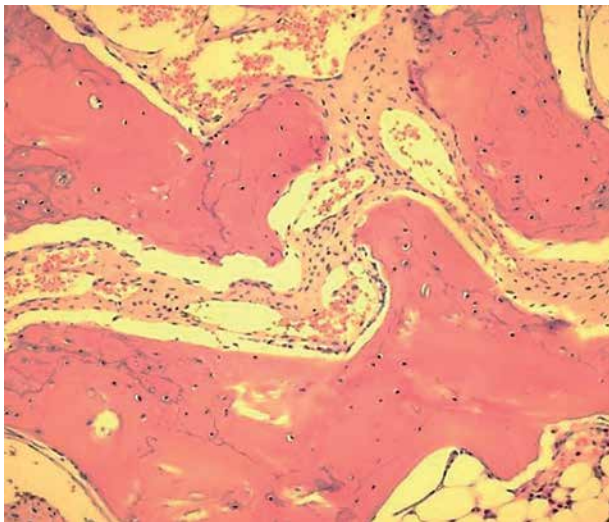


Fig. 11. Trabeculae with cementum lines, spaces lined with endothelium and osteoblasts forming linear systems after 6 months of healing (HE stain, magnification 200×)

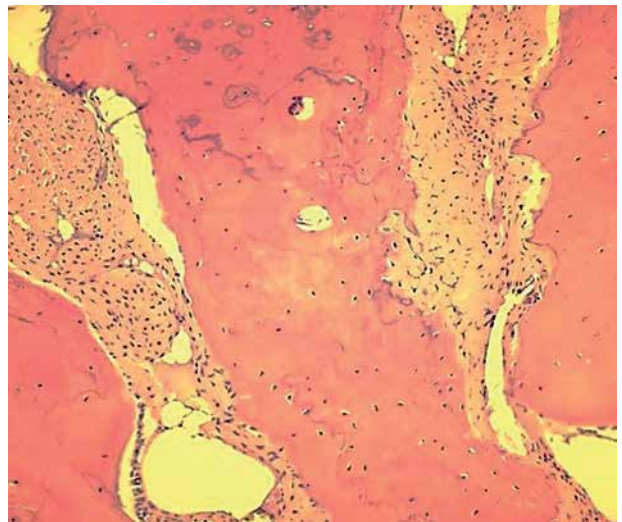


Fig. 12. Numerous osteoblasts, forming continuous layer on surface of trabeculae

Table I. Rating height differences healing between the study group and control group after consecutive months of observation

HEIGHT HEALING [μm] (HIGHEST VALUE)	STUDY GROUP					CONTROL GROUP					P VALUE
	AVER- AGE	STAN- DARD DEVI- ATION	MEDI- AN	MIN.	MAX.	AVER- AGE	STAN- DARD DEVI- ATION	MEDI- AN	MIN.	MAX.	
AM1 i KAM1	1027.1	141.4	995.5	904.1	1181.5	703.7	111.8	705.7	570.8	845.2	0.007
AM3 i KAM3	979.6	107.0	1020.2	858.2	1060.4	776.4	271.7	790.8	375.7	1213.3	0.264
AM6 i KAM6	1150.5	196.7	1155.3	951.5	1344.8	786.0	122.4	775.2	587.0	959.2	0.010
BM1 i KBM1	992.2	14.6	995.2	976.3	1005.0	703.7	111.8	705.7	570.8	845.2	0.003
BM3 i KBM3	1180.7	167.5	1182.0	1012.5	1347.5	776.4	271.7	790.8	375.7	1213.3	0.053
BM6 i KBM6	1149.0	91.6	1162.9	1051.2	1232.8	786.0	122.4	775.2	587.0	959.2	0.003

Discussion

Over the last few years reconstructive surgery has undergone a period of intensive development, which has led to an increase in demand for various kinds of grafting materials. Bone transplant procedures are used widely in maxillofacial surgery, plastic surgery, periodontology, orthopaedics, and neurosurgery. Bone is the second most commonly grafted tissue in the human body after blood. The regeneration processes that accompany transplantation procedures depend on 4 factors: osteogenic cells (osteoblasts or stem cells), osteoinductive signals conveyed through growth factors, an osteoinductive matrix that ensures suitable scaffolding, blood, and nutritional factors. The only material that meets all the criteria is autogenous bone, the use of which, however, is associated with a high (8-39%) risk of such complications as infection, haematoma, nerve damage, and the occurrence of chronic pain in the donor site. In the case of larger defects, obtaining a suitable amount of graft material may prove problematic. In light of this fact bone substitutes are attracting a great deal of interest [28, 29].

Bone tissue regeneration based on biologically compatible materials is proceeding in the same way as bone wound healing. The only difference is that after the graft has been placed in the defect, there is additionally a reaction to foreign bodies accompanied by temporary inflammation, and even traces of necrosis. The histological picture is dominated by macrophages and polymorphonuclear giant cells. The desired phenomenon is the presence of blood in the osseous bed. Good absorption of glycoproteins, lipoproteins, and platelets into the graft surface allows for activation of a coagulation cascade and complement system. The clot that forms during this process provides scaffolding from fibrin, fibronectin, and hyaluronic acid and with the help of adhesive bonds increases the attraction of circulating growth factors and cytokines. This helps trigger angiogenesis and

the chemotactic migration of undifferentiated cells, which in later stages of healing undergo differentiation in an osteoblast direction [30, 31].

Hydroxyapatite ceramics, which have long been used in such procedures, have the highest biocompatibility and bioactivity properties of all well-known implant materials. Hydroxyapatite substrate is an osteoconductive and to a lesser extent osteoinductive material, thanks to which implants made from it have the ability to bind with bone. To achieve proper bonding with the bone it is important to ensure close and precise adhesion of the graft to the bone together with its mechanical post-operative stability [32].

Chlopek *et al.* grafted lactide copolymer and glycolide together with a composite of this copolymer with hydroxyapatite to the mandible of a New Zealand rabbit. They observed that resorption of both materials commenced from the third week of implantation. The creation of bone tissue in the case of the composite proceeded in parallel with the resorption of the polymer and occurred in both hydroxyapatite particles and in formed collagen fibres. The percentage of connective tissue following application of the polymer itself was much higher than in the case of the composite throughout the entire observation period [33].

The author's own study revealed that resorption of ceramic-poly lactide material in group A was minimal, while in group B there was a significant reduction in the diameter of the granules. This result may suggest that a composite containing an increased amount of poly lactide in relation to hydroxyapatite may have high resorption activity. In spite of this fact, no statistically significant differences were observed between the study groups that had any influence on bone healing (assessed morphometric parameters).

In a study conducted by Magdziarz on 57 rabbits, the author drew attention to the impact of a composite comprising copolymer PLLA/GLA and hydroxyapatite on the healing of osseous defects in rabbits.

No local or systemic tissue reactions were observed. Bone tissue healing was barely noticeable at the end of a 6-week observation period, and yet after 12 weeks the healing process was finished completely. A comparison with the control group revealed that faster bone healing was achieved when a composite was implanted [34]. The results of our own histological analyses of bone tissue samples taken from experimental animals confirmed the positive influence of a ceramic-poly lactide composite on bone tissue formation.

According to our own observations, the time needed to complete bone regeneration is around 6 months, which differs significantly from Magdziarz's experiments. Zhang *et al.* also reported different results. They grafted a hydroxyapatite and polyamide composite onto the mandible of a New Zealand White rabbit. The bone had finished healing half a year after implantation [35].

Ignjatovic *et al.* conducted an *in vivo* study on a composite HAP/ PLLA biomaterial implanted into the femur of a Balb/C mouse. They demonstrated good adhesion and expression of cells responsible for bone regeneration on the surface of the ceramic-polymer biomaterial [36, 37, 38].

Histology tests conducted by the author a month after the procedure revealed the build-up of fibrous tissue in osseous defects filled with bone substitutes. This tissue included regular, round spaces containing the remnants of implantation material. No inflammatory cells were observed nor any foreign body reaction in bones. Observations after 3 months revealed the formation of new trabeculae, for the most part poorly organised. Six months after the beginning of the experiment the trabeculae had formed a regular system with osteoblasts arranged in a linear series.

In one case necrotic trabeculae were present, accompanied by purulent inflammatory infiltration, which may have indicated a bacterial infection. Histological images revealed peripheral polymer resorption, and in central parts fragments of hydroxyapatite had become overgrown with new bone tissue.

Macroscopic tests performed after 3 months confirmed that the defects had gradually filled with new bone tissue. In both groups implantation sites differed significantly from the surrounding area. After 6 months the operating fields were recognisable only in the form of slight differences in colouring.

Conclusions

The study method proved its usefulness in achieving the study objectives.

Compared with control group K the osseous defects in groups A and B filled with ceramic-poly lactide material healed with less inflammatory infiltration and faster regression, and exhibited no resorption

or osteonecrosis, which ensured better regeneration of bone tissue.

A statistical analysis of the study results revealed the greater resorption capability of the composite in group B, which may have been due to its higher poly lactide content. Simultaneously, we observed comparable healing of osseous defects filled with ceramic-poly lactide composites in 80/20 and 61/39 ratios.

The use of a ceramic-poly lactide material induces differentiation of mesenchymal cells into osteoblasts, which initiates osteogenesis. This mechanism has not been fully explained and should be the object of further studies.

The authors declare no conflict of interest.

References

1. Ehmke B., Erpenstein H. Atlas chirurgii periodontologicznej. Konopka T (ed.). Urban & Partner; Wrocław 2008; 201-215.
2. Knychalska-Karwan Z, Ślósarczyk A. Hydroksyapatyt w stomatologii. Krakmedia, Kraków 1996; 48-56.
3. Osaka A, Miura Y, Takeuchi K, et al. Calcium apatite prepared from calcium hydroxide and orthophosphoric acid. J Mater Sci Mater Med 1991; 2: 51-55.
4. Khoury F. Zabiegi augmentacyjne w implantologii. Dijakiewicz M (eds.). Wydawnictwo Kwintesencja, Warszawa 2011; 32-40.
5. Lloyd AW. Interfacial bioengineering to enhance surface biocompatibility. Med Device Technol 2002; 13: 18-21.
6. Laskus-Perendyk A, Mateńko D. Odbudowa ubytków kostnych z użyciem polimeru HTR. Opis przypadku. Czas Stomatol 1996; 3: 162-165.
7. Ślósarczyk A, et al. Biomateriały ceramiczne. In: Biocybernetyka i inżynieria biomedyczna 2000. Nałęcz M (ed.). Polska Akademia Nauk 2003; IV: 128-142.
8. Świczko-Żurek B. Biomateriały. Wydawnictwo Politechniki Gdańskiej, Gdańsk 2009; 115-134.
9. Szyszkowska A, Krawczyk P. Materiały stosowane do odbudowy ubytków kostnych w stomatologii – praca pogładowa. Implantoprotetyka 2008; 4: 21-24.
10. Chłopek J. Kompozyty w medycynie. Kompozyty 2001; 1: 50-54.
11. Lee SJ, Lim GJ, Lee JW, et al. In vitro evaluation of a poly(lactide-co-glycolide) – collagen composite scaffold for bone regeneration. Biomaterials 2006; 27: 3466-3472.
12. Włodarski KH, Włodarski PK, Galus R. Bioaktywne kompozyty w regeneracji kości. Przegląd Ortop Traumatol Rehab 2008; 10: 201-210.
13. Di Silvio L, Dalby MJ, Bonfield W. Osteoblast behaviour on HA/PE composite surfaces with different HA volumes. Biomaterials 2002; 23: 101-107.
14. Rosół P. Analiza trwałości implantów z kompozytów polimerowych. Praca doktorska, Akademia Górniczo-Hutnicza, Kraków 2006.
15. Yang XB, Webb D, Blaker J, et al. Evaluation of human bone marrow stromal cell growth on biodegradable polymer/bioglass composites. Biochem Biophys Res Comm 2006; 342: 1098-1107.
16. Zhang Y, Tanner KE, Gurav N, Di Silvio L. In vitro osteoblastic response to 30 vol % hydroxyapatite-polyethylene composite. J Biomed Mater Res 2007; 81: 409-417.
17. Marciniak J, Kaczmarek M, Ziębowicz A. Biomateriały w stomatologii. Wydawnictwo Politechniki Śląskiej, Gliwice 2008.

18. Rogers W. *Sterilisation of Polymer Healthcare Products*. Rapra Technology 2005.
19. Rozema FR, Bos RR, Boering G, et al. The effects of different steam-sterilization programs on material properties of poly (L-lactide). *J Appl Biomater* 1991; 2: 23-28.
20. Rutala WA. *Disinfection, Sterilization and Antisepsis In Health Care*. Polyscience Publications, New York 1998.
21. Gogolewski S. Biomateriały ceramiczne. In: *Biocybernetyka i inżynieria biomedyczna 2000*. Nałęcz M (ed.). Polska Akademia Nauk 2003; IV: 257-330.
22. Gogolewski S, Mainil-Varlet P, Dillon JG. Sterility, mechanical properties, and molecular stability of polylactide internal-fixation devices treated with low-temperature plasmas. *J Biomed Mater Res* 1996; 32: 227-235.
23. Middleton JC, Tipton AJ. Synthetic biodegradable polymers as orthopedic devices. *Biomaterials* 2000; 21: 2335-2346.
24. Komlev VS, Barinova SM, Koplík EV. A method to fabricate porous spherical hydroxyapatite granules intended for time-controlled drug release. *Biomaterials* 2002; 23: 3449-3454.
25. Zapala J, Wyszyńska-Paweł G. Teraźniejszość i przyszłość chirurgii rekonstrukcyjnej czaszki twarzowej. In: *Biotechnologiczne i medyczne podstawy ksenotransplantacji*. Smorąg Z (ed.). Ośrodek Wydawnictw Naukowych, Poznań 2006.
26. Zapala J. *Patologia urazowa nerwu wzrokowego w klinice i doświadczeniu*. Rozprawa habilitacyjna, Uniwersytet Jagielloński, Kraków 1999.
27. Zarzecka J. Wykorzystanie zawiesiny autologicznych keratynocytów hodowanych in vitro w gojeniu ran błony śluzowej jamy ustnej. Rozprawa habilitacyjna, Uniwersytet Jagielloński, Kraków 2008.
28. Koźlik M, Wójcicki P, Rychlik D. Preparaty kośćcozastępcze. *Dent Med Probl* 2011; 4: 547-553.
29. Van Heest A, Swiontkowski M. Bone-graft substitutes. *Lancet* 1999; 353: 28-29.
30. Chruściel-Nogalska M, Światłowska M. Przebieg gojenia ubytków kostnych szczęki i żuchwy i jego wpływ na ukształtowanie podłoża protetycznego w oparciu o piśmiennictwo. *Protet Stomatol* 2001; 51: 197-201.
31. Maciejewska I, Nowakowska J, Bereznowski Z. Osteointegracja wszczepów zębowych – etapy gojenia kości. *Protet Stomatol* 2006; 3: 214-219.
32. Dawidowicz A, et al. Zastosowanie mikroanalizy pierwiastkowej do oceny osteoindukcji i osteokondukcji dokostnych implantów hydroksyapatytowych. *Polimery Med.* 2005; 1: 1-19.
33. Chłopek J, Morawska-Chochół A, Rosół P. Mechanizm regeneracji tkanki kostnej po implantacji kompozytu z polimeru resorbowalnego modyfikowanego hydroksyapatytem. *Inż Biomater* 2006; 58-60: 98-101.
34. Magdziarz OI. Wpływ kopolimeru kwasu mlekowego z kwasem glikolowym [P(LLA/GLA)] napełnionego hydroksyapatytem (HA) na gojenie ubytków kostnych żuchwy królików. Rozprawa doktorska. Śląska Akademia Medyczna, Zabrze 2005.
35. Zhang JC, Lu HY, Lv GY, et al. The repair of critical-size defects with porous hydroxyapatite/polyamide nanocomposite: an experimental study in rabbit mandibles. *Int J Oral Maxillofac Surg* 2010; 39: 469-477.
36. Ignjatovic N, Uskokovic D. Synthesis and application of hydroxyapatite/polylactide composite biomaterial. *Appl Surf Sci* 2004; 314-319.
37. Ignjatovic N, Savic V, Najman S, et al. Analysis of in vivo substitution of bone tissue by HAp/PLLA composite biomaterial with poly-L-lactide different molecular weight using FT-IR spectroscopy. *Mater Sci Forum* 2000; 352: 143-150.
38. Najman S, Dordevic L, Savic V, et al. Biological evaluation of hydroxyapatite/poly-L-lactide/ composite biomaterials with poly-L-lactide of different molecular weights intraperitoneally implanted into mice. *Biomed Mater Eng* 2004; 14: 61-70.

Address for correspondence

Paweł Myciński
 Chair of Conservative Dentistry with Endodontics
 Jagiellonian University Collegium Medicum
 Montelupich 4
 31-155 Krakow, Poland
 e-mail: pawelmycinski@poczta.onet.pl