

Quiz

WHAT IS YOUR DIAGNOSIS?

An 85-year-old male with right inguinal lymphadenopathy and suspicion of prostate cancer was admitted to the Institute of Haematology and Transfusion Medicine. Microscopic examination of lymph nodes revealed abundant fields of cohesive CKAE1/AE3-positive cells and small to medium-sized lym-

phocytic infiltrate expressing CD20 and cyclin D1. Haematoxylin and eosin staining is presented in Figs. 1-3; additional immunohistochemical reactions: CKAE1/AE3, CD20, and cyclin D1 are depicted in Figs. 4-6, respectively.

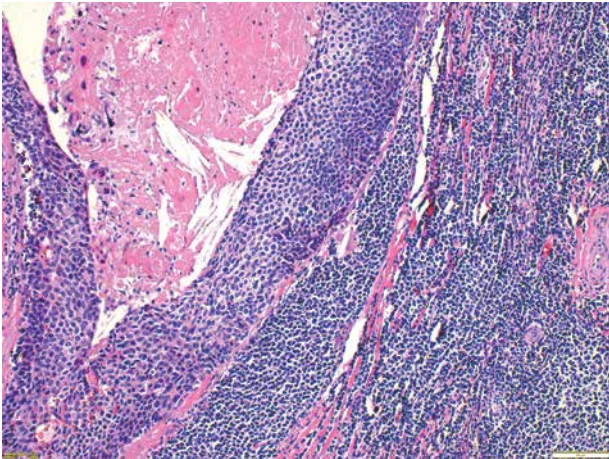


Fig. 1.

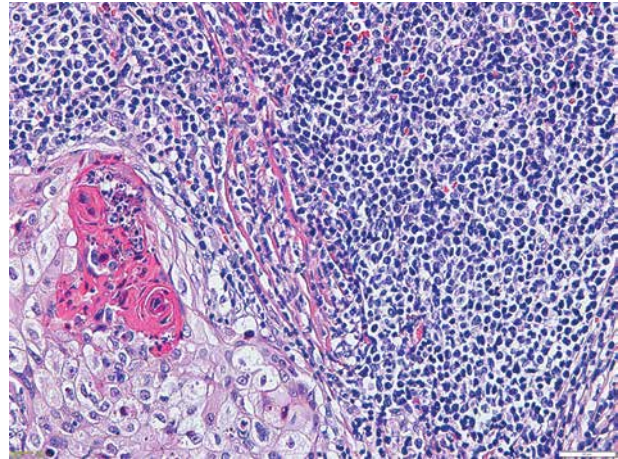


Fig. 2.

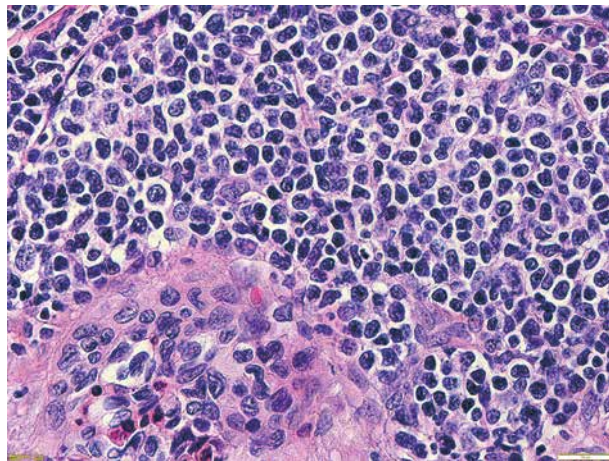


Fig. 3.

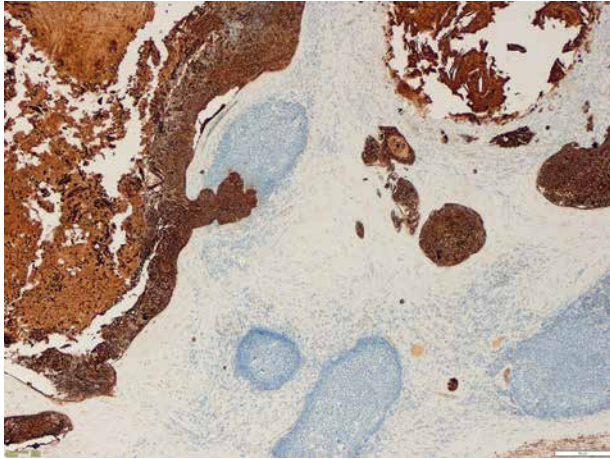


Fig. 4.

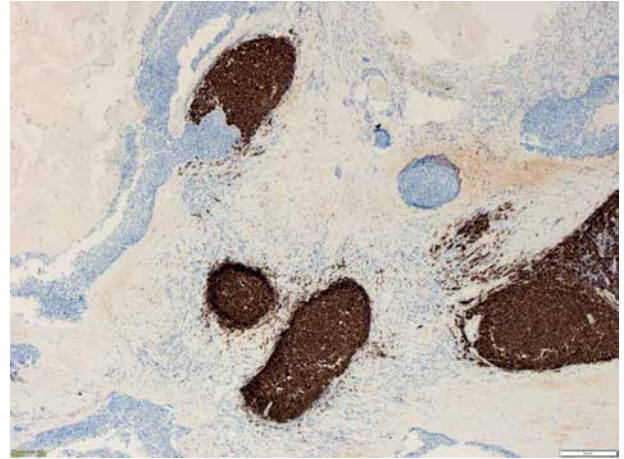


Fig. 5.

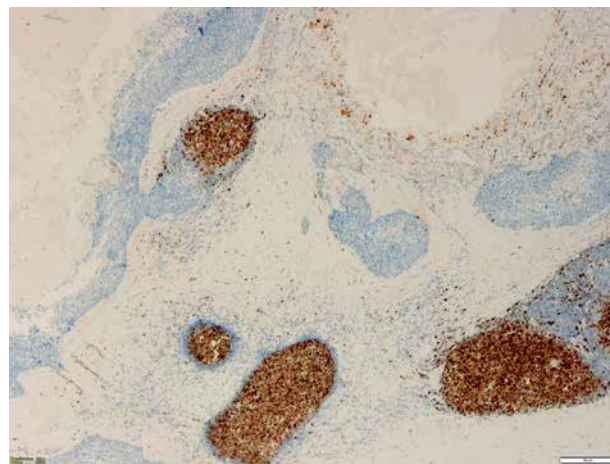


Fig. 6.

Anna Szumera-Ciećkiewicz^{1,2}, Barbara Bikowska-Opalach², Monika Prochorec-Sobieszek^{1,2}

¹Department of Diagnostic Hematology, Institute of Hematology and Transfusion Medicine, Warsaw, Poland

²Department of Pathology and Laboratory Medicine, Maria Skłodowska-Curie Memorial Cancer Center and Institute of Oncology, Warsaw, Poland

Answers should be sent to the Editorial Office by 30.10.2017. The correct answer will be announced in the next issue of the *Polish Journal of Pathology*. All participants with the highest number of correct answers to the quizzes published in vol. 68 (4 issues) will be entered into the prize draw for a book.