

ORIGINAL PAPER

EFFECT OF SINAPIC ACID ON MEMORY DEFICITS AND NEURONAL DEGENERATION INDUCED BY INTRACEREBROVENTRICULAR ADMINISTRATION OF STREPTOZOTOCIN IN RATS

POUNEH SHAHMOHAMADY¹, AKRAM EIDI¹, PEJMAN MORTAZAVI², NEGAR PANAHI³,
DARIUSH MINAI-TEHRANI⁴

¹Department of Biology, Science and Research Branch, Islamic Azad University, Tehran, Iran

²Department of Pathology, Faculty of Specialized Veterinary Sciences, Science and Research Branch, Islamic Azad University, Tehran, Iran

³Department of Basic Sciences, Faculty of Specialized Veterinary Sciences, Science and Research Branch, Islamic Azad University, Tehran, Iran

⁴Faculty of Science & Biotechnology, Shahid Beheshti University, Tehran, Iran

The present study aimed to elucidate the neuroprotective effect of sinapic acid on intracerebroventricular streptozotocin (ICV-STZ) induced neuronal loss and memory impairment. To test this hypothesis, male Wistar rats were randomly divided into 11 groups: normal control, sham-operated control, sinapic acid (2.5, 5, 10, and 20 mg/kg bw intragastrically, daily) alone, Alzheimer control rats (ICV-STZ, 3 mg/kg bw), sinapic acid (2.5, 5, 10, and 20 mg/kg bw intragastrically, daily) together with STZ, and the treatment was performed accordingly. After 28 days of ICV-STZ administration, the animals were assessed for cognitive performance using passive avoidance test and then sacrificed for biochemical and histopathological examinations. Sinapic acid was found to be effective in improving antioxidant status and preventing memory loss in Alzheimer rats. Moreover, TNF- α level in the hippocampus was significantly decreased by sinapic acid. Also, administration of sinapic acid significantly increased the levels of antioxidant enzymes and decreased malondialdehyde level in the hippocampus. Histopathological examination showed that sinapic acid reduced cell loss in the cerebral cortex and hippocampus in Alzheimer's rats. The present study suggests that sinapic acid is effective in the prevention of memory loss and improvement of oxidative stress and might be beneficial in the treatment of Alzheimer's disease.

Key words: sinapic acid, streptozotocin, Alzheimer's disease, rat.

Introduction

Sinapic acid is a hydroxycinnamic acid-derived polyphenol with 3,5-dimethoxyl and 4-hydroxyl substitutes in the phenyl group of cinnamic acid. It is widely distributed in the plant kingdom and is obtained from various plant foods, such as hazelnut, pea, cabbage, wheat, rye, and brown rice [1, 2]. Scientific studies have

revealed that sinapic acid has anti-inflammatory [3], antioxidant [4, 5], antibacterial [6, 7], antihyperglycemic [8], antimicrobial [9, 10], anxiolytic [11], cardioprotective [12, 13], antitumor [14], peroxynitrite scavenging [2], and neuroprotective effects [15, 16].

Alzheimer's disease (AD) is a type of dementia, which is associated with neurodegeneration due to accumulation of neurofibrillary tangles, senile plaque

deposits and neuroinflammation, leading to progressive deterioration in cognition. Various mechanisms of neuronal degeneration have been proposed in AD, including abnormalities in glucose metabolism, reduced glucose utilization, oxidative stress, mitochondrial dysfunction, genetic factors, inflammatory processes environmental factors, apoptosis, etc. These factors may interact and amplify each other in a vicious cycle of toxicity, resulting in neuronal dysfunction, cell dysfunction, and finally cell death [17, 18]. Alzheimer's disease is the most common form of dementia which is characterized by severe neurodegenerative changes such as loss of neurons and synapses in brain [19]. Alzheimer's disease is characterized by the cerebral accumulation of extracellular deposits called amyloid plaques that are composed of amyloid β peptides ($A\beta$) of 38-43 amino acids. Amyloid β plaques are cardinal histopathological hallmarks of Alzheimer's disease, fundamental to the amyloid cascade hypothesis of the disease, which posits cerebral $A\beta$ accumulation as a crucial early player in disease pathogenesis, ultimately leading to neurodegeneration and dementia [20].

Intracerebroventricular (ICV) administration of streptozotocin (STZ), a glucosamine-nitrosourea compound, at a sub-diabetogenic dose to rodents, has provided a relevant model for AD-type neurodegeneration with cognitive impairment, brain insulin receptor dysfunction, progressive cholinergic deficits, glucose hypometabolism, oxidative stress, neuroinflammation, and neurodegeneration, which share many common features with sporadic AD [21, 22, 23].

As oxidative damage plays a role in the etiology of neurological complications, antioxidant treatment is used as a therapeutic strategy in various neurodegenerative diseases [24, 25]. The present study aims to investigate the effect of sinapic acid on behavioral, biochemical, and histochemical changes in ICV-STZ infused rats.

Material and methods

Chemicals

Sinapic acid and STZ were purchased from Sigma-Aldrich Chemical Company (St. Louis, MO). Streptozotocin was dissolved in artificial cerebrospinal fluid (aCSF: 147 mM NaCl, 2.9 mM KCl, 1.6 mM $MgCl_2$, 1.7 mM $CaCl_2$, and 2.2 mM dextrose; pH 7.4) and sinapic acid was dissolved in 10% Tween 80 [16]. Assay kits for catalase (CAT), superoxide dismutase (SOD), glutathione peroxidase (GPX), and malondialdehyde (MDA), were purchased from Randox (Crumlin, UK). Tumor necrosis factor α (TNF- α) ELISA kit was obtained from Diaclone (Besançon, France). All other reagents used in this study were of analytical grade. Solutions of the drugs and chemicals were prepared freshly before use.

Animals

Male Wistar rats, initially weighing 200-230 g, were used in this study. The animals were housed in groups of 5 per cage in a room with controlled temperature ($22 \pm 2^\circ C$), lighting (on, 7 AM; off, 7 PM), and relative air humidity (40-60%). The animals were allowed to have free access to standard laboratory chow and tap water. The diet was purchased from Pars-Dam food service, Tehran, Iran. Experimental procedures including animals and their care were carried out according to institutional guidelines in accordance with national and international laws and the Guidelines for Care and Use of Laboratory Animals in Biomedical Research, as adopted and published by the World Health Organization (WHO) and the United States National Institutes of Health, 1985, No. 85-23. The experimental protocol was approved by the Research Ethics Committee of the Faculty of Sciences, Islamic Azad University.

Intracerebroventricular injection of streptozotocin

Animals were anesthetized using ketamine hydrochloride (100 mg/kg, i.p.) and xylazine (5 mg/kg, i.p.). Their head was placed in position in the stereotaxic apparatus and a midline sagittal incision was made in the scalp. The stereotaxic coordinates for the lateral ventricles [26], were measured as 0.8 mm anterior-posterior to bregma; 1.5 mm lateral to sagittal suture; 3.6 mm dorso-ventral from the surface of the brain. STZ was dissolved in aCSF and slowly infused (1 $\mu l/min$) in a volume of 10 μl using a Hamilton microsyringe on days 1 and 3 [27]. In the sham-operated group, ICV injection was performed with of the same volume of aCSF as the STZ treated group.

Experimental design

Sinapic acid was dissolved in 10% Tween 80 and given orally once a day using an orogastric tube for 28 days, starting from 1 h before ICV administration of the first dose of STZ [28]. In the present study, the protective effect of sinapic acid in Alzheimer's rat model has been investigated. Therefore sinapic acid and STZ were treated simultaneously. Since surgery should be performed for STZ treatment, sinapic acid treatment was performed before surgery (one hour before). The animals were randomly divided into 11 experimental groups of 12 animals each as follows:

- Group I: Normal control rats received 1 ml of 10% Tween 80 intragastrically as vehicle.
- Group II: Sham-operated control rats that underwent surgery. The animals received aCSF (10 μl) in each ventricle (ICV) on the 1st and 3rd days and were given 1 ml of 10% Tween 80 intragastrically.

- Groups III-VI: Normal rats received sinapic acid (2.5, 5, 10, and 20 mg/kg bw) daily using an intragastric tube for 28 days.
- Group VII: Alzheimer's control rats were administered STZ (3 mg/kg, ICV) dissolved in aCSF in a volume of 10 μ l in each ventricle on the 1st and 3rd days. The animals received 10% Tween 80 as vehicle for 28 days [25].
- Groups VIII-XI: Alzheimer's rats received sinapic acid (2.5, 5, 10, and 20 mg/kg bw) daily using an intragastric tube for 28 days.

The oral administration volume was 1 ml and the duration of the treatments was 28 days. The animals were carefully monitored daily.

Step-through passive avoidance task

Behavioral test was initiated 28 days after ICV-STZ administration. The experiments were performed between 9:00 am and 4:00 pm in the laboratory at standard optimal conditions. On day 28 after ICV-STZ administration, the rats were tested for memory retention deficits using a passive avoidance apparatus [29]. The apparatus consisted of a two-compartment dark/light shuttle box of the same dimensions (20 \times 20 \times 30 cm). The two compartments were separated by a guillotine door. The dark compartment had a stainless steel shock grid floor. During the acquisition trial, each animal was placed in the light chamber. After a 60 s habituation period, the guillotine door was opened, and the initial latency of the animals to enter the dark chamber was recorded. Rats with initial latency time more than 60 s, were excluded from further experiments. After the rat had entered the dark chamber, the guillotine door was closed and an electric foot shock (50 Hz, 2 mA, 1.5 s), was delivered to the floor grid using a stimulator for 3 s. Five seconds later, the animal was removed from the dark chamber and returned to its home cage. After 24 h, the retention latency time was measured in the same way as that of the acquisition trial, but the foot shock was not delivered. The latency time and the time in dark compartment (TDC), were recorded to a maximum of 300 s. Short latencies and long TDC indicated poorer retention.

Biochemical analysis

Following the completion of all behavioral tests on day 29, animals were anesthetized, decapitated, and their brains were removed. The hippocampus was dissected from the brain and used for biochemical studies. The dissected hippocampus was homogenized in 10 mM Tris-buffer (pH 7.4) containing 50 mM Tris, 1 mM EDTA, 6 mM MgCl₂, and 5% (w/v) protease inhibitors. The homogenate was centrifuged at 800 \times g for 5 min at 4°C to separate the nuclear debris. The obtained supernatant was centrifuged at

10,500 \times g for 20 min at 4°C to assess TNF- α and oxidative stress parameters, including CAT, SOD, GPX, and MDA.

ELISA quantification of hippocampal TNF- α was performed according to Deak *et al.*, method [30]. This assay employed the quantitative sandwich enzyme immunoassay technique according to the manufacturer's instructions. Furthermore, the homogenates were incubated in duplicate in a 96-well microplate coated with anti TNF- α monoclonal antibody. The absorbance was read at 450 nm.

CAT activity was measured using Aebi method [31]. A 0.1 mL sample of supernatant was added to a cuvette containing 1.9 mL of 50 mM phosphate buffer (pH 7.0). The reaction was initiated by adding 1.0 mL of freshly prepared 30 mM H₂O₂. The decomposition rate of H₂O₂ was spectrophotometrically determined at 240 nm. The CAT activity was expressed as Unit/mg protein.

SOD activity was measured according to the kit directions. A competitive inhibition assay was performed using xanthine-xanthine oxidase-generated O₂ to reduce nitroblue tetrazolium (NBT) to blue formazan. One unit of SOD activity was determined as the amount of enzyme required to reduce NBT to 50% of maximum. The maximum absorbance was read at 550 nm and the enzyme activity was expressed as Unit/mg protein [32].

GPX activity was measured using a method based on the reaction between GSH remaining after the action of GPX and 5,5'-dithiobis-2-nitrobenzoic acid to form a complex with maximum absorbance at 412 nm. One unit of GPX activity was determined as 1 mol/l per min decrease in GSH in an enzymatic reaction by 1 mg of protein per min, deducting the effect of non-enzyme-catalyzed reaction [33].

MDA levels were determined using thiobarbituric acid method by spectrophotometrically monitoring MDA-reactive products. The absorbance of the organic layer was measured at 532 nm. Data were expressed as nanomoles of MDA per milligram of protein (nM MDA mg/protein) [34].

Histopathological examination

After completion of behavioral testing on day 29, the animals (6 animals/group) were anesthetized by inhalation of diethyl ether and perfused transcardially through ascending aorta with 100 mL of ice cold phosphate buffered saline (PBS 0.1 M, pH 7.4) followed by 4% paraformaldehyde in cold PBS (0.1 M, pH 7.4). Brains were removed immediately and post-fixed in the paraformaldehyde solution for 48 h. After fixation, the tissue was dehydrated and embedded in paraffin. Coronal sections were evaluated at 1.8-2.0 mm rostral to the optic chiasma. Sections (4 μ m) were prepared and subjected to Bielschowsky staining as described in the protocol of the instructions. After

staining, the stained hippocampus and cortex sections were examined under a light microscope (Nikon E200, Japan). Neuronal cell count in the cortex, CA₁, CA₂, CA₃, and dentate gyrus of the hippocampus, was performed by Image Analyzer software version 1.36.1.

Statistical analysis

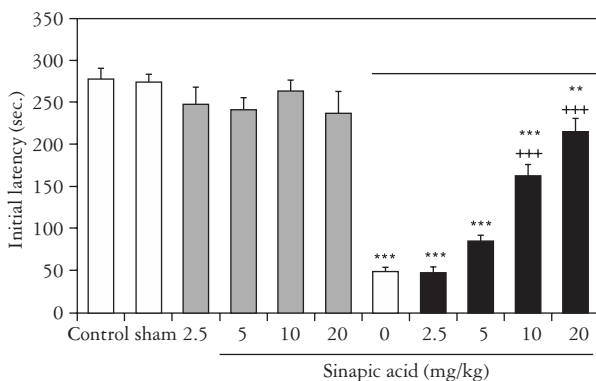
Statistical analyses were carried out using SPSS 10 (SPSS, Chicago, Ill) program for Windows. Data were expressed as mean ± SEM. Data were analyzed using one-way analysis of variance and Tukey's post-hoc test. The criterion for statistical significance was p < 0.05.

Results

Effect of sinapic acid on memory retention

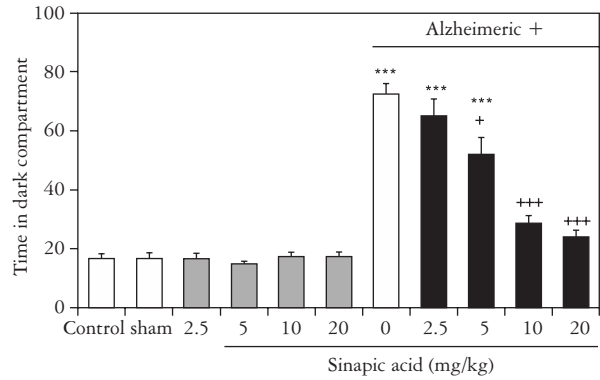
The initial latency in the acquisition trial showed no difference among the groups. However, after 24 h, retention latency in ICV-STZ control group was significantly lower than normal control rats, indicating impaired learning and memory. Administration of sinapic acid at doses of 10 and 20 mg/kg significantly improved the memory deficits as demonstrated by increased retention latencies. The initial latency showed no significant difference between sham-operated and normal control groups. Interestingly, treatment with sinapic acid (at doses of 2.5, 5, 10, and 20 mg/kg) alone, caused no significant changes in initial latency as compared to the normal control rats (Fig. 1).

The results of the behavioral test showed significant differences in the TDC of passive avoidance response between ICV-STZ control group (rats were administered STZ) and normal control group (rats received Tween 80 as vehicle). The administration of sinapic acid (10 and 20 mg/kg) caused a significant



** p < 0.01, *** p < 0.001 indicate differences from normal control group
+++ p < 0.001 indicate differences from Alzheimeric control group

Fig. 1. Effect of oral administration of sinapic acid at doses of 2.5, 5, 10, and 20 mg/kg bw on initial latency in normal and Alzheimeric rats. Each column represents mean ± SEM for 6 rats



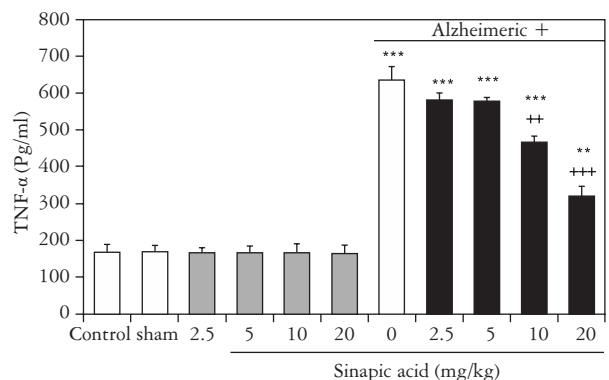
*** p < 0.001 indicate differences from normal control group
+ p < 0.05, +++ p < 0.001 indicate differences from Alzheimeric control group

Fig. 2. Effect of oral administration of sinapic acid at doses of 2.5, 5, 10, and 20 mg/kg bw on time in dark compartment in normal and Alzheimeric rats. Each column represents mean ± SEM for 6 rats

decrease in TDC compared to the ICV-STZ control rats. Also, normal rats treated only with sinapic acid (at doses of 2.5, 5, 10, and 20 mg/kg) did not show any significant difference in TDC compared to normal control and sham-operated groups (Fig. 2).

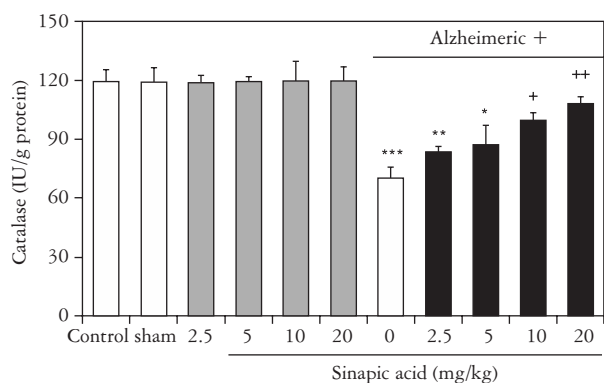
Effect of sinapic acid on biochemical parameters of brain homogenate

Our results revealed that TNF-α levels were significantly elevated in ICV-STZ group as compared to normal control group. Administration of sinapic acid (10 and 20 mg/kg) significantly inhibited the increase of TNF-α levels in the brain of ICV-STZ rats. No significant difference was observed in the TNF-α level in the animals only treated with sinapic acid (2.5, 5, 10, and 20 mg/kg) compared to normal control rats (Fig. 3).



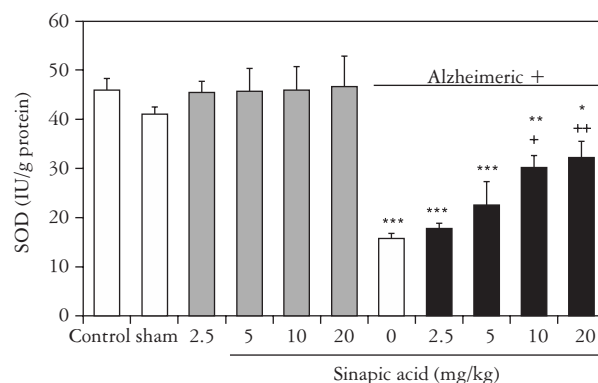
** p < 0.01, *** p < 0.001 indicate differences from normal control group
++ p < 0.01, +++ p < 0.001 indicate differences from Alzheimeric control group

Fig. 3. Effect of oral administration of sinapic acid at doses of 2.5, 5, 10, and 20 mg/kg bw on TNF-α level in normal and Alzheimeric rats. Each column represents mean ± SEM for 6 rats



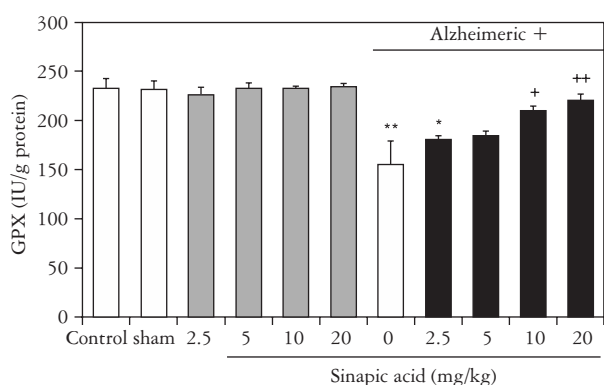
* p < 0.05, ** p < 0.01, *** p < 0.001 indicate differences from normal control group
+ p < 0.05, ++ p < 0.01 indicate differences from Alzheimeric control group

Fig. 4. Effect of oral administration of sinapic acid at doses of 2.5, 5, 10, and 20 mg/kg bw on catalase level in normal and Alzheimeric rats. Each column represents mean ± SEM for 6 rats



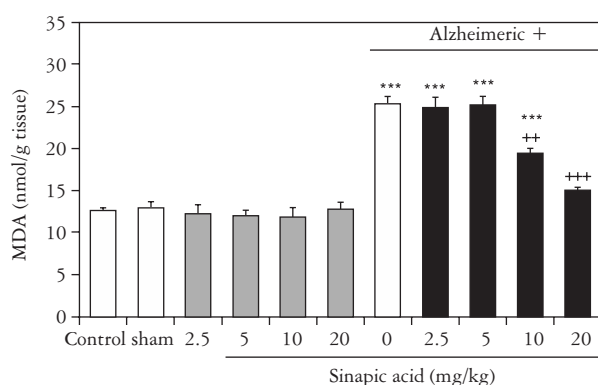
* p < 0.05, ** p < 0.01, *** p < 0.001 indicate differences from normal control group
+ p < 0.05, ++ p < 0.01 indicate differences from Alzheimeric control group

Fig. 5. Effect of oral administration of sinapic acid at doses of 2.5, 5, 10, and 20 mg/kg bw on SOD level in normal and Alzheimeric rats. Each column represents mean ± SEM for 6 rats



* p < 0.05, ** p < 0.01 indicate differences from normal control group
+ p < 0.05, ++ p < 0.01 indicate differences from Alzheimeric control group

Fig. 6. Effect of oral administration of sinapic acid at doses of 2.5, 5, 10, and 20 mg/kg bw on GPX level in normal and Alzheimeric rats. Each column represents mean ± SEM for 6 rats



*** p < 0.001 indicate differences from normal control group
++ p < 0.01; +++ p < 0.001 indicate differences from Alzheimeric control group

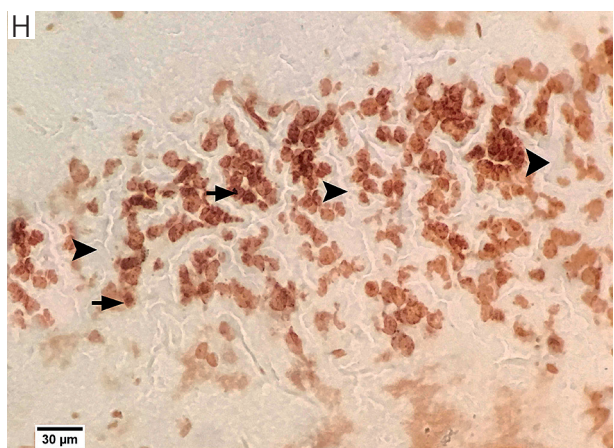
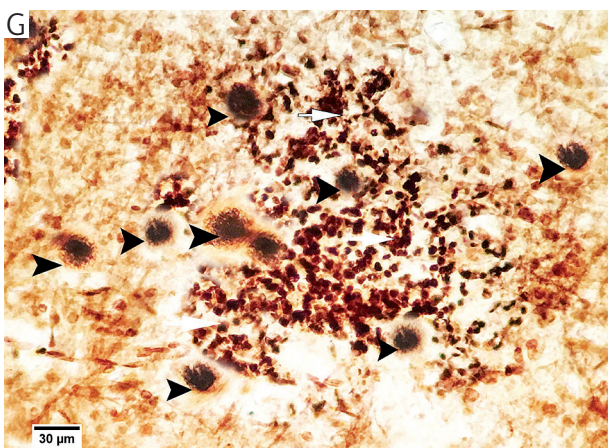
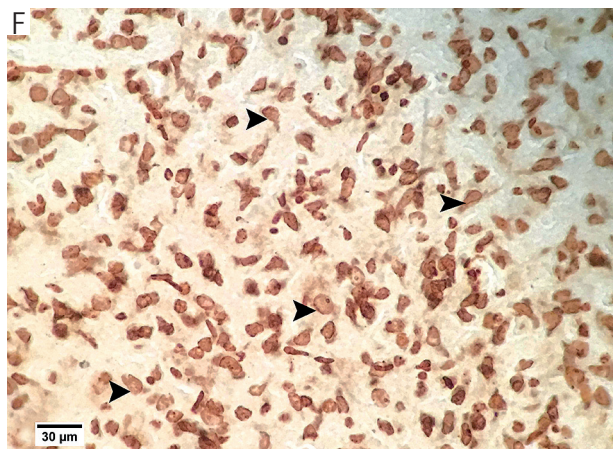
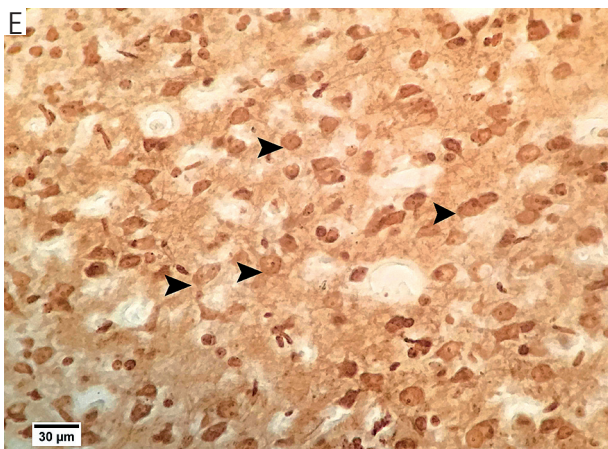
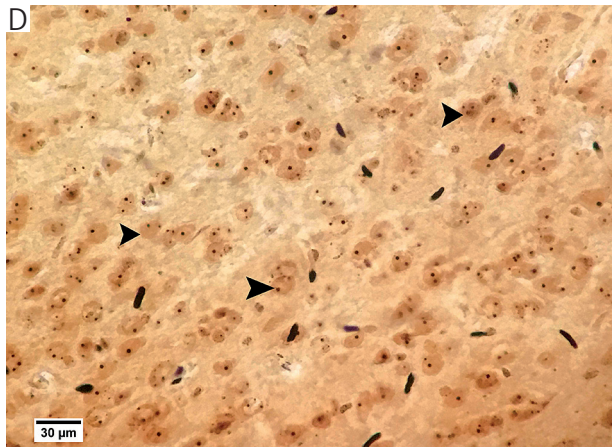
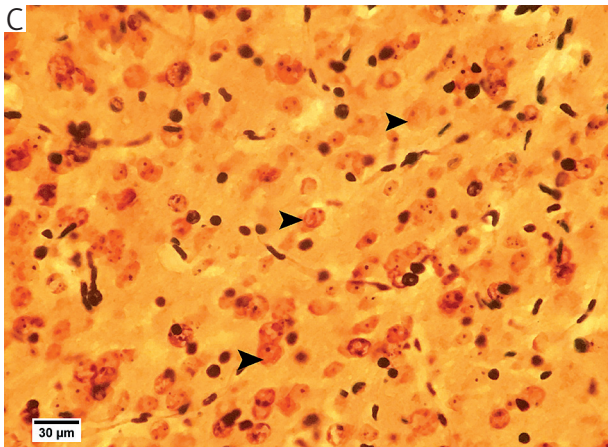
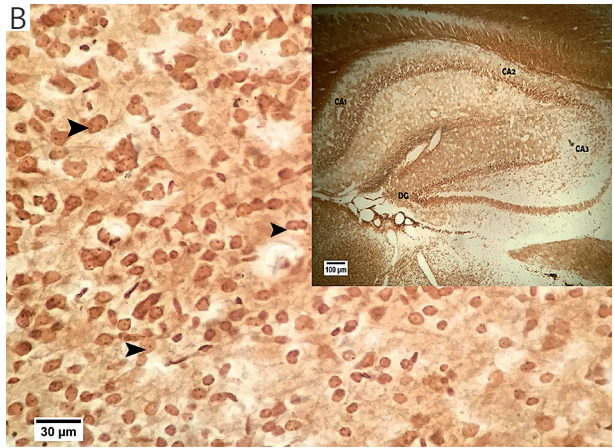
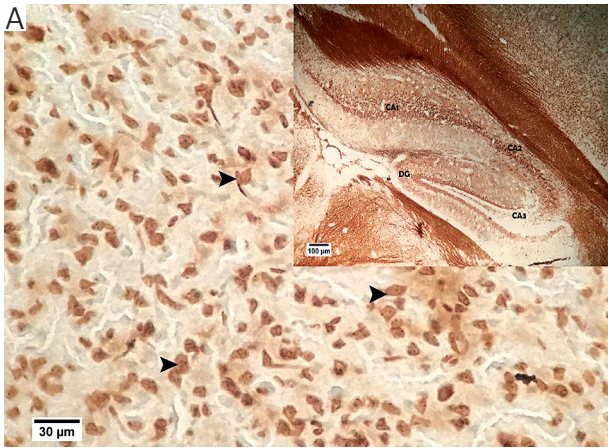
Fig. 7. Effect of oral administration of sinapic acid at doses of 2.5, 5, 10, and 20 mg/kg bw on MDA level in normal and Alzheimeric rats. Each column represents mean ± SEM for 6 rats

Our data showed that the activity of antioxidant enzymes (CAT, SOD and GPX) significantly decreased in the ICV-STZ control group compared to the normal control group. However, administration of sinapic acid (at doses of 10 and 20 mg/kg) significantly increased the activity of these enzymes in the ICV-STZ rats. No significant change was observed in sham-operated rats or normal rats received sinapic acid (at doses 2.5, 5, 10, and 20 mg/kg) as compared to the normal control rats (Figs. 4-6). On the other hand, the level of MDA significantly increased in the ICV-STZ control group compared to the normal control group, and treatment with sinapic acid (at doses 10, and 20 mg/kg) significantly and dose dependently decreased the level of MDA in the brain. No significant change was observed in

the normal rats only treated with sinapic acid (at doses 2.5, 5, 10, and 20 mg/kg) and sham-operated rats (Fig. 7).

Effect of sinapic acid on histological changes in cerebral cortex and hippocampus

Histopathological changes in neurons following ICV-STZ injection, were assessed by Bielschowsky staining on the cerebral cortex and hippocampus sections. In the ICV-STZ (Alzheimer's) group, there was a decrease in neuronal population in different regions of the brain and hippocampus, which is associated with gliosis, severe degeneration, and neuritic plaques (an average of 12 plaques in high power field) in the cerebral cortex. Neuronal loss, especially in CA₁ area, was seen in the hippocampus. The brain



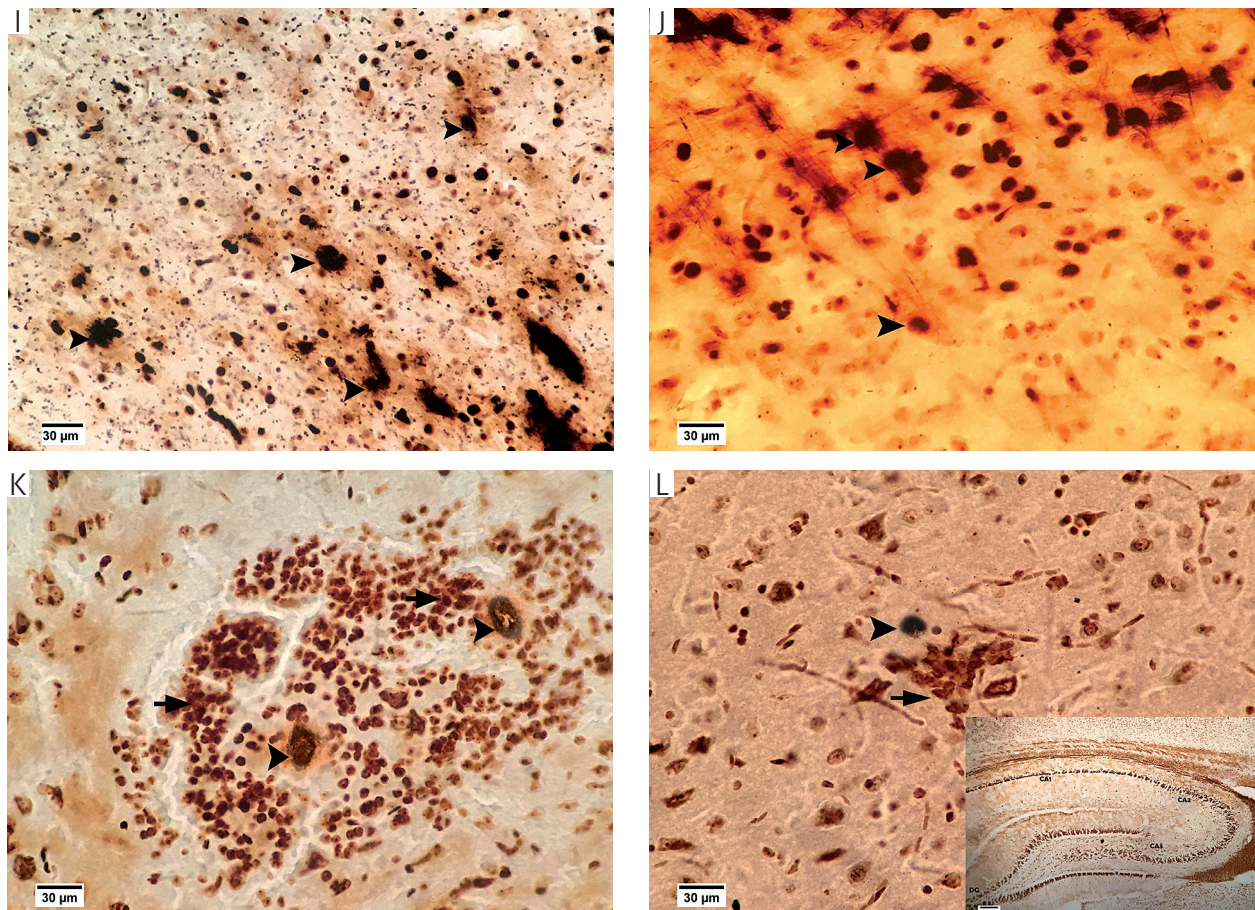


Fig. 8. Effect of sinapic acid administration on histopathological changes in cortex and hippocampus in experimental groups using Bielschowsky staining. A) Sections of the control group show normal cortex with well-organized pyramidal neuronal cell layer (arrowhead) and normal organization of the hippocampus. B) Brain cortex and hippocampus with normal neurons (arrowhead) and organization in the sham-operated group. C-F) Sections of brain cortex in sinapic acid administration (at doses of 2.5, 5, 10, and 20 mg/kg) without STZ injection, which show normal neurons (arrow head) and organization. G) Brain cortex in Alzheimer's group (untreated STZ-injected rats) demonstrates marked gliosis and neuronal degeneration and severe neuritic plaques (arrowhead). H) CA1 in hippocampus in Alzheimer's group with loss of neuronal cells. I) Brain cortex in treated STZ-injected rats (2.5 mg/kg sinapic acid), which shows few neuritic plaques (arrowhead). J) Brain cortex in treated STZ-injected rats (5 mg/kg sinapic acid), which shows few neuronal degeneration and neuritic plaques (arrowhead). K) Brain cortex in treated STZ-injected rats (10 mg/kg sinapic acid), which shows mild gliosis (arrow) and two neuritic plaques (arrowhead). L) Brain cortex in treated STZ-injected rats (20 mg/kg sinapic acid), which shows mild gliosis (arrow) and one neuritic plaques (arrowhead). Hippocampus in this group shows marked restoration of normal architecture

sections of the control normal rats treated with sinapic acid and the sham-operated group, showed no pathological changes in this area. Administration of sinapic acid in Alzheimer's group at doses of 10 and 20 mg/kg, significantly decreased neuronal degeneration and cell loss in cerebral cortex and hippocampus. In the group treated with the dose of 10 mg/kg, there were 2 plaques and in the group treated with the dose of 20 mg/kg, one plaque with mild gliosis was observed (Fig. 8 and Table I).

Discussion

In the present study, we indicated that sinapic acid could dose-dependently reduce the changes of behav-

ioral parameters, increase TNF- α levels, increase activities of CAT, GPX, and SOD, decrease MDA levels, and attenuate histological damage in the cortex and hippocampus in the ICV-STZ rats. According to our results, administration of sinapic acid in ICV-STZ rats, caused behavioral, biochemical, and histological improvements. No significant alterations were seen in the normal rats treated with sinapic acid.

In the current study, administration of STZ caused significant behavioral, biochemical, and histopathological changes in rats. It has been reported that ICV-STZ rodent model is an appropriate animal model for the study of sporadic dementia of Alzheimer's type [35, 36, 37, 38, 39]. ICV administration of STZ in rats leads to impairments in brain biochemistry,

Table I. Effect of sinapic acid at doses of 2.5, 5, 10 and 20 mg/kg bw on neuron numbers in normal and Alzheimeric rats^a

GROUPS	NEURON NUMBERS				
	CORTEX	CA ₁	CA ₂	CA ₃	DENTATE GYRUS
Group I [Normal control]	81.8 ± 1.32	124.0 ± 0.71	48.4 ± 0.40	72.6 ± 0.51	191.2 ± 0.86
Group II [Sham-operated control]	82.8 ± 1.53	124.0 ± 2.43	48.2 ± 0.97	73.2 ± 0.86	193.6 ± 1.91
Group III [Normal + sinapic acid (2.5 mg/kg)]	82.4 ± 2.42	124.2 ± 1.53	47.2 ± 1.80 *	73.4 ± 1.12	194.6 ± 1.56
Group IV [Normal + sinapic acid (5 mg/kg)]	82.6 ± 2.50	123.6 ± 1.50	48.0 ± 1.14	74.8 ± 1.79	189.2 ± 1.53
Group V [Normal + sinapic acid (10 mg/kg)]	80.2 ± 1.59	124.2 ± 0.86	47.2 ± 1.98	73.4 ± 0.67	192.4 ± 0.67
Group VI [Normal + sinapic acid (20 mg/kg)]	78.6 ± 1.36	123.2 ± 1.46	48.2 ± 1.46	73.8 ± 1.11	193.0 ± 1.92
Group VII [Alzheimeric control]	36.6 ± 2.50***	50.0 ± 1.87***	41.0 ± 1.55**	64.0 ± 1.73**	113.2 ± 4.21***
Group VIII [Alzheimeric + sinapic acid (2.5 mg/kg)]	50.6 ± 2.29****	76.6 ± 2.16****	46.8 ± 1.49	64.8 ± 2.11**	170.0 ± 0.77****
Group IX [Alzheimeric + sinapic acid (5 mg/kg)]	69.8 ± 1.36****	109.2 ± 1.43****	45.8 ± 1.39	70.6 ± 1.21+	172.8 ± 1.80****
Group X [Alzheimeric + sinapic acid (10 mg/kg)]	79.0 ± 0.71+++	115.6 ± 1.91+++	49.4 ± 0.93+++	74.2 ± 0.80+++	179.4 ± 1.75****
Group XI [Alzheimeric + sinapic acid (20 mg/kg)]	81.8 ± 1.43+++	119.2 ± 2.20+++	48.4 ± 0.81+++	77.2 ± 1.88+++	181.8 ± 1.72+++

^a The number of neurons in ten field in each area are counted; Values are expressed as mean ± SEM for six rats; * p < 0.05, ** p < 0.01, *** p < 0.001 significantly different from the Alzheimeric control group; +++ p < 0.001, ++++ p < 0.0001 significantly different from the normal control group;

cerebral glucose, energy metabolism, cholinergic transmission and increases free radical generation and demyelination, which finally lead to cognitive deficits [35, 40, 41]. Altogether, these effects resemble sporadic dementia of Alzheimer's type in humans [42]. The exact mechanism of STZ cytotoxicity has not yet been clarified, but it is known that the alkylating effects of STZ metabolites produce reactive oxygen species (ROS), causing oxidative stress and DNA damage. Peripheral administration of STZ (i.p.) is commonly used to generate diabetic model, but ICV-STZ acts through different mechanism from STZ (i.p.), because the oxidative stress caused by STZ (i.p.) and ICV-STZ is not mediated by the same mechanism. This increased oxidative stress may be due to hyperglycemic condition in the brain following STZ administration. Brain slices of ICV-STZ rats showed decreased glucose uptake from incubation medium compared to control rats, which results in hyperglycemia in the brain [43]. In a study by Plaschke and Hoyer [44], increased extracellular glucose was observed in the brain of ICV-STZ injected rats, This may lead to increased nonenzymatic glycosylation of proteins and auto-oxidation of glucose, which results in the generation of advanced glycation end-products. This process leads to subsequent oxidative stress and cellular damage [45].

Our results showed that STZ administration impairs memory recalling without affecting memory acquisition and consolidation in passive avoidance tasks, which is in accordance with earlier studies [46, 47]. Passive avoidance learning refers to learned inhibition of behavior to avoid punishment. Both hippocampus and amygdala are thought to be involved in fear conditioning (passive avoidance) [48]. All these regions of the brain are mainly involved in cholinergic transmission and play vital role in learning and memory processing, and seem to be more prone to oxidative damage [49, 50]. Also, our data indicated that administration of sinapic acid increased memory retention in ICV-STZ rats. In this regard, studies have shown that sinapic acid shows cognitive-improving effects in a CO₂- or scopolamine-induced mouse amnesia model [51, 52]. It has been reported that sinapic acid significantly attenuates memory impairment in passive avoidance task. Also, it has been suggested that sinapic acid ameliorates Aβ1-42 protein-related pathology, such as neuronal cell death and cognitive dysfunction through its anti-oxidative and anti-inflammatory activities and may be an efficacious treatment for AD [16].

In line with other studies, our results showed that TNF-α levels increased in hippocampus of ICV-STZ rats [53, 54]. Also, our data showed that administration of sinapic acid could decrease TNF-α level in hippocampus of ICV-STZ rats. These results are similar to those of other studies that believe the link between

neuroinflammation and memory deficits [55, 56]. Release of TNF- α and interleukin 1 β (IL-1 β) initiates inflammatory cascades [57]. Therefore, TNF- α and IL-1 β are considered as markers of inflammation in peripheral tissue and brain [56]. Also, some studies believe that TNF- α induces reactive oxygen species toxicity and oxidative stress [58, 59]. The expression of cytokines, generation of free radicals, and neurodegenerative changes are correlated with each other and may contribute to the pathologic process [60]. The antioxidant and anti-inflammatory activities of sinapic acid have been well reported in the literature [3, 61]. It is known that sinapic acid has an anti-inflammatory effect in macrophages through suppression of inducible nitric oxide synthase (iNOS) and cyclooxygenase-2 (COX-2) and expression of proinflammatory cytokines, such as TNF- α , and IL-1 β [3]. Sinapic acid has neuroprotective, free radical scavenging, and anti-inflammatory activities [3], suggesting that sinapic acid could be an appropriate agent for the treatment of AD and other neurodegenerative diseases. Sinapic acid pretreatment significantly alleviates nitric oxide-induced nitrosative stress, leading to reduction of inflammation and vasoconstriction of endothelial cells and prevention of necrosis [62, 63]. Therefore, sinapic acid is an approved potent anti-inflammatory [2, 3] and neuroprotective agent [15, 51].

In the present study, examination of the hippocampal homogenates of ICV-STZ rats, showed a significant reduction in the activities of antioxidant enzymes (SOD, CAT, and GPX) and increased MDA level. Our findings showed that administration of sinapic acid increased the activities of antioxidant enzymes and decreased MDA levels. The alterations in oxidative stress markers and memory deficits in STZ-induced dementia model was similar to the results of Sharma and Gupta [23], suggesting that STZ-induced impairment of learning and memory are associated with oxidative stress in rats. Free radical damage to macromolecules (sugar, lipid, protein, and nucleic acids) accelerates aging and causes age-related neurodegenerative diseases, such as AD [64, 65]. Lipid peroxidation is an indicator of neuronal membrane degeneration. It has been reported that brain lipid peroxidation occurs in early AD [66]. It has also been shown that aging increases lipid peroxidation in the senescence-accelerated mouse brain [67]. MDA is one of the end-products of lipid peroxidation and the key pathogenic factor in biomembrane damage [68]. Increased levels of MDA and decreased levels of antioxidant enzymes (SOD, CAT, and GPX) are considered to be the indicators of oxidative stress. Given that oxidative damage plays a role in the etiology of neurological diseases, treatment with antioxidants is considered as a therapeutic strategy in different neurodegenerative disorders. It

has been suggested that sinapic acid is a highly effective radical scavenger with potent antioxidant activity [4, 6, 69]. It is likely that the apparent neuroprotective effect of sinapic acid in the hippocampal CA₁ region depends on the sensitivity of the hippocampal CA₁ neurons to oxidative stress [70, 71]. It is well-known that sinapic acid has antioxidant and anti-lipid peroxidation activities [12, 72, 73]. In this regard, it has been indicated that sinapic acid reduces lipid peroxidation level and protects cardiac cells from membrane damage through its antioxidant potential. The antioxidant activity of sinapic acid was possible due to the presence of phenolic groups as reported in the literature [61]. It is known that pre-and-co-treatment with sinapic acid normalizes the levels of lipid peroxidation products, thereby inhibiting oxidative stress and stabilizing lysosomal membrane in isoproterenol-induced rats. This effect revealed that anti-lipid peroxidation and membrane stabilizing activities of sinapic acid is due to its free radical scavenging and membrane stabilizing effects [72].

The effect of sinapic acid was also seen on histopathological changes in brain regions of rats treated with STZ. The histopathological changes were examined using Bielschowsky staining in sequential brain sections to determine the extent of damage induced by STZ. Brain sections of STZ-treated rats showed cell loss, neuronal necrosis associated with gliosis and neurofibrillary tangles (NFTs) in the cerebral cortex, and disorganization of hippocampus as compared to normal control and sham-operated groups. STZ caused damage to the hippocampus, especially in CA₁ region, and the morphology of cells changed in this particular region as compared to the normal control group. Rai *et al.* [73] suggest that STZ treatment caused enhanced neuroinflammatory mediators and altered redox stress that contribute to the neurodegenerative processes. These free radicals also further trigger the neuronal damage via formation of pro-inflammatory mediators and associated cytotoxic products during neuroinflammation that can be detrimental to neuronal function. Sinapic acid treatment prevents the damage and causes less damage to the cortical and hippocampal cells compared to STZ-treated rats. These histopathological changes following STZ administration indicate neuronal degeneration in the cortex and hippocampus, which is mainly involved in memory regulation.

In the present study, administration of sinapic acid significantly improves cognitive behavior and biochemical and histopathological changes in ICV-STZ infused rats. Neuroprotective effect of sinapic acid suggests that it is a potent antioxidant, which is in agreement with previous studies [16, 74, 75]. Therefore, these results indicate that sinapic acid could be an effective agent for reducing neurotoxicity through antagonizing oxidative damage induced by ICV-STZ.

It has been claimed that sinapic acid can significantly inhibit hypoxia-induced memory impairment [51] and reduce kainic acid-induced hippocampal cell death [15] through its free radical scavenging activity. Also, Zou *et al.* [2] reported that sinapic acid has a peroxynitrite scavenging effect, and suggested that sinapic acid may play a vital role in the neuronal protection against peroxynitrite-associated diseases. It has been reported that sinapic acid attenuate A β 1-42 protein-induced activation of microglia and astrocytes. Therefore, sinapic acid is an approved potent anti-inflammatory [2, 3] and neuroprotective agent [15, 51].

In summary, our results confirm that ICV-STZ administration can induce behavioral, biochemical, and histopathological changes due to free-radical generation. Administration of sinapic acid significantly and dose-dependently reduced these changes, which was supported by increase in endogenous antioxidant defense system and decrease in inflammatory responses. These effects may be partly due to its antioxidant and anti-inflammatory activities. The present study showed that sinapic acid can serve as a useful probe in the study of clinical pharmacology of neuronal damage and may be helpful in attenuating oxidative stress and inflammation in neurodegenerative disorders, such as AD.

The authors declare no conflict of interest.

References

- Alasalvar C, Karamac M, Amarowicz R, et al. Antioxidant and antiradical activities in extracts of hazelnut kernel (*Corylus avellana* L.) and hazelnut green leafy cover. *J Agric and Food Chem* 2006; 54: 4826-4832.
- Zou Y, Kim AR, Kim JE, et al. Peroxynitrite scavenging activity of sinapic acid (3,5-dimethoxy-4-hydroxycinnamic acid) isolated from *Brassica juncea*. *J Agric Food Chem* 2002; 50: 5884-5890.
- Yun KJ, Koh DJ, Kim SH, et al. Anti-inflammatory effects of sinapic acid through suppression of inducible nitric oxide synthase, cyclooxygenase-2 and proinflammatory cytokines expression via nuclear factor-kB inactivation. *J Agric Food Chem* 2008; 56: 10265-10272.
- Nowak H, Kujawa K, Zadernowski R, et al. Antioxidative and bactericidal properties of phenolic compounds in rapeseeds. *Fat Sci Technol* 1992; 94: 149-152.
- Teixeira J, Gaspar A, Garrido EM, et al. Hydroxycinnamic acid antioxidants: an electrochemical overview. *Biomed Res Int* 2013; 2013: 251754.
- Tesaki S, Tanabe S, Ono H, et al. 4-Hydroxy-3-nitrophenylacetic and sinapic acids as antibacterial compounds from mustard seeds. *Biosci Biotechnol Biochem* 1998; 62: 998-1000.
- Engels C, Schieber A, Ganzle MG. Sinapic acid derivatives in defatted oriental mustard (*Brassica juncea* L.) seed meal extracts using UHPLC-DAD-ESI-MSn and identification of compounds with antibacterial activity. *Eur Food Res Technol* 2012; 234: 535-542.
- Kanchana G, Shyni WJ, Rajadurai M, et al. Evaluation of antihyperglycemic effect of sinapic acid in normal and streptozotocin-induced diabetes in albino rats. *Global J Pharmacol* 2011; 5: 33-39.
- Barber MS, McConnell VS, DeCaux BS. Antimicrobial intermediates of the general phenylpropanoid and lignin specific pathways. *Phytochem* 2000; 54: 53-56.
- Johnson ML, Dahiya JP, Olkowski AA, et al. The effect of dietary sinapic acid (4-hydroxy-3, 5-dimethoxy-cinnamic acid) on gastrointestinal tract microbial fermentation, nutrient utilization, and egg quality in laying hens. *Poul Sci* 2008; 87: 958-963.
- Yoon BH, Jung JW, Lee JJ, et al. Anxiolyticlike effects of sinapic acid in mice. *Life Sci* 2007; 81: 234-240.
- Roy SJ, Mainzen Prince PS. Protective effects of sinapic acid on cardiac hypertrophy, dyslipidaemia and altered electrocardiogram in isoproterenol-induced myocardial infarcted rats. *Eur J Pharmacol* 2013; 699: 213-218.
- Silambarasan T, Manivannan J, Priya MK, et al. Sinapic acid prevents hypertension and cardiovascular remodeling in pharmacological model of nitric oxide inhibited rats. *PLoS One* 2014; 9: 115682.
- Hudson EA, Dinh PA, Kokubun T, et al. Characterization of potentially chemopreventive phenols in extracts of brown rice that inhibit the growth of human breast and colon cancer cells. *Cancer Epidemiol Biomarkers Prev* 2000; 9: 1163-1170.
- Kim DH, Yoon BH, Jung WY, et al. Sinapic acid attenuates kainic acid-induced hippocampal neuronal damage in mice. *Neuropharmacology* 2010; 59: 20-30.
- Lee HE, Kim DH, Park SJ, et al. Neuroprotective effect of sinapic acid in a mouse model of amyloid β (1-42) protein-induced Alzheimer's disease. *Pharmacol Biochem Behav* 2012; 103: 260-266.
- Hoyer S. Causes and consequences of disturbances of cerebral glucose metabolism in sporadic Alzheimer disease: therapeutic implications. *Adv Exp Med Biol* 2004; 541: 135-152.
- Hoyer S. Glucose metabolism and insulin receptor signal transduction in Alzheimer disease. *Eur J Pharmacol* 2004; 490: 115-125.
- Kamat PK, Rai S, Swarnkar S, et al. Mechanism of synapse redox stress in okadaic acid (ICV) induced memory impairment: role of NMDA receptor. *Neurochem Int* 2014; 76: 32-41.
- Hardy J, Selkoe DJ. The amyloid hypothesis of Alzheimer's disease: progress and problems on the road to therapeutics. *Science* 2002; 297: 353-56.
- Agrawal R, Tyagi E, Shukla R, et al. Insulin receptor signaling in rat hippocampus: a study in STZ (ICV) induced memory deficit model. *Eur Neuropsychopharmacol* 2011; 21: 261-273.
- Labak M, Foniok T, Kirk D, et al. Metabolic changes in rat brain following intracerebroventricular injections of streptozotocin: a model of sporadic Alzheimer's disease. *Acta Neurochir Suppl* 2010; 106: 177-181.
- Sharma M, Gupta YK. Intracerebroventricular injection of streptozotocin in rats produces both oxidative stress in the brain and cognitive impairment. *Life Sci* 2001; 68: 1021-1029.
- Ahmad M, Saleem S, Ahmad AS, et al. Ginkgo biloba affords dose-dependent protection against 6-hydroxydopamine-induced parkinsonism in rats: neurobehavioural, neurochemical and immunohistochemical evidences. *J Neurochem* 2005; 93: 94-104.
- Ansari MA, Ahmad AS, Ahmad M, et al. Selenium protects cerebral ischemia in rat brain mitochondria. *Biol Trace Elem Res* 2004; 101: 73-86.
- Paxinos G, Watson C. *The Rat Brain in Stereotaxic Coordinates*. Sydney Academic press, 1986.
- Sharma M, Gupta YK. Effect of alpha lipoic acid on intracerebroventricular streptozotocin model of cognitive impairment in rats. *Eur Neuropsychopharmacol* 2003; 13: 241-247.
- Raghavendra V, Kulkarni SK. Possible antioxidant mechanism in melatonin reversal of aging and chronic ethanol-induced amnesia in plus-maze and passive avoidance memory tasks. *Free Radic Biol Med* 2001; 30: 595-602.

29. Deak T, Bellamy C, D'Agostino LG. Exposure to forced swim stress does not alter central production of IL-1. *Brain Res* 2003; 972: 53-63.
30. Elçioglu HK, Kabasakal L, Tufan F, et al. Effects of systemic Thalidomide and intracerebroventricular etanercept and infliximab administration in a streptozotocin induced dementia model in rats. *Acta Histochemica* 2015; 117: 176-181.
31. Aebi H. Catalase in vitro. *Methods Enzymol* 1984; 105: 121-126.
32. Sun Y, Oberley LW, Li Y. A simple method for clinical assay of superoxide dismutase. *Clin Chem* 1988; 34: 497-500.
33. Paglia DE, Valentine WN. Studies on the quantitative and qualitative characterization of erythrocyte glutathione peroxidase. *J Lab Clin Med* 1967; 70: 158-169.
34. Halliwell B, Chirico S. Lipid peroxidation: its mechanism, measurement, and significance. *Am J Clin Nutr* 1993; 57: 715-724.
35. Ishrat T, Hoda MN, Khan MB, et al. Amelioration of cognitive deficits and neurodegeneration by curcumin in rat model of sporadic dementia of Alzheimer's type (SDAT). *Eur Neuro-psychopharmacol* 2009; 19: 636-647.
36. Agrawal R, Tyagi E, Shukla R, et al. A study of brain insulin receptors, AChE activity and oxidative stress in rat model of ICV STZ induced dementia. *Neuropharmacology* 2009; 56: 779-787.
37. Nitsch R, Hoyer S. Local action of the diabetogenic drug, streptozotocin, on glucose and energy metabolism in rat brain cortex. *Neurosci Lett* 1991; 128: 199-202.
38. Lannert H, Hoyer S. Intracerebroventricular administration of streptozotocin causes long-term diminutions in learning and memory abilities and in cerebral energy metabolism in adult rats. *Behav Neurosci* 1998; 112: 1199-1208.
39. Salkovic-Petrisic M, Knezovic A, Hoyer S, et al. What have we learned from the streptozotocin-induced animal model of sporadic Alzheimer's disease, about the therapeutic strategies in Alzheimer's research. *J Neural Transm* 2013; 120: 233-252.
40. Hoyer S, Lannert H. Inhibition of the neuronal insulin receptor causes Alzheimer-like disturbances in oxidative/energy brain metabolism and in behavior in adult rats. *Ann N Y Acad Sci* 1999; 893: 301-303.
41. Shoham S, Bejar C, Kovalev E, et al. Intracerebroventricular injection of streptozotocin causes neurotoxicity to myelin that contributes to spatial memory deficits in rats. *Exp Neurol* 2003; 184: 1043-1052.
42. Hoyer S, Nitsch R, Oesterreich K. Predominant abnormality in cerebral glucose utilization in late-onset dementia of the Alzheimer type: a cross-sectional comparison against advanced late-onset and incipient early-onset cases. *J Neural Transm Park Dis Dement Sect* 1991; 3: 1-14.
43. Pathan AR, Viswanad B, Sonkusare SK, et al. Chronic administration of pioglitazone attenuates intracerebroventricular streptozotocin induced-memory impairment in rats. *Life Sci* 2006; 79: 2209-2216.
44. Plaschke K, Hoyer S. Action of the diabetogenic drug streptozotocin on glycolytic and glycogenolytic metabolism in adult rat brain cortex and hippocampus. *Int J Dev Neurosci* 1993; 11: 477-483.
45. Ott A, Stolk RP, van Harskamp F, et al. Diabetes mellitus and the risk of dementia: the Rotterdam study. *Neurol* 1999; 53: 1937-1942.
46. Awasthi H, Tota S, Hanif K, et al. Protective effect of curcumin against intracerebral streptozotocin induced impairment in memory and cerebral blood flow. *Life Sci* 2010; 86: 87-94.
47. Ishrat T, Khan MB, Hoda MN, et al. Coenzyme Q10 modulates cognitive impairment against intracerebro-ventricular infusion of streptozotocin in rats. *Behav Brain Res* 2006; 171: 9-16.
48. Lenard L, Kertes E. Influence of passive avoidance learning by substance P in the basolateral amygdala. *Acta Biol Hung* 2002; 53: 95-104.
49. Arendt T. Alzheimer's disease as a disorder of mechanisms underlying structural brain self-organization. *Neurosci* 2001; 102: 723-765.
50. Pratico D, Delanty N. Oxidative injury in diseases of the central nervous system: focus on Alzheimer's disease. *Am J Med* 2000; 109: 577-585.
51. Karakida F, Ikeya Y, Tsunakawa M, et al. Cerebral protective and cognition-improving effects of sinapic acid in rodents. *Biol Pharm Bull* 2007; 30: 514-519.
52. Sun XL, Ito H, Masuoka T, et al. Effect of Polygala tenuifolia root extract on scopolamine-induced impairment of rat spatial cognition in an eight-arm radial maze task. *Biol Pharm Bull* 2007; 30: 1727-1731.
53. Misra S, Tiwari V, Kuhad A, et al. Modulation of nitrergic pathway by sesamol prevents cognitive deficits and associated biochemical alterations in intracerebroventricular streptozotocin administered rats. *Eur J Pharmacol* 2011; 659: 177-186.
54. Kamat PK, Tota S, Rai S, et al. A study on neuroinflammatory marker in brain areas of okadaic acid (ICV) induced memory impaired rats. *Life Sci* 2012; 90: 713-720.
55. Wei P, Liu Q, Li D, et al. Acute nicotine treatment attenuates lipopolysaccharide-induced cognitive dysfunction by increasing BDNF expression and inhibiting neuroinflammation in the rat hippocampus. *Neurosci Lett* 2015; 604: 161-166.
56. Qin L, He J, Hanes RN, et al. Increased systemic and brain cytokine production and neuroinflammation by endotoxin following ethanol treatment. *J Neuroinflammation* 2008; 5: 10.
57. Frankola KA, Greig NH, Luo W, et al. Targeting TNF-alpha to elucidate and ameliorate neuroinflammation in neurodegenerative diseases. *CNS Neurol Disord Drug Targets* 2011; 10: 391-403.
58. Arsenijevic D, Bilbao FD, Giannakopoulos P, et al. A role for interferon-gamma in the hypermetabolic response to murine toxoplasmosis. *Eur Cytokine Netw* 2001; 12: 518-527.
59. Victor VM, De la Fuente M. Several functions of immune cells in mice changed by oxidative stress caused by endotoxin. *Physiol Res* 2003; 52: 789-796.
60. Fernandez-Botran R, Miller JJ, Burns VE, et al. Correlations among inflammatory markers in plasma, saliva and oral mucosal transudate in post-menopausal women with past intimate partner violence. *Brain Behav Immun* 2011; 25: 314-321.
61. Gaspar A, Martins M, Silva P, et al. Dietary phenolic acids and derivatives. Evaluation of the antioxidant activity of sinapic acid and its alkyl esters. *J Agric Food Chem* 2010; 58: 12273-12280.
62. Ghaznavi R, Kadkhodae M. Comparative effects of selective and non-selective nitric oxide synthase inhibition in gentamicin-induced rat nephrotoxicity. *Arch Toxicol* 2007; 81: 453-457.
63. Mahmoud AM, Ahmed OM, Galaly SR. Thymoquinone and curcumin attenuate gentamicin-induced renal oxidative stress, inflammation and apoptosis in rats. *EXCLI J* 2014; 13: 98-110.
64. Liu R, Liu IY, Bi X, et al. Reversal of age-related learning deficits and brain oxidative stress in mice with superoxide dismutase/catalase mimetics. *Proc Natl Acad Sci USA* 2001; 100: 8526-8531.
65. Wickens AP. Ageing and the free radical theory. *Respir Physiol* 2001; 128: 379-391.
66. Williams TI, Lynn BC, Markesbery WR, et al. Increased levels of 4-hydroxynonenal and acrolein, neurotoxic markers of lipid peroxidation, in the brain in mild cognitive impairment and early Alzheimer's disease. *Neurobiol Aging* 2006; 27: 1094-1099.
67. Petursdottir AL, Farr SA, Morley JE, et al. Lipid peroxidation in brain during aging in the senescence-accelerated mouse (SAM). *Neurobiol Aging* 2007; 28: 1170-1178.
68. Nayagam AAJ, Sudhakar N, Manoran S. Hepatoprotective efficacy of *Tricholepis radicans* DC against CCl4 induced liver toxicity in albino rats. *J Pharm Res* 2011; 4: 1073-1075.

69. Galano A, Francisco-Marquez M, Alvarez-Idaboy JR. Mechanism and kinetics studies on the antioxidant activity of sinapic acid. *Phys Chem Chem Phys* 2011; 13: 11199-11205.
70. Wang X, Pal R, Chen XW, et al. High intrinsic oxidative stress may underlie selective vulnerability of the hippocampal CA1 region. *Brain Res Mol Brain Res* 2005; 140: 120-126.
71. Wilde GJ, Pringle AK, Wright P, et al. Differential vulnerability of the CA1 and CA3 subfields of the hippocampus to superoxide and hydroxyl radicals in vitro. *J Neurochem* 1997; 69: 883-886.
72. Roy SJ, Mainzen Prince PS. Protective effects of sinapic acid on lysosomal dysfunction in isoproterenol induced myocardial infarcted rats, *Food Chem Toxicol* 2012; 50: 3984-3989.
73. Rai S, Kamat PK, Nath C, et al. A study on neuroinflammation and NMDA receptor function in STZ (ICV) induced memory impaired rats. *J Neuroimmunol* 2013; 254: 1-9.
74. Pari L, Mohamed Jalaludeen A. Protective role of sinapic acid against arsenic – induced toxicity in rats. *Chemi Biol Interact* 2011; 194: 40-47.
75. Silambarasan T, Manivannan J, Priya MK, et al. Sinapic acid protects heart against ischemia/reperfusion injury and H9c2 cardiomyoblast cells against oxidative stress. *Biochem Biophys Res Commun* 2015; 456: 853-859.

Address for correspondence

Akram Eidi
 Department of Biology
 Science and Research Branch
 Islamic Azad University
 Fars
 16535 Tehran, Iran
 e-mail: akram_eidi@yahoo.com