

CASE REPORT

**SPONTANEOUS PATHOLOGICAL COMPLETE REGRESSION
OF HIGH-GRADE TRIPLE-NEGATIVE BREAST CANCER
WITH AXILLARY METASTASIS**GÁBOR CSERNI¹, ORSOLYA SERFŐZŐ², ÉVA AMBRÓZAY², LÁSZLÓ MARKÓ³, LÁSZLÓ KRENÁCS⁴¹Institute of Pathology, University of Szeged, Szeged, Hungary²Breast Imaging Unit, Mamma Rt, Kecskemét, Hungary³Departments of Oncology and Surgery, Bács-Kiskun County Teaching Hospital, Kecskemét, Hungary⁴Laboratory of Tumour Pathology and Molecular Diagnostics, Szeged, Hungary

We report on a breast carcinoma with medullary features diagnosed by core needle biopsy in a 72-year-old woman. Both the primary tumour and its fine needle aspiration-proven, rapidly growing axillary metastasis regressed completely in less than 2 months, by the time surgery was performed. The biopsy of the primary tumour demonstrated a dense stromal infiltrate of CD8+/granzyme B+ activated cytotoxic T-cells suggestive of a robust antitumour immune response. Paradoxically, both tumour cells and tumour infiltrating immune cells demonstrated a diffuse PD-L1 expression, revealing that antitumour immune response has the ability to spontaneously overcome inhibitory mechanisms induced by cancerous growth.

Key words: PD-L1, spontaneous regression, tumour-infiltrating lymphocytes, triple-negative breast cancer.

Introduction

Spontaneous regression of malignant tumours is defined as the disappearance of cancer without any therapy given or following a treatment that is considered inadequate to cure this disease. It is a rare event, estimated to occur in 1 out of 60,000 to 100,000 cases [1], and is more common in some types of tumours (e.g. melanoma) than others. Breast cancer regression was reported in 43/741 cases of spontaneously regressing cancers compiled and summarized by Challis and Stam reviewing the period of 1900-1987 [2], and only a few additional reports have been published since [3 4, 5, 6, 7]. Several mechanisms have been implicated, but most authors associate spontaneous regression with variously activated antitumour immunity [2]. Here, we report on a biopsy-proven breast cancer with axillary metastasis that spontaneously regressed completely in less than 2 months.

Case report

A 72-year-old obese female with type 2 diabetes and hypertension was recalled after attending an opportunistic screening mammography (day 0 of her presented history; Fig. 1A). She appeared 27 days later, when her right breast was perceived as having a 7-mm circumscribed nonpalpable benign lesion with microcalcification in the upper-outer quadrant at the 10 o'clock position, with a physically negative ipsilateral axilla, which on ultrasound (US) showed an enlarged lymph node (13 × 8 mm) with a thickened cortical layer. In contrast, the upper-outer quadrant of her left breast harboured an ill-defined, spiculated mass with microcalcification (Fig. 1B); this corresponded to a firm mobile palpable mass measuring 16 mm in the greatest dimension on US, located in the two o'clock position, 2 cm from the areola and 6 mm deep from the skin. The left axilla demonstrated a rounded pathological lymph

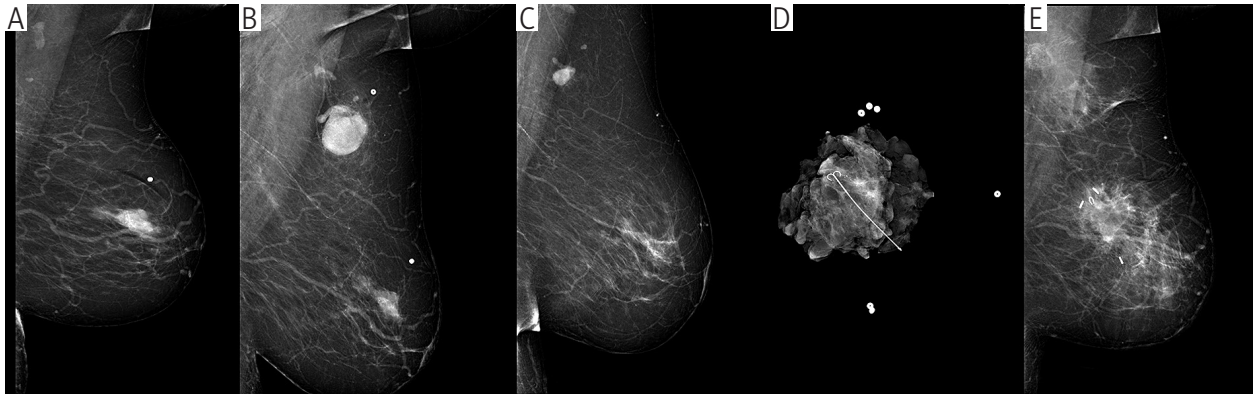

Fig. 1. The figure demonstrates different time points of the case history on single-view left side mammography. A) The screening medio-lateral-oblique (MLO) view at time 0 shows the primary tumour in the upper-outer quadrant. B) After recall, on day 27, the MLO view shows the tumour in the same location with a newly identified axillary metastasis. C) On day 83, before the introduction of the localising hooked wire, the tumour site and the metastasis are less evident on the ML view. D) The specimen mammogram shows the wire guided removal of the primary tumour site. E) The MLO view of the operated left breast on day 131 shows the clips in the tumour bed area, with no evidence of residual disease or calcification

node, which was not present on the screening mammogram (Fig. 1B); this measured 34×25 mm on US. 14G needle core biopsy was obtained from the left sided primary tumour, and this resulted in a grade 3 (poorly differentiated) carcinoma with medullary features, also classified as lymphocyte predominant breast cancer with over 60% stromal mononuclear cells [8] (Fig. 2A). The phenotype was triple-negative, i.e. the tumour cells were negative for oestrogen receptors (ER), progesterone receptors (PR), and human epidermal growth factor receptor-2 (HER2), but showed cytokeratin 5 staining and high (about 60%) Ki-67/MIB1 labelling on immunohistochemistry. US-guided fine needle aspiration cytology was done on both axillary lymph nodes described, yielding a negative result on the right side and proving metastatic involvement on the left side (Fig. 2B). Magnetic resonance imaging of the breasts could not be performed due to the patient being

oversized for the machine. On the basis of a multidisciplinary team decision, the right sided breast lesion was also targeted with US-guided core needle biopsy on day 40; this resulted in an invasive carcinoma diagnosis (luminal A-like no special type carcinoma, grade X – ungradable due to limited amount of material, but non-high grade; ER and PR highly expressed, HER2-negative, CK5-negative, Ki-67/MIB1 labelling of around 10%, Table I). Performance of bilateral radio-guided and wire-guided wide local excisions plus right sided sentinel lymph node biopsy and left sided axillary lymph node dissection were decided; these were done on day 83 of the presented medical history, 56 days after the left sided biopsies. The left sided lesion was not easy to localise preoperatively (Fig. 1C), but the critical area was confirmed to be removed by specimen mammography (Fig. 1D). The 82-g, dominantly fatty specimen included a 14×11 -mm tumour bed with no re-

Table I. The table shows the antibodies used and there sources, dilutions used in the analysis

ANTIBODY	6F11	SOURCE	DILUTION
ER	PgR3112	Leica-Novocastra	1:400
PR	4B5	Leica-Novocastra	1:200
HER2	DO7	Roche-Ventana	RTU
p53	XM26	Leica-Novocastra	RTU
CK5	MIB1	Thermo-Fisher	1:20
Ki67	22c3	Dako-Agilent	1:100
PD-L1	NAT105	Dako-Agilent	1:40
PD1	11F1	Abcam	1:50
Granzyme B	polyclonal	Leica-Novocastra	1:100
CD3	1A5	Dako-Agilent	RTU
CD8	Frequent	Biocare	1:150

sidual carcinoma, but wavy loose fibrotic tissue, and focal aggregates of lymphocytes and calcifications (Fig. 2C). No lymph node metastases were detected, but two lymph nodes also demonstrated signs of regression with a similar wavy loose fibrous tissue (Fig. 2D). Although radio-pathological correlation was present, a repeated breast imaging was performed on day 131; it showed a postoperative status with clips in the excision area, but no signs of residual disease (Fig. 1E). The whole excised breast was investigated histologically, and this showed no residual invasive tumour or tumour bed; however, a low-grade (well-differentiated), ER-positive, HER2-negative, and CK5-negative solid and cribriform ductal carcinoma *in situ* (DCIS) of 8 mm greatest dimension was found away from the tu-

mour bed. We obtained a careful history of the patient. There have been no changes in food, nor in drugs taken for her diabetes and hypertension. Metformin (1000 mg twice daily), an antidiabetic with reported antitumor activity [9] had been part of her treatment for many years, she was taking it before the diagnosis of breast cancer, during its fast nodal progression (Fig. 1A, B) and its regression (Fig. 1B, C). Spontaneous regression of the grade 3 carcinoma and its axillary metastases was established, and the ipsilateral DCIS identified was considered an incidentally identified different disease. The right sided carcinoma corresponded to a 5-mm carcinoma of no special type, and its single sentinel node was free of metastasis. Adjuvant aromatase inhibitor treatment was initiated.

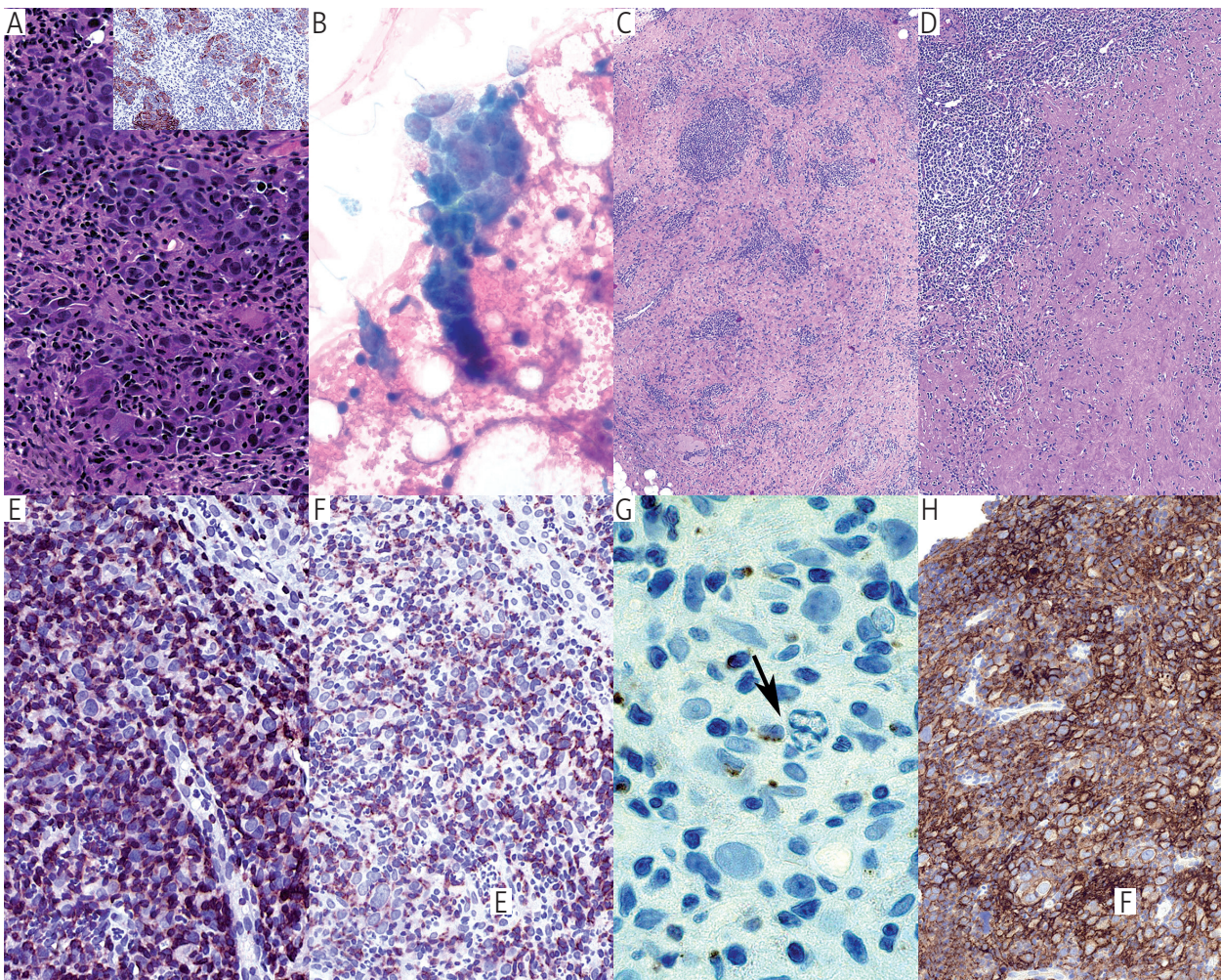


Fig. 1. The figure shows different microscopical aspects of the primary tumour (bed) and its nodal metastasis (bed). A) Detail of the core needle biopsy of the primary tumour shows a lymphocyte rich stroma and pleomorphic tumour cells (HE, 60 \times ; Insert: CK5 immunostaining, 40 \times). B) The fine needle aspirate from the metastatic lymph node shows tumour cells and smaller lymphocytes (Papanicolaou, 60 \times). C) The operative specimen showed a tumour bed empty of tumour cells, but with foci of lymphoid aggregates (HE, 60 \times). D) The lymph node also shows complete regression with fibrous transformation (HE, 60 \times). E) The CD3 reaction highlights that the majority of the stromal lymphocytes are T-cells (CD3, 60 \times). F) The dense lymphoid infiltrate is composed of CD8-positive T-cells (CD8, 60 \times). G) The high-power granzyme-B immunostain illustrates the close contact of activated cytotoxic (killer) T-cells with a tumour cell with the apoptosis of the latter (arrow; Granzyme-B, 100 \times). H) The tumour biopsy demonstrates intense and diffuse PD-L1 positivity in both tumour cells and the infiltrating immune cells (PD-L1, 40 \times)

Histological re-appraisal of the primary tumour sample of the regressed carcinoma demonstrated dense peritumoural and intratumoural stromal lymphocytic infiltrate giving the impression that virtually every tumour cell was in direct physical contact with lymphocytes (Fig. 2A, E-H). These lymphocytes were predominantly CD8+/granzyme B+ activated cytotoxic T-cells, and scattered apoptotic tumour cells could also be appreciated (Fig. 2G). Furthermore, the sample demonstrated diffuse programmed cell death ligand 1 (PD-L1) expression in tumour cells and infiltrating immune cells (Fig. 2H), while programmed cell death (PD1) molecules showed up to 50% positivity rate restricted to the infiltrating lymphocytes.

Discussion

Spontaneous regression of breast cancer is a rare event, and although recognised in the medical literature, it is still a surprising phenomenon. With current interest in antitumour immunity and its stimulation with immunotherapy and immune checkpoint inhibitors, these cases might deserve special attention.

Due to the rarity of the phenomenon of spontaneous regression, case reports and their compilations only collect possible explanations, and the study of the reported single cases is restricted by the lack of sufficient data on a number of newly introduced biomarkers. Immune mechanisms are the most commonly mentioned possible cause of cancer regression, but infectious, hormonal, operative trauma-related, ischaemia/necrosis-related factors have all been mentioned in the literature [2].

Even the rare case reports on spontaneously regressive breast cancer are heterogeneous: they include partial or nearly complete regression [4, 5], and complete regression cases [3, 4]. The preoperative diagnosis of spontaneously regressive breast cancers is also variable, some rely on fine needle aspirates only [5, 7], and a few have a tissue diagnosis by core needle biopsy [3, 6], allowing the assessment of the lymphoid component at diagnosis. The postoperative assessment either showed necrosis with inflammatory cells [5] or, as in the presented case, a fibrotic tumour bed with inflammatory cells [7]. The phenotype of the tumours has been rarely reported, but it seems that oestrogen receptor-positive carcinomas have also regressed spontaneously [5], or on corticosteroid alone [4], although the phenomenon might be more common in triple-negative carcinomas [6] or oestrogen and progesterone receptor negative carcinomas when HER2 was not tested [3]. Our spontaneously regressive case seems to represent a basal-like carcinoma on the basis of the triple-negative phenotype, and diffuse CK5 and p53 expression [10]. In keeping with the presented history, medullary carcinomas (generally triple-negative in phenotype) had better prognosis than carcinomas of no special type of the same grade, and medullary carcinomas with greater amount of lymphoid stroma had better survival than those with fewer mononuclear cells [11],

pointing to the role tumour infiltrating lymphocytes may play in antitumour defence.

Both CD4- and CD8-positive subsets of CD3-positive T-cells have been implicated in the genesis of spontaneous regression [5], although natural killer cells were also suggested in another case [4]. The initiation might be related to the biopsy trauma, as suggested by Maillet *et al.* [6]. Our findings suggest a robust antitumour immune response mediated by activated cytotoxic (killer) T-cells. To the best of our knowledge, our report is the first that reveals strong and diffuse tumoural expression of PD-L1 in spontaneously regressive breast cancer, a molecule that may play a major role in tumour-associated T-cell inhibitory mechanisms [12]. One could assume that such a PD-L1 expression is contrary to spontaneous regression because high PD-L1 expression was found to be associated with poor prognosis [13], but this phenomenon may suggest that the antitumour immune response has the ability to spontaneously overcome inhibitory mechanisms induced by cancerous growth. Our finding of strong and diffuse PD-L1 expression is in keeping with the results obtained on a relatively large tissue microarray study associating PD-L1 expression with oestrogen receptor negativity, progesterone receptor negativity, high histological grade, high Ki67 labelling, and high numbers of tumour infiltrating lymphocytes, CK5 expression, and p53 expression [14]. High PD-L1 labelling is relatively common in triple-negative breast carcinomas, and a better prognosis has been associated with lymphocyte predominant breast carcinomas showing high PD-L1 expression [14], which is also in line with the reported case. However, it remains elusive how the presented tumour managed to overcome the PD-L1 – PD1 axis spontaneously because the results quoted in the previous sentence were gained from tumours of patients who received systemic treatment. The potential role of metformin was considered unlikely due to the drug having been taken even before the progressive phase of the regressing carcinoma.

This work was partly supported by the National Research, Development, and Innovation Office grant number: GINOP-2.3.2-15-2016-00020.

The authors declare no conflict of interest.

References

1. Vernon LF. William Bradley Coley, MD, and the phenomenon of spontaneous regression. *Immuno Targets Ther* 2018; 7: 29-34.
2. Challis GB, Stam HJ. The spontaneous regression of cancer: a review of cases from 1900 to 1987. *Acta Oncol* 1990; 29: 545-550.
3. Dussan C, Zubor P, Fernandez M, et al. Spontaneous regression of a breast carcinoma: a case report. *Gynecol Obstet Invest* 2008; 65: 206-211.
4. Maiche AG, Jekunen A, Rissanen P, et al. Sudden tumour regression with enhanced natural killer cell accumulation in a patient with stage IV breast cancer. *Eur J Cancer* 1994; 30A: 1642-1646.

5. Tokunaga E, Okano S, Nakashima Y, et al. Spontaneous regression of breast cancer with axillary lymph node metastasis: a case report and review of literature. *Int J Clin Exp Pathol* 2014; 7: 4371-4380.
6. Maillat L, Chopin N, Treilleux I, et al. Regression spontanée de cancers mammaires après biopsie: à propos de deux cas. *Gynecol Obstet Fertil* 2014; 42: 269-272.
7. Ito E, Nakano S, Otsuka M, et al. Spontaneous breast cancer remission: A case report. *Int J Surg Case Rep* 2016; 25132-25136.
8. Salgado R, Denkert C, Demaria S, et al. The evaluation of tumor-infiltrating lymphocytes (TILs) in breast cancer: recommendations by an International TILs Working Group 2014. *Ann Oncol* 2015; 26: 259-271.
9. Zi F, Zi H, Li Y, et al. Metformin and cancer: An existing drug for cancer prevention and therapy. *Oncol Lett* 2018; 15: 683-690.
10. Nielsen TO, Hsu FD, Jensen K, et al. Immunohistochemical and clinical characterization of the basal-like subtype of invasive breast carcinoma. *Clin Cancer Res* 2004; 10: 5367-5374.
11. Ridolfi RL, Rosen PP, Port A, et al. Medullary carcinoma of the breast: a clinicopathologic study with 10 year follow-up. *Cancer* 1977; 40: 1365-1385.
12. Dong H, Strome SE, Salomao DR, et al. Tumor-associated B7-H1 promotes T-cell apoptosis: a potential mechanism of immune evasion. *Nature Med* 2002; 8: 793-800.
13. Muenst S, Schaerli AR, Gao F, et al. Expression of programmed death ligand 1 (PD-L1) is associated with poor prognosis in human breast cancer. *Breast Cancer Res Treat* 2014; 146: 15-24.
14. Bae SB, Cho HD, Oh MH, et al. Expression of Programmed Death Receptor Ligand 1 with High Tumor-Infiltrating Lymphocytes Is Associated with Better Prognosis in Breast Cancer. *J Breast Cancer* 2016; 19: 242-251.

Address for correspondence

Gábor Cserni
Institute of Pathology
University of Szeged
Állomás u. 1
H6720 Szeged, Hungary
email: cserni@freemail.hu