

Quiz

WHAT IS YOUR DIAGNOSIS?

We report a case of a 43-year old female who underwent total nephrectomy because of a renal tumour.

On macroscopic examination the tumour measured $105 \times 105 \times 90$ mm involving about 4/5 of the kidney volume, with areas of necrosis.

Histologically the tumour consisted of mainly papillary structures (Fig. 1), with few nest and

tubules (Fig. 2), lined by cells with eosinophilic and clear cytoplasm (Fig. 3), accompanied by scattered psammoma bodies (Fig. 1, 2). Moderately polymorphic nuclei were haphazardly distributed within the neoplastic epithelium, with prominent eosinophilic nucleoli (Fig. 4).

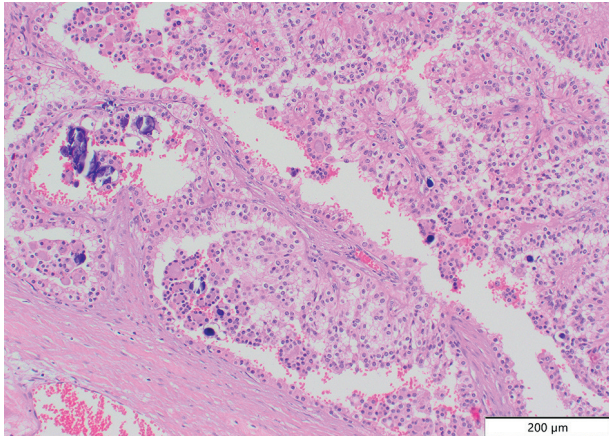


Fig. 1.

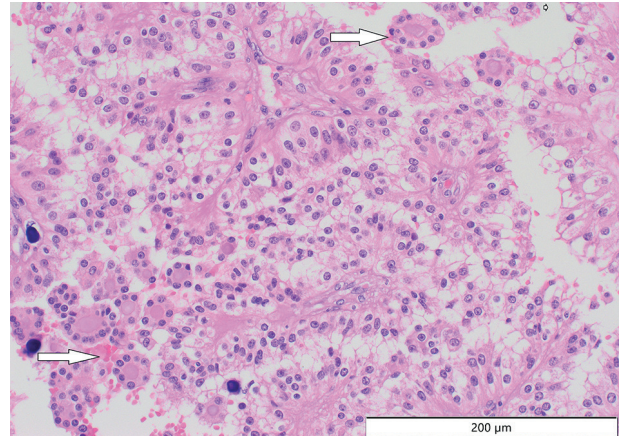


Fig. 2.

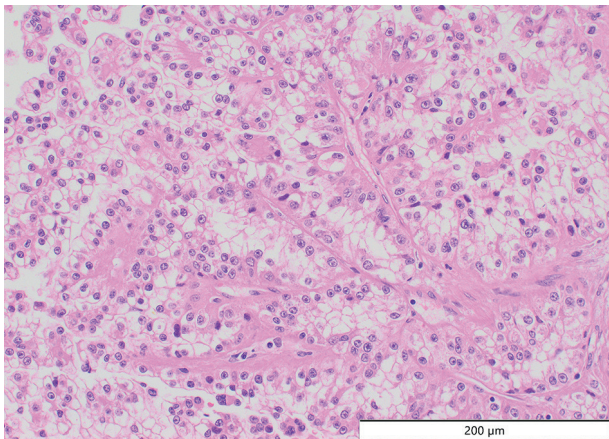


Fig. 3.

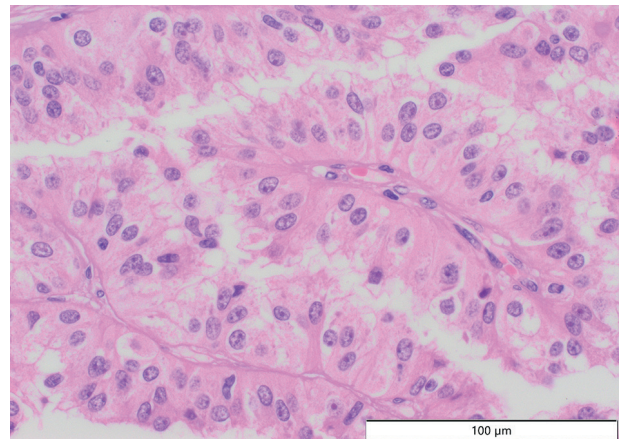


Fig. 4.

Agnieszka Harazin-Lechowska¹, Grzegorz Januś¹, Aleksandra Ambicka¹, Marcin Przewoźnik¹,
Bożena Cybulska-Stopa², Katarzyna Gajewska-Wicher², Janusz Ryś¹

¹Department of Tumour Pathology, Maria Skłodowska-Curie National Research Institute of Oncology, Krakow Branch, Krakow, Poland

²Department of Clinical Oncology, Maria Skłodowska-Curie National Research Institute of Oncology, Krakow Branch, Krakow, Poland

Answers should be sent to the Editorial Office until 15th January 2022. The correct answer will be announced in the next issue of the *Polish Journal of Pathology*.