

CASE REPORT

**ATYPICAL CLINICAL PRESENTATION MIMICKING STROKE
IN AN ADULT PATIENT CAUSED BY A RARE DIFFUSE
LEPTOMENINGEAL GLIONEURONAL TUMOUR**

ANGELIKA STAPIŃSKA-SYNIEC¹, ANNA GOGOL², ALBERT ACEWICZ³, MICHAŁ SOBSTYL¹,
TERESA WIERZBA-BOBROWICZ³, WIESŁAWA GRAJKOWSKA^{3,4}

¹Department of Neurosurgery, Institute of Psychiatry and Neurology, Warsaw, Poland

²Department of Neurology, District Hospital in Wołomin, Wołomin, Poland

³Department of Neuropathology, Institute of Psychiatry and Neurology, Warsaw, Poland

⁴Department of Patomorphology, Center of Postgraduate Medical Education, Warsaw, Poland

A diffuse leptomeningeal glioneuronal tumours (DLGNT) are very rare tumours of the central nervous system, typically characterized by enhancement of subarachnoid space with cystic lesions, diffuse leptomeningeal infiltration, and no primary mass. We report an atypical clinical presentation of DLGNT. A 48-year-old male was admitted to hospital with symptoms of ischaemic stroke. Magnetic resonance imaging of the head revealed contrast enhancement of the meninges and other parts of the brain. A stereotactic frame biopsy was performed on the patient, which revealed the DLGNT. Diffuse leptomeningeal glioneuronal tumours are mostly seen in individuals less than 18 years old and are characterized by slow growth and low-grade histological appearance. Diffuse leptomeningeal glioneuronal tumours can be aggressive in adults.

Key words: diffuse leptomeningeal glioneuronal tumour (DLGNT), disseminated oligodendroglial-like leptomeningeal tumour of childhood.

Introduction

A diffuse leptomeningeal glioneuronal tumour (DLGNT) is a very rare tumour of the central nervous system that appeared for the first time in the 2016 revised 4th edition of the World Health Organization (WHO) classification of nervous system tumours [1]. A diffuse leptomeningeal glioneuronal tumour is assigned to the category of neuronal and mixed neuronal-glial tumours. In the literature, it is also known as a disseminated oligodendroglial-like leptomeningeal tumour of childhood [1]. Typically, DLGNT is characterized by enhancement of subarachnoid space with cystic lesions, diffuse leptomeningeal infiltration by glioneuronal cells with no primary mass, and indolent course [2]. Despite mainly affecting the paediatric population, it can be rarely diagnosed in adults [3].

Herein, we report a non-typical clinical presentation of a case of DLGNT in a 48-year-old male, with a literature review.

Case report

A 48-year-old, non-smoking, Caucasian male with no previous medical history or alcohol abuse was admitted to the emergency unit with speech disturbances and anxiety, which started abruptly on the day of admission. According to his wife, he complained of a headache before the symptoms had appeared. On the physical examination, there were no signs of infection and respiratory or circulation insufficiency. Global aphasia and mild right-side pyramidal paresis of facial muscles and upper limb were observed (NIHSS of 7). The head computed tomography (CT) scan showed

no haemorrhage or other acute pathology. However, in the left parietotemporal region a small slightly hyperdense tumour resembling meningioma was present. Given the significant neurological syndrome suggesting acute stroke with symptoms lasting less than 4.5 hours and no definite contraindications, intravenous thrombolytic treatment was started, resulting in the improvement of speech disturbances.

On the second day after admission, confusion was dominant, which prompted a lumbar puncture. The result of the basic cerebrospinal fluid examination was a slightly elevated cell count of 20 cells per micro-litre (90.0% of lymphocytes), total protein 60.6 mg% (normal range 15–45), glucose 8.58 mmol/l (normal range 2.78–4.44), and lactate 51.5 (normal range 10–22), which led to the immediate introduction of treatment with wide-spectrum antibiotics (ceftriaxone, vancomycin, and ampicillin), acyclovir, and dexamethasone. The patient's condition improved gradually, but anxiety persisted, and the patient left the hospital at his own request interrupting the treatment and before the proper diagnosis was made. A few days later, he reappeared complaining of severe headache.

During his second stay, an extensive investigation was performed including a two-phase magnetic resonance imaging of the head. It revealed improper signal and contrast enhancement of the meninges, midbrain, central parts of the cerebellum as well as left thalamus and the pineal region with a protruding mass into the third ventricle. Also, the subpial space of the cervical spine was infiltrated by the tumour (Fig. 1A–D). All of these findings progressed over time.

Various conditions were taken into account concerning differential diagnosis: infectious disease, parasite infestation, neoplasm, autoimmune encephalitis, and neurosarcoidosis, but no definite diagnosis was possible. All laboratory tests performed with results are presented in Table I. After re-initiation of empirical antibacterial treatment and glucocorticosteroids, the patient's condition improved again, but the result was only temporary, and gradual worsening with stupor and right-side pyramidal symptoms, as well as myoclonic seizures, was observed. Finally, despite persistent disapproval, after comprehensive detailed information about the procedure, the patient agreed to a stereotactic frame biopsy. The neurosurgical procedure was done under general anaesthesia. The procedure was planned based on the stereotactic intraoperative contrast-enhanced head CT. The biopsy was taken from the lesion in the left frontal operculum. The postoperative head CT scan revealed small intraparenchymal bleeding at the biopsy site.

Histopathological examination revealed hypercellular neoplastic infiltration composed of monomorphic, bland oligodendroglial-like cells (Fig. 2A).

The tumour cells were positive for OLIG2 (Fig. 2B) and synaptophysin (Fig. 2C). The glial fibrillary acidic protein expression was restricted to a minor proportion of neoplastic cells (Fig. 2D). The Ki-67 proliferation index was up to 5%. Further molecular testing displayed a lack of 1p/19q codeletion and *IDH1*, *IDH2* mutations. The final diagnosis of DLGNT was established.

With an extremely unfavourable clinical course, the patient died almost 3 months after the first symptoms appeared and one month after the final diagnosis.

Discussion

Diffuse leptomeningeal glioneuronal tumours are mostly seen in individuals less than 18 years old, with a slight predominance in the male population [4]. These tumours are usually characterized by slow growth, and the majority of them have a low-grade histological appearance and low mitotic index; however, they are still not assigned to any WHO grade [1]. Despite mainly affecting the paediatric population with an indolent course, DLGNTs may also be aggressive tumours diagnosed in adults [3]. In most cases, the clinical presentation comprises hydrocephalus due to tumour cell accumulation in subarachnoid space, seizure, or headaches [4]. Diffuse leptomeningeal glioneuronal tumour immunophenotype comprises a deletion of short arms of chromosome 1 (1p deletion) and sometimes also the long arm of chromosome 19 deletion (19q deletion), which corresponds to its other name 'oligodendroglial-like' because 1p/19q codeletion is pathognomonic for oligodendroglioma [5]. In contrast to oligodendrogliomas, DLGNTs are negative with the presence of isocitrate dehydrogenase (IDH) 1 and 2 gene mutations [5]. Characteristic radiological features include thick leptomeningeal enhancement with the presence of subpial cysts, hyperintense in T2 and hypointense in T1, located particularly in temporal lobes, basal parts of frontal lobes, infratentorially, and in the spinal cord [6, 7]. In most cases, no dominant mass is identified [6, 7]. Diffuse leptomeningeal glioneuronal tumours are diagnosed based on the results of the neuropathological examination of the specimens obtained during surgical resection or a frame or open biopsy. Thus, molecular testing (IDH 1/2 mutation, 1p/19q codeletion) is necessary to make a correct diagnosis. Treatment includes surgical resection, radiation, and chemotherapy in different combinations [4, 8, 9]. The average survival time is 22 months [4].

Deng *et al.* studied molecular alterations in DLGNTs [10]. They classified DLGNT into 2 subgroups: DLGNT methylation class 1 (DLGNT-MC-1) with 1p deletion and DLGNT methylation class 2 (DLGNT-MC-2) with 1q duplication [10]. This mo-

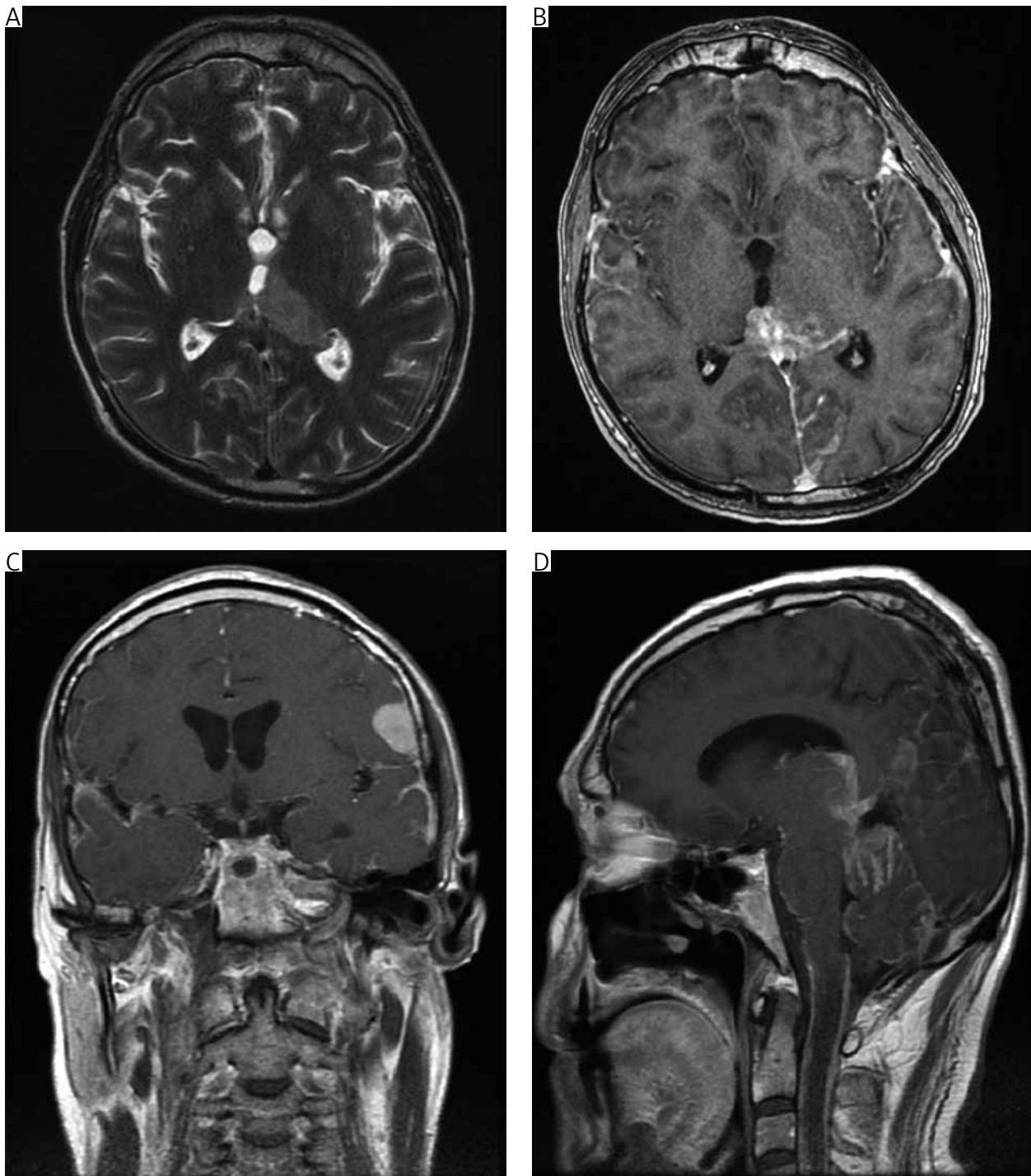


Fig. 1. A) T2-weighted axial image showing the pathological mass located in the pulvinar and left thalamus protruding to the third ventricle occupying the pineal region; B) T1-weighted, contrast-enhanced axial image showing the mass in the pineal region and posterior part of the third ventricle; C) T1-weighted contrast-enhanced coronal image showing the mass in the left operculum and widespread subpial dissemination seen in both hemispheres; D) T1-weighted, contrast-enhanced sagittal image showing widespread involvement by the tumour of the cerebral aqueduct, and the subpial space of the cerebellum and the subpial space of the cervical spine

lecular-based classification corresponds to different clinical features. The DLGNT-MC-1 group is characterized by lower age at diagnosis (5 vs. 14 years in DLGNT-MC-2) and less aggressive clinical course with 5-year overall survival reaching 100% vs. 43%

in DLGNT-MC-2 [10]. Xu *et al.*, based on 19 literature reports comprising 54 cases, divided patients with DLGNT diagnosis into a poor prognosis group and a stable condition group (SG) depending on the clinical course of the disease [11]. The progn-

Table I. List of performed laboratory and microbiology tests

PARAMETERS	MATERIAL	AGENT SUSPECTED	LABORATORY/MICROBIOLOGY TEST
Infectious disease	CSF	Bacterial	CSF culture
		Viral	PCR for HSV I/II
		M. tuberculosis	CSF: QuantiFERON-TB Gold Plus and RT-PCR (<i>M. tuberculosis</i> complex), CSF culture
	Serum	Syphilis	WR
		Mycosis	Aspergillus and cryptococcus antigen
		Parasitic infestation	Anti-Echinococcus and cysticercosis Abs
		HIV/AIDS	Anti-HIV 1/2 Abs
Blood	Bacterial	Blood culture	
Autoimmune encephalitis	Serum		Anti-NMDA, anti-AMPA1, anti-AMPA2, anti-GABA B, anti-LGI1, anti-CASPR2 Abs
Carcinomatous meningitis	CSF – microscopic evaluation		Non-lymphoid neoplasm cells

Abs – antibodies, *CSF* – cerebrospinal fluid, *HSV* – herpes simplex virus, *RT-PCR* – real time polymerase chain reaction, *WR* - Wasserman test

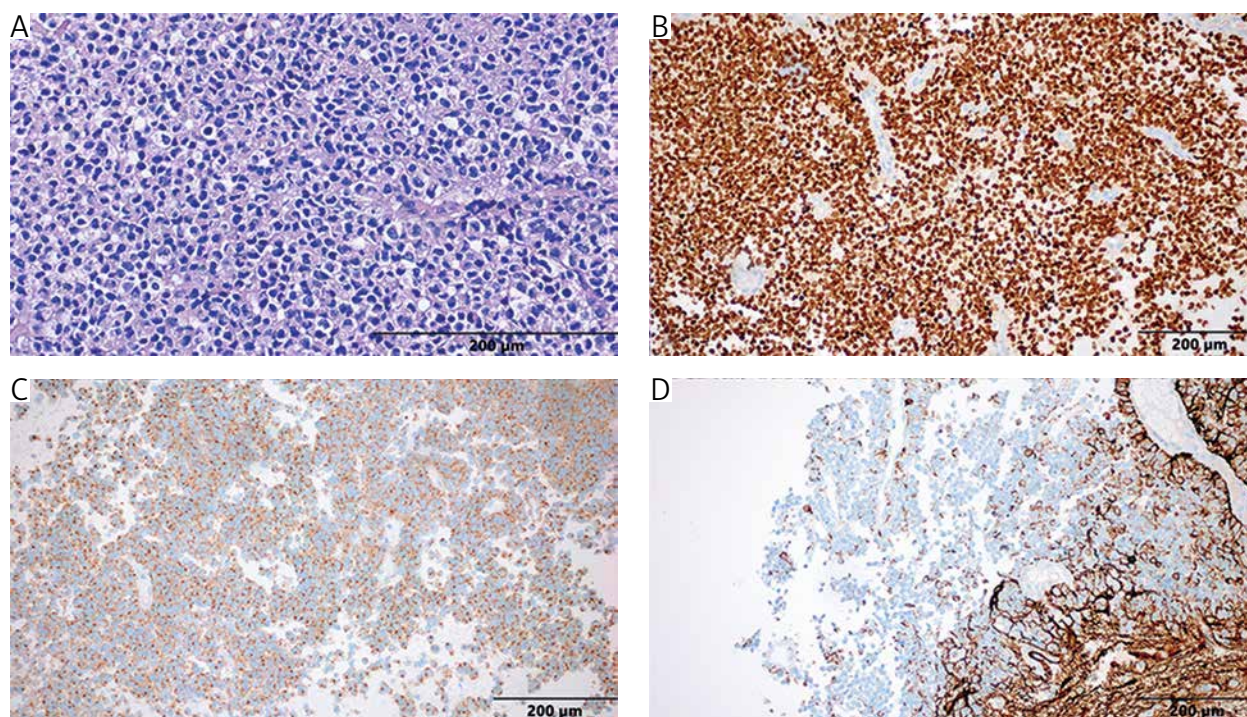


Fig. 2. Histopathological evaluation. A) Haematoxylin and eosin staining revealed hypercellular infiltration composed of monomorphic, bland oligodendroglial-like neoplastic cells with perinuclear halos; B) Immunohistochemical staining showed neoplastic cells positive for OLIG2; C) The tumour cells showed immunopositive reaction for synaptophysin; D) Some of the neoplastic cells revealed immunopositive reaction of glial fibrillary acidic protein

sis group was characterized by higher age at diagnosis and a higher percentage of multiple site lesions and hydrocephalus [11]. The percentage of 1p/19q codeletion was higher in the SG [11].

Because DLGNT is very rare and its clinical presentation may take different forms, the role of molecular genetics is essential for an accurate diagnosis

[12–14]. Moreover, knowledge of DLGNTs is required to avoid misdiagnosis and inadvisable treatment of mimicking diseases such as chronic infectious meningitis [8, 15, 16].

To our knowledge, this is the first described case of DLGNT in an adult patient presented and treated initially as an ischaemic stroke. The final diagnosis

was delayed due to the patient's decision to withdraw from further therapy after transient improvement during the first hospital stay. Even the lumbar puncture did not reveal the presence of tumour cells in the corticospinal fluid. The diagnosis could even be delayed until the performance of stereotactic biopsy of the mass lesion in the left operculum. The described case represents difficult clinical, neuroradiological, and diagnostic challenges in an adult patient affected by a DLGNT tumour. The prognosis was poor, and the patient passed away 3 months after the stroke-mimicking symptoms.

Conclusions

Diffuse leptomeningeal glioneuronal tumours are nervous system tumours that are rarely diagnosed, especially among adults. Their low incidence and various clinical presentations result in a tendency to misdiagnose or delay proper diagnosis. Although being considered as indolent paediatric tumours, DLGNTs also appear in adults with a propensity for aggressive course and poor survival rates.

The authors declare no conflict of interest.

References

1. Wesseling P, Capper D. WHO 2016 classification of gliomas. *Neuropathol Appl Neurobiol* 2018; 44: 139-150.
2. Gardiman MP, Fassin M, Orvieto E, et al. Diffuse leptomeningeal glioneuronal tumors: a new entity? *Brain Pathol* 2010; 20: 361-366.
3. Fiaschi P, Badaloni F, Cagetti B, et al. Disseminated oligodendroglial-like leptomeningeal tumor in the adult: case report and review of the literature. *World Neurosurg* 2018; 114: 53-57.
4. Cho HJ, Myung JK, Kim H, et al. Primary diffuse leptomeningeal glioneuronal tumors. *Brain Tumor Pathol* 2015; 32: 49-55.
5. Louis DN, Perry A, Reifenberger G, et al. The 2016 World Health Organization Classification of Tumors of the Central Nervous System: a summary. *Acta Neuropathol* 2016; 131: 803-820.
6. Ghoniya R, Raheja A. Imaging in diffuse leptomeningeal glioneuronal tumor. *Neurol India* 2019; 67: 615-616.
7. Lakhani DA, Mankad K, Chhabda S, et al. Diffuse leptomeningeal glioneuronal tumor of childhood. *Am J Neuroradiol* 2020; 41: 2155-2159.
8. Tiwari S, Yadav T, Pamnani J, et al. Diffuse leptomeningeal glioneuronal tumor: a unique leptomeningeal tumor entity. *World Neurosurg* 2020; 135: 297-300.
9. Aguilera D, Castellino RC, Janss A, et al. Clinical responses of patients with diffuse leptomeningeal glioneuronal tumors to chemotherapy. *Childs Nerv Syst* 2018; 34:29-334.
10. Deng MY, Sill M, Chiang J, et al. Molecularly defined diffuse leptomeningeal glioneuronal tumor (DLGNT) comprises two subgroups with distinct clinical and genetic features. *Acta Neuropathol* 2018; 136: 239-253.
11. Xu H, Chen F, Zhu H, Luo L, Zhang R. Diffuse leptomeningeal glioneuronal tumor in a Chinese adult: a novel case report and review of literature. *Acta neurologica Belgica* 2020; 120: 247-256.
12. Kang JH, Buckley AF, Nagpal S, Fischbein N, Peters KB. A diffuse leptomeningeal glioneuronal tumor without diffuse leptomeningeal involvement: detailed molecular and clinical characterization. *J Neuropathol Exp Neurol* 2018; 77: 751-756.
13. Tiwari N, Tamrazi B, Robison N, Krieger M, Ji J, Tian D. Unusual radiological and histological presentation of a diffuse leptomeningeal glioneuronal tumor (DLGNT) in a 13-year-old girl. *Childs Nerv Syst* 2019; 35: 1609-1614.
14. Appay R, Pages M, Colin C, Jones DTW, Varlet P, Figarella-Branger D. Diffuse leptomeningeal glioneuronal tumor: a double misnomer? A report of two cases. *Acta Neuropathol Commun* 2020; 8: 95.
15. Karlowee V, Kolakshyapati M, Amatya VJ, et al. Diffuse leptomeningeal glioneuronal tumor (DLGNT) mimicking Whipple's disease: a case report and literature review. *Childs Nerv Syst* 2017; 33: 1411-1414.
16. Lee JK, Ko HC, Choi JG, Lee YS, Son BC. A case of diffuse leptomeningeal glioneuronal tumor misdiagnosed as chronic tuberculous meningitis without brain biopsy. *Case Rep Neurol Med* 2018; 2018: 1391943.

Address for correspondence

Angelika Stapińska-Syniec, MD
 Department of Neurosurgery
 Institute of Psychiatry and Neurology
 9 Sobieskiego St.
 02-957 Warsaw, Poland
 e-mail: angelika.stapinska@gmail.com