

# Coexistence of lichen planus and ulcerative colitis – a case report

Zuzanna Ślebioda, Elżbieta Szponar

Department of Oral Mucosa Diseases, Poznan University of Medical Sciences, Poland  
Head: Elżbieta Szponar MD, PhD

Post Dermatol Alergol 2011; XXVIII, 2: 142–144

## Abstract

The coincidence of a few diseases related to auto-aggression in one patient has already been reported in the current Polish and foreign medical literature. A case of a 36-year-old male who suffered from two diseases of autoimmune origin – lichen planus and ulcerative colitis – is presented in this paper. The diagnosis of oral reticular lichen planus was made based on typical clinical findings in the oral cavity and confirmed in histopathological examination of the buccal mucosa specimen. To exclude candidiasis, culture on *Candida*-selective medium was also performed.

**Key words:** lichen planus, ulcerative colitis, oral lesions.

## Introduction

Both lichen planus and ulcerative colitis belong to the group of diseases related to autoimmune origin [1-6]. In the current Polish and foreign medical literature there have been reported some cases where the coincidence of a few different autoimmune-related conditions was observed in one person [7-10]. The described concurrent diseases include: coeliac disease and ulcerative colitis, autoimmune hepatitis and ulcerative colitis, lichen planus and graft-versus-host disease (GVHD) [6-8].

In this paper a case of a 36-year-old male with two concurrent autoimmune diseases – lichen planus and ulcerative colitis – is presented.

## Case report

Patient aged 36 was admitted to the Department of Oral Mucosa Diseases at Poznan University of Medical Sciences in November 2008 due to bilateral, white, non-removable patches on the buccal mucosa and on lateral tongue surfaces, which he had observed for the first time three months earlier. He had also detected lesions of a similar type on the genital mucosa. The previous diagnosis included suspicion of leukoplakia and chronic hyperplastic candidiasis. The patient did not report any pain,

burning, taste disturbances or dryness in the mouth. He has never smoked tobacco.

Eight months before the oral examination he had been diagnosed with ulcerative colitis. As his general condition was good, based on the results of accessory investigations (e.g. colonoscopy, rectosigmoidoscopy, ultrasound evaluation of the abdominal cavity) his systemic therapy was composed of pharmacological treatment with sulphasalazine and folic acid together with dietary recommendations. The results of his whole blood test and serum iron level from October 2008 were normal. In further blood investigations infections with HBV, HCV and HIV were also excluded.

Previous treatment of the oral lesions included topical antifungal drugs (nystatin, miconazole) and a topical anti-inflammatory agent based on choline salicylate.

In the clinical extra-oral examination no abnormalities were detected. Meanwhile the intra-oral evaluation revealed the presence of white, non-removable patches and plaques located bilaterally on the buccal mucosa and lateral tongue surfaces. The lesions were surrounded by gently marked Wickham striae, which became more evident after performing the Schiller test (Fig. 1). On the dorsal surface of the tongue some white-yellow removable coating was observed (Fig. 2).

Two mucosa specimens from the left and right buccal area were collected for histopathological evaluation. In

---

**Address for correspondence:** Zuzanna Ślebioda, Department of Oral Mucosa Diseases, Poznan University of Medical Sciences, Bukowska 70, 60-812 Poznan, Poland, tel. +48 61 854 70 39, 604 108 546, e-mail: stom.zach@ump.edu.pl, zuzia\_slebioda@o2.pl

microscopic preparation there was observed a diffuse lymphocytic infiltration, which confirmed the clinical diagnosis of lichen planus (Fig. 3).

A smear from the tongue and buccal mucosa followed by culturing the material on *Candida*-selective medium did not confirm candidiasis (negative result of the culture).

As the patient did not report any subjective symptoms related to reticular lichen planus at the time of examination, he received only detailed oral hygiene instructions and he was scheduled for a follow-up visit in 3 months.

## Discussion

The aetiopathogenesis of lichen planus remains not clearly defined, but probably it is related to a disturbed immune reaction characterized by an excessive cell-mediated response. It results in damage of the basal cell layer in the epithelium. In oral lesions of lichen planus the presence of CD4 and CD8 lymphocytes was detected in mucosal *lamina propria*. That suggests a lymphocytic inflammatory reaction to an antigen localized in basal layer keratinocytes [2-4].

The aetiology of ulcerative colitis is also not fully understood. The origin of this condition is multifactorial, but like in lichen planus, immune disturbances seem to play the main role in this process. In ulcerative colitis there is observed excessive activation of Th lymphocytes with a concomitant decreased amount of Ts lymphocytes. This leads to a hyperactive response to the antigens. Moreover, the number of T lymphocytes that produce interleukin 5 increases in mucosal *lamina propria* in this condition [5].

Previous literature reports and our own observations confirm a possibility of the coincidence of some autoimmune diseases in one person. The concurrence of a few conditions related to auto-aggression was described by Kałużny *et al.* [7], who observed ulcerative colitis and coeliac disease in one of the examined patients, while the other presented subject suffered from autoimmune hepatitis and ulcerative colitis. The authors also emphasized the

role of similar immune reaction mechanisms responsible for the development of all the diseases described in their report. Kaniewska and Rydzewska suggested a possibility of coincidence of coeliac disease and other autoimmune disorders, e.g. chronic inflammatory bowel diseases, type I diabetes and primary biliary cirrhosis. According to the authors, introducing a gluten-free diet at the early stage of coeliac disease may prevent the development of other autoimmune conditions in these patients [8]. The coincidence of chronic inflammatory bowel diseases and *pyoderma gangrenosum* was also reported by some authors [10]. According to Wróbel *et al.*, autoimmune disorders that may appear together with lichen planus include graft-versus-host disease (GVHD), primary biliary cirrhosis and type B and C chronic hepatitis [9]. There have also been reports that confirmed the coincidence of lichen planus and chronic inflammatory bowel diseases – a situation also described in our paper. Giomi *et al.* described a case of a 37-year-old female with ulcerative colitis and lichen planus on the genital mucosa with no other skin or

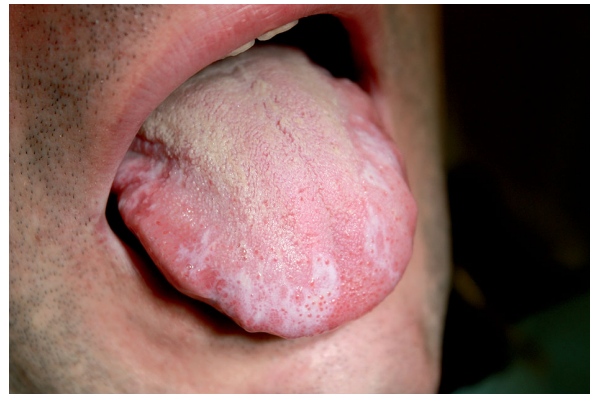

Fig. 2. Reticular lichen planus on the tongue in patient

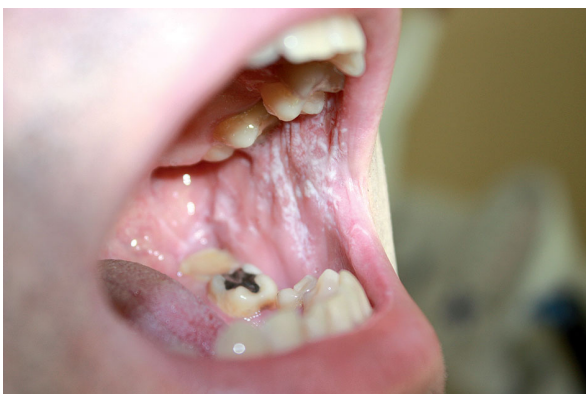

Fig. 1. Reticular lichen planus on buccal mucosa in patient

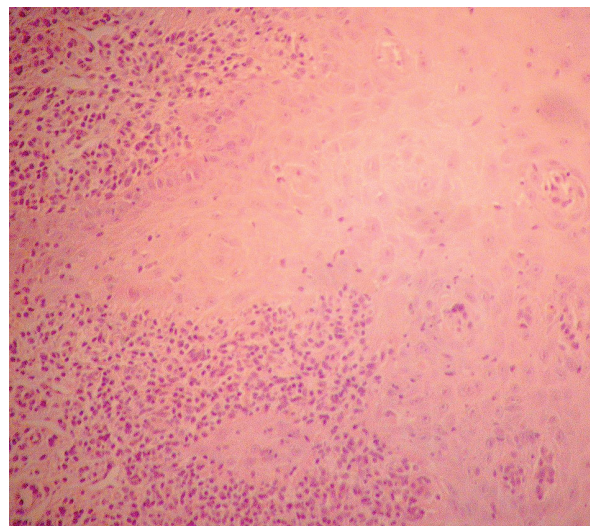


Fig. 3. Diffuse, subepithelial lymphocyte infiltration in reticular lichen planus, patient (H&E stain, 100×)

oral symptoms [11]. Oral lichen planus in a 40-year-old female with ulcerative colitis was observed by Chemli *et al.* [12]. In a preliminary report concerning the oral cavity state in patients with ulcerative colitis Paradowska, who had examined twelve randomly chosen patients with ulcerative colitis, found lichen planus in one case [13]. Serrão *et al.* described a case of cutaneous lichen planus in a 19-year-old female with Crohn's disease [14], while Kano *et al.* observed the concurrence of Crohn's disease, lichen planus and *erythema nodosum* [15].

Lichen planus' exacerbations may be induced by some drugs, e.g. quinidine and a preparation based on arsenic, bismuth and gold compounds [8]. The influence of non-steroidal anti-inflammatory drugs (NSAIDs) on the development of lichen planus-type lesions in the mouth has also been reported [16-18]. Drugs of this type are commonly used by patients with chronic inflammatory bowel diseases. Therefore one may expect to observe lichen planus more frequently in this group of patients in comparison to people who do not require any treatment with NSAIDs. The regression of lichen planus with muco-cutaneous symptoms after the cessation of sulphasalazine and mesalazine in two patients was reported by Alstead *et al.* [17]. Meanwhile Cox *et al.* presented the case of a patient with ulcerative colitis and lichen planus, where the cessation of sulphasalazine did not result in the improvement of oral mucosa and skin condition [19].

Based on the presented literature cases and on our own observations, it seems to be advisable to consider the risk of lichen planus coincidence with some other systemic diseases related to autoimmune origin, e.g. with chronic inflammatory bowel diseases.

## References

- Eisen D. The evaluation of cutaneous, genital, scalp, nail, esophageal and ocular involvement in patients with oral lichen planus. *Oral Surg Oral Med Oral Pathol Oral Radiol Endod* 1999; 88: 431-6.
- Wiernicka M, Mazurek-Mochol M, Turek-Urasińska K. Liszaj płaski u dziecka – opis przypadku. *Dent Med Probl* 2004; 41: 773-7.
- Kurnatowska AJ, Stankiewicz A. Pęcherzowa postać liszaja płaskiego – opis przypadku. *Dent Med Probl* 2004; 41: 779-82.
- Minicucci EM, Weber SA, Stolf HO, Ribeiro DA. Oro-genital lichen planus: report of two cases. *Maturitas* 2008; 59: 201-5.
- Gionchetti P. Etiopathogenesis of inflammatory bowel diseases. *World J Gastrol* 2006; 12: 4807-12.
- DeRossi SS, Salazar G, Sarin J, Alawi F. Chronic lesions of the gingival and mucosa. *JADA* 2007; 138: 1589-92.
- Kałużny Ł, Targońska B, Ignyś I, Krawczyński M. Współistnienie wrzodziejącego zapalenia jelita grubego i innych chorób z autoagresji. Opis dwóch nastoletnich chłopców. *Nowa Pediatria* 2003; 1: 56-7.
- Kaniewska M, Rydzewska G. Choroba trzewna u dorosłych – patogeneza, manifestacje kliniczne, współistnienie z nieswoistymi chorobami zapalnymi jelit i innymi chorobami o podłożu immunologicznym. *Przegl Gastroenterol* 2009; 4: 173-7.
- Wróbel K. Objawy dermatologiczne w chorobach przewodu pokarmowego. *Przew Lek* 2003; 6: 84-92.
- Jankowska-Konsur A, Maj J, Baran E. Piodermia zgorzelinowa: analiza kliniczna 22 przypadków obserwowanych w Klinice Dermatologii Akademii Medycznej we Wrocławiu w latach 2000-2004. *Post Dermatol Alergol* 2006; XXIII: 12-6.
- Giomi B, Pestelli E, Massi D, et al. Vulvar lichen planus associated with ulcerative colitis. A case report. *J Reprod Med* 2003; 48: 209-12.
- Chemli S, Rym D, Jebali A, Hammami W. Association lichen planus and ulcerative colitis. A case report. *Tunis Med* 2006; 84: 65-7.
- Paradowska A. Oral cavity at ulcerative colitis – preliminary study. *Dent Med Probl* 2008; 45: 382-5.
- Kano Y, Shiohara T, Yagita A, Nagashima M. Erythema nodosum, lichen planus and lichen nitidus in Crohn's disease: report of a case and analysis of T cell receptor V gene expression in the cutaneous and intestinal lesions. *Dermatology* 1995; 190: 59-63.
- Serrão VV, Organ V, Pereira L, et al. Annular lichen planus in association with Crohn disease. *Dermatol Online J* 2008; 14: 5.
- Hamburger J, Potts AJ. Non-steroidal anti-inflammatory drugs and oral lichenoid reactions. *Br Med J* 1983; 287: 1258.
- Alstead EM, Wilson AG, Farthing MJ. Lichen planus and mesalazine. *J Clin Gastroenterol* 1991; 13: 335-7.
- Makins R, Ballinger A. Gastrointestinal side effects of drugs. *Export Opin Drug Saf* 2003; 2: 421-9.
- Cox NH, Finlay AY, Watkinson G. Atypical lichen planus associated with ulcerative colitis. *Dermatologica* 1986; 173: 294-6.