

Solid facial oedema of acne: a case report

Marta Pastuszka, Aleksandra Kaszuba, Andrzej Kaszuba

Department of Dermatology, Paediatric Dermatology and Dermatological Oncology, Medical University of Lodz, Poland
Head: Prof. Andrzej Kaszuba MD, PhD

Post Dermatol Alergol 2011; XXVIII, 5: 402–405

Abstract

Solid facial oedema is a rarely described skin condition, which occurs as a complication of acne vulgaris. Its aetiopathogenesis has not yet been definitively clarified. However, it seems that the key role is played by chronic inflammation that can cause obstruction of lymphatic vessels, cellulitis, fibrosis and oedema. Inherited factors should also be kept in mind. In the course of the illness, painless swelling of the forehead, upper eyelids, nasolabial folds and nasal saddle is observed. In the treatment the best results are obtained with isotretinoin alone (at a dose of 0.1-0.3 mg/kg) or in a combination with an antagonist of histamine type 1 receptors – ketotifen (1 mg 2 times a day). Presentation of a 26-year-old male patient with solid facial oedema of acne, in whom complete remission was obtained after oral isotretinoin and ketotifen. The patient was admitted to the hospital because of (persistent for about 1 year) erythema and oedema of the forehead, upper eyelids and nasal saddle. Prior treatment (antibiotics, corticosteroids, calcineurin inhibitors) did not achieve clinical improvement. Detailed anamnesis revealed that the patient had been previously treated for acne vulgaris (of moderate intensity), using topical preparations with benzoyl peroxide and antibiotics and oral antibiotics (lymecycline). This treatment was completed about 6 months before the appearance of swelling. The patient was administered oral isotretinoin and ketotifen, giving complete clinical remission. Based on earlier reports and the course of therapy in the presented patient, it can be concluded that oral isotretinoin in a combination with antagonist of histamine type 1 receptors is effective in treatment of patients with this disease.

Key words: acne vulgaris, solid facial oedema, isotretinoin.

Introduction

Solid facial oedema (Morbihan's disease) is a rarely described skin condition, which occurs as a complication of acne vulgaris [1]. There is no correlation between the degree of severity of acne and the severity of solid swelling of the face. The literature describes cases of very severe oedema in patients with mild acne and mild swelling in the course of severe forms of acne vulgaris [2]. The majority of the patients described so far experienced solid facial oedema at least one year after the first appearance of acne lesions. Only in one patient did the development of the disease occur after the complete resolution of acne vulgaris [3]. Inherited factors should also be kept in mind.

The aetiopathogenesis of solid facial oedema has not been fully elucidated. However, it seems that the key role is played by chronic inflammation that can cause obstruction of lymphatic vessels, limited inflammation of the subcutaneous tissue (cellulites), fibrosis (induced by mast

cells) and oedema [4]. The presence of large amounts of mast cells in infiltration, observed in the reticular layer of the dermis in patients with this disease, was first pointed out by Jungfer, who thought that these cells play a key role in the pathogenesis of disease [5]. Tosti, in turn, hypothesized that genetic factors play an important role in the development of solid facial oedema (he described the occurrence of solid facial oedema in twins) [6].

The disease is manifested by the presence of (sometimes severe) painless swelling, which may involve the entire face. However, the oedema is usually limited to the skin of the forehead, upper eyelids, cheeks, nasolabial folds, or nasal saddle, changing the appearance of the patient [7]. Sometimes it is hard to see; the swelling can be seen only by comparing the current appearance of the patient with old photos. Pitting on pressure is absent. Patients generally do not report symptoms (especially skin changes may be accompanied by photophobia, or tearing). In most cases erythema or scaling are not observed. Results of laboratory tests are usually normal [8].

Address for correspondence: Marta Pastuszka MD, Department of Dermatology, Paediatric Dermatology and Dermatological Oncology, Medical University of Lodz, 1/5 Kniaziewiczza, 91-347 Lodz, Poland, e-mail: marta14-09@o2.pl

Presentation of a 26-year-old patient with a solid swelling of the face, hospitalized in the Clinic of Dermatology, Paediatric Dermatology, and Oncology in Lodz, in whom complete remission was achieved after oral administration of ketotifen and isotretinoin.

Case report

The patient, aged 26, was admitted to the Clinic of Dermatology, Paediatric Dermatology and Oncology, Medical University of Lodz in April 2010 because of 1-year swelling of the face. He was under the care of the Dermatological Outpatient Clinic until the time of the hospitalization, where he was treated (without any effects) with corticosteroids (administered topically, orally and parenterally), antihistamines (1st, 2nd and 3rd generation), antibiotics (including macrolides and amoxicillin with clavulanic acid), and calcineurin inhibitors. The patient reported no symptoms. He did not take any drugs and did not undergo any operation. Facial swelling was not associated with any specific factors (in this example: medications, infections, or exposure to sunlight). Family history was irrelevant.

On admission to hospital the patient had erythema and swelling of the forehead, upper eyelids and nasal bridge (Fig. 1 A-B). Pitting on pressure was absent. Some single open and closed comedones and papules were seen on the skin of the nose and cheeks. The patient was in very

good overall condition, with no fever. There was no deviation in laboratory tests. A detailed history concerning medical conditions revealed that the patient was previously treated for acne vulgaris (of medium intensity) using topical antibiotics, benzoyl peroxide and oral antibiotics (lymecycline). However, this treatment was completed about 6 months before the appearance of the oedema.

The diagnosis – solid facial oedema – was based on the data from the patient's history and the clinical picture. The patient was administered the following treatment: isotretinoin at a dose of 0.5 mg/kg/day (40 mg/day) and ketotifen (1 mg twice a day). The patient was discharged for further treatment in an outpatient setting. A slight improvement was observed after 1 month of the therapy. After another 2 months a significant improvement was seen (Fig. 2 A-B). Due to variations in laboratory tests (cholesterol – 263 mg/dl, triglycerides – 328 mg/dl), the dosage of isotretinoin was reduced to 30 mg/day. Subsequent monitoring of laboratory tests, performed after 1 month of taking isotretinoin at a dose of 30 mg/day, were within normal limits. At the same time, remission of lesions was observed (Fig. 3 A-B). However, the patient was recommended further continuation of the treatment (he was treated for 9 months). The laboratory tests showed no deviations from the normal limits after completion of the treatment, and to date no recurrence of the swelling of the face has been observed.

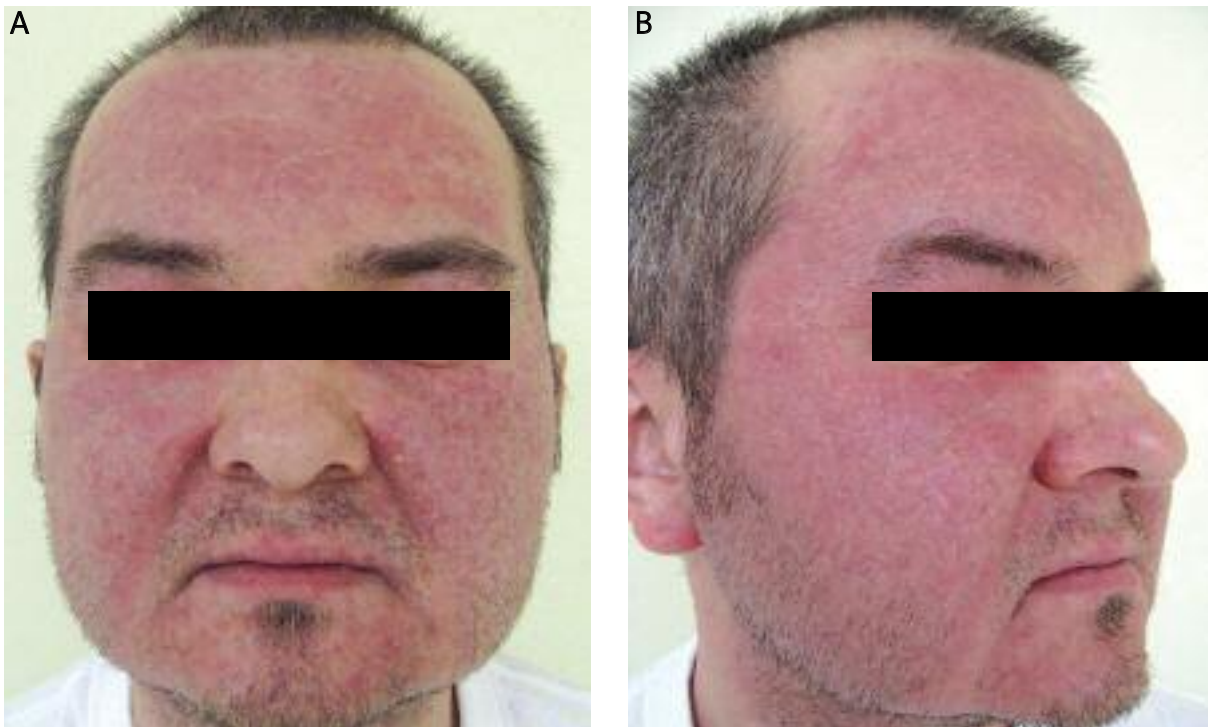


Fig. 1 A-B. Solid facial oedema – patient before treatment

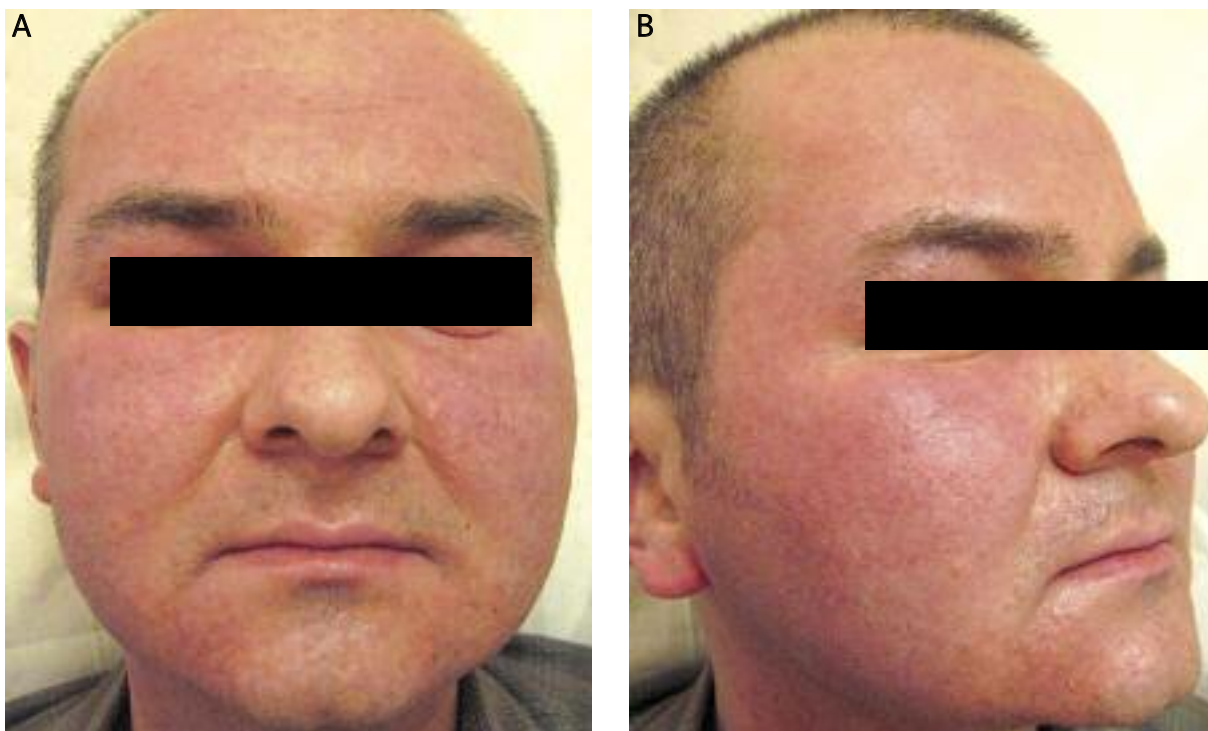


Fig. 2 A-B. Solid facial oedema – patient after 3 months therapy

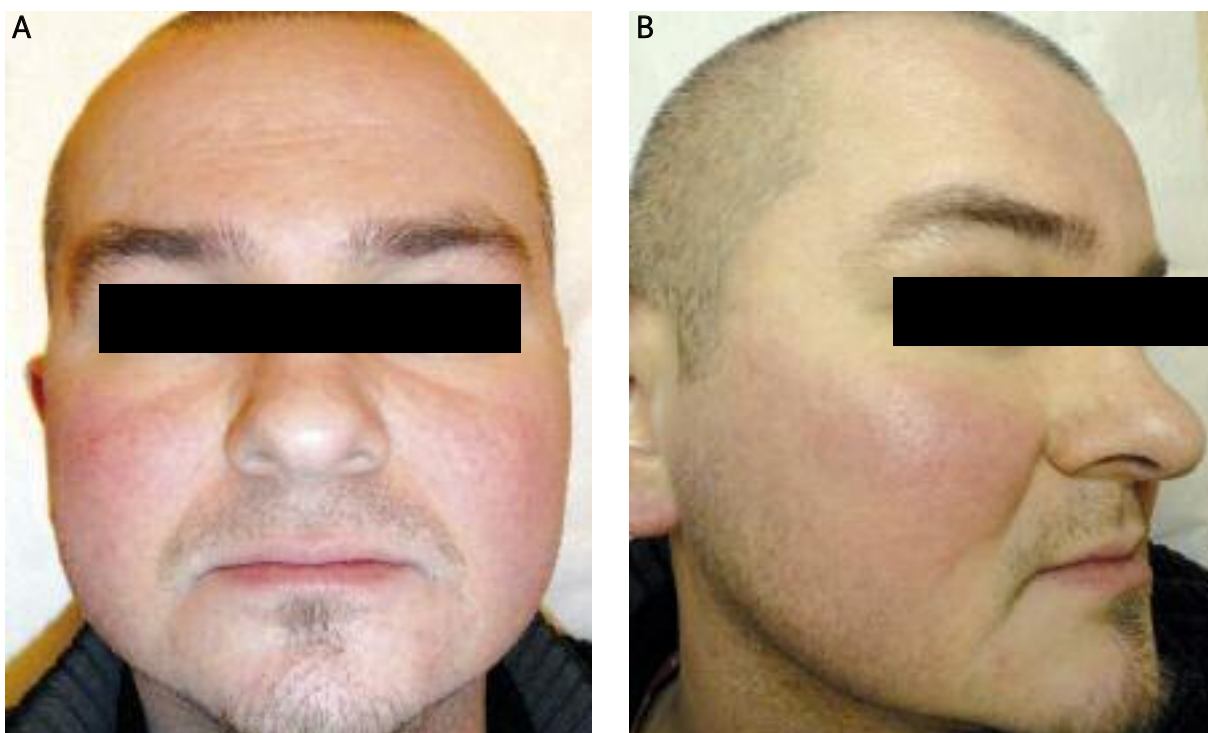


Fig. 3 A-B. Solid facial oedema – patient after treatment

Discussion

Cases of solid facial oedema are described casuistically, slightly more often in men than in women [9]. The first description of this disease comes from 1918 [10]. It considered the role of staphylococcal infections in the pathogenesis of the disorder. In the literature, the disease has been described under various synonyms: recurrent erysipelas (Hutchinson), erysipelas persistans faciei (Kaposi), erytema persistans faciei (Kreibush), lymphangitis faciei (MacKenzie) or persistent lymphatic oedema [11]. In 1985 Conelly and Winkelmann pointed out the relationship between the occurrence of solid swelling of the face and acne [12]. They hypothesized that chronic inflammation, accompanying acne changes, can lead to chronic inflammation that can cause obstruction of lymphatic vessels, limited inflammation of the subcutaneous tissue (cellulitis), fibrosis (induced by mast cells) and progressive oedema. Friedman *et al.* drew attention to the lack of correlation between the severity of acne lesions and the severity of swelling of the face. However, the aetiopathogenesis of this disease is still not fully explained [13].

The histopathological study concludes massive subcutaneous fibrosis with the presence of numerous mast cells, especially around blood vessels [14]. Jungfer *et al.* first pointed out the role of mast cells in the pathogenesis of disease.

The differential diagnosis of solid facial oedema takes into account the following conditions: Melkersson-Rosenthal syndrome (granulomas in a biopsy), elephantiasis nostrans, which is a persistent oedema after recurrent cases of erysipelas (swelling is then usually one-sided, with alternating exacerbations and remissions), and swelling of the face in the course of rosacea [15].

The treatment of solid facial oedema is often unsatisfactory. Orally administered antibiotics and corticosteroids, as well as X-ray irradiation, laser treatment or surgery, usually produce no or only minimal clinical improvement [16]. The best therapeutic results are usually obtained after administration of isotretinoin alone (at a dose of 0.1-0.3 mg/kg) or in combination with a histamine receptor antagonist type 1 – ketotifen (1 mg twice daily) [17].

Isotretinoin was first recommended in the treatment of solid facial oedema by Friedman (1.0 mg/kg over a period of 5 months) with a partial clinical improvement. Helander and Aho treated a 20-year-old patient with solid facial oedema with isotretinoin (1.0 mg/kg) in combination with clofazimine (they also achieved significant remission) [18]. However, the best therapeutic results were obtained by Jungfer in 1993 in a 20-year-old patient, who was administered isotretinoin (0.5 mg/kg for 4 months) in combination with ketotifen [19]. It should be emphasized that the beneficial effects of synthetic derivatives of vitamin A in patients with solid facial oedema are prob-

ably due to its anti-inflammatory effects (e.g. inhibition of mast cell migration) [20].

References

1. Connelly MG, Winkelmann RK. Solid facial edema as a complication of acne vulgaris. *Arch Dermatol* 1985; 121: 87-90.
2. Friedman SJ, Fox BJ, Albert HL. Solid facial edema as a complication of acne vulgaris: treatment with isotretinoin. *J Am Acad Dermatol* 1986; 15: 286-9.
3. Kilinc I, Gencoglan G, Inanir I, Dereli T. Solid facial edema of acne: failure of treatment with isotretinoin. *Eur J Dermatol* 2003; 13: 503-4.
4. Carney JW. Solid edema of face. *Arch Dermatol* 1966; 94: 664-6.
5. Jungfer B, Jansen T, Przybilla B, Plewig G. Solid persistent facial edema of acne: successful treatment with isotretinoin and ketotifen. *Dermatology* 1993; 187: 34-7.
6. Tosti A, Guerra L, Bettoli V, Bonelli U. Solid facial edema as a complication of acne vulgaris in twins. *J Am Acad Dermatol* 1987; 17: 843-4.
7. Patel AB, Harting MS, Hsu S. Solid face edema: treatment failure with oral isotretinoin monotherapy and combination oral isotretinoin and oral steroid therapy. *Dermatol Online J* 2008; 14: 14.
8. Humbert P, Delaporte E, Drobacheff C, et al. Solid facial edema associated with acne. Therapeutic efficacy of isotretinoin. *Ann Dermatol Venerol* 1990; 117: 527-32.
9. Braun-Falco O, Plewig G, Wolff H, Burgdorf W. *Dermatologia*. Wydawnictwo Czelej, Lublin 2004; 1008.
10. Weidler WB. Solid edema of the face: report of three cases. *Trans Am Ophthalmol Soc* 1918; 16: 48-54.
11. Mahajan PM. Solid facial edema as a complication of acne vulgaris. *Cutis* 1998; 61: 215-6.
12. Dragan LR, Baron JM, Stern S, Shaw JC. Solid facial edema preceding a diagnosis of retro-orbital B-cell lymphoma. *J Am Acad Dermatol* 2000; 42: 872-4.
13. Jansen T, Regele D, Schirren CG, et al. Persistent erythema and edema of the face associated with rosacea and lymph vessel dysplasia. *Hautarzt* 1998; 49: 932-5.
14. Uhara H, Kawachi S, Saida T. Solid facial edema in a patient with rosacea. *J Dermatol* 2000; 27: 214-6.
15. Nagasaka T, Koyama T, Matsumura K, Chen KR. Persistent lymphoedema in Morbihan disease: formation of perilymphatic epithelioid cell granulomas as a possible pathogenesis. *Clin Exp Dermatol* 2008; 33: 764-7.
16. Mendez-Fernandez MA. Surgical treatment of solid facial edema: when everything else fails. *Ann Plast Surg* 1997; 39: 620-3.
17. Camacho-Martinez F, Winkelmann RK. Solid facial edema as a manifestation of acne. *J Am Acad Dermatol* 1987; 17: 843-4.
18. Helander I, Aho HJ. Solid facial edema as a complication of acne vulgaris: treatment with isotretinoin and clofazimine. *Acta Derm Venerol* 1987; 67: 535-7.
19. Manolache L, Benea V, Petrescu-Seceleanu D. A case of solid facial oedema successfully treated with isotretinoin. *J EADV* 2009; 23: 965-6.
20. Hölzle E, Jansen T, Plewig G. Morbihan disease: chronic persistent erythema and edema of the face. *Hautarzt* 1995; 46: 796-8.