

# Chromoblastomycosis

Paweł M. Krzyściak<sup>1</sup>, Małgorzata Pindycka-Piaszczyńska<sup>2</sup>, Michał Piaszczyński<sup>3</sup>

<sup>1</sup>Department of Mycology, Chair of Microbiology, Jagiellonian University Medical College, Krakow, Poland  
Head of Department: Paweł M. Krzyściak MD, PhD

<sup>2</sup>Chair and Clinical Department of Internal Diseases, Dermatology and Allergology in Zabrze, Medical University of Silesia, Katowice, Poland

Head of Department: Prof. Jerzy Jarzab MD, PhD

<sup>3</sup>Department of General, Vascular and Transplant Surgery, Medical University of Silesia, Katowice, Poland  
Head of Department: Prof. Lech Cierpka MD, PhD

Postep Derm Alergol 2014; XXXI, 5: 310–321

DOI: 10.5114/pdia.2014.40949

## Abstract

Chromoblastomycosis is a chronic fungal infection of the skin and subcutaneous tissue. The infection usually results from a traumatic injury and inoculation of microorganism from a specific group of dematiaceous fungi (usually *Fonsecaea pedrosoi*, *Phialophora verrucosa*, *Cladophialophora carrionii*). In the tissues fungi produce characteristic sclerotic cells or muriform cells. Dermal lesions can range from small nodules to large papillary-like eruptions. The disease has been described worldwide but the prevalence is higher in rural populations in countries with a tropical or subtropical climate, such as Madagascar in Africa and Brazil in South America. Diagnostic techniques are based on direct examination, culture and histopathology. Despite a variety of treatment modalities, which include long courses of antifungals, surgical excision and destructive physical therapies, the disease remains one of the most difficult deep mycotic infections to eradicate.

**Key words:** diagnosis, epidemiology, *Fonsecaea pedrosoi*, mycoses, treatment.

## Definition and history of research

Chromoblastomycosis (CBM) is defined as a chronic cutaneous and subcutaneous fungal infection resulting from traumatic implantation of certain dematiaceous fungi through the skin. The aetiological agents gain entrance through transcutaneous puncture wounds, usually by parts of plants. The definition of CBM is occasionally narrowed to the disease caused by fungus of the *Chaetothyriales* order [1]. In a typical manifestation the dermal lesions form cauliflower-like nodules. In the infected tissue, characteristic dark-coloured, thick-walled, muriform cells i.e. sclerotic cells (Medlar bodies) are observed (Figure 1), which is a histopathological criterion for the diagnosis [1–4].

The disease was initially considered to be closely related to blastomycosis, which is a different type of a fungal infection caused by dimorphic fungi of the *Blastomyces dermatitis* sp. It is reflected in the name of the disease, which suggests it is a fungal infection caused by pigmented *Blastomyces* fungus (Greek *chroma*, ~atos = complexion, skin colour, + *Blastomyces* Greek *blastós* = sprout, bud + *mykes* = fungus + *osis* Greek suffix denot-

ing the state of something/somebody). However, the diseases are differentiated by the type of the fungal cells in the host tissue. In CBM, cell division of the fungi, which infect the tissue occurs as a result of producing septa i.e. meristematically (Greek *meristos* = divided) and not by budding, which is present in the yeast phase of *Blastomyces* [2].

The term CBM is semantically closely related to phaeohyphomycosis, a fungal infection also caused by dematiaceous fungi, however production of Medlar bodies (sclerotic cells) in the tissues does not occur.

For many years various names have been proposed for this disease entity, some of which are presented in Table 1. Eventually in 1992, the International Society for Human and Animal Mycology (ISHAM) decided that the term *Chromoblastomycosis* was the proper one [5]. Currently the disease is defined in the International Classification of Diseases (ICD) as follows: ICD-9 no 117.2, ICD 10-B43.

In 1911, Alexandre Pedroso in Sao Paulo, Brazil, studied the cases with nodular and ulcerous dermal lesions on the foot and on the shin. He named the disease

---

**Address for correspondence:** Paweł Krzyściak, 18 Czysza St, 31-121 Krakow, Poland, e-mail: pawel.krzyosciak@uj.edu.pl

**Received:** 29.10.2013, **accepted:** 19.01.2014.

*blastomycose negra*. However, Pedroso and Jose Maria Gomes published their observations as late as in 1920 [6]. In the meantime in 1914, Max Rudolph, a German physician living in Brazil, described six cases of the disease which he named figueira (fig tree). Moreover, he was able to isolate dematiaceous fungi from 4 cases, which he recognised as belonging to the variety of *Blastomycetes*. He managed to infect white rats and monkeys with the fungi. The descriptions of the disease and the mycological discoveries reported by Rudolph indicate that it was the same fungus that had been discovered by Pedroso a few years earlier [7, 8].

A year later, in 1915, Medlar [9] and Lane [10] published in the USA a case of a patient from Boston who suffered from a disease caused by an unknown type of a fungus. They found lesions to be blastomycetic. The lesions included a number of spherical, pigmented, parasitic cells (Medlar bodies). The fungus was carefully studied and was given the name *Phialophora verrucosa*.

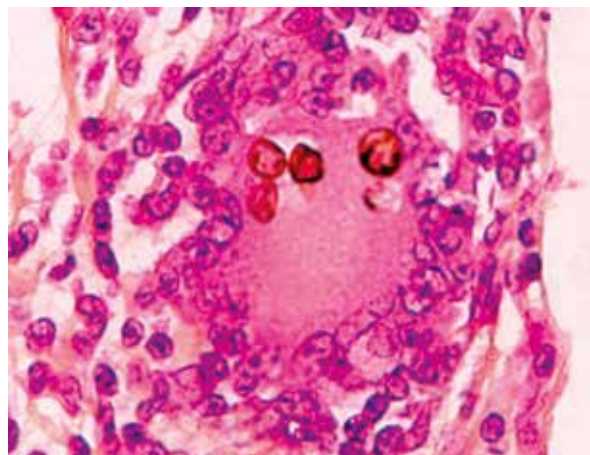
In 1922, Brumpt [11] demonstrated that it was not *Phialophora verrucosa* which caused the infection in the case described by Pedroso, but a different fungus which he named *Hormodendrum pedrosoi*. In 1923, Fonseca and Leao described a different method of sporulation for this fungus, which linked it with the *Acrotheca* genus (species re-classification to the *Acrotheca pedrosoi* genus). In 1922, Terra *et al.* used the term “*Chromoblastomycosis*” for the first time [12 cited by 13].

In 1935, another method of sporulation was discovered in *Acrotheca (Hormodendrum) pedrosoi*. In this method spores were created in phialides, which related the fungus to the *Phialophora* genus described by Medlar (name *Phialophora pedrosoi* was suggested). Three different types of conidiation in the same organism resulted in many misleading descriptions of the fungus using various names related to species and genus. Some most significant synonymous names are presented in the Table 1.

In 1935, Carrion in Puerto Rico described the third aetiological agent of CBM – *Hormodendrum compacta*. Puerto Rican fungus had all three methods of sporulation characteristic of *Hormodendrum*, but also demonstrated individual features so that it could be recognised as a different species. In 1936, Pablo Negróni proposed a generic name *Fonsecaea*, which was accepted as correct. It has been used until now.

In the 1950s, another fungal species was added to the aetiological agents of CBM, namely *Cladosporium* (currently *Cladophialophora*) *carrionii*, first described by Trejos in 1954. It solved the problem of describing an increasing number of species classified in the *Cladosporium* genus, which were responsible for CBM cases [14].

Studies on similarity and aetiological agents of CBM are still continued. In 2004, scientists from the University of Chiba in Japan found that there is no difference in subunit ribosomal DNA D1/D2 domain sequence between *F. pedrosoi* and *F. compacta*, which may indicate that the



**Figure 1.** Sclerotic cells (Medlar bodies) inside Langhans giant cell obtained histopathologically – skin biopsy specimen

**Table 1.** Synonymous names of aetiological agents of chromoblastomycosis

**Synonyms of *Fonsecaea pedrosoi* (Brumpt) Negróni 1936**

*Hormodendrum pedrosoi* Brumpt 1922

*Acrotheca pedrosoi* (Brumpt) Fonseca & Leão 1923

*Trichosporum pedrosianum* (Brumpt) M. Ota 1927

*Trichosporum pedrosoi* (Brumpt) Brumpt 1927

*Gomphinarina pedrosoi* (Brumpt) C.W. Dodge 1935

*Hormodendroides pedrosoi* (Brumpt) M. Moore & F.P. Almeida 1936

*Phialophora pedrosoi* (Brumpt) Redaelli & Cif. 1941

*Carrionia pedrosoi* (Brumpt) Bric.-Irag. 1942

*Rhinochadiella pedrosoi* (Brumpt) Schol-Schwarz 1968

**Synonyms\* of *Fonsecaea compacta* (Carrion) Carrion 1940**

*Hormodendrum compactum* Carrion 1935

*Phialoconidiophora compacta* (Carrion) M. Moore & F.P. Almeida 1936

*Phialophora compacta* (Carrion) Redaelli & Cif. 1942

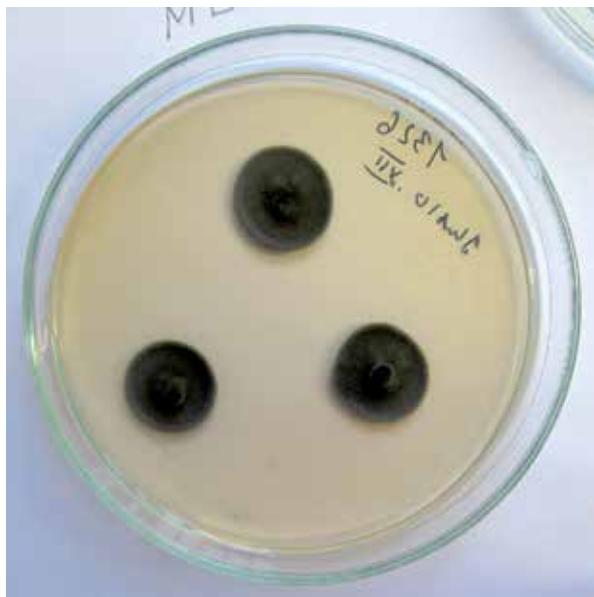*Rhinochadiella compacta* (Carrion) Schol-Schwarz 1968

**Synonyms of *Cladophialophora carrionii* (Trejos) de Hoog, Kwon-Chung & McGinnis 1995**

*Cladosporium carrionii* Trejos 1954

*Although the term F. compacta has synonymous names, it is already a synonym of F. pedrosoi.*

latter is merely a morphological variation of the first [15]. In the same year, Sybren de Hoog *et al.* re-classified the *Botryoides monophora* sp. It was deposited in the culture collection CBS 269.37 to the new *Fonseca* genus. And thus, a new species was created i.e. *Fonsecaea monophora*, morphologi-



**Figure 2.** Conidiophores of *F. pedrosoi* – Cotton Blue Lactophenol staining

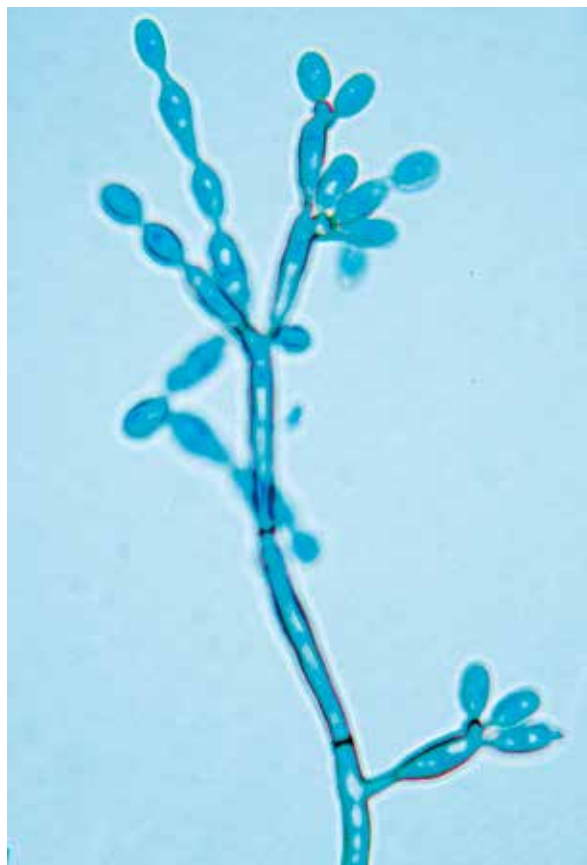cally very similar to *F. pedrosoi*. Currently, standard diagnosis does not differentiate between these species narrowing the diagnosis to the *F. pedrosoi/monophora* complex [16].

### Aetiological agents

The most frequent aetiological agents of CBM are the following species: *Fonsecaea pedrosoi* (Figures 2 and 3), *Phialophora verrucosa* and *Cladophialophora carrionii*. *Rhinoctadiella aquaspersa* [17, 18] and *Exophiala dermatitidis* are less frequently reported. It has also been observed that *Exophiala jeanselmei* [19–21] and *E. spinifera* [22–25], normally responsible for the development of phaeohyphomycosis, produce muriform cells in typical lesions of CBM. In recent years other species that may be the agents of CBM have been described: *Fonsecaea monophora* [26, 27], *Fonsecaea nubica* [28] and *Phialophora richardsiae* [29].

All the species listed above belong to the *Herpotrichiellaceae* family of the *Chaetothyriales* order within the phylum of sac fungi (*Ascomycota*). Members of this family are related to teleomorphic form of *Capronia* sp. The teleomorphic form is isolated mainly from wood and *Basidiomycota*, whereas parasitic forms occur in an anamorphic form (asexual reproduction). These fungi frequently grow meristematically (this type of growth may be observed in Medlar bodies in the tissue of mammals infected with CBM and in plant tissues) and in a yeast-like form. Furthermore, due to melanin production, the fungi are characterised by dematiaceous mycelium, therefore, this type of microorganisms is defined in English-language literature as *black yeast* or *black yeast-like fungi* [30].

In the literature, cases of CBM caused by dematiaceous fungi of different families and orders can be found. These

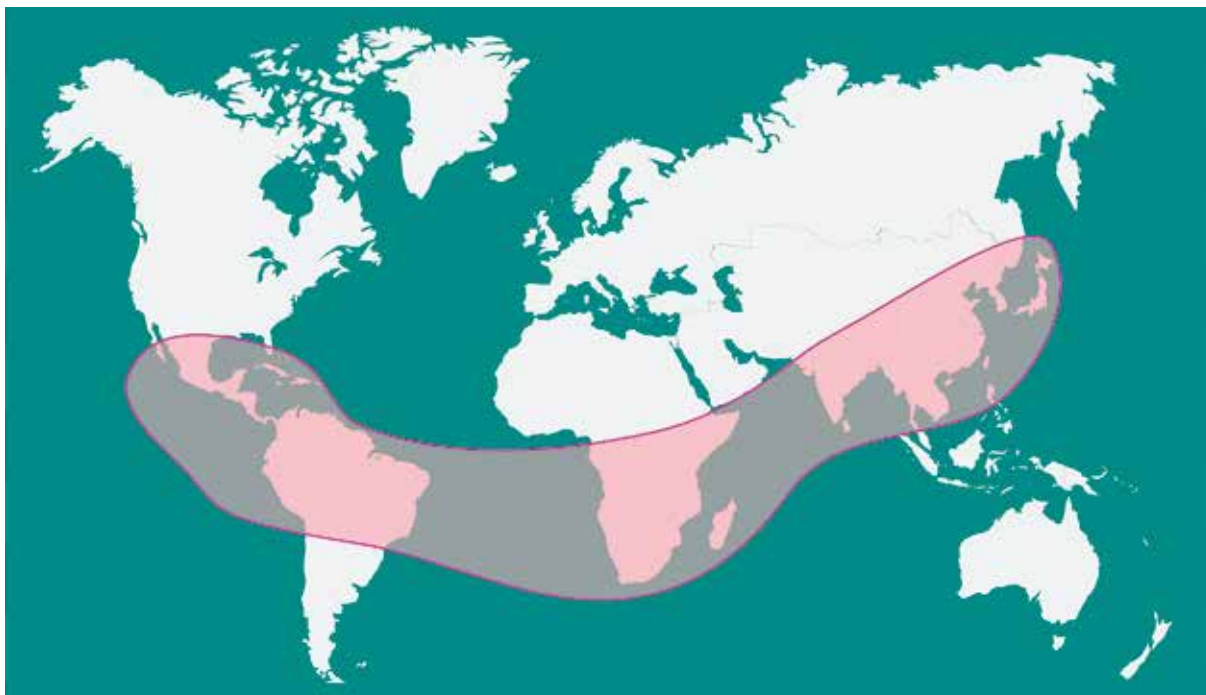


**Figure 3.** *Fonsecaea pedrosoi* colony on SGA medium after 14 days of incubation

infections affect mainly individuals with the impaired immune system [31]. In the casuistic literature well-documented cases of fungal infections are reported. These are *Aureobasidium pullulans* in a patient after liver transplant [32] and *Rhytidhysterion* sp. in a patient following kidney transplant in India [33]. There are also poorly documented cases of CBM caused by different dematiaceous fungi. It is a case of a dermal lesion on the palm caused by *Chaetomium funicola* in a healthy elderly patient in Panama [34], however without definitely recognised muriform cells in the tissue, which could be spores or fragments of hyphae of the fungus [35]. Furthermore, in the Centraalbureau voor Schimmelcultures (CBS) Fungal Biodiversity Centre collection, a strain of *Catenulostroma chromoblastomycosum* is deposited with the information that it is the case of CBM from Zaire [36] (currently Democratic Republic of the Congo). However, no reliable clinical description exists whether the biopsy was done and whether the characteristic features of CBM were identified [35].

### Geographical distribution

The disease is prevalent in the world. However, most cases are reported in humid tropical and subtropical



**Figure 4.** Geographical distribution of chromoblastomycosis based on CDC [65], and the PubMed Base review

climate areas of America, Asia and Africa. The highest prevalence rates are reported in Mexico (Oaxaca and Veracruz) [37], Cuba [38], Venezuela [39], the Dominican Republic, Colombia [40] and Brazil (mainly in the region of Amazonia) [13, 41, 42] (Figure 4).

The first case of CBM outside American continents was reported in the Pasteur Institute in Algiers in 1927 [43]. In Africa most cases were reported in Madagascar (1955–1994, 1323 cases) [44] and in the South Africa.

In Asia CBM is most frequently reported in Japan [45], Sri Lanka [46] and India [47]. Furthermore, the disease is fairly common in China, especially in Shandong and Henan provinces. The first case was reported in 1952. Since that time over 500 cases from 20 provinces have been reported [48]. In Japan about 10 cases of CBM are reported annually. The occurrence rate of individual species in the last two decades of the 20<sup>th</sup> century was as follows: *F. pedrosoi* – 71%, *E. jeanselmei* – 20%, *Phialophora verrucosa* – 4.5%, *Exophiala dermatitidis* – 2% [49].

Not many cases have been reported in Australia. They are mostly caused by *Cladophialophora carrionii* [50, 51].

In a temperate climate, e.g. in Europe, CBM is rare and is rather a non-indigenous disease. In 1928, in Leningrad, Tschernjawski identified CBM in a Polish woman who most likely developed the infection falling off a horse near Vilnius. It was presumably the first described case of CBM in Europe. The isolated fungus was classified into *Hormodendrum rossicum* sp., which later became synonymous with *F. pedrosoi* [52]. In 1938, 14 cases of CBM were reported in Russia. However, all of

them occurred in an Asian region of the country [53]. In Europe, indigenous cases of CBM were reported in Finland [54]. Furthermore, in former Czechoslovakia [55–57] and in Germany [58], cases of the disease were also reported. In the United Kingdom, the first described cases were related to immigrants from Jamaica and Ceylon [53].

The first case of CBM in Poland was reported in 1972 in *Przegląd Dermatologiczny* [59]. Up to now 4 documented cases of this disease in Poland have been known [60].

Currently, studies on the relationship between geographical distribution of fungal species/varieties responsible for CBM and the forms of infections are conducted. Differences in the species which are the agents of CBM have been observed, depending on the region. *F. pedrosoi* is related to humid areas of a tropical and subtropical climate, whereas *C. carrionii* is dominant in a semi-arid climate [37, 39, 42, 50, 61]. It is particularly visible in Madagascar where in the tropical rainforest area in the north of the island, *F. pedrosoi* is prevalent, whereas in the south of the island with the “thorny desert” climate, *Cladophialophora carrionii* is more common [44, 62]. In the north of China, *C. carrionii* and in the south *F. monophora* are prevalent [48].

Based on the internal transcribed spacer regions (ITS) of fungal DNA analysis, the *Fonsecaea* genus was divided into three groups; group A – *F. pedrosoi*, group B – *F. monophora* and group C – different species of the *Fonsecaea* genus [31]. Further studies of Yaguchi *et al.* [63] and Xi *et al.* [48] resulted in a division of the *F. pedrosoi* group into subgroups, i.e. A1 and A2 and the *F. monophora* group into subgroups, i.e. B1, B2 and B3. It was found that individual subgroups

occur in different parts of the world. It may be significant due to the relation of aetiological agents and geographical distribution with the form of CBM. *Fonsecaea pedrosoi* appears to be a pathogen closely related to CBM only, whereas *F. monophora* is an opportunistic pathogen with diverse clinical spectrum [16].

It was found that within the *Fonsecaea* genus the A1 subgroup occurs in Thailand, Australia, South America, Africa, South and East China; the A2 subgroup in Central and South America; the B1 subgroup in Central and South America, and South China; the B2 subgroup in Central America, Japan and East China. Finally, the B3 subgroup occurs in the USA, the United Kingdom and South China [48–63].

In the study on South Korean isolates, a high differentiation was observed – strains of *F. pedrosoi* similar to the strains reported in South and East China, two groups of *F. monophora* similar to the strains from South and East China and Japan. Additionally, a strain identical to the one in Costa Rica was identified and a strain similar to the Thai strains was isolated from an immigrant (which meant that the infection had developed earlier in Thailand) [64]. Figure 3 shows a high prevalence of CBM.

## Epidemiology and ecology

### Sources of infection

The discovery of natural habitats of the fungi and the source of fungal parasitic infection for humans is crucial for understanding the development of pathogenicity in those organisms [65]. Fungi responsible for CBM are found in the environment in the world and are part of the microbiota, which decomposes organic matter in soil and water. They also appear on the plants [41, 66]. Conant was the first to isolate *Phialophora verrucosa* from soil in 1937, thus proving saprophytic nature of these fungi. In Japan, *P. verrucosa* ( $n = 17$ ) and *F. pedrosoi* ( $n = 1$ ) were isolated, mainly from rotting wood. Most of saprophytic strains were able to induce the infection in experimental animals [67].

*Fonsecaea pedrosoi* was isolated from the thorns of *Mimosa pudica* in the spot indicated by the patient with CBM where the infection probably occurred. However, *F. pedrosoi* was not isolated from the thorns of the plant in different locations, which suggests the “reservoir-type” of infection [66]. Rubin *et al.* described a well-documented incident of an injury caused by a branch of the tree. *F. pedrosoi* was isolated from both the plant and the lesion [68].

Gezuele *et al.* reported a relatively high proportion (approx. 20%) of *Phialophora verrucosa* and *Fonsecaea pedrosoi* isolates in 328 samples of plant remains, soil and different materials, employing the method of mice inoculation and direct breeding. Out of 64 samples of dead parts of the trees and palm trunks, 32 contained one or both of the above fungal species. From 11% of soil samples that most frequently contained plant remains, pathogenic species were isolated. Scientists indicate the

contrast between isolation of aetiological agents of CBM from the environment and a relatively rare occurrence of CBM in Uruguay [69].

Vicente *et al.* studied the appearance of the black yeast in the place of residence of patients with clinical symptoms of CBM in Parana, Brazil. They found that strains isolated from the environment differ from common aetiological agents of CBM. The black yeast belonged to the same order, but constituted separate unknown species. They did not manage to isolate *Fonsecaea pedrosoi* from 56 studied locations [70].

### Characteristics of population affected by chromoblastomycosis

In tropical and subtropical countries, the infection is more prevalent in males 30–50 years of age engaged in agriculture (approximately 70% of cases) [37, 46]. For instance, in Madagascar, 87% of patients with CBM are males above 16 years of age [62]. Minotto *et al.* observed the 4 : 1 male-to-female incidence ratio in Brazil. Moreover, the disease is most prevalent in farmers (aged 50–60) [13]. It is explained by a more frequent engagement of males in agricultural activities in those countries, which increases the possibility of injury with parts of plants affected by fungi responsible for CBM [66].

The inhibitory action of female sex hormones on fungal development is also postulated. A genetic susceptibility to the infection is also possible [71]. Interaction between the host and the infecting fungus is still being analysed. Tsuneto *et al.* found that individuals with HLA-A29 antigen are more susceptible to infection. They demonstrated that in patients with CBM this antigen is 10 times more frequent compared to the controls. No difference in susceptibility to CBM in relation to the race was observed [72].

In Japan, the male-to-female incidence ratio is nearly equal (1 : 0.8) [49]. Most frequently CBM occurs at 50 to 80 years of age and affects mainly upper limbs, buttocks and lower limbs in males and upper limbs, neck, face and lower limbs in females [49].

No predilection of fungi for specific host tissues was found. The disease mostly affects lower limbs, especially feet which are most frequently exposed to contact with the infected material e.g. soil, plants or rotting wood [62, 66]. Palms, arms and buttocks are also frequently infected. Lesions on ears, cornea, neck, face, breast, chest and stomach are occasionally described [13, 73–75].

## Pathomorphology and pathophysiology of chromoblastomycosis

### Pathomorphology

Tissue response to CBM is nonspecific and may be similar to the response in deep mycoses. Major changes observed in the area of the epidermis and keratinised

epidermis are *hyperkeratosis* and *pseudoepitheliomatous hyperplasia*. Few microulcerations with mycosis may be found [76]. Typical muriform cells (Medlar bodies) are usually observed in the epidermis, however they may change into filamentous forms, especially in the scabs covering lesions [77]. Muriform cells may divide and multiply by forming septa (septation). However, they never bud, which distinguishes them from the forms found in blastomycosis [2].

In the cutaneous and subcutaneous tissues, nonspecific, diffuse infiltrations are observed (Figure 4).

### Immunology of infection

It is still unknown which form of the fungus (hyphae, spores or sclerotic bodies) is the invasive form [78]. On the surface of the thorns of *Mimosa pudica*, the presence of hyphae and spores of *F. pedrosoi* was detected. However, sclerotic bodies, similar to those observed in the tissues of patients were found inside the thorns [66]. Preparing a special medium, which induces the production of sclerotic bodies enabled to conduct studies with various forms of mycelium [79].

Neutrophils and macrophages are crucial cells in the immunological response in CBM. A typical reaction of granulation, regulated by polymorphonuclear neutrophils is observed in patients [76]. The first line of defence are dendritic cells. Dermal macrophages were shown to present fungal antigens in their cytoplasm. Similar properties were found in dermal dendrocytes and in Langerhans cells [80]. In patients with CBM those cells show an increased expression of CD 86, HLA-DR and CD 83 receptors. In response to spores, dendritic cells produce TNF- $\alpha$ , IL-10 and IL-12. After *F. pedrosoi* antigen stimulation, in patients with a severe form of CBM, dendritic cells produce large amounts of IL-10 and small amounts of IFN- $\gamma$  [81].

CD4+ and CD8+ T lymphocyte populations, B lymphocytes and macrophages play a significant role in cell-mediated response [80]. Infecting thymus-deprived mice resulted in the development of the lesions characteristic of CBM, whereas in mice deprived of NK cells and macrophages and in healthy mice, the lesions recovered 4–6 weeks after the infection [82]. A large number of sclerotic cells were found in the lesions. Delayed hypersensitivity and antibodies against *F. pedrosoi* antigens were detected. Lymphocytes influence the immune response in CBM, which was confirmed by the fact that lymphocyte transfer from healthy mice resulted in full recovery within 2 months [82]. Further studies showed that immunisation of mice with *F. pedrosoi* alive spores results in a massive inflow of CD4+ lymphocytes into lymph glands. Activated T lymphocytes demonstrate *in vitro* proliferation after another stimulation with a specific antigen and produce IFN- $\gamma$ . Furthermore, the absence of CD4+ lymphocytes in mice results in more severe changes, delayed hypersensitivity and the production of lower amounts of

IFN- $\gamma$  in CBM compared with wild strains. The absence of CD8+ lymphocytes does not affect the above parameters [83]. A similar situation is observed in humans where in patients with severe forms of the disease, large amounts of IL-10 are produced, a low level of IFN- $\gamma$  is found and isolated lymphocytes cannot proliferate. In mild cases of the disease, small amounts of IL-10 are found, a high level of IFN- $\gamma$  and increased lymphocyte proliferation are also observed [84]. Studies indicate a crucial role of CD4+ T lymphocytes which produce IFN- $\gamma$  as an immune defence against *F. pedrosoi* [83, 84].

Hayakawa *et al.* found that the presence of aetiological agents of CBM decreases the expression of MHC-II and CD8 receptors on macrophages, as well as nitric oxide secretion by these receptors [85]. By using a specially prepared medium, da Silva *et al.* proved that these were spores, not sclerotic cells, that are responsible for the impairment of the maturation of Langerhans cells, which was expressed by a decreased expression of CD40 and B7-2 receptors on their surface [86].

Langerhans cells are capable of phagocytising one, rarely two *F. pedrosoi* spores, while dermal macrophages are capable of internalising 4–5 spores. Langerhans cells do not phagocytise sclerotic bodies, although they may be adjoined to them [86]. The ability of phagocytising by macrophages depends on a species of a fungus responsible for the infection of CBM and also on the presence of complement proteins. *F. pedrosoi* and *Rhinocladiella aquaspersa* are phagocytised more frequently compared to *P. verrucosa* and *C. carrionii*. Complement-dependent phagocytosis occurs particularly in the case of *P. verrucosa* and *R. aquaspersa* [85]. Phagocytosis of the fungal cells is not related to their death. Little or lack of cytotoxic effect was demonstrated against *F. pedrosoi*, *C. carrionii* and *P. verrucosa* [85]. On the other hand, Langerhans cells prevent the growth of hyphae from both sclerotic cells and spores, regardless of the presence of phagocytosis [79]. Bocca *et al.* reported that melanin present in *F. pedrosoi* cells inhibits the production of nitric oxide by macrophages [87].

In the studies on the causes of development of chronic CBM, Sousa *et al.* found that C-type lectin receptor Mincle and Dectin-2 receptor are the major receptors related to the innate identification of *F. pedrosoi* [88]. It was demonstrated that the absence of inflammatory reaction to *F. pedrosoi* infection is caused by the absence of innate immune response, and not by an immunosuppressive action of the fungus. The absence of response stimulation is caused by the absence of co-stimulation of the Toll-like receptor (TLR) pathway. Administration of the combination of *F. pedrosoi* spores and bacterial lipopolysaccharide triggers a strong inflammatory response. These antigens alone poorly stimulate TNF secretion, thereby it appears that administration of TLR agonists may serve as the therapy of CBM, also after their topical administration [88].

Scientists emphasise that the host defence mechanism against CBM has not been fully understood yet. The role of humoral response in controlling the disease still remains unknown. In serum of patients with CBM antimicrobial antibodies are detected. However, in healthy individuals who live in endemic regions and are in constant exposure to aetiological agents of CBM a specific humoral response is also present. The response, however, does not correlate in any way with the development of CBM. The time of seroconversion may be long, even as long as a year following the end of the therapy.

### Clinical symptoms

The aetiological agent (i.e. fungal fragment) gains entrance through transcutaneous puncture wounds [68]. A primary lesion is represented by an erythematous papule or a warty growth, which gradually enlarges from the site of infection assuming various forms and sizes. The infection may occur anywhere on the body, however most frequently it affects limbs, especially feet and shins [37, 46]. Cases of buttock, trunk and face infection have also been reported [17, 37, 74, 89, 90]. In more advanced stages of the disease dissemination may occur in the form of satellite lesions which arise from scratching autoinoculation and spread via the lymphatic system [49]. Clinical changes progress slowly and frequently the period from infection to diagnosis is 10 years.

The disease can present clinically in 5 different forms: nodular, tumoral lesions, verrucous, plaque and cicatricial [1, 91].

**Nodular type** contains the youngest and the smallest elements of the clinical picture of CBM. This type includes fairly soft, moderately raised, pale pink or purple nodules. The surface may be smooth, papillary or scaly. In further development of the lesions many nodules gradually transform into bigger tumoral lesions.

**Tumoral type** is represented by much bigger and more protruding, papillomatous, occasionally lobulated, tumour-like masses, partially or completely covered with dirty-grey epidermal remains, scabs and keratosis. On the feet and lower parts of the shin where the disease tends to be the most disseminated, tumoral masses frequently become huge in size and have a characteristic cauliflower-like appearance.

**Verrucous type** is characterised by hyperkeratosis; lesions are verrucous in appearance and may resemble common warts (*verruca vulgaris*). Wart growth is frequently noted along the edges of feet.

**Plaque type** is the least frequent form of CBM. It includes plano-convex lesions of various shapes and sizes, reddish to violet in colour and scaly on the surface.

**Cicatricial type** – these are the lesions on the skin level which develop by the peripheral growth with atrophic scarring, while in the centre of the lesion, the healing process occurs. Typically, the lesions are annular,

arched or creeping within the lesion. They tend to cover substantial areas of the body.

Apart from the division presented above, the lesions in CBM may be classified according to their severity. Three levels are distinguished: 1) a mild form – single scales or nodules < 5 cm in diameter; 2) a moderate form – single or multiple lesions of tumoral, verrucous or plaque type isolated or conjoined, covering one or two adjacent body areas < 15 cm in diameter; and 3) a severe form includes any type of single or multiple lesions covering extensive skin areas, both neighbouring and distant. Severe lesions tend to poorly respond to treatment or become treatment-resistant.

Castro and de Andrade [3] by modifying the method of Restrepo *et al.* [92] assume an algorithm to determine the severity of the infection on the point scale: mild form (up to 3 points), moderate/intermediate form (4–6 points), severe form (7 and more points). Points are calculated according to 4 criteria, i.e. the assessment of size, number of lesions, presence of complications and response to prior treatment. Pruritus (75%) and pain (55%) are reported with the co-existence of both in most cases [37].

### Complications

Secondary infections and ulcerations are frequent CBM complications. Bonifaz *et al.* reported secondary bacterial infections in over 60% of patients [37]. In severe cases, lymphoedema [47, 93] and ankylosis occur. Foot and shin swelling leads to elephantiasis. Carcinogenesis, which is an infrequent serious complication of chronic CBM, results in the development of squamous cell carcinoma [94–97].

Invasive infections as a result of CBM are extremely rare. Nonetheless, *F. pedrosoi* was reported in brain abscesses both in immune deficient patients and in immunocompetent individuals [98–102]. It appears that a more frequent aetiological agent of disseminated infections is *F. monophora*, a species morphologically identical with *F. pedrosoi* [16].

### Differentiation

Lesions in CBM are polymorphic and should be differentiated from the lesions related to various medical conditions. To confirm the diagnosis, the presence of muriform cells (Medlar bodies) and the identification of an aetiological agent in the microbiological culture are necessary [1]. Many infectious diseases may present similar symptoms to the ones found in CBM. These are fungal infections (including paracoccidioidomycosis, blastomycosis, coccidioidomycosis, phaeoophomycosis, sporotrichosis, granulomatous candidiasis, trichophytosis); bacterial infections (cutaneous tuberculosis, leprosy, tertiary syphilis, nocardiosis, ecthyma); mycobacterioses (caused by *Mycobacterium marinum*, *M. fortuitum*); par-

asitic infections (leishmaniasis and rhinosporidiosis). Chromoblastomycosis should also be differentiated from non-infectious diseases such as planoepithelial carcinoma, psoriasis, sarcoidosis or lupus erythematosus [1, 3].

### Laboratory diagnosis

Technically, diagnosis of CBM does not pose a great difficulty, however the average time between the occurrence of the disease and the diagnosis was 14 years, as reported by Minotto *et al.* [13]. Standard diagnosis is based on the presence of Medlar bodies in the potassium hydroxide-cleared specimen obtained from skin scrapings or histopathologically.

### Culture techniques

Microbiological culture is essential to determine an aetiological agent. For cultures, parts of the biopsy sample are used for growth in Sabouraud-agar (SGA) and Sabouraud-agar supplemented with cycloheximide. Fungi, which are the aetiological agents of CBM grow slowly on the standard media and form black colonies. Macroscopic assessment of the colony and slide culture technique are employed in identification to assess microscope micro-morphology and types of sporulation. Molecular biology techniques are useful and essential to differentiate some species. According to some definitions of CBM, an isolated fungus must belong to the *Chaetothyriales* order [1] (cf. a chapter on aetiological agents). Therefore, the correct identification of the species is essential for the correct diagnosis.

### Direct examination

The specimen is obtained from skin scrapings from the lesion. Sclerotic bodies are easily observed in potassium hydroxide-cleared specimens with dimethyl sulfoxide. Typical golden-brown sclerotic cells (Medlar bodies) and other elements of the mycelium are the objective of examination.

### Histopathology

Biopsy is performed to confirm the diagnosis. In most cases, *tuberculoid-type granulomas* are reported, consisting of lymphohistiocytic infiltration, epithelial cells and Langhans multinucleated giant cells (Langhans giant cell is a large cell formed by the fusion of epithelioid cells (macrophages activated as a result of a continuous activity of cytokines in delayed hypersensitivity), characteristic of many granulomatous conditions.) Sclerotic bodies are found in the stratum corneum and the following layers of the epidermis and the skin. Sclerotic bodies may also be found in the granulomatous processes and in the giant cells. Special staining is not necessary to observe the

lesions as they are easily observed in haematoxylin-eosin stained tissues [37].

### Different techniques

Imaging techniques and serology are not typically employed in the diagnosis. In molecular diagnosis, duplex PCR of ribosomal DNA for *Fonsecaea* spp. [103] and a special oligonucleotide primer for *C. carrionii* identification are used [104].

### Treatment

The disease is related to a low cure ratio and high relapse ratio, especially in chronic and extensive infections. The choice of the treatment and the success of the therapy depend on the aetiological agent, size, extent and location of the lesion. The presence of complications is a significant factor affecting the treatment. Skin fibrosis and oedema decrease drug bioavailability in the tissue [105, 106]. In patients with early and small lesions, the aim of treatment is a complete cure. However, in the case of extensive lesions even long-term treatment may not be successful and may only result in reduction and control of the disease to prevent complications.

Bonifaz *et al.* analysed 51 cases of CBM and reported a cure in 31% of patients, improvement in 57% and treatment failure in 12% of patients. The most common method was cryosurgery for small lesions, itraconazole treatment for extensive lesions and the combination of both methods [37].

Clinical cure is defined as a complete resolution of the lesions, typically with the remaining sclerotic scar. Mycological cure is defined as the absence of the fungus in microscopic specimens and the absence of growth in cultures [105].

Three treatment methods of CBM can be distinguished: antifungal chemotherapy, physicochemical methods and the combination of both.

### Antifungal chemotherapy

**Itraconazole.** In the treatment of CBM, daily doses of 200 mg or 400 mg of itraconazole are administered, depending on the severity of the infection [107]. Mild and moderate forms (Castro and de Andrade [3]) may be successfully cured after 6–12 months [92, 106, 108]. Severe forms tend to show a significant improvement after several months of the therapy, however long-term cure is rarely observed. After the termination of the therapy, relapses are frequently noted [26], presumably because itraconazole is not an antifungal but fungistatic agent.

Itraconazole has been successfully employed in the pulse therapy (400 mg/day for a week, every month). This therapy reduces the amount of the drug and, consequently, the cost of the therapy. However, it is question-



able whether this mode of dosage produces resistance to the drug [109, 110].

In the literature, there are isolated reports on the use of itraconazole in conjunction with cryosurgical methods, 5-fluorocytosine or amphotericin B.

**Terbinafine.** Terbinafine demonstrates an antifungal activity *in vitro* against aetiological agents of CBM. Esterre *et al.* proved that the drug has an antifibrotic action in the treatment of CBM [40]. The recommended daily dose is 500–1000 mg [107, 111]. Efficacy of lower doses (250 mg/day) is also reported [112]. Due to the mechanism of action of terbinafine, the risk of side effects in long-term therapy is minimal.

**Posaconazole.** The recommended dose is 800 mg/day. Treatment is characterised by good efficacy and tolerance. However, it is related to very high costs of the therapy [107, 113].

**5-fluorocytosine (5-FC).** By the 1980s, 5-fluorocytosine had been a drug of choice in CBM. However, inconsistent results were noted in both mono- and combined therapy [114]. The recommended dose was 100–150 mg/kg/day in four doses for 6–12 months. Moreover, a 10% solution of the drug could be administered topically in the form of an occlusive dressing. *F. pedrosoi* may develop resistance to 5-fluorocytosine *in vitro*.

## Physical methods

**Surgical excision of the lesion in CBM,** although performed, is not recommended. It is believed that surgical manipulation in the area of the lesion may favour the dissemination of the disease. Therefore, it should be performed only in selected cases [3].

Primary limited lesions are usually treated surgically. Cryotherapy is performed, frequently conjoined with itraconazole therapy. Malagasy doctors use cautery in conjunction with terbinafine therapy.

**Cryosurgery.** Cryosurgical methods involving liquid nitrogen in the treatment of CBM were first employed in 1973 in Mexico, by Manuel Medina-Ramirez [115]. In 1989, a study was published on treatment assessment of a greater number of CBM patients. The time of cryotherapy ranges from 30 s to 4 min, depending on the authors. Also cycles vary, from a single procedure to over forty procedures. In the case of localised lesions, in 5 patients, treatment response was very good without the presence of relapses within four and a half years after the procedure [34].

Chromoblastomycosis was successfully treated with cryotherapy combined with itraconazole therapy [111, 116]. It is unknown how the cure is achieved. The fungi are eliminated from lesions as late as 1–2 weeks after the therapy, which excludes the possibility of a direct influence of the cold on fungal cells and indicates the immune mechanism [117, 118].

**Thermotherapy.** The literature, mainly of Japanese authors from the late 1970s and the early 1980s, provides

reports on the local treatment with “pocket warmers” placed on the lesion 24 h/day for a couple of months [119–122].

The mechanism of action relies on fungal intolerance to high temperature. Limited availability of pocket warmers in tropical countries where CBM is prevalent limits the therapy to developed countries with a temperate climate [3].

Thermotherapy was employed in conjunction with antifungal chemotherapy: itraconazole, terbinafine and 5-fluorocytosine [123, 124].

**Laser vaporisation.** Laser vaporisation is a highly promising method which is an alternative method of CBM treatment. A combination of laser vaporisation and thermotherapy has been reported to successfully eradicate CBM lesions in patients with relapses of the disease [125, 126]. This approach was employed as the only method for the removal of buttock lesions in Germany [127].

## Drug sensitivity test

As yet there have been no standardised methods to assess sensitivity of dimorphic and filamentous fungi to drugs *in vitro*. *In vitro* drug-resistance assessment can only prove microbiological resistance of the microorganism, but it cannot be employed to predict a clinical response [106].

There were reports on drug resistance to itraconazole by *F. pedrosoi* spp. isolated from patients on long-term itraconazole treatment [128].

## Summary

Although CBM has been known for 100 years, it still remains an unresolved clinical problem. Relapses are frequently reported. Also, many issues regarding aetiological agents, their appearance in the environment, geographical distribution and pathogenicity need to be addressed. Host genetic susceptibility to the disease and the immune system response mechanism should be considered.

## References

1. Queiroz-Telles F, Esterre P, Perez-Blanco M, et al. Chromoblastomycosis: an overview of clinical manifestations, diagnosis and treatment. *Med Mycol* 2009; 47: 3-15.
2. Ajello L. The gamut of human infections caused by dematiaceous fungi. *Jpn J Med Mycol* 1981; 22: 1-5.
3. Castro LGM, de Andrade TS. Chromoblastomycosis: still a therapeutic challenge. *Expert Review of Dermatology* 2010; 5: 433-44.
4. Schwartz R, Baran E. Chromoblastomycosis e-medicine from WebMD, 2010. Available at: <http://emedicine.medscape.com/article/1092695-overview>.
5. Odds FC, Arai T, Disalvo AF, et al. Nomenclature of fungal diseases: a report and recommendations from a sub-com-

- mittee of the international society for human and animal mycology (isham). *J Med Vet Mycol* 1992; 30: 1-10.
6. Pedroso A, Gomes JM. 4 casos de dermatite verrucosa produzida pela phialophora verrucosa. *Anais Paulistas de Medicina e Cirurgia* 1920; 11: 53-61.
  7. Castro RM, Castro LG. On the priority of description of chromomycosis. *Mykosen* 1987; 30: 397-403.
  8. Rudolph M. Über die brasilianische (figueira). *Archiv für Schiffs- und Tropen-Hygiene* 1914; 18: 498.
  9. Medlar EM. A cutaneous infection caused by a new fungus phialophora verrucosa with a study of the fungus. *J Med Res* 1915; 32: 507-22.
  10. Lane CG. A cutaneous disease caused by a new fungus phialophora verrucosa. *J Cutan Dis* 1915; 33: 840-6.
  11. Brumpt E. *Precis de parasitologie*. Masson & Cie, Paris 1922.
  12. Terra F, Torres M, Fonseca FO, et al. Novo tipo de dermatite verrucosa: micose por acrotheca com associação de leishmaniose. *Brasil Medico* 1922; 36: 363-8.
  13. Minotto R, Bernardi CDV, Mallmann LF, et al. Chromoblastomycosis: a review of 100 cases in the state of rio grande do sul, Brazil. *J Am Acad Dermatol* 2001; 44: 585-92.
  14. Trejos A. *Cladosporium carrionii* n. sp. and the problem of cladosporia isolated from chromoblastomycosis. *Rev Biol Trop* 1954; 2: 75-112.
  15. Abliz P, Fukushima K, Takizawa K, et al. Identification of pathogenic dematiaceous fungi and related taxa based on large subunit ribosomal dna d1/d2 domain sequence analysis. *FEMS Immunology and Medical Microbiology* 2004; 40: 41-9.
  16. de Hoog GS, Vicente A, Gerrits van den Ende AHG, et al. Molecular ecology and pathogenic potential of *fonsecaea* species. *Medical Mycology* 2004; 42: 405-16.
  17. Arango M, Jaramillo C, Cortés A, et al. Auricular chromoblastomycosis caused by rhinocladiella aquaspersa. *Medical Mycology* 1998; 36: 43-5.
  18. Badali H, Bonifaz A, Barrón-Tapia T, et al. Rhinocladiella aquaspersa, proven agent of verrucous skin infection and a novel type of chromoblastomycosis. *Med Mycol* 2010; 48: 696-703.
  19. Hoffmann CD, Danucalov IP, Purim KS, et al. Infections caused by dematiaceous fungi and their anatomoclinical correlations. *An Bras Dermatol* 2011; 86: 138-41.
  20. Kinkead S, Jancic V, Stasko T, et al. Chromoblastomycosis in a patient with a cardiac transplant. *Cutis* 1996; 58: 367-70.
  21. Naka W, Harada T, Nishikawa T, et al. A case of chromoblastomycosis: with special reference to the mycology of the isolated exophiala jeanselmei. *Mycoses* 1986; 29: 445-52.
  22. Barba-Gómez JF, Mayorga J, McGinnis MR, et al. Chromoblastomycosis caused by exophiala spinifera. *J Am Acad Dermatol* 1992; 26: 367-70.
  23. Develoux M, Dieng MT, Ndiaye B, et al. Chromomycosis caused by exophilia spinifera in sahelian Africa. *Annales de Dermatologie et de Venereologie* 2006; 133: 68-9.
  24. Padhye AA, Hampton AA, Hampton MT, et al. Chromoblastomycosis caused by exophiala spinifera. *Clin Infect Dis* 1996; 22: 331-5.
  25. Tomson N, Abdullah A, Maheshwari MB. Chromomycosis caused by exophiala spinifera. *Clin Exp Dermatol* 2006; 31: 239-41.
  26. Najafzadeh MJ, Rezusta A, Cameo MI, et al. Successful treatment of chromoblastomycosis of 36 years duration caused by *fonsecaea monophora*. *Med Mycol* 2010; 48: 390-3.
  27. Xi L, Lu C, Sun J, et al. Chromoblastomycosis caused by a meristematic mutant of *fonsecaea monophora*. *Med Mycol* 2009; 47: 77-80.
  28. Najafzadeh MJ, Sun J, Vicente V, et al. *Fonsecaea nubica* sp. nov, a new agent of human chromoblastomycosis revealed using molecular data. *Med Mycol* 2010; 48: 800-6.
  29. Son YM, Kang HK, Na SY, et al. Chromoblastomycosis caused by phialophora richardsiae. *Ann Dermatol* 2010; 22: 362-6.
  30. Gueidan C. Chaetothyriales. version 29 January 2008 (under construction). <http://tolweb.org/chaetothyriales/29305/2008.01.29> in the tree of life web project <http://tolweb.org/Chaetothyriales/29305/2008.01.29> in The Tree of Life Web Project, 2008.
  31. Najafzadeh MJ, Gueidan C, Badali H, et al. Genetic diversity and species delimitation in the opportunistic genus *fonsecaea*. *Med Mycol* 2009; 47: 17-25.
  32. Redondo-Bellón P, Idoate M, Rubio M, et al. Chromoblastomycosis produced by *aureobasidium pullulans* in an immunosuppressed patient. *Arch Dermatol* 1997; 133: 663-4.
  33. Chowdhary A, Guarro J, Randhawa HS, et al. A rare case of chromoblastomycosis in a renal transplant recipient caused by a non-sporulating species of *rhytidhysterion*. *Med Mycol* 2008; 46: 163-6.
  34. Pimentel ER, Castro LG, Cuce LC, et al. Treatment of chromomycosis by cryosurgery with liquid nitrogen: a report on eleven cases. *J Dermatol Surg Oncol* 1989; 15: 72-7.
  35. Campolina SS, Caligorne RB, Rezende-Silva S, et al. A skin infection mimicking chromoblastomycosis by a capnodialean fungus. *Med Mycol* 2009; 47: 81-5.
  36. Crous PW, Braun U, Groenewald JZ. *Mycosphaerella* is polyphyletic. *Stud Mycol* 2007; 58: 1-32.
  37. Bonifaz A, Carrasco-Gerard E, Saul A. Chromoblastomycosis: clinical and mycologic experience of 51 cases. *Mycoses* 2001; 44: 1-7.
  38. Díaz Almeida JG, Taboas González M, Dube A. Chromoblastomycosis in cuba, retrospective clinical and epidemiologic studies of 72 patients. *Rev Cubana Med Trop* 1978; 30: 95-108.
  39. Perez-Blanco M, Hernández Valles R, García-Humbria L, et al. Chromoblastomycosis in children and adolescents in the endemic area of the falcón state, Venezuela. *Med Mycol* 2006; 44: 467-71.
  40. Restrepo-Moreno A, Calle Velez G, Sanchez-Arbelaez J, et al. A review of medical mycology in Colombia, south America – including presentation of 309 original cases of various mycoses. *Mycopathologia et Mycologia Applicata* 1962; 17: 93-110.
  41. Marques SG, Silva CDM, Saldanha PC, et al. Isolation of *fonsecae pedrosoi* from the shell of the babassu coconut *orbignya phalerata martius* in the Amazon region of maranhao Brazil. *Nihon Ishinkin Gakkai Zasshi* 2006; 47: 305-11.
  42. Silva JP, de Souza W, Rozental S. Chromoblastomycosis: a retrospective study of 325 cases on amazonic region (Brazil). *Mycopathologia* 1998; 143: 171-5.
  43. Montpellier J, Catamei A. Mycose humaine due a un champignon du genre "Hormodendron: *H. algeriensis*, nov. sp.". *Ann Derm Syph* 1927; 8: 626-35.
  44. Esterre P, Andriantsimahavandy A, Ramarcel ER, et al. Forty years of chromoblastomycosis in Madagascar: a review. *Am J Trop Med Hyg* 1996; 55: 45-7.
  45. Fukushiro R. Chromomycosis in Japan. *Int J Dermatol* 1984; 22: 221-9.
  46. Attapattu MC. Chromoblastomycosis – a clinical and mycological study of 71 cases from Sri Lanka. *Mycopathologia* 1997; 137: 145-51.

47. Sharma N, Marfatia YS. Genital elephantiasis as a complication of chromoblastomycosis: a diagnosis overlooked. *Indian Journal of Sexually Transmitted Diseases and AIDS* 2009; 30: 43-45.
48. Xi L, Sun J, Lu C, et al. Molecular diversity of *fonsecaea* (chaetothyriales) causing chromoblastomycosis in southern China. *Med Mycol* 2009; 47: 27-33.
49. Kondo M, Hiruma M, Nishioka Y, et al. A case of chromomycosis caused by *fonsecaea pedrosoi* and a review of reported cases of dematiaceous fungal infection in Japan. *Mycoses* 2005; 48: 221-5.
50. Leslie DF, Beardmore GL. Chromoblastomycosis in Queensland: a retrospective study of 13 cases at the royal Brisbane hospital. *Australas J Dermatol* 1979; 20: 23-30.
51. Santos LD, Arianayagam S, Dwyer B, et al. Chromoblastomycosis: a retrospective study of six cases at the royal Darwin hospital from 1989 to 1994. *Pathology* 1996; 28: 182-7.
52. Tschernjawski J. Chromoblastomycosis. *Archiv für Dermatologie und Syphilis* 1928; 157: 196-206.
53. Symmers WSC. Chromoblastomycosis simulating rhinosporidiosis in a patient from Ceylon. *J Clin Path* 1960; 13: 287-90.
54. Sonck CE. Chromoblastomycosis: five cases from Finland. *Acta Dermato-Venereologica* 1959; 39: 300-9.
55. Chmel L, Svobodova Y, Ranincova A. 1st case of chromoblastomycosis in the Czechoslovakia srr. *Cesk Dermatol* 1963; 38: 145-50.
56. Horáček J, Ulicná L. The 3d case of chromomycosis in Czechoslovakia. *Cesk Dermatol* 1969; 44: 118-20.
57. Otčenásek M, Hubálek Z, Dvorák J, et al. Another clinical case of chromomycosis in Czechoslovakia? *Mykosen* 1968; 11: 719-24.
58. Koch HA, Goeltner E. *Phialophora pedrosoi* als erreger der chromomykose in Deutschland. *Dermatologische Wochenschrift* 1964; 150: 577-81.
59. Kowalska M, Hański W, Bieluńska S. Pierwszy przypadek chromomikozy w Polsce. *Przegl Dermatol* 1972; 59: 349-53.
60. Pindycka-Piaszczyńska M, Krzyściak P, Piaszczyński M, et al. Chromoblastomycosis as an endemic disease in temperate Europe: first confirmed case and review of the literature. *Eur J Clin Microbiol Infect Dis* 2014; 33: 391-8.
61. Azad K, Khanna G, Capoor MR, et al. *Cladophialophora carionii*: an aetiological agent of cutaneous chromoblastomycosis from a non-endemic area, north India. *Mycoses* 2011; 54: 217-9.
62. Esterre P, Andriantsimahavandy A, Raharisolo C. Natural history of chromoblastomycosis in Madagascar and the Indian Ocean. *Bull Soc Pathol Exot* 1997; 90: 312-7.
63. Yaguchi T, Tanaka R, Nishimura K, et al. Molecular phylogenetics of strains morphologically identified as *fonsecaea pedrosoi* from clinical specimens. *Mycoses* 2007; 50: 255-60.
64. Lim SW, Suh MK, Kang GS, et al. Molecular phylogenetics of *fonsecaea* strains isolated from chromoblastomycosis patients in South Korea. *Mycoses* 2011; 54: e415-20.
65. Najafzadeh MJ, Sun J, Vicente VA, et al. Molecular epidemiology of *fonsecaea* species. *Emerg Infect Dis* 2011; 17: 464-9.
66. Salgado CG, da Silva JP, Diniz JA, et al. Isolation of *fonsecaea pedrosoi* from thorns of *mimosa pudica*, a probable natural source of chromoblastomycosis. *Revista Do Instituto De Medicina Tropical De Sao Paulo* 2004; 46: 33-6.
67. Iwatsu T, Okamoto S. Isolation of *phialophora verrucosa* and *fonsecaea pedrosoi* from nature in Japan. *Mycopathologia* 1981; 75: 149-58.
68. Rubin HA, Bruce S, Rosen T, et al. Evidence for percutaneous inoculation as the mode of transmission for chromoblastomycosis. *J Am Acad Dermatol* 1991; 25: 951-4.
69. Gezuele E, Mackinnon JE, Conti-Díaz IA. The frequent isolation of *phialophora verrucosa* and *phialophora pedrosoi* from natural sources. *Sabouraudia* 1972; 10: 266-73.
70. Vicente VA, Attili-Angelis D, Piem MR, et al. Environmental isolation of black yeast-like fungi involved in human infection. *Stud Mycol* 2008; 61: 137-44.
71. Hernandez-Hernandez F, De Bievre C, Camacho-Arroyo I, et al. Sex hormone effects on *phialophora verrucosa* in vitro and characterization of progesterone receptors. *J Med Vet Mycol* 1995; 33: 235-9.
72. Tsuento LT, Arce-Gomez B, Petzl-Erler ML, et al. Hla-a29 and genetic susceptibility to chromoblastomycosis. *J Med Vet Mycol* 1989; 27: 181-5.
73. Bittencourt AL, Londero AT, Andrade JAF. Chromoblastomycose auricular. Relato de um caso. *Revista do Instituto de Medicina Tropical de Sao Paulo* 1994; 36: 181-3.
74. França K, Villa RT, de Azevedo Bastos VR, et al. Auricular chromoblastomycosis: a case report and review of published literature. *Mycopathologia* 2011; 172: 69-72.
75. Hofling-Lima AL, Guarro J, Freitas D, et al. Clinical treatment of corneal infection due to *fonsecaea pedrosoi* – case report. *Arq Bras Oftalmol* 2005; 68: 270-2.
76. Uribe F, Zuluaga AI, Leon W, et al. Histopathology of chromoblastomycosis. *Mycopathologia* 1989; 105: 1-6.
77. Lee MW, Hsu S, Rosen T. Spores and mycelia in cutaneous chromomycosis. *J Am Acad Dermatol* 1998; 39: 850-2.
78. Salgado CG. Fungal x host interactions in chromoblastomycosis. *Virulence* 2010; 1: 3-5.
79. da Silva MB, da Silva JP, Sirleide Pereira YS, et al. Development of natural culture media for rapid induction of *fonsecaea pedrosoi* sclerotic cells in vitro. *J Clin Microbiol* 2008; 46: 3839-41.
80. Sotto MN, Brito TD, Silva AMG, et al. Antigen distribution and antigen-presenting cells in skin biopsies of human chromoblastomycosis. *J Cutan Pathol* 2004; 31: 14-8.
81. Mazo Fávero Gimenes V, Da Glória de Souza M, Ferreira KS, et al. Cytokines and lymphocyte proliferation in patients with different clinical forms of chromoblastomycosis. *Microbes Infect* 2005; 7: 708-13.
82. Ahrens J, Graybill JR, Abishawl A, et al. Experimental murine chromomycosis mimicking chronic progressive human disease. *Am J Trop Med Hyg* 1989; 40: 651-8.
83. Teixeira de Sousa MG, Ghosn EEB, Almeida SR. Absence of CD4+ T cells impairs host defence of mice infected with *fonsecaea pedrosoi*. *Scand J Immunol* 2006; 64: 595-600.
84. Gimenes VMF, De Souza MG, Ferreira KS, et al. Cytokines and lymphocyte proliferation in patients with different clinical forms of chromoblastomycosis. *Microbes Infect* 2005; 7: 708-13.
85. Hayakawa M, Ghosn EEB, de Sousa MGT, et al. Phagocytosis, production of nitric oxide and pro-inflammatory cytokines by macrophages in the presence of dematiaceous fungi that causes chromoblastomycosis. *Scand J Immunol* 2006; 64: 382-7.
86. da Silva JP, da Silva MB, Salgado UI, et al. Phagocytosis of *fonsecaea pedrosoi* conidia, but not sclerotic cells caused by langerhans cells, inhibits cd40 and b7-2 expression. *FEMS Immunol Med Microbiol* 2007; 50: 104-11.
87. Bocca AL, Brito PPMS, Figueiredo F, et al. Inhibition of nitric oxide production by macrophages in chromoblastomycosis: a role for *fonsecaea pedrosoi* melanin. *Mycopathologia* 2006; 161: 195-203.

88. Sousa MDG, Reid DM, Schweighoffer E, et al. Restoration of pattern recognition receptor costimulation to treat chromoblastomycosis, a chronic fungal infection of the skin. *Cell Host Microbe* 2011; 9: 436-43.
89. De A, Gharami RC, Datta PK. Verrucous plaque on the face: what is your diagnosis? *Dermatol Online J* 2010; 16: 6.
90. Gross DJ, Schosser RH. Chromomycosis on the nose. *Arch Dermatol* 1991; 127: 1831-2, 1834-5.
91. Carrion A. Chromoblastomycosis. *Annls New York Academy Science* 1950; 50: 1255-82.
92. Restrepo A, Gonzalez A, Gomez I, et al. Treatment of chromoblastomycosis with itraconazole. *Annals of the New York Academy of Science* 1988; 544: 504-16.
93. Ogawa MM, Alchorne MM, Barbieri A, et al. Lymphoscintigraphic analysis in chromoblastomycosis. *Int J Dermatol* 2003; 42: 622-5.
94. Esterre P, Pecarrère JL, Raharisolo C, et al. Carcinome épidermoïde développé sur des lésions de chromomycose. [Squamous cell carcinoma arising from chromomycosis. report of two cases]. *Ann Pathol* 1999; 19: 516-20.
95. Foster HM, Harris TJ. Malignant change (squamous carcinoma) in chronic chromoblastomycosis. *Aust N Z J Surg* 1987; 57: 775-7.
96. Jamil A, Lee YY, Thevarajah S. Invasive squamous cell carcinoma arising from chromoblastomycosis. *Med Mycol* 2012; 50: 99-102.
97. Torres E, Beristain JG, Lievanos Z, et al. Chromoblastomycosis associated with a lethal squamous cell carcinoma. *An Bras Dermatol* 2010; 85: 267-70.
98. Al-Hedaithy SS, Jamjoom ZA, Saeed ES. Cerebral phaeohyphomycosis caused by *fonsecaea pedrosoi* in Saudi Arabia. *APMIS: Acta Pathologica, Microbiologica, et Immunologica Scandinavica* 1988; 3: 94-100.
99. McGinnis M. Chromoblastomycosis and phaeohyphomycosis: new concepts, diagnosis and mycology. *J Am Acad Dermatol* 1983; 8: 1-16.
100. Nobrega JP, Rosemberg S, Adami AM, et al. *Fonsecaea pedrosoi* cerebral phaeohyphomycosis ("chromoblastomycosis"): first human culture-proven case reported in Brazil. *Revista do Instituto de Medicina Tropical de Sao Paulo* 2003; 45: 217-20.
101. Saberi H, Kashfi A, Hamidi S, et al. Cerebral phaeohyphomycosis masquerading as a parafalcian mass: case report. *Surg Neurol* 2003; 60: 354-9.
102. Santosh V, Khanna N, Shankar SK, et al. Primary mycotic abscess of the brain caused by *fonsecaea pedrosoi*. Case report. *J Neurosurg* 1995; 82: 128-30.
103. de Andrade TS, Cury AE, de Castro LG, et al. Rapid identification of *fonsecaea* by duplex polymerase chain reaction in isolates from patients with chromoblastomycosis. *Diagn Microbiol Infect Dis* 2007; 57: 267-72.
104. Abliz P, Fukushima K, Takizawa K, et al. Specific oligonucleotide primers for identification of *cladophialophora carrionii*, a causative agent of chromoblastomycosis. *J Clin Microbiol* 2004; 42: 404-7.
105. Ameen M. Chromoblastomycosis: clinical presentation and management. *Clin Exp Dermatol* 2009; 34: 849-54.
106. Esterre P, Queiroz-Telles F. Management of chromoblastomycosis: novel perspectives. *Curr Opin Infect Dis* 2006; 19: 148-52.
107. Ameen M. Managing chromoblastomycosis. *Tropical Doctor* 2010; 40: 65-7.
108. Queiroz-Telles F, Purim KS, Fillus JN, et al. Itraconazole in the treatment of chromoblastomycosis due to *fonsecaea pedrosoi*. *Int J Dermatol* 1992; 31: 805-12.
109. Kumarasinghe SPW, Kumarasinghe MP. Itraconazole pulse therapy in chromoblastomycosis. *Eur J Dermatol* 2000; 10: 220-2.
110. Ungpakorn R, Reangchainam S. Pulse itraconazole 400 mg daily in the treatment of chromoblastomycosis. *Clin Exp Dermatol* 2006; 31: 245-7.
111. Bonifaz A, Martinez-Soto E, Carrasco-Gerard E, et al. Treatment of chromoblastomycosis with itraconazole, cryosurgery and a combination of both. *Int J Dermatol* 1997; 36: 542-7.
112. Sevigny GM, Ramos-Caro FA. Treatment of chromoblastomycosis due to *fonsecaea pedrosoi* with low-dose terbinafine. *Cutis* 2000; 66: 45-6.
113. Negroni R, Tobón A, Bustamante B, et al. Posaconazole treatment of refractory eumycetoma and chromoblastomycosis. *Revista do Instituto de Medicina Tropical de Sao Paulo* 2005; 47: 339-46.
114. Bonifaz A, Paredes-Solis V, Saul A. Treating chromoblastomycosis with systemic antifungals. *Expert Opin Pharmacother* 2004; 5: 247-54.
115. Medina-Ramirez M. Treatment of chromomycosis with liquid nitrogen. *Int J Dermatol* 1973; 12: 250-4.
116. Kullavanijaya P, Rojanavanich V. Successful treatment of chromoblastomycosis due to *fonsecaea pedrosoi* by the combination of itraconazole and cryotherapy. *Int J Dermatol* 1995; 34: 804-7.
117. Castro LGM. Mecanismo de cura da cromomycose pela criocirurgia com nitrogênio líquido. *An Bras Dermatol* 1989; 64: 297-300.
118. Castro LGM, Pimentel ERA, Lacaz CS. Treatment of chromomycosis by cryosurgery with liquid nitrogen: 15 years' experience. *Int J Dermatol* 2003; 42: 408-12.
119. Kikuchi Y, Kondo M, Yaguchi H, et al. A case of chromomycosis caused by *fonsecaea pedrosoi* presenting as a small plaque on the left upper arm: a review of reported cases of dematiaceous fungal infection in Japan. *Japan J Med Mycol* 2007; 48: 85-9.
120. Tagami H, Ohi M, Aoshima T. Topical heat therapy for cutaneous chromomycosis. *Arch Dermatol* 1979; 115: 740-1.
121. Tagami H, Ginoza M, Imaizumi S, et al. Successful treatment of chromoblastomycosis with topical heat therapy. *J Am Acad Dermatol* 1984; 10: 615-9.
122. Yanase K, Yamada M. "Pocket-warmer" therapy of chromomycosis. *Arch Dermatol* 1978; 114: 1095.
123. Tanuma H, Hiramatsu M, Mukai H, et al. A case of chromoblastomycosis effectively treated with terbinafine. characteristics of chromoblastomycosis in the Kitasato region, Japan. *Mycoses* 2000; 43: 79-83.
124. Usuki K, Yotsumoto S, Hamada H, et al. A case of chromomycosis with tumor-like growth. *J Dermatol* 1996; 23: 643-7.
125. Hira K, Yamada H, Takahashi Y, et al. Successful treatment of chromomycosis using carbon dioxide laser associated with topical heat applications. *J Eur Acad Dermatol Venereol* 2002; 16: 273-5.
126. Kuttner BJ, Siegel RJ. Treatment of chromomycosis with CO2 laser. *J Dermatol Surg Oncol* 1986; 12: 965-8.
127. Tsianakas A, Pappai D, Basoglu Y, et al. Chromomycosis – successful CO2 laser vaporization. *J Eur Acad Dermatol Venereol* 2008; 22: 1385-6.
128. Andrade TS, Castro LG, Nunes RS, et al. Susceptibility of sequential *fonsecaea pedrosoi* isolates from chromoblastomycosis patients to antifungal agents. *Mycoses* 2004; 47: 216-21.